

Presented by

the Author

1898

TRANSFERRED TO
YALE MEDICAL LIBRARY



Digitized by the Internet Archive
in 2012 with funding from
Open Knowledge Commons and Yale University, Cushing/Whitney Medical Library

http://archive.org/details/treatiseondiseas00buck

A TREATISE

ON

DISEASES OF THE EAR

TOGETHER WITH A BRIEF SKETCH OF THE ANATOMY AND PHYSIOLOGY OF THIS ORGAN

BY

ALBERT H. BUCK, M.D.

CLINICAL PROFESSOR OF THE DISEASES OF THE EAR, COLLEGE OF PHYSICIANS AND SURGEONS, MEDICAL DEPARTMENT OF COLUMBIA UNIVERSITY, NEW YORK; CONSULTING AURAL SURGEON, NEW YORK EYE AND EAR INFIRMARY AND THE PRESBYTERIAN HOSPITAL

Third Revised Edition

NEW YORK
WILLIAM WOOD AND COMPANY
1898

Copyright, 1898
By WILLIAM WOOD AND COMPANY

RF121
898 Bu

PREFACE.

During the past few years the boundary-lines of the territory which was formerly supposed to belong to the aural surgeon have been very materially extended. At first, the larger part of the domain of rhinology was annexed, the legitimate right of such a transfer being recognized by all candid minds. Then, later, when it was discovered that many of the intracranial diseases of otitic origin—previously looked upon as almost necessarily fatal—were to a large extent curable, aural surgeons were obliged to decide promptly whether they should leave this new work entirely to the general surgeon, or should assume all its grave responsibilities themselves. The great majority of them accepted the trust without any hesitation; and the numerous reports of successful operations that have been published by them in recent years, both abroad and in this country, show that this new domain also has been rightfully added to the aural surgeon's former territory.

In the preparation of the present edition of this treatise, careful account has been taken of these important changes, and at the same time a thorough revision has been effected in those portions of the book which treat of the fully accepted topics of practical otology. And here I desire to make grateful acknowledgments to my publishers for their generous course in deciding to make an entirely new set of plates, thus enabling me to alter and revise the text as fully as I might desire.

Finally, I wish to acknowledge my indebtedness to my associate, Dr. Robert Lewis, Jr., for his contribution of the chapter on Affections of the Nasal Cavities and Vault of the Pharynx.

No. 14, East 45th Street;
New York, August 14th, 1898.

CONTENTS.

CHAPTER I.

PAGE

General Diagnosis, ... 1
Tests of the Hearing Power, ... 3
The Use of the Tuning-Fork, ... 7
Ear Specula and Reflectors, ... 12
Introduction of the Speculum and Use of the Reflector, . . . 17
Anatomical Considerations, ... 17
Sources of Light, ... 19
Position of the Patient in Relation to the Light, . . . 19
The Actual Examination, ... 20
Accessory Instruments Used in the Examination of the Ear, . 22

CHAPTER II.

General Pathology, ... 33
The Locality First Affected by the Inflammation, ... 35
The Extent to which the Inflammation May Involve the Outer, Middle, or Internal Ear, ... 35
The Extent to which an Inflammation of One of the Three Cavities May Involve the Other Two, and Perhaps Also Neighboring Parts, 36
The Characteristic Differences between Inflammations of the Ear, . 39
The Alterations Produced in the Tissues and in the Secretions, . 44

CHAPTER III.

Analysis of Symptoms, ... 47
Disturbances of the Function of Hearing, ... 47
Diminished Hearing, ... 47
Degree of Impaired Hearing and Its Rapidity of Development, . 47
Circumstances Preceding or Accompanying the Deafness, . . 48
Variable Character of the Hearing, ... 50
Hearing Better in the Midst of Noise, ... 52
Diminished Range of Hearing, and Deafness for Certain Tones, 52
Sensation of Something Moving in the Ear when the Head is Moved, 53
Sensation of Pressure or Fulness in the Ear, ... 54
Unnatural Resonance of One's Own Voice in the Affected Ear, . 55
Pulsation or Throbbing in the Ear, ... 56
Itching; Soreness, ... 57

PAGE
Pain, ... 57
Pain Produced in the Ear by Movements of the Jaw, . . . 60
Discharge from the Ear, ... 61
Sources, ... 61
Duration, ... 61
Physical Characteristics, ... 62
Vertigo, ... 62
Sensation of Numbness Around the Ear, ... 63

CHAPTER IV.

The Various Alterations in Color, Texture, and Position Presented by the Membrana Tympani, and Their Significance, 64
Normal Conditions, ... 64
Pathological Conditions, ... 66
Hyperæmia, ... 66
Calcareous Deposits, ... 68
Thickening and Hardening, ... 70
Atrophy, ... 70
Abnormal Degree of Retraction, ... 71
Vascular New-Growths, ... 75
Absence of the Malleus, ... 75
Hook-Shaped Manubrium Mallei, ... 76
Horny Growth, ... 76
Cicatrices, ... 76
Adhesions, ... 77
Habitual Distention, ... 78
Perforations, ... 79
Ruptures, ... 79
Cyst-Like Tumors, ... 79
Granulation-Tissue, ... 79
Syphilitic and Tubercular Lesions, ... 81

CHAPTER V.

Diseases of the Auricle, ... 82
Eczema, ... 82
Hæmatoma Auris; Perichondritis, ... 86
New-Growths, ... 96
Fibroid Tumors, ... 96
Epithelioma, ... 97
Cornu Cutaneum, ... 98
Miscellaneous Affections, ... 98
Syphilitic Ulcerations, ... 99
Cirsoid Aneurism, ... 99
Cleft Lobule, ... 100
Wounds and Contusions, ... 100
Burns, ... 101

PAGE
Frost-Bite, ... 101
Herpes Zoster, ... 102
Congenital Malformations, ... 102
Fistula Auris Congenita, ... 103

CHAPTER VI.

Diseases of the External Auditory Canal, ... 105
Impacted Cerumen, ... 105
Circumscribed Inflammation, ... 113

CHAPTER VII.

Diseases of the External Auditory Canal (*Continued*), . . 121
Diffuse Inflammation, ... 121
Desquamative Type of Inflammation, ... 138
Growth of Aspergillus in the Canal, ... 142
Formation of Bands and Membranous Structures in the Canal, . . 144

CHAPTER VIII.

Diseases of the External Auditory Canal (*Continued*), . . 151
Syphilitic Disease, ... 151
Foreign Bodies, ... 155
Wounds and Other Injuries, ... 164
New-Growths, ... 166
Osteoma, ... 166
Carcinoma, ... 171
Sarcoma, ... 173
Myxo-Fibroma, ... 177
Cysts, ... 177

CHAPTER IX.

Methods of Examining the Middle Ear, ... 179
Direct Inspection, ... 179
Inflations of the Middle Ear, ... 180
Valsalva's Method, ... 180
Politzer's Method, ... 181
Catheterization of the Eustachian Tube, ... 189
Other Methods of Investigating the Condition of the Eustachian Tube, ... 197

CHAPTER X.

Classification and Etiology of Diseases of the Middle Ear, . 198
Classification, ... 198
General Etiology, ... 199

CHAPTER XI.

PAGE

NON-SUPPURATIVE OR CATARRHAL INFLAMMATIONS OF THE MIDDLE EAR, ... 205
Eustachian Catarrh, ... 206
Simple Acute Catarrhal Inflammation of the Middle Ear, . . . 208
Serous or Mucous Exudation into the Tympanic Cavity, . . . 219

CHAPTER XII.

NON-SUPPURATIVE OR CATARRHAL INFLAMMATIONS OF THE MIDDLE EAR (*Continued*), ... 230
Chronic Catarrhal Inflammation, ... 230
Nasal and Vault Lesions, ... 231
Goutiness, ... 234
Collateral and Infrequent Exciting Causes, ... 240
Climate, ... 241
Tobacco-Smoking, ... 241
The Poller of Certain Plants, ... 242
Occupation, ... 242
Certain Bodily Diseases, ... 243
Prognosis, ... 244
Treatment, ... 244

CHAPTER XIII.

THOSE PATHOLOGICAL CONDITIONS OF THE FAUCES, VAULT OF THE PHARYNX, AND NASAL CAVITIES, WHICH PLAY AN IMPORTANT PART IN THE CAUSATION OF EAR DISEASES, ... 247
Methods of Examining the Parts, ... 247
The Kind of Light Required, ... 247
Tongue-Depressors, ... 250
Nasal Specula, ... 251
Anterior and Posterior Rhinoscopic Examinations, . . . 251
Hypertrophy of the Lymphoid Tissue in the Vault of the Pharynx, . 254
Etiology, ... 254
Pathology, ... 256
Symptomatology, ... 260
Diagnosis, ... 267
Mode of Making a Digital Examination of the Pharyngeal Vault, . 268
Prognosis, ... 269
Treatment, ... 270
Operation for the Removal of Adenoid Growths from the Pharyngeal Vault, ... 272
Post-Operative Treatment, ... 276
Hypertrophy of the Faucial Tonsils, ... 277
Treatment, ... 278
Tonsillotomy, ... 280

PAGE
Hypertrophy of the Nasal Mucous Membrane, ... 282
Diagnosis, ... 282
Treatment, ... 283
Deformities of the Nasal Septum, ... 286

CHAPTER XIV.

Acute Suppurative Inflammations of the Middle Ear, . . 292
General Remarks, ... 292
Influence of Anatomical Peculiarities, ... 292
Influence of Bacterial Organisms and Other Factors, . . 293
Classification, ... 295
Acute Suppurative Inflammation of the Middle Ear, . . 295
Symptomatology and Course of the Disease, . . . 296
Sequelæ and Complications, ... 303
Diagnosis, ... 304
Prognosis, ... 308
Treatment, ... 310
Measures Directly Antagonistic to the Bacteria, . . 310
Measures for Reducing the Hyperæmia, ... 311
Heat and Cold Compared as Therapeutic Agents, . . 311
An Effective Mode of Employing Heat, ... 313
The Best Method of Applying Cold to the Ear, . . . 313
Local Blood-Letting, ... 314
Paracentesis of the Membrana Tympani, ... 316
Bodily Rest and Avoidance of Physical Exercise Conducive to a Diminution of Hyperæmia of the Middle Ear, . . . 319
Treatment of the Disease After the Acute Stage has Subsided, . 320
Systematic Douching of the External Meatus with Hot Water, . 321
Intratympanic Injections of a Silver-Nitrate Solution, . . 322
General Measures which Aid in Arresting the Discharge, . . 326

CHAPTER XV.

Chronic Suppurative Inflammation of the Middle Ear, . . 328
Etiology, ... 328
Course of the Disease, ... 329
Diagnosis, ... 330
Prognosis, ... 332
Illustrative Cases, ... 333
Group 1. Cases in which the persistence of the discharge is clearly due to a paretic condition of the blood-vessels of the middle ear. The different obstacles which have to be overcome in curing this paresis are also set forth in these histories, 333
Group 2. Cases in which there is no demonstrable bone caries in the middle ear; the odorless discharge being kept up, apparently, by the presence of a polypoid growth in the tympanum, ... 338

PAGE

Group 3. Cases in which the continuance of the discharge seems to be due in part to a proliferative process in some portion of the tympanic mucous membrane, and in part to a limited caries of the bony walls of the tympanum, ... 341

Group 4. Cases in which cheesy and epithelial products accumulate in the vault of the tympanum, undergo decomposition, and so contribute largely to a continuance of the discharge, ... 342

Group 5. Cases in which larger portions of the temporal bone have been destroyed, ... 347

Polypoid Growths, ... 349

Pathological Anatomy, ... 349

Etiology, ... 349

Diagnosis, ... 350

Treatment, ... 351

Treatment, ... 352

Removal of a Polypoid Growth and the After-Treatment of the Stump, ... 352

Removal of Impacted Masses of Cast-Off Epithelium and Cheesy Débris, ... 358

Treatment of an Area of Bone Caries, ... 361

CHAPTER XVI.

Permanent Alterations and Deformities Caused by Suppurative Inflammation of the Middle Ear, ... 363

Treatment, ... 370

CHAPTER XVII.

Miscellaneous Pathological Conditions and Disturbances in the Middle Ear, ... 373

Foreign Bodies, ... 373

Injuries, ... 375

Ruptures of the Membrana Tympani Without Accompanying Damage of Other Parts of the Middle Ear, ... 375

Direct Injuries Involving Various Parts of the Middle Ear, . . 377

Fractures by Contrecoup, ... 380

Malformations, ... 386

New-Growths, ... 387

Cysts, ... 396

Syphilis, ... 397

Tuberculosis, ... 398

CHAPTER XVIII.

Diseases of the Mastoid Process and Neighboring Structures, . 404

Acute Mastoid Disease, ... 404

PAGE
Anatomical and Pathological Considerations, ... 404
Symptomatology and Diagnosis, ... 412
Illustrative Cases, ... 419
Prognosis, ... 427

CHAPTER XIX.

Diseases of the Mastoid Process and Neighboring Structures (*Continued*), ... 429
Acute Mastoid Disease: Operative Treatment, ... 429
The Schwartze Operation, ... 430
After-Treatment, ... 443

CHAPTER XX.

Diseases of the Mastoid Process and Neighboring Structures (*Continued*), ... 446
Chronic Mastoid Disease, ... 446
Symptomatology, ... 448
Diagnosis, ... 449
Illustrative Cases, ... 450
Treatment, ... 453
Stacke's Radical Operation, ... 454
Schwartze-Stacke Operation, ... 458

CHAPTER XXI.

Periphlebitis and Infective Thrombosis of the Sigmoid Sinus, 460
Symptomatology and Diagnosis, ... 460
Illustrative Cases, ... 465
Further Operative Measures Required when it is Discovered that Thrombosis of the Sigmoid Sinus Exists, . . 483

CHAPTER XXII.

Meningitis; Extradural Abscess; and Abscess of the Brain, . 488
Symptomatology and Diagnosis, ... 488
Analysis of Symptoms, ... 489
Earlier Stage, ... 489
Later Period of the Disease, ... 490
Differential Diagnosis, ... 493
Illustrative Cases, ... 495
Treatment, ... 511

CHAPTER XXIII.

Functional and Organic Diseases of the Auditory Nerve, . . 516
Pathology, ... 516

PAGE
Illustrative Cases, ... 522
Diagnosis, ... 540
Prognosis, ... 541
Treatment, ... 541

CHAPTER XXIV.

Sketch of the Anatomical Relations and Physiology of the Ear, ... 542
Anatomy of the Middle Ear, ... 542
Anatomy of the Labyrinth, ... 554
Mode of Action of the Labyrinthine Mechanism, ... 562
Vascular Relations of the Different Parts of the Ear, . . . 570

General Index, ... 575

DISEASES OF THE EAR.

CHAPTER I.

GENERAL DIAGNOSIS.

In investigating cases in which complaint is made of the ear, we can derive aid, in ascertaining the true nature of the disturbance, from several different sources, viz.: from the patient's own account (or that of some member of the family); from various outward manifestations discoverable by simple inspection and palpation; to a certain extent from the body-temperature and the pulse-rate; and, finally, from an examination of the more or less hidden approaches to the deeper cavities of the ear. In almost all cases the information derived from any one of these sources needs to be confirmed by the evidence obtained from the others before we can safely adopt a positive diagnosis. Thus, for example, in examinations with the speculum and reflected light, the picture presented to the eye of the examiner often possesses no absolute diagnostic value; that is, it may represent the legitimate accompaniment or result of either one of two or three different pathological processes. The true interpretation of the picture is obtained only after we have learned the history of the case, have inspected the accessible parts in the immediate neighborhood, and have tested the hearing and perhaps also the body-temperature.

To save time, and also to make sure of not forgetting some important step in the examination, the beginner will find it useful in practice to adopt a routine plan of procedure in every case. First, he should get the history of the trouble, whatever it may be, from the patient. He should also test the hearing of both ears (watch and voice tests), and make a note of the results ascertained. Although in the vast majority of instances he will derive no material aid from the procedure, he should nevertheless apply the vibrating tuning-fork to the patient's forehead or vertex, and note any predominance of the sound (as observed by the latter) in one or the

other ear. Then, if he is dealing with a case in which there has been either spontaneous pain or tenderness upon pressure, he should observe the appearance of the auricle and of the skin covering the mastoid process; and he should pass his finger firmly over the regions in front of and behind the ear, and at the same time he should observe whether the glands on the side of the neck, below the ear, are enlarged or tender, and whether there is any evidence of phlebitis or thrombosis of the jugular vein. In the cases of a more serious type, he will be likely to find limited areas of tenderness at spots which are comparatively remote from the ear—*e.g.*, in the vicinity of the occipital protuberance, and sometimes near the vertex. Having examined all these external parts, and having learned to what extent, if at all, they have become involved through a spreading of inflammation from the deeper parts of the ear, he should next proceed to inspect, by aid of speculum and reflected light, the condition of the external auditory canal and drum membrane. If, as a result of this inspection, he finds that the membrana tympani is healthy and that the disease is confined to the external auditory canal, he may consider his task in diagnosis completed. But if, on the other hand, he finds that the middle ear is not in a normal condition—and in the majority of cases this is what he may confidently expect to find—he will have to subject the patient's fauces, pharyngeal vault, and nasal cavities to a careful scrutiny before he can consider that he has done full justice to the problem before him.

Such a routine plan of examining a case of ear disease will place the physician in possession of the most prominent facts; but, nevertheless, in many instances it will be found necessary to supplement them with still others. I will give a single instance of this by way of illustration:

The case, we will suppose, is one in which the external meatus is found to be closed by a swollen condition of its soft parts; and this, in connection with the swollen and tender condition of the mastoid integuments, suggests the question: Are all these manifestations due simply to an inflammation that has originated primarily in the outer canal of the ear, or are they due to an inflammation of the tympanic cavity which has spread to such an extent and has reached such a degree of violence that the outward parts have become secondarily involved? If we could inspect the membrana tympani and the soft parts which lie just outside of it in the canal, it would doubtless be an easy matter to answer this question cor-

rectly. But the swollen condition of the meatus prevents us from doing this, and we are therefore obliged to seek a solution of the problem in some other way. Thus, for example, we may learn from the patient in what order the different symptoms—tinnitus, impairment of hearing, pain, tenderness of outer parts, etc.—have manifested themselves. The development of tinnitus and deafness only after the ear has been painful and tender for one or more days, will furnish *prima facie* evidence of an acute inflammation of the soft parts of the external auditory canal; while the existence of impaired hearing, tinnitus, and perhaps also deep-seated throbbing, for a period of several hours or days before the development of tenderness on pressure, indicates that the inflammation must have begun in the middle ear. A history of an antecedent "cold in the head" or of an attack of the grippe would almost render this diagnosis positive.

This sort of problem, which relates only to the starting-point and extent of the disease, is generally not so very difficult to solve; but there are others which will often compel us to weigh carefully a number of factors that belong entirely outside the ordinary domain of otology. I refer to that class of cases in which progressive and serious impairment of the hearing is associated with visible lesions of comparative insignificance. The inquiry here suggested will carry the specialist out of the narrow limits of aural into the broad domain of general pathology; for it not infrequently happens that a disturbance of the digestive processes, an inflammation of the pelvic organs (in the female), an anæmic state, or that ill-defined general condition termed "goutiness" or "lithæmia," is the important etiological factor.

We may now proceed to consider more in detail the subjects which have simply been touched upon in the preceding general remarks.

TESTS OF THE HEARING POWER.

In the case of an adult, considerable dependence may be placed upon the individual's own statements in regard to the character and degree of the impairment of the hearing; but in the case of a child the information desired must be obtained from the parents or the guardian. Nothing is more common, however, than to hear patients —intelligent adults—say very positively that only one of their ears is affected, whereas on examination it is ascertained that the ear which is supposed to be sound is in reality but little

less impaired than the other. Other persons sometimes maintain stoutly that the hearing of one ear is entirely gone, when in reality the organ possesses a very useful degree of hearing power. In no case, therefore, is it safe to accept unreservedly the patient's statements in regard to the degree of impairment of his hearing.

The ticking of a watch, and words or sentences spoken either in a whisper or in an ordinary tone of voice, constitute the only tests which have ever been employed to any great extent. The watch will be found useful, in most cases, in ascertaining the rate of improvement of the hearing while the patient is under treatment. However, the results obtained from the employment of this test are not always trustworthy; that is, an improvement in the patient's power to hear the ticking of a watch does not always indicate that a corresponding improvement has taken place in his power to hear speech. On the other hand, a patient will often improve very decidedly in his power to hear speech, and yet not be able to hear the ticking of the watch a single inch farther than he did when the test was first tried. It would seem, therefore, as if speech ought always to be employed as the more satisfactory of the two tests. Theoretically, this is indeed true, but in practice, and especially in the small offices which most of us occupy, the speech test is found to be very unsatisfactory. In this state of things the physician is often compelled to depend almost entirely upon the patient's own observations in regard to any improvement that may take place in his hearing power.

In *testing the hearing by means of a watch*, care should be taken to employ one which ticks rather loudly. The feebler-ticking watches will be found of very little use except in those cases in which the impairment of the hearing is comparatively slight. So far as the test itself is concerned, it is better to hold the watch first at a point which lies beyond the hearing distance of the ear which is being tested, and then gradually to bring it nearer and nearer to the ear, until the patient is able to distinguish the sound of the ticking. As a rule, it is not necessary to ask the patient to close the other ear during the progress of the test, as the ticking of an ordinary watch is a sound of too great feebleness to reach the opposite ear. The proximity of a wall, door, or other reflecting surface, may, however, render such a precaution necessary. If the hearing is markedly affected, the ticking of the watch may not be heard even when it is pressed firmly against the auricle. In this connec-

tion it should be remarked that a patient who fails to distinguish the sound of the ticking when the watch is pressed against the auricle will often hear the sound quite distinctly when the watch is held firmly between the teeth or is pressed against the temple or against the mastoid process. In young children the watch test is generally not to be trusted.

Other sources of sound besides the watch have been employed as means of testing the hearing power, but they have all proved to be more or less unsatisfactory. Some years ago Prof. Adam Politzer, of Vienna, in the hope of furnishing a source of sound of uniform character and intensity, devised a small instrument which he calls an "*acoumeter*." The click of this instrument may be heard, in a quiet room, at a distance of thirty feet. In certain cases, therefore, testing by the acoumeter would undoubtedly reveal a change in the hearing power when the employment of the watch might fail to show any change whatever. The superiority of this instrument over a loud-ticking watch has not proved to be so great as was at first anticipated, and accordingly it has failed to find general acceptance, at least on this side of the Atlantic. The clicking, in this instrument, is produced by the fingers, and is consequently irregular and of varying distinctness or intensity. If the clicking could be rendered rhythmical and of uniform intensity through the action of a suitable clockwork mech-

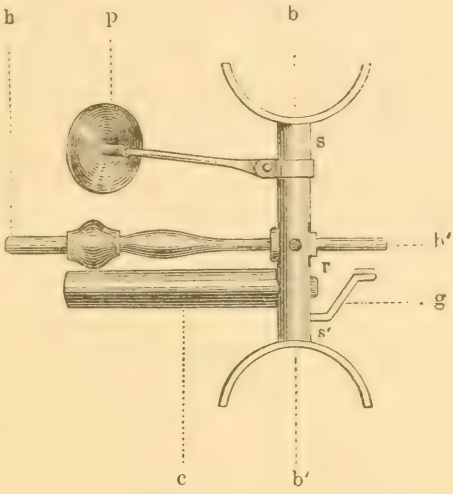

FIG. 1.—Politzer's Acoumeter. (Full size.) *c*, solid cylinder of steel, which is fastened to the stem of hard rubber (*s s'*) by a screw (*r*). A percussion hammer (*h h'*), by means of which the sounds are produced, is attached (by a loose joint) to the rubber stem at a point just above *r*. Two semicircular end-pieces, which are fastened, one at each end of the hard-rubber stem, furnish support for the experimenter's thumb and forefinger. By means of the metal disc (*p*), which is attached to a slender hinged stem, the apparatus may be used in testing bone conduction. In actual use the handle of the percussion hammer is pressed against the support (*g*) and then suddenly released. The weight of the farther end of the hammer causes it to strike with sufficient force against the steel cylinder (*c*).

anism, I believe that the acoumeter thus modified would prove superior to the watch in a large class of cases.

So long as we continue to use the watch as a means of testing the hearing, the *fractional method of recording the hearing distance* is undoubtedly the best. This method, which was first suggested by Dr. Prout, of Brooklyn, N. Y., requires that the numerator of the fraction should represent the distance at which the watch is heard by the person whose hearing is being tested, while the denominator indicates the average distance at which a reasonable number of persons with good hearing can distinguish the ticking of the same watch. It is only when we have occasion to report a case that it is desirable to designate the hearing distances in fractional terms. In our own private records the actual distances are alone sufficient, as the tests are always made with the same watch.

The employment of *spoken or whispered words* as a means of testing the hearing is also involved in many difficulties. I have already mentioned the chief obstacle which in many cases practically precludes the employment of speech as a test, viz., the smallness of the physician's office. But there are other difficulties which are scarcely less serious. I refer to the fact that certain words are much more readily distinguished by the ear than others; that it is not always possible to exclude outside noises; and that the speaker cannot uniformly employ the same pitch, loudness, and distinctness of voice. Hence this test is at best a very crude one. Indeed, it is not a possible thing, to-day, to express degrees of hearing power with anything approaching to the accuracy with which the degree of acuteness of vision may be expressed.

In testing the hearing with spoken or whispered words, certain precautions will be found necessary. Thus, for example, if we wish to test the hearing of one ear by means of spoken words, it is absolutely necessary that the other ear should be closed quite firmly. The patient should also sit in such a position that the physician's voice may be thrown directly against the ear which remains open, *i.e.*, at right angles to that side of the head. If we desire to test the hearing power of both ears, the patient should sit facing us, but with both his eyes closed. Deaf people sometimes possess the power of "reading the lips" to such a remarkable degree that the test can hardly be considered a fair one unless the patient keeps his eyes closed. It is also not sufficient for the patient to answer that he has understood what was said to him; he should be required to repeat the exact words spoken by the physician. The difficulty in

regard to the determination of the hearing distance may be roughly solved in the following manner: Repeat, in an ordinary tone of voice, certain numbers (of two or three figures) at a distance of say twenty feet. The patient, we will assume, hears only a part of them correctly. Try the experiment again at a nearer point, say at twelve feet. If he hears all the words correctly, twelve feet may be taken as the hearing distance for that particular day or moment. If the room is so small that we cannot ascertain the maximum distance at which the patient can hear words spoken in an ordinary tone of voice, we must speak in a whisper in repeating the test words. At each distance selected, at least three sets of complex numbers should be repeated, as otherwise the test can scarcely be considered a fair one. The results of these tests are recorded, and at some later date the experiment is to be repeated. By a comparison of the results obtained at these two trials, we may obtain some idea—although not a very accurate one—of the progress of the case. But, after all, the sources of error are so many that we often feel disposed to place our chief reliance upon the patient's own statements, especially if he be a man of intelligence and not given to imagining.

THE USE OF THE TUNING-FORK.

It is only in exceptional cases that we derive valuable information from the tuning-fork test. Nevertheless, it is a good plan to make its use a matter of routine practice in at least the majority of cases. The ordinary forks employed for the purpose of giving a tone of a certain pitch are of very little use to the aural surgeon. The sound is so feeble in intensity and dies away so quickly that, even if the patient should be able to hear it, the duration of the sound is so very brief that he can scarcely reach a correct conclusion in regard to the auditory sensations which it may have produced before the vibrations will have ceased altogether. The surgical-instrument makers now keep for sale a heavy prismatic fork, of low pitch, and provided with movable clamps attached to each arm, which will be found well adapted to the physician's needs. The presence of the clamps prevents the formation of overtones, which, in the ordinary tuning-forks, constitute a very disturbing element. By striking one of the arms of the instrument lightly upon the knee, one can call forth sonorous vibrations which continue audible for a period of several seconds—long enough to enable the surgeon to place the handle of the fork on the patient's forehead, just above

the bridge of the nose, and to permit the patient to observe calmly in which ear the sound preponderates.

If the preponderance of sound is in the affected ear we may exclude at once any serious disease of the labyrinthine structures or of the auditory nerve at some other point in its course; or, in other words, we may safely assume that the disease is located either in the middle ear or Eustachian tube, or in the external auditory canal. This is in accordance with the results observed in



Fig. 2.—Heavy Prismatic Tuning-fork with Movable Clamps. (Reduced ⅓.)

Fig. 3.—Lucae's Graduated Tuning-fork. (Reduced ¼.) (The pitch desired—within certain fixed limits—may be obtained by adjusting the clamps at different distances from the ends of the fork.)

Weber's experiment, which revealed the fact that when, in a person with normal ears, the orifice of one external auditory canal is closed, the sound produced by a vibrating tuning-fork, placed firmly upon the vertex, is heard more loudly in the closed than in the open ear. The closure of an external auditory canal which contains only air intensifies the vibrations of sound in that cavity; in other words, there is conveyed to the brain of the person experimented upon, the impression

that the sound of the vibrating tuning-fork is louder in the closed than in the open ear. As Politzer has shown, this increase in the loudness of the sound heard in one ear is due not only to increased resonance of the air contained in the external auditory canal, but also in a measure to an increase in the volume of sound reflected back to the auditory nerve through the changed tension of the conducting mechanism (membrana tympani and ossicles). Such a change in tension takes place in all affections of the middle ear and in some of those of the external auditory canal. In an enormous majority of the cases of impaired hearing that come under our observation, these are precisely the regions which are mainly involved, and we therefore expect, with considerable confidence, to hear the patient say—when the vibrating-fork is applied to the vertex—that the sound of this fork is heard more loudly in the defective ear than in that which is believed to be either normal or at all events more capable of hearing than is its fellow. On the other hand, it is not always safe to draw the conclusion that the nervous structures of the deficient ear are at fault when the patient refers the preponderance of sound to the well-hearing ear. The latter, which he supposes to be normal in every respect, may nevertheless be plugged with inspissated cerumen or other obstructing material; in which case it will not be surprising that the phenomena of reflection and increased resonance in the ear which was supposed to be sound should completely nullify all phenomena that might throw light upon the condition of the fundamentally affected ear. An error of this kind, however, will be speedily rectified by an examination of both ears with the speculum and reflected light, and, if necessary, by a repetition of the tuning-fork test after the removal of the mass of cerumen.

To determine the degree of preponderance of sound in one ear, it is only necessary to place the handle of the vibrating-fork upon some part of the skull more remote than the vertex or the centre of the forehead from the affected ear. If the degree of preponderance is only slight, the sound will already begin to be referred to the good ear when the handle of the fork is placed on the forehead at a distance of say one inch from the median line, on the side toward the unaffected ear. If the degree of preponderance is marked, the handle of the vibrating-fork may be placed on the skull just above the normal ear, and yet the sound will be heard by the patient most strongly in the affected ear, on the opposite side of the skull.

Politzer recommends, for ordinary clinical purposes, the employ-

ment of three tuning-forks, having respectively three different rates of vibration, viz., one of 128 (C), another of 512 (C^2), and a third of 2,048 vibrations per second (C^4). But if it be desired to test more minutely the condition of the cochlear organs of hearing, it will be necessary to have at one's command a larger series of tuning-forks, at least eight or nine, together with a Galton's whistle or the series of König's steel rods, by means of which the very highest tones which the human ear can distinguish may be produced. Politzer states that, as a general thing, in affections of the middle ear, the high tones are more readily perceived than the low; and, conversely, that in affections of the nervous apparatus of the cochlea the deep tones are more easily distinguished than the high. At the same time he warns the physician that there are many exceptions to this rule, and that consequently the results of experimental tests with high- and low-pitched tuning-forks must be interpreted in connection with the facts which we may ascertain by our examination of the case in other ways.[1]

FIG. 4. — Galton's Whistle. (Reduced ½.)

The practical value of *Galton's whistle* and of *König's steel rods* of a very high pitch is comparatively small. They enable us to determine the fact that a patient's range of audition is more or less limited in the direction of the higher tones; but we are not warranted in drawing the further conclusion that this limitation is due to the existence of lesions involving the corresponding auditory nerve fibrils or the Corti's mechanisms belonging to these fibrils. In the present state of our knowledge we are compelled to admit that some alterations in the conducting apparatus of the middle ear may prevent the vibrations of these tones of a very high pitch from reaching the nervous mechanisms which are fitted to perceive them. These instruments, therefore, have not yet become a necessary part of the aural surgeon's armamentarium.

[1] Dr. Edmund D. Spear, of Boston, Mass., states in a recent article (*Archives of Otology*, vol. xxvi., No. 4, 1897) that he has succeeded in having constructed for him, out of an alloy of certain metals, a series of tuning-forks which possess very few overtones. Those which are now commonly employed are constructed of steel, and are very rich in overtones. Unfortunately, Dr. Spear does not state where these new forks are to be procured.

In the absence of a tuning-fork a watch held between the teeth may be used as a substitute. If the ticking is too feeble for the patient to hear it in this way, he may be asked to hold a silver spoon suspended from between his teeth. By tapping the spoon lightly with a knife or other object of metal, it may be made to vibrate for an instant or two, and if the patient is a quick observer he will be able to notice in which ear the sound preponderates. At best, however, these makeshifts are poor substitutes for a well-constructed tuning-fork.

In German otological literature a certain degree of value appears to be attached to *Rinne's experiment* as a means of distinguishing between affections of the auditory nerve and those of the conducting apparatus in the middle ear as causes of an impaired hearing power. Rinne, in 1855, made the observation that persons with normal hearing are able to hear the sound of a vibrating tuning-fork held in front of the auricle, after they have ceased to hear the same fork by direct bone conduction through the teeth and skull. The experiment is carried out in this wise: The tuning-fork is set in vibration, its handle is placed against the closed teeth or upon the skull of the patient or person experimented upon, and then, when the tone of the vibrating-fork ceases to be audible to him, it is quickly transferred to a position where the still feebly vibrating arms of the fork will be close to the orifice of the external auditory canal. Under normal conditions the subject of this experiment will again hear the tone of the vibrating-fork when it is thus transferred to this new position.[1] On the other hand, if he is unable to perceive the sound of the fork after it has been transferred from the head to the vicinity of the outer orifice of the meatus, the presumption will be that the conducting apparatus, and not the auditory nerve, is at fault. Post-mortem examinations have been made in three different instances (Bezold, Politzer, and Habermann), and in each instance anchylosis of the stapedio-vestibular joint was found—a confirmation of the correctness of the conclusions drawn from Rinne's test, which had been applied in each case during the patient's lifetime and in each had yielded a negative result. Lucae, from whose account in Eulenburg's Real-Encyclopædie I have derived my present information regarding Rinne's test, lays stress on the importance

[1] This result of Rinne's test is technically called "positive result with Rinne's experiment (+R)"; but when the patient fails to hear the fork through the air after it has ceased to be audible by bony conduction, the result is expressed as "negative result with Rinne's experiment (—R)."

of using tuning-forks of a low pitch, and preferably those provided with clamps, which prolong materially the duration of the vibrations. Gruber refers very briefly to the test, in the last edition of his treatise on diseases of the ear, and attaches comparatively little value to the results obtained by its employment. So far as I am able to judge, Rinne's experiment has added little or nothing to our power of distinguishing between the effects of intralabyrinthine or auditory nerve lesions and those due to alterations of parts situated in the middle ear.

EAR SPECULA AND REFLECTORS.

It is a matter of the first importance that the physician who contemplates studying diseases of the ear should be provided with good instruments. Badly devised or clumsily constructed instruments will make it impossible for him, in many cases, to arrive at a correct diagnosis, and, in other cases still, he will, by their use, cause the patient much unnecessary discomfort or even pain.

In a few individuals, the external auditory canal is so broad and straight that the physician can see its walls throughout their entire length, and even the drum membrane, by direct inspection, without the aid of instruments of any kind. In the majority of persons, however, a satisfactory view of these regions cannot be obtained except with the aid of two kinds of instruments, viz., one to push aside the soft walls of the orifice of the canal (ear specula), the other to illuminate the parts thus rendered accessible (mirrors of various kinds).

Of the different patterns of *ear specula* which are offered for sale in the surgical-instrument makers' shops, the cheapest and at the same time the best are those known by the name of Wilde's ear specula. These instruments have the shape of truncated hollow cones; they are of coin silver, and are polished within and without. For all ordinary demands, three different sizes will be found sufficient. They should not exceed three and a half centimetres ($1\frac{3}{8}$ inch) in length. The aperture at the smaller end of the instrument should measure not less than three and a half millimetres ($\frac{1}{8}$ inch) in diameter, for the smallest of the three sizes of specula, and not more than eight millimetres ($\frac{5}{16}$ inch) for the largest. The distance of the smaller end of the speculum from the membrana tympani is such that it is not possible to illuminate even a small section of the latter if the diameter of the smaller aperture is mate-

rially less than one-eighth of an inch; the illuminating rays, in this case, coming to a focus at some point outside of the membrana tympani. As a matter of fact, it is no easy matter to obtain a view of even a small portion of the drum membrane through a well-polished silver speculum of the smallest of the three sizes named. Finally, the walls of the instrument should be no thicker than is sufficient to prevent them from bending under ordinary manipulations. Thick-walled specula rob us of valuable space and diminish to a proportionate extent the degree of illumination.

Fig. 5. Wilde's Ear Speculum. (Natural size.)

Two kinds of contrivances are generally used for the purpose of reflecting light into the external auditory canal, viz., the *hand-mirror* and the *forehead-mirror*. So far as the mirror itself is concerned, these two are one and the same thing. In practice it has been found that the best illumination is obtained with a concave mirror of circular form, whose focal distance should vary from twelve to thirty centimetres (5 to 12 inches), according to the visual power of the observer. The majority of men will find a focal distance of about twenty centimetres (between 7 and 8 inches) the best adapted to their purposes. With regard to the size of the mirror, it may be said that one having a diameter of seven centimetres ($2\frac{3}{4}$ inches) is as large as the observer can conveniently handle. Almost all the mirrors offered for sale have a central aperture or unsilvered spot, through which the observer can see the parts illuminated directly in the focal line. If the hand-mirror be used, it is probably better to place the eye in the focal line than to look over the edge of the mirror. At the present day, however, all students of otology who are not near-sighted should be taught to use only the forehead-mirror. While at first it may be found more difficult to manipulate than the hand-mirror, its advantages over the latter are so great as to more than compensate for the difficulties encountered in learning how to use it properly. These difficulties once overcome, the physician no longer requires an assistant, but has both hands free for the various manipulations which are required in even the simplest case. The forehead-mirrors usually sold in the shops, and commonly pictured in the text-books, are very poorly adapted to the wants of an aural surgeon; some of them are, in fact, absolutely useless for his purposes. If we examine these instruments

carefully, we shall find that they are fundamentally wrong in two respects: first, no space, or insufficient space, is left between the forehead-plate and the upper edge of the mirror, thus rendering it either difficult or impossible for the observer to see the ear in the manner shown in Fig. 7; second, the ball-and-socket joint, by which the mirror is attached to the forehead-plate, allows the former to be rotated to such a limited extent, both from side to side and from before backward, that the observer will often find himself unable to use the source of light that may happen to be available, unless he changes its position or that of the patient, or both. If the forehead-mirror, however, be properly constructed, the observer will find comparatively little difficulty in placing himself in such a position that he can utilize almost any source of light that he may find at hand. The accompanying cut (Fig. 6) gives a correct representation of a forehead-mirror well adapted to the wants of the aural surgeon. The details of construction are as follows: The forehead-plate is made of hard rubber or (preferably) of metal, nickel-plated, $9\frac{1}{2}$ centimetres ($3\frac{3}{4}$ inches) long, $2\frac{1}{2}$ centimetres (1 inch) broad at the broadest part, a trifle more than a millimetre (or about $\frac{1}{20}$ inch) in thickness, and curved flatwise, so as to lie at all points in firm contact with the forehead. This concave side should not be padded, partly for reasons of cleanliness, and chiefly because such padding materially diminishes the stability of the mirror when once adjusted to the observer's forehead. At both ends of the plate there is a long and narrow opening, through which the forehead-band or strap is to be inserted. A word or two with regard to the latter. The dealers are in the habit of furnishing forehead-bands of elastic material covered with black cotton or silk. In summer-time, or in a warm room, the dye is set free by the perspiration, and the physician finds a black stain on his temples wherever the band has touched the skin. To obviate this annoyance the forehead-band

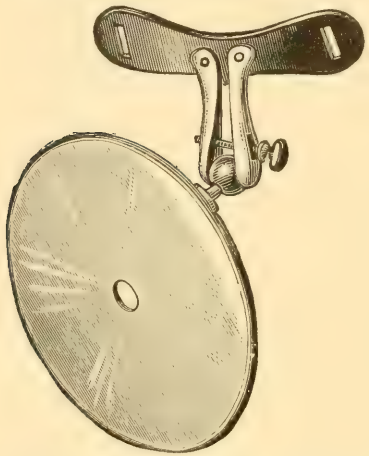

FIG. 6.—Forehead-mirror. (Half the natural size.) (For cut of mirror in actual use, see page 16.)

should be made partly of undyed leather and partly of elastic (or non-elastic) material. The leather portions should begin at either end of the forehead-plate and should extend to a distance of twelve or thirteen centimetres (about 5 inches) from these. Beyond these limits an elastic or non-elastic band of any material or color may be used. The adjustment of the band to the size of the head is effected by means of a buckle.

As to the mirror itself, I have already described it sufficiently. Its mode of attachment to the forehead-plate is, however, a matter of great importance. All the contrivances used for this purpose are based upon the principle of the ball-and-socket joint. The majority of them, however, as I have already stated, allow so little freedom of motion that the physician often finds himself unable to use the source of light at his command. In the first place, the ball should be attached, through the medium of a strong stem (of solid brass), to the metal back of the mirror (see Fig. 6). This stem should be fastened to the mirror at a distance not exceeding seven millimetres (or about $\frac{1}{4}$ inch) from its circumference. The point at which the stem broadens out into the ball should also be seven millimetres distant from the back of the mirror, and the ball itself should measure about one centimetre ($\frac{3}{8}$ inch) in diameter. The socket in which the ball revolves consists of two segmental sockets hollowed out of the ends of two brass shanks, which are attached, each by a single rivet, to the convex side of the forehead-plate. The length of each shank is five centimetres (2 inches). By means of an adjustable screw, which passes through a slot in one shank, the mobility of the joint may be increased or diminished at will.

If we examine such a mirror as I have endeavored to describe, we shall find, in the first place, that it may be rotated unusually far forward, thus enabling the observer to use a source of light situated comparatively high above the patient's head. In the second place, the mirror may be rotated so far toward one side or the other that the observer can use a source of light situated close to the extremes of either side. In the third place, we are not so strongly tempted to close one eye, when using the forehead-mirror in the manner shown in Fig. 7, as we are when looking through the central aperture of the hand-mirror. Only one eye does the real work of examination in both cases, but in using the forehead-mirror we are not conscious, in the slightest degree, that we are not observing the object with both eyes in the ordinary manner. In dispensary practice as well as in private office work it will be found more restful to

the eyes—that is, less of a strain upon them—if we adopt the practice of habitually keeping both eyes open. Finally, if it be found desirable to inspect the illuminated parts in the focal line—or, in other words, to secure the maximum degree of illumination—the mirror can readily be rotated in such a manner as to bring the central aperture in front of either eye. Unless a mirror can fulfil all these requirements it may safely be assumed that the instrument is not as perfect as it is possible to make it.

I have gone thus minutely into the details of construction and advantages of the forehead-mirror because I have observed that the

Fig. 7.—Forehead-mirror in Actual Use.

use of the hand-mirror in aural examinations is still very common, not only in this country, but also on the continent of Europe. As no one who has once experienced the comfort of working with a good forehead-mirror would ever think of returning to the habitual use of the hand-mirror, I can only explain the widespread use of the latter instrument by assuming that no really good forehead-mirror has been brought to the notice of the profession. The one which I have described is essentially the same as that which was first shown to me in 1870 by Dr. Robert F. Weir, of this city, and which he had been using, if I remember rightly, for several months previously.

The forehead-mirror is to be worn in the manner represented in the accompanying cut, *i.e.*, with the ball-and-socket joint resting upon the bridge of the nose, and the mirror itself projecting at a

still lower level. As our ordinary sources of light are almost invariably situated at a level higher than that of the examiner's eyes, the plan adopted by some, of resting the mirror against the forehead, will be found rather awkward in aural examinations.

If for any reason it is thought desirable to magnify the object under examination, a lens of suitable focal distance may be held between the eye of the observer and the speculum. A person with good eyesight, however, will gain but little, if any, additional information by the use of lenses in the examination of the ear.

INTRODUCTION OF THE SPECULUM AND USE OF THE REFLECTOR.

If the physician wishes to introduce a speculum into the ear in such a manner as to gain a satisfactory view of the membrana tympani and deeper parts of the external auditory canal, without causing his patient either harm or unnecessary discomfort, he must first become acquainted with at least the more important points in the anatomy of these parts. I will therefore enumerate here, very briefly, those peculiarities in the anatomy of the external auditory canal which seem to me to have an important practical bearing upon the procedure which I have undertaken to describe.

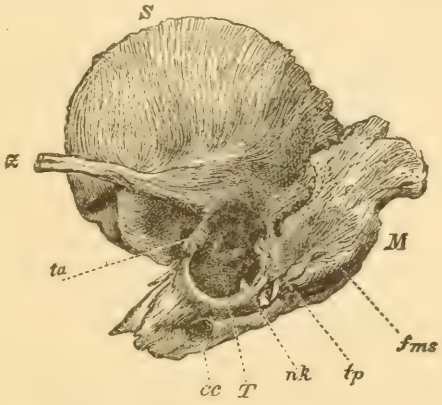

FIG. 8.—Temporal Bone of a New-born Child. (After Gruber.) *S*, Squamous portion; *M*, mastoid portion; *Z*, zygomatic process; *T*, tympanic cavity; *fms*, fissura mastoideo-squamosa; *cc*, foramen caroticum; *ta*, *nk*, *tp*, points where the annulus tympanicus is beginning to develop spurs of bone.

Anatomical Considerations.—In infancy, the external auditory canal is almost entirely composed of soft tissues, and the drum-membrane lies but little below the level of the surrounding surface of the skull (Fig. 8). In older children and in adult life the inner half of the canal consists of a cylinder of bone, the inner end of which is spanned by the drum-membrane. There are still other anatomical differences between the infantile canal

and that of adult life, which bear directly upon this question of examinations of the ear. In infants the drum-membrane faces chiefly downward, while in adults it faces chiefly outward. Again, in infants the soft walls of the meatus tend to collapse and lie in contact with each other, the general direction of the canal from the drum-membrane being outward and upward. It should also be kept clearly in mind that in the infant at birth the little ring of bone (annulus tympanicus, Fig. 9) in which the drum-membrane is set, and to which the membranous meatus is firmly fastened, is itself still very feebly attached to the squamous portion of the temporal bone. Finally, in adults, the cartilaginous portion of the meatus tends to droop downward and forward (Fig. 10). As the framework of this portion of the canal is not composed of a solid plate of cartilage, but is provided with several fissures (Santorinian fissures, see Fig. 11) spanned by elastic tissues, it will be found to possess a very considerable degree of mobility. In old age, however, these fibrous portions, which play, in a measure, the part of hinges, become stiff and hard from the abundant deposit of chalk-like material, and the natural mobility of the canal is thereby seriously diminished. These, I believe, are the only important points that have a direct practical bearing upon the subject of the introduction of the aural speculum.

FIG. 9.—Annulus Tympanicus, at Birth.

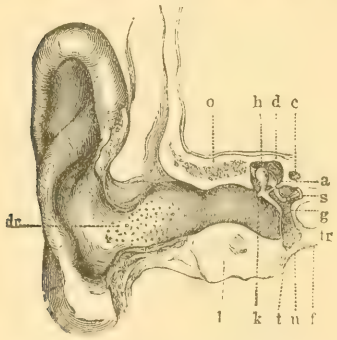

FIG. 10.—Vertical Section through the Right External Auditory Canal, Drum-membrane, and Middle Ear. *o*, Cellular spaces in the upper bony wall of the canal (these cells communicating with the cavity of the tympanum); *d*, roof or tegmen of the tympanum; *t*, tympanum; *u*, lower wall of the same; *tr*, membrana tympani or drum-head; *h*, head of hammer; *a*, anvil; *s*, stirrup; *c*, canal of Fallopius; *f*, fossa jugularis; *dr*, mouths of glands at orifice of the external auditory canal. (After Politzer.)

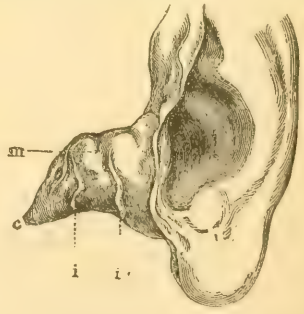

FIG. 11.—Auricle and Cartilaginous Portion of the External Auditory Canal. *m*, Cartilaginous meatus; *c*, inner pointed end of the same; *ii*, fissures of Santorini (incisuræ Santorinianæ)—Left ear. (After Politzer.)

Sources of Light.—In the examination of the ear with either the hand- or the forehead-mirror, it is not necessary to procure any other source of light than those which can almost always be found in every house. Direct sunlight is so dazzling that we cannot use it with either comfort or advantage. Ordinary daylight, such as can be obtained by directing our mirror toward the sky above the horizon, or toward the white wall of a house near by, generally affords sufficient illumination for ordinary purposes. If the window of the room looks out upon a narrow street, it will be found better to trust to artificial light. In our larger cities the incandescent electric light (16- or 20-candle power), or the brilliant Welsbach light, or even the ordinary argand gas-burner, will be found to furnish all that can be desired in the way of a source of light. In office practice some kind of movable fixture should be used, in order that the light can readily be placed at different levels, according to the height of the patient. The ordinary gas-flame, the light of a kerosene lamp, or even that of a candle, will afford all the illumination required in the great majority of cases. The interposition of lenses, for the purpose of increasing the brilliancy of the illumination, is superfluous. On the other hand, an interposed lens may in certain cases, especially where the physician has some defect of vision, bring out clearly certain details in the picture of the drum-membrane which, without the aid of this magnifying power, might readily escape his attention.

Position of the Patient in Relation to the Light.—The physician should try to acquire the power to use sources of light situated in all imaginable positions. As a matter of course, the light must occupy such a position that when the observer's face is directed toward the ear that is to be examined, he can see the flame or other source of illumination by simply turning his *eyes* in the proper direction. If he is obliged to turn his *head*, however, in order to see the light, it is certain that he will not be able, by means of his mirror, to reflect any of it into the patient's ear. In the next place, the source of light (if an artificial one) should not be at too great a distance from the observer, as in that case the illumination of the auditory canal would be rather feeble. The best position for the light is at a point a short distance behind and on one or the other side of the patient, not more than three feet from him, and about six inches above the level of the ear to be examined. If the light occupies a position on the observer's right-hand side, and is at the usual height above the patient's ear, there is a strong probability that in his

manipulations with the right hand he will intercept the rays of light, and so shut off a view of the object under examination. If it happens, however, to be more convenient for him to use a source of light which is situated on his right side, he can readily avoid the difficulty just alluded to by raising the light to a higher level, thus enabling the rays to reach the mirror over his right arm. Probably the best plan for the beginner is to draw his illumination from a source which is situated on his left side. After he has acquired practice in using the forehead-mirror, it will make very little difference to him what position the light occupies, provided it be not on a lower level than the object under examination, and provided, of course, that it can be readily seen by the observer when his face is turned toward the ear of the patient.

The Actual Examination.—After the physician has acquired a certain degree of skill in the management of both speculum and mirror, he will find very little difficulty in adapting himself to the different circumstances under which he may find it necessary to make an examination of the ear. To lay down rules for all these varying conditions would simply be a waste of time. It will be sufficient if I describe the proper mode of procedure to be followed when the patient can be placed in the position which best suits the comfort of the physician who makes the examination. Thus, for example, if the left ear be the one that we wish to examine, and if the patient be an adult, he should be made to sit in such a position that he will have the light in front of him, a little toward his right side, and a few inches above the level of his eyes. The physician, of course, sits directly facing the patient's left ear. The latter should be as nearly as possible on the same level with the observer's eyes. Where this is not the case, the patient's head must be bent toward one or the other side, until the long axis of his external auditory canal corresponds with the observer's axis of vision. The next step is to cause the reflected rays of light to fall directly upon the ear. In this connection there are one or two practical points to which attention should be called. In the first place, it is not necessary, with a mirror whose focal distance is about twenty centimetres, to observe whether the rays have been brought to a focus in the auditory canal, or several centimetres this side of it in the axial line of the canal. In other words, the illumination along the axial line, for a distance of several centimetres on either side of the focal point, is amply sufficient for all practical purposes. Hence, the observer, in examining an ear by the aid of a forehead-mirror, should hold his

head in that position in which he can most comfortably see the parts to be examined. In the second place, in his efforts to cause the rays of light to fall upon the ear, he should not use the mobility of his neck as a means of attaining this object. It is far better to fix his head in the proper position for observing the parts comfortably, and then rotate the mirror in its ball-and-socket joint until he finds the position in which it reflects the light in the direction desired. This done, the observer is ready to introduce the speculum and proceed with the examination.

Until we have learned by actual experience how large a speculum the ear under examination will admit, it is best to begin arbitrarily with one of medium size. The ear to be examined, we will suppose, is the left one and belongs to an adult. Holding the instrument between the thumb and forefinger of the left hand, and lifting the auricle upward and backward with the right hand, we should introduce the speculum cautiously into the orifice of the canal. As we push the instrument farther and farther inward, by a sort of boring motion, we should keep the eye directed upon the parts illuminated at the bottom of the speculum. By thus watching the progress of the inner end of the instrument, we shall be able to introduce it as far as we desire without causing the patient pain or even discomfort. In lifting the auricle upward and backward, while introducing the speculum, it makes no difference which hand is employed for the purpose, though it is, of course, easier to employ the right hand for the patient's left ear, and the left for his right. After the speculum is in position, however, and we desire to use the right hand for operative or other purposes, the traction upon the auricle and the maintenance of the speculum in a steady position must be given over to the left hand. To accomplish this easily, the fore and middle fingers should be used for the purposes of traction, while the thumb is left free to steady the speculum.

In the preceding paragraph the statement is made that, in the case of an adult, the auricle should be drawn upward and backward before the speculum is introduced into the external auditory canal. This advice is undoubtedly correct for a large majority of cases, but there are not a few instances in which the maximum help is obtained by drawing the auricle as a whole outward and a little backward. In young infants, on the other hand, it is generally necessary to draw the lower wall of the canal outward and a little downward, while the parts constituting the upper portion of the canal are put

upon the stretch outward and at the same time somewhat upward and backward.

With regard to the question of how far the speculum should be introduced into the meatus, it may be said that as soon as the instrument has reached a position in which a clear view of the membrana tympani and deeper portions of the canal can be obtained, nothing will be gained by pushing it farther inward. With Toynbee's and Von Troeltsch's specula it is an easy matter for a person who is rough or careless in his manipulations to injure the deeper parts of the canal. With Wilde's conical specula and the broad-mouthed instruments of Gruber, however, the danger is greatly lessened.

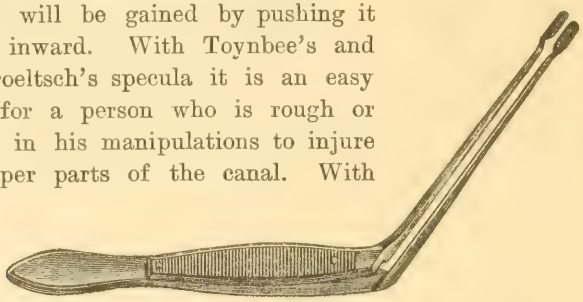

Fig. 12.—Politzer's Angular Forceps. (Reduced ⅓.)

Accessory Instruments Used in the Examination of the Ear.—In a large proportion of the cases that come before us we find that the speculum and mirror are the only instruments required for obtaining a full and satisfactory view of the external auditory canal and drum-membrane. In a certain number of cases, however, we find the view obstructed by the presence of various substances, such as cerumen, hairs, scales of epidermis, pus, etc. These must, of course, be removed, if we desire to see clearly the parts beyond, and for this purpose one or more of the following instruments may be employed: angular forceps, cotton-carriers, probes and curettes, and the syringe. I mention the syringe last, because I believe it to be the clumsiest and in some cases the

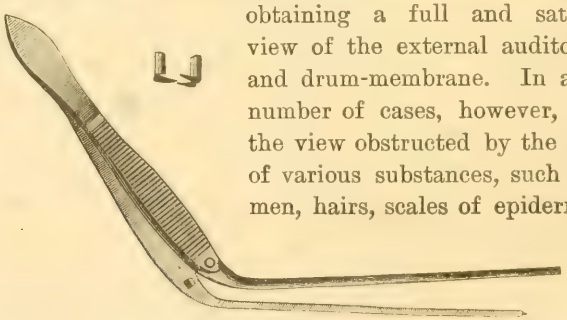

Fig. 13.—Slender Forceps. (⅔ actual size.) *a*, Toothed ends of forceps (somewhat exaggerated).

least efficient of the means enumerated. Further on, I shall have occasion to discuss the merits of this instrument more fully.

A well-constructed pair of *angular forceps* is an invaluable instrument to the aural surgeon. He should be provided with two patterns of the instrument—a rather stout pair (Fig. 12), which he can use in removing large bodies that are near the outer orifice, and a slender pair (Fig. 13), that can be employed in the deeper parts of the canal.

The long arms or blades of the more slender instrument should measure about six and a half or seven centimetres in length. If they are less than six centimetres in length, some difficulty may be experienced in illuminating the object which it is proposed to remove, during the actual operation. The shorter arms should measure about six centimetres (2⅜ inches) in length, and the spring which they form by their union should be quite feeble. A stiff spring is very apt to make the operator's hand tremble when he is using the forceps. At its extreme free end the blade should measure a trifle less than a millimetre in breadth, and hardly three-fourths of a millimetre in thickness. From this point it should gradually increase in both dimensions, until near the angle it measures 2½ mm. in breadth and 1½ mm. in thickness. The tips of the blades should be provided with short teeth, two on one side and one on the other. The teeth shown in the accompanying cut are relatively much too long. They should project to only a slight degree, just sufficiently to furnish grasping power. Indeed, some prefer that the ends of the blades should be merely roughened somewhat along the surfaces which come in contact with each other. When the blades are closed, and the instrument is looked at from one or the other side, no elevation should be visible at the angle. The presence of such a hump may seriously diminish either the degree of illumination or the extent of the field of vision. In the next place, it is important that, when the free extremities of the blades are brought close together, the stouter portions at the angle should not be too far apart. In a good instrument, if no greater force is exerted than is sufficient to make the toothed ends interlock, the distance between the blades at the angle should not exceed a millimetre or a millimetre and a half (or the total diameter of both blades with the intervening space, should not exceed five millimetres). Finally, in examining a number of these slender forceps, apparently all alike in other respects, I have observed that, when more force is used than is sufficient to bring the blades in contact

with each other throughout their entire length, the interlocking toothed ends separate, in some instances quite widely. While this is an extremely annoying fault in a pair of forceps, it is also one that can be readily discovered at the time of purchasing the instrument.

Fig. 14.—The Harrison Allen Cotton-carrier.

Of the stouter forceps, I like best the pattern which is sold in the shops under the name of Politzer's forceps (Fig. 12). As this instrument is not intended for delicate work, it is not necessary that I should devote any space to the consideration of the details of its construction. As usually found in the shops, it is a sufficiently good instrument for all the purposes to which the physician is likely to apply it. If he desire to purchase only one pair of forceps, it is on the whole better for him to have in his possession the slender pattern.

The *Cotton-carrier* is an exceedingly useful instrument to the aural surgeon. It consists of a slender rod of malleable steel, about twelve centimetres in length, which is slightly roughened at one end, for the reception of the cotton, and at the other broadens out into a short and rather thick handle. For ordinary purposes, a cotton-carrier with a shank of 1 mm. in diameter is the best size. For the more delicate manipulations which are sometimes required in the middle ear (with a perforated drum-membrane), an instrument with a shank of not more than half a millimetre in diameter will be found more appropriate. The Harrison Allen cotton-carrier, when constructed of a more slender pattern than that shown in the cut (Fig. 14), will be found thoroughly satisfactory. It is a common fault of the cotton-carriers sold in this city that the ends are too much roughened, thus rendering the removal of the mass of cotton at times an exceedingly difficult matter. With the nail-blade of a pocket-knife, however, it is easy to remedy this defect in a very few moments. It is a much more difficult matter to apply the cotton to the holder quickly, neatly, and firmly. To describe the procedure intelligibly is a task which I can hardly hope to accomplish satisfactorily, and I therefore prefer to let my readers work out each one a method for himself. The most important point, as a matter of course, is to cover up the comparatively sharp end of the

instrument so thoroughly with the cotton that it can do no harm. With regard to the uses to which the instrument, thus armed, can be put, I may say in general that it affords the quickest and best means known to me of removing from the exposed cavities of the ear fluid or semi-solid substances. The cotton-carrier is also employed for other equally important purposes; but of these we shall make mention in subsequent chapters.

Probes and Curettes are important accessory instruments. In very many cases, simple inspection of the parts leads us to wholly erroneous conclusions with regard to the true state of things. Thus, for example, simple inspection would perhaps justify us in making the diagnosis of a swollen and ulcerated condition of the posterior half of the membrana tympani; while inspection, combined with the proper use of the probe or curette, might reveal the existence of a polypoid mass that originated in the tympanic cavity, forced itself

Fig. 15.—Slender Silver Ear-probe. (⅜ actual length.)

through a comparatively small perforation, and then spread itself out over the posterior half of the drum-membrane. I might enumerate many other pathological conditions which even the most skilful specialist would be very likely to interpret incorrectly if he did not use the probe as a means of correcting or confirming his first impressions. Of course, if obstacles intercept the view, these must first be removed; and here the probe or the curette may also serve an excellent purpose. Both of these instruments, however, must be delicately constructed, or the physician will find them of very little use, either as aids in making a correct diagnosis, or as substitutes for the forceps and syringe. The most essential details of construction of these instruments are the following:

The probe (Fig. 15) should be made of a single rod of soft silver, and for a distance of 8 ctm. from one end it should be finished with four sides (each 1.5 mm. in diameter) in order to furnish a good hold for the fingers. This handle portion of the probe should merge gradually into a slender shank, less than half a millimetre in diameter, and terminating in a small knob, about three-fourths of a millimetre in diameter. A total length of 15 ctm. will be found amply sufficient.

The curettes should be made of steel, and their handles should

be of the same length as that of the probe, but they should be eight- instead of four-sided, and correspondingly heavier (diameter of nearly four millimetres). The shank, at the point where it broadens out abruptly into the handle, measures 1.5 mm. in diameter; at the point where it joins the ring, it measures but 0.5 mm. in diameter. The handles and shanks of the two different sizes of curettes are precisely alike; the only difference is in the size of the rings. Both are oval in shape, the smaller one measuring 3x2 mm., the larger one 5x4 mm. (external measurement). Their thickness, from one flat side to the other, is about 0.3 mm.; measured transversely, from the outer to the inner side of the ring, it is about 0.6 mm. in the larger curette, and about 0.3 mm. in the smaller one.[1] The outer edges should be nicely rounded, and not left sharp.

Although I have never written or said anything about using these instruments for scraping purposes, I was recently very much surprised to find that some of those offered for sale in the shops

Fig. 16.—Steel Curette with Rounded Edges. (⅔ actual length.)

(under the name of "Buck's curettes") were so constructed that they could only be used as scrapers; that is, the flattened sides of the ring were directed downward, *i.e.*, in a direction at right angles to the long axis of the shank, and the edges were left sharp; while in the curettes which I have always used and recommended, the flat part of the ring and the shank are in one and the same plane, and the edges are well rounded. For all purposes of lifting, loosening, and separating any and all sorts of abnormal products or growths in the auditory canal, the latter type of instrument is admirably adapted, while the other is perfectly useless. On the other hand, I very much doubt whether the slenderness of the shank would permit these sharp-edged curettes to do effective work in the only direction in which they seem fitted to be of any use—that is, in scraping away carious bone. Under certain circumstances, it will be found desirable to bend the shank slightly near its attachment to the ring. The steel in this part of the shank, therefore, should be left untempered.

The Syringe.—With regard to the use of the syringe, it is not

[1] A large proportion of the curettes sold in the shops are almost unfit for use, by reason of the undue thickness of the ring-shaped end. I have repeatedly called the attention of the instrument-makers to this serious defect, but they apparently pay no heed to what I say on this subject.

an easy matter to lay down any well-defined rules. It is a very common practice to use this instrument with warm water for the removal of any and all sorts of obstacles in the external auditory canal, whether they be large or small, hard or soft. A distinguished writer on surgery once gave the advice that no instrument smaller than the elbow should ever be introduced into the ear, and the general acceptance of this doctrine as unimpeachably sound probably furnishes the correct explanation of the fact that syringing is looked upon as the only safe method of clearing away obstacles from the auditory canal. All manipulations about this organ, it should be remembered, call for delicacy of touch, steadiness of hand, and the ability so to manage the illumination that the surgeon shall see distinctly everything that he does in the external auditory canal. Hence it is perfectly legitimate for one who undertakes to instruct in the art of curing ears, to assume that his readers are not so reckless or so clumsy as deliberately to injure their patients. If, however, they are men of this stamp, the advice of the distinguished surgeon is undoubtedly eminently appropriate for them; but to those who wish to learn the surest and most effective means of bringing the membrana tympani into full view, and are willing to take the trouble to acquire the manual skill and delicacy of touch requisite for the effective and painless employment of the instruments described above, I would give the advice to use the syringe only when circumstances compel them to use it. If the latter instrument could always or even generally be trusted to effect the desired object, I should feel as if I were not quite justified by the facts in laying so much emphasis upon the employment of these instruments; but the truth is, that in a very large number of cases it is utterly impossible to obtain a satisfactory view of the membrana tympani and deeper parts of the ear unless we resort to instrumental interference such as I have described. In fact, there are not a few cases, as we shall learn further on, in which the most experienced observer will find that the appearances presented to his eye are not what they seem to be, and that the true anatomical relations can only be learned by touching and moving the different parts upon which his eyes are fixed.

Here are a few hints that may serve in lieu of rules:

1. Soft cerumen or abundant foul pus should preferably be removed by syringing.

2. Hard cerumen or laminated masses of desquamated epidermis should be loosened from the surrounding walls of the canal by means

of the curette. Oftentimes, especially in canals of large size, the mass may then be extracted entire by means of the angular forceps (preferably Politzer's). If the canal is not of large size, the curette may be used to loosen and break off sections of the mass, which may thus be removed piecemeal, either by means of the slender angular forceps, or by using the curette somewhat as one would use a hoe.

3. When the outer portions of such a mass have been removed, and it is found that the inner part remains wedged in between the drum-membrane and the anterior and upper wall of the canal, the curette should be used to open a small passage between the mass and the upper wall of the canal, as far inward as to the drum-membrane if practicable. Then, by directing the stream of water from the syringe toward this artificial channel, one may often succeed in exerting a *vis à tergo* sufficient to dislodge the impacted mass. But in the conditions here described my own preference is to do the entire work of removal, from beginning to end, with the curette and forceps.

Fig. 17.—Hard-rubber Ear-syringe.

4. Small objects, like hairs, scab-like formations, etc., can always be readily got out of the way by aid of the curette or the slender forceps, or by wiping them away with a little cotton wound around the end of a cotton-carrier.

A good *ear-syringe* should have a piston that works easily. This is the first and most important requirement. In the next place, it should be provided with some contrivance which will enable the operator to alternately fill and discharge the instrument with one hand. This object is commonly attained by having the handle of the piston terminate in a ring large enough to admit the thumb, while two other rings large enough to admit the fore and middle fingers are fastened opposite to each other on the base of the cylinder. In the hard-rubber ear-syringes the neck of the cylinder is hollowed out in such a manner as to afford to the fore and middle fingers all the support that they receive from the rings in the metal instruments. With regard to the size of cylinder best adapted to the requirements of a good ear syringe, I may say that, in general, it is better to employ an instrument of rather large capacity. Nevertheless, the one-ounce hard-rubber ear-syringes usually sold in the shops (Fig. 17) fairly answer all the reasonable requirements of a good syringe. Olive-pointed nozzles are not to be com-

mended; those which are shaped like that in the accompanying cut are decidedly preferable. The terminal tip or spout should not exceed four millimetres (a little over one-eighth of an inch) in diameter.

The water employed in syringing the ear should have a temperature of about 100° F. As the present chapter treats only of the different means which may be employed for arriving at a diagnosis, I will simply say here that for the purpose under discussion ordinary non-sterilized hot water is sufficiently safe. In the case of adults we must be prepared to hear the patient complain of feeling dizzy or faint. This is by no means an uncommon experience. In some cases we can attribute this symptom to the temperature of the water used—either too hot or too cold—or to the employment of too great force in driving in the piston. In others, however, the symptom will develop despite every precaution which the physician may take. One or two unpleasant experiences of this nature have led me to adopt the rule of asking the patient from time to time, during the progress of the operation, whether he experiences either dizziness or faintness. In this way we may obtain timely warning of the necessity of discontinuing the operation or at least intermitting it for a short time.

A few words may be added in regard to the different steps of the procedure. The patient's neck and shoulder should first be protected with a towel, and he should be given a glass finger-bowl or a mug to hold beneath his ear. The shallow hard-rubber or metal basins sold by the instrument-makers for this latter purpose are thoroughly unpractical. A sudden motion of the patient's body is apt to cause the contents of the basin to spill over upon his person, while if a mug, bowl, or other deep vessel be used, the same accident is much less likely to occur. In the majority of cases the bowl or mug may be used both as a reservoir from which to fill the syringe and as a receptacle for catching the water that runs out from the ear. If the proper conveniences, however, are at hand, it is better to fill the syringe from a separate vessel, as sometimes the matters which are washed out from the ear block the canal of the nozzle, and so cause trouble. After we have filled the syringe with the right hand, we must straighten the patient's external auditory canal with the fingers of the left hand, in the manner described when speaking of the introduction of the speculum. This done, the nozzle is to be introduced a short distance—roughly estimated, not more than half an inch—into the meatus, and the water thrown

in with little or great force, according to the nature of the conditions which led to the use of the instrument. If we are not pointing the syringe in the right direction, or if we have pushed the nozzle too far into the ear, the patient will be very likely to reveal the fact by the expression of his countenance. No description, however, can serve as an adequate guide to the successful carrying out of this procedure, which physicians are apt to consider a very easy task, but which is often quite the reverse. In infants the hard-rubber or the metal syringe must be used with great caution. The fountain

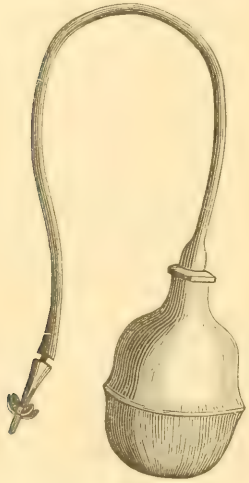

FIG. 18.—Angelo's Ear-douche. (⅓ actual size.)

FIG. 19.—Nozzle of Angelo's Ear-douche. (Slightly enlarged.)

douche or some form of bulb syringe is a much safer instrument to use, provided it be furnished with a suitable nozzle, one that cannot be introduced too far into the external meatus. The nozzles usually supplied with the douche are either so large that it is impossible to do effective work with them, or so slender and sharp-pointed that they may easily injure the canal or even the drum-membrane itself. In some of the shops it is now possible to purchase a pattern of ear-syringe which is sold under the name of "*Angelo's Ear-douche*," and which is free from these objections. (See Figs. 18 and 19.) It consists of four parts, all easily removable, viz.: a white rubber bulb or reservoir, a hard-rubber stem to fit into the neck of the bulb, a piece of soft-rubber tubing about eight or ten inches long,

and a terminal pronged ear-nozzle. The latter is made of hard rubber, and is provided with four prongs which are symmetrically placed around the nozzle, each at a distance of about half an inch from the free end. The diameter of the nozzle at the tip is three and one-half millimetres; at the bases of the prongs it is about four millimetres. The prongs themselves project about six millimetres from the sides of the nozzle, and they are inclined a little backward, away from the tip. This instrument, however, is chiefly valuable for therapeutic purposes, and I will therefore reserve what I have to say about its other merits for a later chapter.

The art of properly cleaning the ear is the art which I would urge the beginner in otology to cultivate. I am strongly tempted to add that when he has mastered this very difficult art, he will find himself a master both in the diagnosis and in the treatment of diseases of the ear. This is not far from the truth. As an instructor I have repeatedly made the observation that, after the ear had been properly cleansed, even a beginner would often be able to make a correct diagnosis of rather complicated conditions. But very rarely indeed have I known a pupil to be able to clean an ear even fairly well, until he had served a somewhat long apprenticeship. This cleansing process must be done by means of the cotton-carrier, the curette, the slender middle-ear probe, and the delicate angular forceps. If the external auditory canal is filled with a very foul pus, it may be pleasanter for the physician to remove as much of it as he can by syringing. If the discharge, however, is not particularly offensive, and if there is no decided accumulation of cheesy material and epithelium, time will be saved by employing, from the very beginning, the cotton-carrier armed with absorbent cotton. By varying the amount of cotton used, the physician can make a mop suitable either for the removal of large quantities of pus in the broad external auditory canal, or for the thorough cleansing of a small sinus leading through Shrapnell's membrane into the recesses of the middle ear. If syringing alone is employed, the picture afterward presented to the eye of the observer will almost invariably be a deceptive one. All the depressions and interstices will continue to hold a certain amount of water, and under these circumstances the most experienced observer can scarcely fail to interpret incorrectly what he sees. But oftentimes even the cotton-carrier fails to accomplish all that is desired. Masses of cheesy pus or of epithelium remain embedded in the recesses or cling firmly to the tissues, and

we are obliged to use the curette, the slender probe, or the forceps. In all these recommendations I assume that I am dealing with physicians who possess a fair degree of steadiness of hand and delicacy of touch. I assume, furthermore, that they have mastered the art of illuminating the deeper parts of the ear with a forehead-mirror.

CHAPTER II.

GENERAL PATHOLOGY.

Before discussing the different ways in which disease may affect the organ of hearing, I think it will be well to rehearse here briefly the anatomical relations of its different parts and the more prominent features of each.

The organ of hearing is made up of a variety of tissues, disposed for the greater part in cavities which are either out of sight or are difficult to see and explore. In a rough way we may describe these

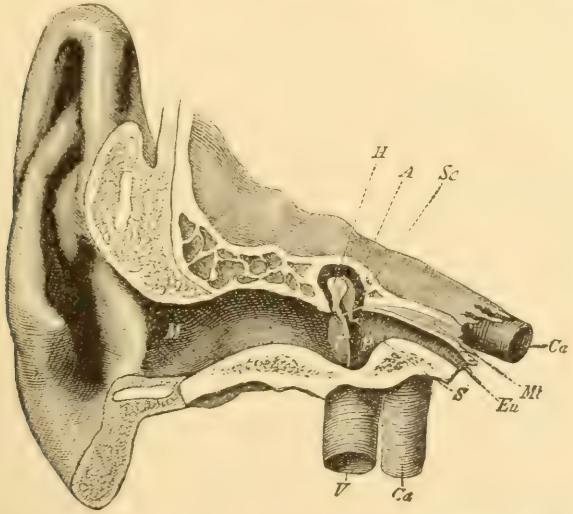

Fig. 20.—Anatomical Relations of External Auditory Canal, Middle Ear, etc. *M*, External auditory canal: *H*, hammer; *A*, anvil; *Se*, tendon of the tensor tympani muscle; *Mt*, tensor tympani muscle; *Eu*, Eustachian tube: *S*, stirrup; *P*, promontory, or inner wall of tympanum; *T*, membrana tympani; *Cd*, carotid artery; *V*, jugular vein. (After Hartmann.)

cavities as surrounded on all sides by dense bone, sometimes very thick, and in only a few places noticeably thin. For reasons of convenience it is customary to speak of the three anatomically different cavities as *the internal, the middle,* and *the outer ear.* The lat-

ter (the external auditory canal without the auricle) is simply an elongated cul-de-sac lined with skin and open at its outer end.

The *middle ear* is a very complicated system of cavities, absolutely shut out from the outside world except through a long, narrow, and, for a large part of the time, closed channel which opens into the vault of the pharynx. These cavities are lined with a thin mucous membrane, which also plays the part of a periosteum or nourishing membrane for the underlying bone. In the chief one of these communicating cavities, viz., the tympanum proper, is placed an isolated arch of three ossicula. This arch springs from the central and upper part of the tympanic membrane, and is inserted into the larger of the two openings that lead into the labyrinth, viz., the oval window. This arch is the connecting link between the sounds of the outside world and the nervous apparatus whose function it is to analyze them and convey them to the brain in the form of words, musical tones, and noises. The mucous membrane which lines all the other parts of the many-chambered middle ear also covers every portion of the bony arch. At four points, and only four, there is a break in the continuity of the bony walls of the middle ear: the beginning of the channel (the Eustachian tube) leading to the pharynx, the tympanic membrane, the membrane which spans the fenestra rotunda—the smaller of the two openings leading into the labyrinth —and the annular ligament which holds the foot-plate of the stirrup in the fenestra ovalis.

The labyrinthine system of cavities is commonly spoken of as the *internal* or *inner ear*. It has absolutely no direct communication with the outer world. It is practically, therefore, a serous cavity. In it is lodged the terminal expansion of the auditory nerve —a complicated mechanism made up of a variety of beautiful structures. Later, we shall see how disease may invade this inner sanctuary; but generally it escapes in great measure the rude attacks of inflammation which involve the neighboring middle ear.

Putting to one side, for the moment, the few other diseases or abnormal changes which may take place in the ear, we may say that it is the chief task of aural pathology to set forth and make plain the different changes which inflammation may produce in the three different cavities described above. We shall get a much clearer idea of "diseases of the ear" if we grasp and hold on firmly to this simple conception of a single morbid process, which, however, may vary greatly in its essential character, in its localization, and in its issues. In harmony with this idea, then, it may be truthfully said

that in ninety-nine out of one hundred cases of ear disease, the physician's task consists in finding out—(1) in which of the three cavities named the inflammation began; (2) the extent to which it has involved that particular cavity or system of cavities; (3) whether it has involved one or both of the neighboring cavities, and perhaps even remoter structures not belonging to the ear; (4) what are its essential characteristics; and, finally, (5) what are the alterations which it has produced in the tissues affected and in the secretions of the part. To make these points somewhat clearer, I will consider each of them briefly in turn.

1. **The Locality first Affected by the Inflammation.**—The external auditory canal is sometimes the seat of a primary inflammation which shows no tendency whatever to extend inward toward the cavity of the middle ear. At most, it will involve the outer aspect of the membrana tympani, which portion of the membrane, however, is an essential part (anatomically speaking) of the external auditory canal. On the other hand, a primary inflammation of the middle ear—in the strict sense of the term—is rarely if ever encountered. In the vast majority of cases the primary inflammation develops in the upper part of the pharynx, and spreads thence to the middle ear. The only apparent exceptions are the cases of middle-ear inflammation that have developed as the result of syphilis, scarlet fever, small-pox, measles, etc. But even in these cases there are generally good grounds for believing that the primary source of the disease must be placed in the pharynx. An inflammation of the labyrinth is probably never primary; and yet there are German authorities who maintain that there is such a disease as a primary inflammation of the labyrinth.

2. **The Extent to which the Inflammation may involve the Outer, Middle, or Internal Ear.**—In the external auditory canal an inflammation may involve the entire canal in all its parts, or it may be confined to one-half of the canal only—either the outer or the inner half—or it may occupy even a more limited area. When the middle ear becomes inflamed the prevailing tendency is probably toward a diffuse, more or less evenly distributed type of inflammation; but extraordinary exceptions to this rule are now and then encountered. Thus, for example, an inflammation may light up in the middle ear and spend its chief force in some limited portion of this system of cavities. Localized inflammations of the mastoid antrum and of the upper half of the tympanic cavity proper are no longer great rarities. When first seen these cases often present

every appearance of independent localized inflammations, owing either to the fact that the diffuse inflammation of the middle ear, out of which the localized inflammation grew, has by that time so far subsided as to be very insignificant, or else to the assumed fact that there may be such a thing as an independent localized inflammation of the middle ear.

3. **The Extent to which an Inflammation of one of the three Cavities may involve the other two, and perhaps also neighboring Parts.**—An inflammation of the external auditory canal shows practically no tendency to involve the middle ear. The outer portion of the membrana tympani may participate actively in the inflammation, but then it must be remembered that this is an integral part of the outer canal. Formerly, it was quite common to read of the danger arising from an extension of inflammation from the auditory canal to the brain, through the intervening bone. I doubt whether such a thing ever occurs; certainly not from a *bona fide* primary inflammation of this part of the ear. On the other hand, it is not an unusual occurrence for patients suffering from an inflammation of the external auditory canal to have at the same time, and from the same underlying causes, a subacute catarrhal inflammation of the middle ear. Neither of these, however, can rightly be spoken of as being secondary to, or an extension of, the other. An arthritis of the temporo-maxillary joint is an occasional result of an inflammation of the auditory canal (either primary or secondary). The relations of these two regions are so intimate that one cannot help being surprised that an acute arthritis is so seldom associated with an inflammation of the adjoining meatus. A localized inflammation (abscess) of the cartilaginous portion of the auditory canal sometimes burrows to a considerable distance from its original starting-point. I have known it to give rise in this way to a large collection of pus, which presented every appearance of being a parotid abscess. In a similar manner it may spread backward and present the external appearances of severe mastoid disease, thus rendering it an exceedingly difficult matter to reach a correct diagnosis.

To describe fully the paths along which an inflammation of the middle ear sometimes travels, would fill the space of an ordinary text-book. Countless air-spaces surround it in many directions, and from these, blood-vessels, lymphatics, and nerves extend, through minute channels in the bone, to the external periosteum of the skull and into the cranial cavity. That part of the jugular vein which lies upon the temporal bone, and is called the sigmoid sinus, is in

very close proximity to the middle ear. The same is true of the internal carotid artery. Blood-vessels of the middle ear pierce the annular ligament of the fenestra ovalis and anastomose with the vessels of the vestibular part of the labyrinth; and a similar anastomosis undoubtedly takes place between the vessels of the scala tympani and those of the middle ear through the membrane of the fenestra rotunda. These anatomical facts show how almost unlimited are the possibilities of an extension of a middle-ear inflammation.

In basilar meningitis, whether of the epidemic form or not, it sometimes happens that the inflammation extends from the cranial cavity, probably by way of the aquæductus vestibuli, into the vestibule and eventually into all parts of the labyrinth. Furthermore, there is every reason to believe that the acute inflammation of the middle ear, which is sometimes observed in these cases, owes its origin to an extension of the inflammation from the labyrinth. In this connection, however, it must be remembered that the inflammation may spread directly from the cranial cavity to the middle ear, as well as by the more roundabout course through the labyrinth. Such a direct spreading of the inflammation is favored, in some cases, by a congenital defect in the bony roof of the tympanic cavity; the dura mater and the tympanic mucous membrane, in these cases, being in direct contact with each other. This defective condition of the tegmen tympani is probably not an uncommon condition in infancy and early childhood; and while it serves to explain how basilar meningitis may readily set up an acute inflammation of the middle ear, it equally well affords a satisfactory reason for the rapid spread—as observed in certain exceptional cases—of an acute inflammation of the latter cavity to the meninges.

In early life the mastoid antrum is often separated from the outside soft parts (periosteum and skin) by a very thin shell of bone, and the bony channels for the emissary veins are doubtless often quite large. As a result of these anatomical conditions, it is not unusual in children to observe a rapid spread of an acute inflammation of the middle ear to the mastoid integuments. In this way large collections of pus sometimes form behind the ear before the drum-membrane ruptures or even shows a marked state of tension. The legitimate conclusion from this is that, in cases of this kind, the route of least resistance for the pus is through the antrum and openings for the emissary veins, and not, as in the case of adults, through the tissues of the membrana tympani. At first thought it would seem as if the Eustachian tube, the drainage-channel provided

by nature, ought to prove adequate, at least in the majority of cases, to the task of carrying off the secretions resulting from inflammatory action. As a matter of fact, this channel rarely suffices, and the tension due to the increasing accumulation of pus generally continues until the drum-membrane ruptures. The inadequacy of the Eustachian tube as a drainage channel is due to the fact that its tympanic orifice is not a gaping opening, but rather a valve-like slit, apparently closed, in a natural condition of the parts. When, therefore, an inflammation attacks the middle ear, the resulting swelling of the mucous membrane practically closes the tympanic orifice of the Eustachian tube; from being a loose-fitting valve it becomes a tight-fitting one, and all drainage through it probably ceases. Later on, in exceptional cases, large quantities of pus may pass through it into the vault of the pharynx; and in some chronic cases, in which the drainage through a small perforation in the drum-membrane is not sufficiently free, the greater part of a foul and irritating discharge may take place habitually through the Eustachian tube. A very striking hypertrophy of the pharyngeal mucous membrane below the mouth of the tube, and confined wholly to the side corresponding with the affected ear, is apt to result from this mode of drainage.

Before closing this section I must not fail to mention the fact that the facial nerve occasionally becomes involved, in the course of an inflammation of the middle ear. As a rule, facial paresis or paralysis is observed only in those cases of long-standing inflammation in which caries or necrosis of the bony walls has developed, especially in the vicinity of the fenestra ovalis and the entrance to the antrum. The facial nerve, it will be remembered, enters the meatus auditorius internus along with the auditory nerve, passes in close proximity to one of the whorls of the cochlea, curves round above the fenestra ovalis, and then, making a rather sharp bend, runs in a fairly straight direction downward, between the posterior margin of the oval window and the lower border of the entrance to the antrum, but much nearer to the latter, to emerge finally among the soft parts near the styloid process. For a distance of at least fifteen millimetres, in the middle part of its course through the temporal bone, this nerve is separated by a comparatively thin layer of bone from the mucous membrane of the middle ear. The favorite spot for caries in the tympanic cavity is precisely this neighborhood of the entrance to the antrum, and, consequently, it is not surprising that facial paresis or paralysis should not be a rare symptom in cases of long-standing purulent inflammation of the drum cavity. Now

and then, a recognizable degree of facial paresis is observed in the course of an acute inflammation of the tympanum. In these cases one is tempted to assume that the nerve stands in an abnormally close relationship to the tympanic mucous membrane; its surrounding shell of bone being, perhaps, defective at some point, or the presence of anastomosing blood-vessels between the two tissues rendering the extension of inflammation from the tympanum to the nerve easier than usual.

4. **The Characteristic Differences between Inflammations of the Ear.**—Inflammation of the external auditory canal presents only two characteristically different types—the diffuse and the circumscribed variety; and the latter is very apt to be the direct result of the former. The diffuse variety sometimes involves only a limited patch or area of the canal, and is then generally confined to such manifestations as congestion, moderate infiltration of all the layers of the skin, and desquamation of only the outer or exposed portions. At other times it extends throughout the entire length of the passage, and is then very apt to involve the outer surface of the drum-membrane. Under these circumstances there is generally more or less active exudation from the inflamed surface. It may be nothing more than a mere moistening of the parts, but in some cases the exudation may be so active as to present all the appearances of a veritable otorrhœa. In a few cases the patch of localized inflammation includes a sharply defined part—usually the posterior half—of the membrana tympani and the adjacent skin of the osseous part of the canal. The underlying cause is probably, in most cases, a disturbance of the general nutrition—some lack of balance between the processes of assimilation and those of destructive metamorphosis, or a sluggishness on the part of those organs whose function it is to eliminate from the blood all those used-up products which, if allowed to remain in excess in the circulation, will play the part of irritants at various spots in the body. The external auditory canal seems to be one of these ill-favored spots, and the vault of the pharynx is certainly another. For convenience it is customary to call this condition goutiness, or lithæmia, or latent gout. In young and apparently robust children we sometimes see very striking examples of this sort of diffuse inflammation of the external auditory canal, associated generally with a similar condition of the corresponding auricle; and in these cases we can almost always trace the disease directly to an improper diet and to the habit, on the part of the mother, of allowing the child to eat at any and all hours of the day.

Here, it is not improbable that the irritated state of the gastro-intestinal mucous membrane may, by reflex processes, excite an inflammation in the comparatively remote ear. Further on, when I take up the subject of goutiness in its relations to the ear, I will consider more fully the pathological changes which take place in the external auditory canal.

In the inflammations of the middle ear, very great differences may be observed. It is particularly in this class of cases that we must make close inquiry into both the direct and the remote causes, if we wish to gain even an approximately satisfactory idea of the character, localization, and extent of the inflammation. The least conspicuous, the most insidious, and perhaps, in the main, the most damaging in its effects upon the hearing, of all the different forms of middle-ear inflammation, is that which is technically known as "chronic catarrhal inflammation of the middle ear." Despite all the study of the past thirty years, we still have much to learn in regard to the pathological changes which characterize this insidious affection. Nevertheless, we are making some progress in our knowledge of this complex group, and we shall doubtless some day be able to separate it into at least some of its component elements. But, at the present time, this is not possible, and we can therefore do no better than to continue using this unsatisfactory term—"chronic catarrhal inflammation." Among the facts which have been ascertained in regard to this disease, I may mention the following: It is closely related to all the different nasal and pharyngeal vault affections; it is apt to develop in several members of the same family, thus suggesting the likelihood that heredity may play a part in its causation; certain localities and certain kinds of climate are competent materially to stimulate its activity; goutiness or lithæmia is unquestionably prone to aggravate, if not actually to cause it; a disordered state of the stomach, liver, intestines, uterus, and possibly other organs may reflexly, or in some other not clearly understood manner, produce the same effect; and, finally, our power to control the disease or to overcome the damage which it may have done to the function of hearing is very limited.

In this ill-defined affection we are safe in assuming that the important lesions—those which impair the hearing—are of such a nature as to render the transmitting apparatus (the ossicles and the soft parts about the oval and round windows) more rigid, less mobile than is natural. These lesions are of two kinds, viz., (1) thickening of the mucous membrane at various important points, like the

secondary tympanic membrane and the incudo-stapedial and stapedio-vestibular joints; and (2) increased rigidity (sclerosis) of the mucous membrane at these same points. The first of these lesions will be found to exist during the earlier period of the disease, while the second always belongs to a late stage, developing only after years of increased congestion of the mucous membrane, with more or less proliferation of its cellular elements. This latter change—viz., the production of a certain amount of new connective tissue—is followed in due time by certain further tissue-alterations to which the name *sclerosis* is given. These alterations, which take place with unfailing certainty in all newly produced connective tissue—no matter in what part of the body it may be located—consist in a general shrinking, both transversely and longitudinally, of all the fibre-like elements into which the cells have been converted, and also at the same time in an obliteration (or at least a marked diminution in calibre) of the blood-vessels which run through this tissue and of any glandular structures which it may contain. A sclerosed mucous membrane, therefore, is one which is not only thinner and less vascular than normal, but is also harder, less succulent, and consequently more obstructive to the quick and free action of the stapedio-vestibular joint.

As yet we are unable to form any very accurate idea of the extent to which the impaired hearing, in this class of cases, is to be attributed to the abrogation of the functions of the tensor tympani and stapedius muscles. The sclerosing process undoubtedly invades both of them, and to a greater or less degree paralyzes their action; and it is also conceivable that in certain cases a state of permanent contracture may be produced, whereby the membrana tympani, on the one hand, and the stapedio-vestibular annular ligament, on the other, are kept by these muscles permanently in an abnormal state of tension.

In the more acute forms of inflammation of the middle ear we encounter a number of very different pathological events. Rarely are two cases alike in all respects. The differences relate to the mode of invasion, the rapidity with which the disease spreads, the extent of area involved, the location of the spot or spots where it spends its chief force, the nature and extent of the damage done by it, the degree of pain which accompanies it, etc. All these differences, which for so many years sorely puzzled the aural surgeon, have now been to a great degree explained by the bacteriologist. An inflammation of the middle ear follows a certain course, and

presents certain pathological phenomena, according as the invading army of micro-organisms is composed largely of this, that, or the other variety, according to the resisting powers of the individual attacked, and, finally, according to the presence or absence of certain peculiarities in the anatomical relations of the middle ear.

Our knowledge in regard to the behavior of the different varieties of *micro-organisms* which have been found in the middle ear in different cases of acute inflammation, is still very imperfect. In fact, we have simply reached the point where we fee] warranted in attributing a large proportion of the more violent attacks, and especially those in which the inflammation shows a tendency to spread to neighboring structures, to the presence of the streptococcus. But in those severe forms of middle-ear inflammation which develop in the course of diphtheria, scarlet fever, measles, and small-pox, it is still uncertain to what extent the streptococcus and to what the micro-organisms peculiar to these diseases are responsible for the damage done.

The *resisting powers of the individual* attacked undoubtedly play an important part in determining how severe the disease shall be in any given case; but the ordinary external evidences of good health furnish no trustworthy criterion by which we may judge of the degree of these powers. It is doubtless in tuberculosis that these resisting powers of the mucous membrane invaded by the bacilli of this disease play the most striking part. There can scarcely be any reasonable doubt that at some time or other, and probably on many occasions, these bacilli have come in contact with the mucous membrane of everybody's middle ear. But only in certain exceptional cases have they found the local conditions favorable for their further life in this locality. And this favorableness of the soil (*i.e.*, the mucous membrane) to their growth and spread is simply another term employed for expressing the fact that there is a certain lack of vigor in the vitality of the part involved—*i.e.*, a diminished resisting power.

Finally, the *anatomical relations* are not wholly without influence in determining what particular portions of the middle ear shall become the seats of active disease. Thus, for example, it is extremely rare to witness any serious pathological changes in the vicinity of the mouth of the Eustachian tube, and this fact suggests the probable correctness of the view that quietude—absence of disturbing currents of air or fluid—is essential to the development of such a focus of disease. The region in question is the most unquiet

part of the middle ear, while the recesses and pockets above the membrana tympani and the mastoid antrum are undoubtedly the quietest. It is in precisely these spots that we find most frequently the evidences of the destructive work done by the tubercle bacilli and by the streptococci. The loose-meshed connective tissue which lies between the head and neck of the malleus and the outer wall of the epitympanic space (Fig. 21) – the region of Shrapnell's membrane—is peculiarly adapted to become the seat of such an invasion of micro-organisms, and it is therefore no wonder that even the adjacent bone itself is often invaded in this vicinity.

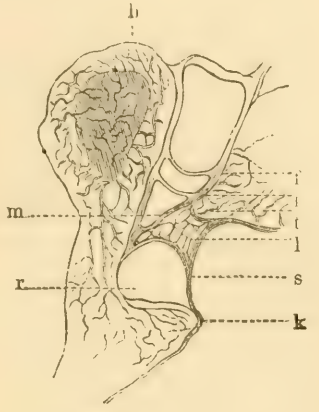

FIG. 21.—Longitudinal Section of the Hammer, showing the system of cavities or pockets lying between the head and neck of that ossicle and the drum-membrane. *h*, Head of hammer; *k*, short process; *s*, layer of skin toward external auditory canal; *r*, larger space situated just above the short process; *l* and *m*, smaller cavities. (After Politzer.)

The law which is here suggested applies to all those minute organisms which reach the middle ear through the Eustachian tube, along the free surface of the mucous membrane, either suspended in the air or (which is more probable) mixed with the secretions of the part. But in the case of syphilis it is highly probable that the organisms are brought to the region by the blood-current, if not in all instances, at least in the great majority; and we are therefore unable, in this disease, to speak of any particular part of the middle ear as being noticeably exempt from its manifestations. Possibly the vicinity of the oval or of the round window may be involved more often than other parts. This idea is suggested to my mind by the frequency with which the hearing seems to be seriously diminished.

In those cases of inflammation of the middle ear which owe their origin to a "cold in the head," to the entrance of some irritating fluid, like salt water, into the drum cavity by way of the Eustachian tube, or to the extension, earward, of a naso-pharyngeal catarrh of lithæmic or gouty origin, the inflammatory process involves the middle ear, so far as we are able to ascertain, diffusely and more or less evenly. It is possible that here, too, the conditions may be compli-

cated by the presence of certain varieties of micro-organisms which act only superficially and rather mildly upon the mucous membrane; the vasomotor disturbances created by the other etiological factors robbing the latter of its normal power of resistance. But when these cases, as they sometimes do, develop the most serious and widespread inflammation, we are forced to believe that the streptococcus or some other equally virulent organism (if such an one exist) has found its way into the cavity.

5. **The Alterations produced in the Tissues and in the Secretions.**—In the earlier stages of a simple inflammation of the middle ear, the blood-vessels of the mucous membrane are dilated in varying degree, and the tissues are more or less infiltrated with the watery elements of the blood and to some extent with lymphoid corpuscles. In a short time these same elements are poured out into the free spaces of the middle ear—those which under normal conditions contain simply air; and, as the inflammation progresses, the quantity of fluid thus poured out may become so great as to exert a strong pressure upon the surrounding walls. If this pressure exceeds a certain degree, pain will be developed; and a still further increase of the pressure may produce an actual necrosis of the soft parts pressed upon, by robbing them of their supply of nutriment. It is in this way, doubtless, that perforations often occur in the membrana tympani, and in the same way we may explain the development of localized areas of exposed, if not carious bone, in certain parts of the middle ear. But it is a mistake, I believe, to attribute all such middle-ear necroses wholly to the effects of pressure. It is more likely that both the mucous membrane and the underlying bone are robbed of their nutriment through inflammation and plugging of their blood-vessels due to an invasion of streptococci or other microbes. On the other hand, I do not wish to underrate the importance of pressure as a contributory factor in these necrotic processes, or to belittle the great value of paracentesis of the membrana tympani as a means of preventing the occurrence of such necroses.

Wherever blood-vessels or lymphatics run, there may we locate the routes along which the streptococcus can readily travel; and as both of these orders of vessels pass freely from the different chambers of the middle ear to the parts lying within the cranial cavity, so may we expect that, whenever there are favoring circumstances —diminished powers of resistance on the part of the patient, and an unduly long postponement of operative interference on the part

of the physician—the inflammation will spread from the middle ear to the intracranial structures.

The *discharge* which takes place from an inflamed ear may vary greatly in consistency, color, and odor. These different qualities bear some relation to the different pathological conditions of the parts; but, unfortunately, the relation is not of so fixed and constant a character that we can safely draw conclusions from them in regard to the nature of the lesions.

A thin, watery discharge, of slightly pinkish hue and without odor, is generally observed in cases of acute inflammation of the middle ear, soon after a perforation has developed in the drum-membrane. In a short time, however, the discharge grows thicker and assumes a yellowish hue. From this state, in favorable cases, it either simply becomes less abundant before it finally ceases altogether, or else it first passes through an intermediate stage in which the secretion presents all the physical characteristics of ropy nasal mucus. Even in such recent cases the discharge may be characterized by a very unpleasant odor, suggesting the thought of a possible caries of the bone. The odor, however, is simply an indication that the auditory canal has not been cleansed with sufficient thoroughness or frequency.

A creamy and very abundant discharge, in cases which commenced several weeks previously, and which were unusually severe in their earlier stages, is very apt to indicate that the disease is not confined chiefly—as is the case in most instances of simple purulent otitis media—to the tympanic cavity proper, but probably involves to an equal degree the associated system of mastoid cells.

In chronic cases, the presence of a brownish- or bluish-colored discharge, having a decidedly bad odor, is generally believed to indicate the existence of a carious bone process. The occasional appearance of blood in the discharge, in the same class of cases, almost invariably indicates the presence of a polypoid mass, or at least of granulation tissue, in some part of the inflamed ear.

The mere fact of a discharge from the external orifice of the ear must not be taken as satisfactory evidence that it comes through a perforation in the membrana tympani, even when the history of the case, the appearance of the membrana tympani, and the absence of a congested or swollen condition of the skin lining the external auditory canal point clearly to the middle ear as the source of the discharge. An exosmosis, a sort of sweating process, may be so active as to furnish a fairly abundant discharge from the ear. This

may occur under two quite different conditions: In one set of cases the tympanic cavity will be found full of fluid secretion evidently under pressure; and in the other, the membrana tympani will be found to be adherent throughout to the mucous membrane of the opposite wall of the middle ear. In the latter case, the amalgamation of the skin-covered drum-membrane with the mucous membrane of the inner tympanic wall seems to impart to it some of the characteristics of the latter; that is to say, whenever the Eustachian tube becomes inflamed, the spread of this inflammation to the structures of the middle ear expresses itself in a short time by the escape from the outer surface of the adherent membrana tympani, as if from the free surface of a mucous membrane, of a watery or seropurulent discharge.

A certain amount of *ropy mucus* forms a part of the discharge from the ear in so many cases that its presence scarcely calls for any comment. But when it is observed that this mucus constitutes the main constituent, we are warranted in drawing two conclusions: first, that the irritation or inflammation is, at that period of the disease, located principally in the Eustachian tube; and, second, that a free outlet does not exist at the lower or pharyngeal end of this channel, and that, in consequence of this obstruction, the secreted mucus finds an easier escape in the opposite direction, viz., by way of the middle ear and external auditory canal. In other words, the vault of the pharynx is the region which, in this class of cases and at this stage of the disease, calls most urgently for treatment.

CHAPTER III.

ANALYSIS OF SYMPTOMS.

In the present chapter I propose to analyze somewhat fully the various symptoms which are encountered by the physician, with greater or less frequency, in his experience with diseases of the ear. The list of these symptoms is not very long: it comprises impairment of the hearing, subjective noises, the phenomenon of hearing better in the midst of noise, the sensation of something moving in the ear when the head is moved, a sensation of fulness in the ear, unnatural resonance of one's voice in the affected ear, pulsation or throbbing, itching, soreness, pain, painful mastication, a discharge from the outer canal, dizziness, numbness, and possibly one or two other symptoms which do not immediately occur to me. Each one of these symptoms is attributable to some exciting cause, and a familiarity with these causes is essential to him who would arrive at a correct diagnosis in any given case of ear disease. It seems desirable, therefore, to take up these symptoms, one by one, and discuss them somewhat fully in their bearings upon the different pathological conditions of the ear.

DISTURBANCES OF THE FUNCTION OF HEARING.

Diminished Hearing.—This symptom indicates that the natural perception of sound has been interfered with at some point between the brain and the orifice of the external auditory canal. Inquiry should be made into the degree of impairment noticed, the rapidity or the slowness of its development, the circumstances (illness, exposure, accidental injuries) which preceded or accompanied the deafness, and the intermittent or fixed character of the symptom.

Degree of Impaired Hearing and its Rapidity of Development.—A moderate diminution of the hearing power, of recent origin, and unassociated with pain, is almost always due to one of two causes—an accumulation of cerumen in the external auditory canal, or a catarrhal swelling of the mucous membrane of the middle ear.

If the deafness developed somewhat suddenly, and without subjective noises, the probability is that the case is one of impacted cerumen. But if it developed more slowly, and especially if there had been a certain amount of tinnitus at the same time, the probabilities would favor the diagnosis of a catarrhal cause. If pain preceded the deafness, the lesion might be a furuncular inflammation in the external auditory canal, producing a closure of this passage, or it might be an acute catarrhal inflammation of the middle ear. Here, too, the presence or absence of tinnitus, and the presence or absence of the symptom of painful mastication, would help materially in determining the seat of the lesion; painful mastication and no tinnitus indicating a furuncular inflammation of the outer canal, while the existence of tinnitus without painful mastication would point to some change in the middle ear as the cause of the deafness.

The sudden or rapid loss of hearing after mumps or epidemic spinal meningitis nearly always indicates a lesion of the auditory nerve, either in the brain or at some point in the peripheral distribution of the nerve (cochlea or porus acusticus internus). If, with the loss of hearing, there are associated the symptoms of dizziness, marked subjective noises, and a staggering gait, the diagnosis of an auditory nerve lesion (probably labyrinthine) may be assumed with a good deal of confidence. The development of the same combination of symptoms in a person who has not, a short time previously, passed through an attack of either of the epidemic diseases mentioned, indicates the probable occurrence of something like an apoplectic effusion in the cochlea, or the development of a gumma or other syphilitic lesion in the porus acusticus internus, in the labyrinth, or at the oval or round window.

Finally, the slow and insidious development of deafness, even in those cases in which there are no plainly recognizable evidences of nose or throat trouble, points to the existence of something wrong in one or the other of these two regions, or in both. It is possible, however, that in some of these cases we may be justified in excluding both of these factors from any participation in the causation of the deafness, and in assigning the chief part to primary intratympanic changes of a rheumatic or gouty nature.

Circumstances Preceding or Accompanying the Deafness.—The exanthematous diseases, scarlet fever, small-pox, and measles, as well as typhoid fever and the grippe, are very apt to have middle-ear complications. Consequently, when deafness develops in the course of these maladies, or during the stage of convalescence,

we have a right to suspect the middle ear as being the seat of the alterations upon which the deafness depends. Deafness developing in the course of a head-cold will also be found, as a rule, to depend upon middle-ear alterations. The only exception to this rule is where the "cold" serves to render tight-fitting what before was a loose-fitting plug of cerumen in the external auditory canal. This is effected through reflex excitation of the ceruminous glands, as a result of which a much larger than the normal quantity of soft cerumen is poured out into the canal. Deafness following some injury to the head (*e.g.*, a blow, or a fall) should give rise to the suspicion that a fracture, or at least a diastasis, has taken place at the base of the skull, presumably through the Glaserian fissure. These cases may be divided into two categories: those in which the impairment of the hearing is due to some temporary interference with the conducting apparatus of the middle ear (escape of blood into the drum cavity, tearing of the upper part of the drum-membrane, or the swelling of these parts due to inflammation caused by the traumatism); and those in which the fracture has not been limited to the bony parts surrounding the drum-membrane, but has involved at the same time the mass of bone surrounding the cochlea and related cavities. The profoundness and the persistent character of the deafness alone warrant the conclusion, in a case of traumatic injury of the head, that this more serious damage to the temporal bone must have taken place. On the other hand, hemorrhage from the ear immediately after the occurrence of the injury, and even the establishment of a copious watery discharge a few hours later, do not justify the diagnosis of a fracture through the cochlear portion of the petrous bone; for both of these symptoms have been observed in cases in which the hearing has afterward been fully or almost fully restored; and very few, I imagine, will maintain the view that a traumatic injury of the cochlea may terminate in recovery of anything like a useful degree of hearing.

Exposure, for a long period, to loud noises—such, for example, as are encountered in the business of boiler-making or in that of a stamp mill—produces sometimes a profound degree of incurable deafness. It is not known surely whether the damage done to the ear in this class of cases is to be located chiefly in the cochlea, or chiefly in the conducting apparatus. I have seen comparatively few of these cases, but the impression which these few have left upon my mind is, that the perpetual jarring of the transmitting apparatus, causing the various joints of the auditory ossicula to perform excur-

sions of extreme amplitude, produces in time a subacute proliferative inflammation of the mucous membrane covering these joints and lining the middle ear generally, the ultimate issue of which is a permanent thickening of this membrane. The deafness, therefore, according to this hypothesis, would be due to anchylosis of the joints of the ossicles, and, probably, more particularly to anchylosis of the stapedio-vestibular joint.

Variable Character of the Hearing.—This symptom may be interpreted in various ways. In affections of the external auditory canal, it simply means that an obstacle of some kind blocks the way—at one time more, at another time less perfectly—and so prevents the free entrance of sound. This obstacle may consist of a foreign body (impacted cerumen, fluid or inspissated pus, or some object introduced from without), or it may be due to the obliteration of the calibre of the external auditory canal by the swelling of some portion of its walls (as in the case of a furuncle). The sudden transitions from good to bad hearing, and *vice versa*, point almost with certainty to some such temporary obstruction in the external auditory canal.

Lesions of the middle ear are also associated with variations in the hearing power, but as a rule the latter are much less marked and of less frequent occurrence. In a large proportion of the cases these variations in the hearing depend upon the fact that the Eustachian tube often remains in a much narrowed, if not actually closed condition, for longer or shorter periods of time. The presence of a serous or mucoid exudation in the tympanic cavity may readily give rise to variations in the hearing, according as it interferes or not with the working of the ossicular mechanism. In chronic cases of purulent discharge from the middle ear, the variations in hearing may be due to corresponding changes in the amount of pus accumulated on the outside of the conducting apparatus. A mass of granulation tissue, or of cast-off epithelium, in the vault of the tympanum, may overhang the stirrup and oval window, and play the part of a very efficient damper upon the transmission of sound to the adjacent labyrinth.

There are other causes of variable hearing in regard to which our knowledge is not very precise. In one class of cases, the patients observe that, in passing from the cold outdoor air into a warm room, their hearing becomes noticeably less acute; this condition usually lasts only a short time. In another class of cases, it is observed that bodily fatigue is competent to seriously aggravate

the existing impairment of hearing, even up to the point—as some patients insist—of complete deafness. In a third class, the patients find that in the midst of noise—in a noisy street, in one of our city omnibuses or horse-cars, in a railroad car, etc.—they are able to hear very much better than in the quiet surroundings of their homes. Finally, in a fourth class a well-marked improvement in the hearing is observed for a brief period (minutes, not hours) immediately after the local bleeding caused by the removal of a mass of hypertrophied lymphoid tissue from the vault of the pharynx.

In the first of these three classes of patients it will generally be found that there is habitually a congested and swollen condition of the naso-pharyngeal and aural tracts of mucous membrane; that is, that the calibre of the Eustachian tube is habitually so narrow that a trifling increase in the swelling of its walls may easily close it entirely for a little while. With this condition of vasomotor paresis in the domain of the nasal and aural mucous membrane, there is doubtless associated a diminished power of the vasomotor inhibitory nerves of the same region. Under the conditions named, therefore, it is easy to understand how a patient, in passing from a cold into a warm room, experiences a sense of fulness about the head, and a material increase in the hardness of hearing. Vasomotor disturbances also doubtless play a leading part in the cases which are referred to in class four.

In the case of those who hear much less easily when they are fatigued, both bodily and mentally, than when they are in a fresh and rested condition, it is likely that the impairment of the hearing is due in part to diminished (temporary) brain power, and in part to diminished nerve and muscle power in the working of the stapedius and tensor tympani muscles. The act of hearing is not entirely a passive act. The brain must be put in a receptive attitude, and, if the act of hearing is to be performed in its most perfect manner, it is necessary that the two muscles enumerated above should keep varying the tension of the drum-membrane and of the stapedio-vestibular ligament, in accordance with the ever-changing acoustic needs of these parts of the transmitting apparatus. In the case of a person who is noticeably deaf—and in whose middle ear, therefore, a certain amount of hardening of the soft parts doubtless exists—both of these acts—that of paying attention and that of altering the tension by muscular action—must be performed, even when both brain and muscles are thoroughly rested, with greater effort, with greater vigor, than in the case of a person with normal hear-

ing. When, however, such a person becomes exhausted with fatigue, it is easy to understand how both brain and muscle may refuse to make the great effort required, under these circumstances, for the successful performance of the act of hearing.

Hearing Better in the Midst of Noise.—There can scarcely be any doubt that in these cases, which are by no means rare, a certain amount of anchylosis, particularly at the stapedio-vestibular joint, must exist. In the midst of quiet surroundings the human voice, in its ordinary tones, produces no sound vibrations sufficiently vigorous to overcome the resistance offered by the rigid attachments of an anchylosed stirrup. The speaker must, therefore, under these conditions, employ a louder tone of voice, if he wishes to overcome this resistance and be heard by the patient. But when the latter is in one of our city omnibuses, or in a moving train of cars, or in any other place where there are loud noises frequently repeated, these often prove adequate to overcome, momentarily, the resistance offered by the anchylosis. During the continuance of these noises, therefore, the patient possesses a fairly mobile stirrup, and consequently at such times he or she is able to understand easily words spoken in an ordinary tone of voice; that is, these more delicate, less intense sounds exert, during the continuance of the noise, as much influence upon the patient's cochlea as they would upon that of a person with good hearing, amid quiet surroundings.

Diminished Range of Hearing and Deafness for Certain Tones.—Almost the only cases of this nature which have come under observation have occurred in professional musicians or in persons who had cultivated music a great deal. Ordinary individuals, with no special musical training, might very easily, it seems to me, pass through life without ever discovering the fact that their hearing was deficient for all tones above or below a certain pitch, or that they could not distinguish one or two isolated tones in the intermediate portions of the musical scale. In other words, it is very easy for a non-musical person to overlook any deficiencies of this kind; and, consequently, it is not possible to state just how often such anomalies in the hearing power occur. It is certain, however, that in actual practice both of the defects named are encountered quite rarely. Some years ago there was a decided tendency to refer these defects to some lesion of the cochlear portion of the auditory nerve; but in recent times the disposition is rather to assume that the fault lies in some part of the transmitting apparatus. In favor of this belief I may mention an experience which has doubtless

happened to many of my readers. I refer to the imperfect manner in which certain portions of a piece of music, played on the piano in an adjoining room, reach our ears through an ordinary partition wall. The deeper tones are generally heard plainly and easily, but sometimes whole portions of the piece, in its upper tones, fail entirely to reach us. The trouble here is clearly not with our ears, but with the partition wall, which lacks the power to vibrate readily in response to these particular tones which have failed to reach our ears. Now, if such a thing may happen in the case of a body like a partition wall, interposed between the source of sound and our ears, why may not the same thing take place when the transmitting apparatus of the middle ear happens to be so altered in its conditions of tension and mobility that it cannot readily vibrate in response to certain tones? This explanation, it seems to me, is the true one for at least a large proportion of cases of diminished range of hearing, or of deafness for certain tones.

SENSATION OF SOMETHING MOVING IN THE EAR WHEN THE HEAD IS MOVED.

This symptom points almost unerringly to the presence of a watery fluid in the tympanic cavity; while the sensation of something moving in the ear when the head is perfectly quiet, may be interpreted as indicating the presence of some living creature—presumably an insect—in the external auditory canal. Theoretically, one would expect that certain foreign bodies, lying loosely in the external auditory canal, would also produce the sensation of something moving in the ear whenever the head was moved. But, as a matter of fact, this is rarely the case. On the other hand, it is not an uncommon experience for patients with a foreign body in the external auditory canal to complain of the sensation of something moving in the ear and causing a crunching noise whenever they move their jaws. As strong corroborative evidence of the existence of a certain quantity of watery fluid in the tympanic cavity, I might mention the fact that those in whom this pathological condition exists often notice that they can hear perfectly well so long as they remain in the recumbent posture, but that the hearing again becomes clouded as soon as they hold their heads erect. When such persons lie down, the serous fluid, in obedience to the law of gravity, flows away from the membrana tympani and the oval and round windows, into the mastoid antrum, and possibly to a certain extent into ad-

jacent mastoid cells; and the hearing, under these conditions, must then be at its best. But when the head is brought again into the erect position, the fluid must flow back into the tympanum proper, and once more interfere mechanically with the working of the membrana tympani, ossicles, and secondary tympanic membrane.

SENSATION OF PRESSURE OR FULNESS IN THE EAR.

There are at least three different pathological conditions of the ear which may give rise to the sensation of pressure or fulness. These are: an accumulation of hardened cerumen in the external auditory canal; an increased tension of the membrana tympani outward, through the presence of too much air or too much secretion in the tympanic cavity; and, finally, a preponderance of the atmospheric pressure on the outer surface of the drum-membrane over that which is exerted, by way of the Eustachian tube, against its inner surface. So far as the first of these three conditions is concerned, it is not necessary to say anything further in this place. Pressure against the drum-membrane, from within outward, is generally due to the filling of the tympanum with secretion from an inflamed tympanic mucous membrane; but occasionally the tension of the drum-membrane outward is due to the presence of an excessive quantity of air in the middle ear. We have no precise knowledge in regard to the pathology of this peculiar condition. It is plain, however, that an obstructed Eustachian tube must constitute one of the factors requisite for the imprisonment of an excessive quantity of air in the drum cavity, and it is probable that the obstruction is valve-like in its nature, permitting the free entrance of air from the nasal cavities, but not permitting, as it does in the natural condition of the parts, an equally free return of any surplus air that may have entered the middle ear. If the problem be considered from the mechanical standpoint merely, it would seem as if the tympanic orifice of the Eustachian tube is more likely than any other portion of this channel to be the seat of such a valve-like obstruction. But if we study the question from the standpoint of pathology and pathological anatomy, we are forced to believe that the obstructive lesion is to be sought for rather at the other end of the tube or in the adjacent pharyngeal vault. Both hypotheses, however, are open to serious objections, and the final solution of the problem must await the accumulation of further facts bearing upon the condition in question.

In a normal condition of the parts the atmospheric pressure should be the same, or nearly the same, on both sides of the membrana tympani; but when this equilibrium is disturbed and the pressure from without inward is greater than that from within outward, a sensation of fulness will be felt in the ear. The cause of this preponderance of pressure upon the outer surface of the drum-membrane is to be found in an obstructed Eustachian tube, which permits the air to enter the middle ear too scantily. Then, furthermore, it is to be borne in mind that there is, under these circumstances, a constant tendency toward the formation of a vacuum in the cavity of the tympanum, by reason of the absorption of the air contained in this cavity. This absorption of the air is doubtless going on to a greater or less extent in the drum cavity even when all the relations are normal, but under such circumstances the frequent and unhindered entrance of a fresh supply of air from the naso-pharyngeal cavity prevents the establishment of even a slight approach toward the condition of a vacuum—or, in other words, it maintains the two opposing atmospheric pressures in a state of equilibrium. But when the Eustachian tube is obstructed, the air cannot enter the middle ear fast enough to make good the loss caused by this process of absorption, and from this moment onward the intratympanic atmospheric pressure becomes gradually less than that which operates against the outer surface of the drum-membrane.

UNNATURAL RESONANCE OF ONE'S OWN VOICE IN THE AFFECTED EAR.

This symptom is observed in a variety of pathological conditions of the ear, all of which, however, possess this feature in common, viz., that they present an obstacle to the free escape of sound through the external auditory canal. This resonance occurs in inflammatory conditions of the middle ear in which the membrana tympani is more or less thickened; in cases also in which there is no appreciable thickening of this membrane, but simply increased tension (either inward or outward); and, finally, in cases in which the external auditory canal is obstructed by the presence of a mass of impacted cerumen or some foreign body, or where a furuncle or other localized swelling closes a portion of the canal. In all the conditions enumerated a certain amount of independent resonance takes place either in the middle ear or in the external auditory canal, and gives rise to the sensation which is now under con-

sideration. For the moment, the sound of the speaker's voice is reinforced by the conversion of the middle ear or the external auditory canal—one or both, as the case may be—into a resonator capable of intensifying at least some of the tones composing the spoken words. Under normal conditions, this reinforcement of sound is not perceptible, and the speaker's own voice sounds natural to him. An obstacle of some kind, therefore, seems to be necessary to the establishment of the conditions characterizing a resonator. The closing of the orifice of the external auditory canal with the finger, during the act of speaking, furnishes easily the conditions required, and illustrates plainly what is meant by the term "resonance of one's own voice."

PULSATION OR THROBBING IN THE EAR.

This symptom, when associated with pain in the ear, points to the existence of an inflammatory condition either in the tympanic cavity or in the external auditory canal. The absence of any material diminution of the hearing, in a case of this kind, would warrant the belief that the inflammation is confined to the latter region; but when the hearing is impaired at the same time, it is not possible to draw any safe conclusion as to where the inflammation is located, although a careful review of the order in which the different subjective symptoms have developed may enable us to make a tolerably good guess. But it is in the non-painful cases that the explanation of the existence of pulsation in the ear is found to be the most difficult; and especially is this true of the cases in which the drum-membrane is still intact. Pulsation, under these circumstances, means that some arteriole in the middle ear is being pressed upon. The presence of fluid in the middle ear, in sufficient quantity to offer even slight resistance to the expansion of one of the small arteries, is perhaps the commonest cause of pulsation in the ear. An obstructed Eustachian tube may produce the same result by permitting the atmospheric pressure in the external auditory canal to force the drum-membrane or one of the ossicles against some arteriole on the inner wall of the tympanic cavity. It is possible also that this symptom of pulsation may owe its origin to the presence of a vascular growth in the immediate vicinity of the ossicles of hearing, or to bands of connective tissue which at some point exert pressure upon an arteriole of the middle ear. Besides these more or less direct intratympanic causes, a few instances have been

observed in which a somewhat vascular mass of adenoid tissue, by no means of large size, and located in close proximity to the pharyngeal orifice of the corresponding Eustachian tube, but not causing any marked obstruction of this passage or interfering to any appreciable degree with nasal breathing, has, in some way not easy to understand, given rise to pulsation in the ear. It is perhaps permitted to draw the inference that the venous circulation of the middle ear is obstructed by the presence of such a vascular mass in the vault of the pharynx, and that pulsation of the arteries next in order in the circuit is the result of this obstruction.

In cases in which the drum-membrane has been destroyed, either wholly or in large part, and in which there is still a certain amount of purulent otitis media, pulsation will usually be found to be due to the presence of a mass of vascular granulation tissue in the upper part of the tympanum, close to the stirrup and oval window.

ITCHING; SORENESS.

When these two symptoms are experienced in the external auditory canal, independently of any previous injury to the parts, or of any purulent discharge from the middle ear, they are usually to be attributed to an eczematous condition of the skin lining this canal. The itching is oftentimes intolerable, and yet the skin at the corresponding spot may appear to be in every respect normal. At other times there may be a great deal of local congestion and infiltration, and yet the symptom of itching may be wholly lacking. A tickling sensation is sometimes felt deep down in the ear, or, rather, just below it. There is very little doubt that the seat of the irritation which gives rise to this tickling sensation is to be located in the Eustachian tube or in the pharyngeal vault close to the tubal orifice.

PAIN.

In the absence of an evident traumatic cause, we may attribute the existence of pain in the ear to one of three conditions: first, a diseased tooth, producing a reflex neuralgia in the ear; second, an obstructed Eustachian tube, permitting undue atmospheric pressure to be exerted upon the membrana tympani, and probably an unnatural stretching of the mucous membrane lining the cavities of the middle ear, by reason of the rarefied state of the air contained in these cavities; and, lastly, an actual inflammatory process, which

may be located in any part of the structures or cavities composing the ear.

A *reflex neuralgic pain* is apt to be intermittent, and it is, as a rule, not specially severe; but in exceptional cases it may be so severe, and the paroxysm may be so prolonged, that the physician in attendance will feel almost sure that he is dealing with a case of serious ear inflammation. The mirror and speculum can alone set him right in a case of this kind, although the absence of any appreciable impairment of the hearing, and of tinnitus, can almost be trusted as confirmatory evidence of the correctness of this diagnosis.

The pain which owes its origin to an obstructed Eustachian tube is apt to be paroxysmal in character, and is never severe. With it, furthermore, are generally associated tinnitus, a sense of pressure or fulness in the ear, and an unnatural resonance of the patient's own voice. Then, finally, there is rarely lacking an antecedent history of nasal or naso-pharyngeal inflammation—the immediate cause of the obstruction in the Eustachian tube.

The pain which is associated with an inflamed ear presents different characteristics, and is to be interpreted differently, according to where the seat of the inflammation is located; according to whether it is of recent date, or has existed for a long time; according to whether it develops in a previously healthy ear, or in one that has been the seat of a chronic inflammatory process; and according to the nature of the remedies or remedial measures which may have been applied in the particular case under consideration. The problems which belong properly under this head cover a wide field of aural pathology, and it will not be practicable for me to touch upon more than some of the leading points connected with these problems.

1. *Location of the inflammation in its relations to the pain.*—When the latter symptom is referred directly to the depths of the ear, and to this locality only, we may safely conclude that the inflammation has not extended beyond the auditory canal or the tympanic cavity proper. There is nothing in the character of this pain, however, that would warrant us, without the aid of other symptoms, in deciding that the inflammation must be located in one rather than in the other of these two regions. When the pain radiates from the ear upward, over the side of the head, upward and forward toward the temple, and backward toward the occipital region, the conclusion is warranted that the mastoid antrum and epitympanic space have become actively involved in the inflammation. Then, in the next place, the concentration of the pain in the region immedi-

ately behind the ear signifies that the inflammation has spread from the mastoid antrum to the neighboring cellular structures. Finally, in rare cases, the pain persists in this region even after operative interference has provided relief from all pressure and thorough drainage for all the cells involved in the inflammation. Under these circumstances we are warranted in drawing the conclusion that the inflammation has extended so far backward as to involve the walls of the sigmoid sinus, and perhaps even to set up a phlebitis of this vein. Furthermore, we are permitted to assume that the dura mater which lies directly over this part of the temporal bone is, to a greater or less degree, involved in the inflammatory process; but how far this inflammation has progressed, and whether or not the neighboring brain substance is also involved, are questions upon which the pain alone throws very little light. Neither can we draw any safe conclusions from the intermittent or constant character of the pain experienced.

2. *Duration of the pain.*—The mastoid processes of different individuals differ so widely in their anatomical construction, and there are such different degrees of richness of anastomosis between the blood-vessels of all this neighborhood in different individuals, that the mere duration of the pain cannot, in cases where the inflammation is of purely recent origin, be taken as a safe guide to the nature and extent of the pathological changes which it has produced in any given case and at any given moment of time. If, for example, the tympanic and mastoid blood-vessels anastomose freely with those which lie within the cranial cavity and in the bony channel through which the sigmoid sinus passes, the tympanic inflammation may spread quickly to these more dangerous regions. Then, again, if the pneumatic cells are of large size, and widely distributed throughout the mastoid process and immediate neighborhood, the inflammation may, in a very few days, produce an empyema as extensive as that which we should ordinarily not expect to see developed in less than two or three weeks. The duration of the pain, therefore, aids us only to a limited degree in forming an idea as to how far, in acute attacks, the inflammation of the middle ear has progressed in any particular case.

In cases of inflammation confined simply to the external auditory canal, the duration of the pain is a matter of no serious consequence, and we may therefore pass on to the consideration of those cases in which pain develops in an ear that has for months or years been the seat of a purulent inflammation of the middle ear. Brief attacks

of pain are of rather common occurrence in these chronic purulent cases, and they usually indicate that some temporary obstruction to the free escape of pus from the middle ear is causing pressure upon an inflamed and therefore sensitive mucous membrane. But when the pain persists for days, or even weeks, we may with justice suspect that either in the epitympanic space or in the mastoid antrum, pathological changes are at work which may end in serious intracranial disease or in phlebitis of the sigmoid sinus. At all events, we should not fall back upon the diagnosis of a chronic subacute hypertrophic (or condensing) osteitis until we shall have thoroughly satisfied ourselves that the other more serious conditions do not exist.

3. *The possible dependence of the pain upon the local employment of remedies or remedial measures.*—This is a question which it is sometimes very difficult to decide. Nevertheless, it is one which every physician who treats a case of ear disease should bear constantly in mind. And it is not simply the beginner in aural therapy who needs to be cautioned upon this point: the most experienced otologists are obliged to keep this maxim constantly before them. I need only to mention how easy it is to overstep the proper limits of mechanical manipulation of the structures of the external auditory canal and middle ear, or to apply such a remedy as nitrate of silver a little more freely or in a more concentrated form than the parts can bear with advantage. Pain, under these circumstances, affords the best warning that our therapeutic ways need to be mended.

PAIN PRODUCED IN THE EAR BY MOVEMENTS OF THE JAW.

This symptom points to the existence of inflammation in the external auditory canal—an inflammation which may have developed in the cutaneous lining of the canal primarily, or one which may have extended to this locality from the adjacent middle ear or from the temporo-maxillary joint. I remember a single instance in which this symptom owed its origin to the circumstance that a powerful upward blow upon the jaw had fractured the thin plate of bone which separates the joint cavity from the external auditory canal. I also remember an instance in which the pain in the ear, caused by movements of the jaw, was due to a primary (presumably rheumatic) arthritis of the corresponding temporo-maxillary joint. In mumps the movements of the jaw are apt to produce a painful sensation in the region of the ear, and yet on examination the external

auditory canal will be found to be free from any evidences of inflammation. The pain in such cases is doubtless to be attributed to the pressure exerted upon an inflamed parotid gland.

DISCHARGE FROM THE EAR.

A very large percentage of aural troubles are accompanied by a discharge from the external auditory canal, and this discharge may come from a variety of sources, and may vary considerably in quantity, in its physical characteristics, and in its duration.

Sources.—An excessive flow of cerumen constitutes the simplest form of discharge from the ear. When the secretion from the ceruminous glands first reaches the surface of the skin, it has a pale yellow color, and is quite like water in its consistency. In a few cases, probably under the influence of reflex stimulation, this secretion is poured out in such quantity as to lead the patient to speak of it as a "discharge from the ear." While in these exceptional cases the ceruminous glands alone seem to furnish the discharge, there is a much larger class of cases in which the fluid evidently comes from the surface of the skin of the auditory canal generally. I refer to cases of diffuse inflammation—probably of gouty origin—of the skin lining the external auditory canal. In a third class of cases the discharge may come from a very limited area of the canal, as from a circumscribed ulceration or from a mass of granulation tissue; both of these lesions being independent in character, and not having any connection at the time with deeper middle-ear trouble. Such cases are by no means common; and still more rare are those in which the discharge comes from an abscess which lies below, or in front of, the external auditory canal, or in the parotid region, and forces an outlet for itself through the walls of the canal. In the great majority of instances, however, the discharge comes from the middle ear, through a perforation in some part of the drum-membrane, or through the soft tissues situated just above the membrane and known as Shrapnell's membrane, or finally through a fistulous channel in the adjacent wall of bone. It is possible, also, that a portion of the abundant watery discharge which is observed to follow a fall or blow upon the head may represent an escape of cerebro-spinal fluid.

Duration.—A discharge from the ear, which continues through weeks, months, or even years, is almost sure to be of middle-ear origin; and yet there are occasional exceptions to this rule. When,

for example, a diffuse gouty inflammation of the canal progresses so far as to involve the surrounding walls of bone, there is apt to be a fairly active discharge, and it may go on for a long period. From the mere fact that a discharge is intermittent in character, we can draw no safe conclusions as to the source from which it comes.

Physical Characteristics.—A thin, watery fluid is the usual type of the discharge which takes place in the earliest stages of an acute middle-ear inflammation. When the discharge from an inflamed tympanum becomes mucoid in character, we have a right to infer, as already stated in a previous chapter, that it is being secreted by the glandular structures in the walls of the Eustachian tube, or in the anterior end of the tympanum, near the orifice of the Eustachian tube. A bloody or blood-stained discharge indicates, in acute cases, a high degree of fulness of the blood-vessels belonging to the parts, or even a rupture of some of them; in chronic cases it indicates the development of granulation tissue, the newly produced and delicate-walled blood-vessels of which have ruptured at one or more places. Brown, brownish-black, and bluish discharges can usually be traced to an area of diseased bone located somewhere in the epitympanic space or in the region of the mastoid antrum. A copious discharge, persistent in character and consisting almost entirely of creamy pus, points almost invariably to mastoid disease, usually involving a larger or smaller portion of the pneumatic cells of which it is composed. A foul-smelling discharge may come from any part of the ear, and must not be accepted—as is often done—as evidence of the existence of bone disease. The foul odor simply indicates a stagnation of the discharge in some part of the external auditory canal or the middle ear, to which air has access, and where, therefore, decomposition is almost sure to take place.

VERTIGO.

This symptom is often encountered in otological practice. The mere act of syringing the ear is competent to produce dizziness in a perfectly healthy person. Manipulations of the membrana tympani and inner half of the external auditory canal with a delicate probe or a curette, even when carried out with gentleness, are also competent to produce the same symptom. A plausible explanation of this phenomenon is that the irritation of the membrana tympani or adjacent walls of the external auditory canal induces anæmia of the brain through reflex vasomotor spasm. The same symptom may

also be produced in other ways than those already mentioned; as, for example, by undue pressure exerted upon the stirrup, either directly through the agency of a polypoid growth or a mass of laminated epithelium, or indirectly through increased atmospheric pressure upon the outer surface of the membrana tympani. In these instances it is clear that there is increased pressure upon the contents of the labyrinth, and this means a direct irritation of the nerve centres which are located in the ampullæ of the semicircular canals, and which—as is now generally conceded—govern the sense of equilibrium.

SENSATION OF NUMBNESS AROUND THE EAR.

In various affections of the ear it is not an uncommon experience to hear patients complain of a peculiar sensation of numbness in or about the ear. The ear feels dead, they say. Hitherto I have attached so little importance to the symptom that I have not even taken the trouble to ascertain more exact data respecting the limits of this area of numbness: whether the sensation varies in intensity, and under what circumstances the patients become conscious of its presence. I remember, however, that some of the patients have spoken of this numbness as being particularly noticeable when they brushed their hair on the corresponding side of the head, or when they passed their fingers lightly over the auricle and adjacent skin surfaces. Others have been conscious of the numbness even when these parts were not touched. I have refreshed my memory by consulting Quain's Anatomy, and I find that the relations of certain branches of the trifacial nerve to the middle ear and external auditory canal are such that one can readily understand how inflammatory processes in the regions named may, in certain individuals, induce sufficient pressure upon these nerves (through inflammatory exudation) to give rise to the symptom which is here under consideration. For example, the branch of the superior maxillary nerve which supplies the integument over the malar bone passes through the aquæductus Fallopii, directly above the tympanic cavity. Then again, the auriculo-temporal branch of the inferior maxillary nerve passes outward between the ear and the temporo-maxillary articulation, and supplies the skin of the external auditory canal, portions of the auricle, and the greater part of the temporal region. The symptom of numbness in and around the ear should therefore be added to the list of phenomena which may be observed in inflammations of the drum cavity and external auditory canal.

CHAPTER IV.

THE VARIOUS ALTERATIONS IN COLOR, TEXTURE, AND POSITION PRESENTED BY THE MEMBRANA TYMPANI, AND THEIR SIGNIFICANCE.

NORMAL CONDITIONS.

THE typically normal drum-membrane is something which the otologist does not often see. On the other hand, the most acute hearing may be possessed by an ear in which the membrana tympani presents decided departures from what we assume to be the normal standard.

FIG. 22.—Normal Tympanic Membrane, as Seen from the External Auditory Canal. (Very much enlarged.) In the posterior and superior quadrant of the membrane, a little to the left of the manubrium mallei, may be seen the shadowy outlines of the long process of the ambos. (After Zuckerkandl.)

In the adult the drum-membrane should present a slightly pearl-gray color, and yet at the same time it should also possess a certain degree of translucency. The substantia propria, which forms the groundwork of the drum-membrane, is similar in structure to certain tendons and aponeuroses of muscles which present a gray or pearl-gray color, and it is not unlikely that this may explain, in large measure, the grayish hue of the normal tympanic membrane. In infants and young children this peculiar color is either lacking or is less well defined.

Over the outer surface of the membrane are spread, first, a thin layer of elastic tissue, capillary blood-vessels, lymphatics, and nerves, and then finally a pellicle of horny epithelial cells. Under normal conditions these superimposed structures offer very little obstruction to the passage of light, but a part of it is undoubtedly arrested by the substantia propria, and reflected back to the eye of

the observer from its outer surface, thus producing the grayish appearance already referred to above.

From the processus brevis to its lower free end the manubrium mallei is, as it were, sheathed in the substantia propria, and forms therefore an integral part of the drum-membrane. Its outer surface is covered by soft parts (mainly epidermis) of exceeding thinness, and consequently under normal conditions it presents to the eye of the observer an appearance as if this piece of bone were entirely uncovered. The picture is that of a narrow white or whitish-yellow straight band running from the upper and anterior limit of the membrana vibrans downward and backward to about the centre of the membrane. Probably in most cases the tip end of the manubrium will seem to be a little nearer to the anterior inferior than to the posterior superior periphery of the membrane. But for all practical purposes it is sufficiently accurate to describe this really central point as *appearing* to be equidistant from the two peripheries.

The processus brevis itself, as seen through the speculum by reflected light, looks like a tiny cone-shaped spur, whose base merges insensibly into the surrounding soft parts. Its color is precisely the same as that of the manubrium from which it springs.

In a normal state the outer surface of the drum-membrane is quite smooth; sufficiently so, in fact, for the light to be reflected from it in much the same manner as it ordinarily is from a polished surface of hard wood. By reason of the shape—that of the concave side of a shallow cone—and the inclination of the membrane, the area of reflected light always seems to have the same limits and to occupy the same position upon the membrana tympani. It is seen in the form of an isosceles triangle whose apex coincides with the tip end of the manubrium mallei, while its comparatively narrow base rests against the periphery of the membrane. It is technically termed "the bright spot."

Under natural conditions the region occupied by the membrana flaccida—Shrapnell's membrane—is not distinguishable from the neighboring skin-covered walls of the auditory canal by any special boundaries or differences in color or texture. The region in question lies directly above the processus brevis of the malleus, and its limits are the sides and top of the arched notch in the squamous portion of the temporal bone.

PATHOLOGICAL CONDITIONS.

Under the influence of disease the membrana tympani may present a number of different pictures, some of which possess a fixed significance, while others can only be safely interpreted in the light of both the history of the case and certain accompanying phenomena. Simple pictures, indicative of a single pathological process, do not often come before us for interpretation. Almost always they are of a complicated nature.

Of all the pathological changes which are observed in the drum-membrane, an *undue fulness of the blood-vessels* is probably the commonest. This congestion is observed first in the region of Shrapnell's membrane, from which point it extends along the manubrium mallei and around the periphery of the membrane; these being the localities through which the main arterial and venous trunks pursue their course. If the exciting cause continues or becomes more pronounced, either the manubrial and peripheral lines of congestion will broaden out into veritable bands, or else a diffuse congestion of the minute blood-vessels distributed to the intervening portions of the drum-membrane will gradually establish itself; and coincidently with these changes a certain amount of infiltration of the congested tissues will be sure to take place.

At the very onset of an acute attack it is not an uncommon thing for one or more of these small blood-vessels to rupture and permit the escape of blood. When the latter flows slowly through the breach in the wall of the vessel, the epidermal layer does not break under the increasing pressure, but gradually stretches until the resulting sac, filled with blood, may be as large as a large pea. The starting-point of these hemorrhages is the immediate vicinity of the processus brevis, at which point the main vascular trunks pass from the middle ear into the external auditory canal, or from the latter region into the former. It is not at all an unusual thing to find in these same acute cases a blebs filled with bloody serum in the place of fluid or clotted blood.

As regards the pathological significance of these two different pictures, the following statements may aid the observer in arriving at fairly correct conclusions: A dilated condition of the manubrial and peripheral blood-vessels may be either the outward expression of similar vascular disturbances in the middle ear, or else simply the effect of an inflammatory disturbance in the external auditory

canal—*e.g.*, eczematous in character. The absence of any recognizable eczema in the neighborhood furnishes strong evidence in favor of the former hypothesis. On the other hand, the presence of an eczematous condition of the skin of the outer canal may so interfere with the venous circulation of the membrana tympani that the latter may present a markedly congested and infiltrated condition. When we are in doubt how we should interpret such a picture, we may generally obtain evidence enough to determine the question by carefully weighing the previous history and by testing the hearing of the affected ear. The absence of tinnitus, of a sense of pressure, or of an antecedent cold in the head, taken in connection with at most a very slight impairment of the hearing power, would favor the belief that the congestion and infiltration are simply phenomena of interference with the surface circulation of the drum-membrane. On the other hand, a history pointing to trouble advancing by way of the Eustachian tube, and the existence of well-marked diminution in the hearing power (when not of ancient date), would justify us in maintaining that the pathological changes observed in the drum-membrane are part and parcel of those which exist in the middle ear.

Still another picture is sometimes encountered, viz., that of a decidedly opaque, flat, or even slightly convex membrana tympani, on the outer surface of which are seen a limited number of isolated, tortuous, and radiating blood-vessels. This picture is one of comparatively rare occurrence. Under normal conditions the membrana tympani possesses two separate networks of blood-vessels: one which is spread out between the mucous membrane and the substantia propria, and a second which is similarly spread out between the latter and the epidermal covering. It is therefore easy to understand that under a sufficiently high pressure from within, the first network of blood-vessels—that which lies next to the mucous membrane—might be completely closed, and the outer network thus be forced to do double duty by way of compensation. This is apparently what took place in one of the cases of tubercular disease of the middle ear which are reported in a later chapter. In this case cheesy material accumulated in the cavity of the tympanum and pushed the drum-membrane out slightly. Over the outer surface of this yellowish-white and thoroughly opaque membrane ran three or four tortuous, radiating blood-vessels, distended far beyond their natural calibres. The skin lining the external auditory canal appeared to be entirely normal. It is hard to see what other factor

than pressure from within outward could have brought about this dilatation of the blood-vessels on the outer side of the drum-membrane.

In another set of cases certain pathological conditions existing in the cavity of the tympanum cause material changes in the color displayed by the membrana tympani. Thus, for example, this membrane may seem to have a deep red or a purplish color, and yet on careful examination it will be found that there is no recognizable fulness of the plexus of blood-vessels running between the epidermis and the substantia propria. In such cases the coloration may be due either to the presence of a blood-stained serum in the middle ear, or to the reflection of light from an engorged mucous membrane covering the promontory. Then again, the presence of a yellowish serum in a middle ear whose lining mucous membrane is highly congested will give to the membrana tympani, under reflected light, a dark bottle-green color. The entrance of air into the tympanum when thus filled with serum will cause a still further modification of the picture, viz., that due to the presence of sharply outlined bubbles of air.

Besides the case of diffuse redness of the entire membrana tympani, there are others, of decidedly rare occurrence, in which the lower third, or at most the lower half, of the membrane alone presents a distinctly red coloration. One's first impulse, on seeing this picture, is to assume that blood-stained serum fills the middle ear to a corresponding level or depth. However, in the only instances of this phenomenon which I have seen, the upper limit of the colored area did not move in response to the movements of the patient's head, but remained fixed. There was no fluid exudation in the middle ear, but instead the floor of this cavity was occupied by a well-characterized vascular new-growth (hæmangioma).

A *whitish or yellowish-white coloration of the drum-membrane* is of frequent occurrence, but not of uniform significance. The white appearance may be due to the deposit of calcareous particles in or upon the outer surface of the substantia propria; to the presence of some white material in the middle ear, resting directly against the inner side of the membrane; and, finally, to the soaked condition of its epidermal layer, due either to inflammatory exudation or to fluid which has reached these structures from without.

Calcareous deposits are usually seen in the form of white patches which possess sharply defined boundaries. According to Politzer, the chalky particles are commonly deposited in the tissues of the sub-

stantia propria alone, but at times they may also be found spread out over both of its surfaces—beneath the epidermal layer, on the one hand, and the mucosa, on the other. The polished outer surface of these white patches furnishes sufficient proof of the fact that this foreign material lies between the layers and is not affixed to the outer surface of the membrane. By means of a probe, or, better yet, by aid of the point of a paracentesis needle, one may easily verify the fact that the patch is really a plate of stone-like hardness. When practically the entire drum-membrane is invaded by this pathological change, mere ocular inspection will often have to be supplemented by this test of touching the parts before one can be perfectly sure of the nature of the lesion.

FIG. 23.—Horseshoe-shaped Deposit of Calcareous Material. (After Politzer.)

As regards the significance of such patches, it is generally believed that they furnish good evidence that at some time in the past a suppurative inflammation must have occurred in the corresponding tympanic cavity; that, after the subsidence of the inflammation, aggregations of pus cells were left behind in the tissues; and that these, in the course of time, became converted first into cheesy, and then into calcareous, material. At post-mortem examinations these calcareous deposits have also been found in the neighborhood of the stapedio-vestibular joint, a location where they could scarcely fail to cause a marked degree of deafness. When, therefore, a calcareous plate is observed in the tympanic membrane of an ear which is seriously deficient in hearing power, we are justified in entertaining the suspicion that a similar deposit of calcareous material has probably taken place in the vicinity of the foot-plate of the stirrup.



FIG. 24.—Calcareous Thickening of the Margin of a Large Perforation. (After Politzer.)

The white coloring usually produced by the exudation of the watery elements of the blood into the epithelial cells of the epidermal layer, is a picture which may be seen in the early stages of nearly every acute purulent inflammation of the middle ear. The period during which this picture can be seen is of short duration, for very soon exfoliation takes place, and an intensely red background presents

itself to the eye in the place of the earlier white one. Strange as it may seem, this pathological change in the dermal covering of the drum-membrane is very often misinterpreted by physicians who, while able to obtain—by means of the speculum and reflected light—a view of this membrane, have not yet familiarized themselves sufficiently with the different pictures which it presents. Repeatedly I have been called to see a case of this kind in consultation, and have been told by the attending physician that he had examined the ear, but—to his great surprise—had found the drum-membrane entirely free from congestion. In these instances I have cautiously removed the soaked epidermis from a part of the posterior half of the membrane, and have then asked the physician to re-examine the ear. The lifting up, as it were, of one corner of the curtain has always sufficed to reveal the underlying intense inflammation, and has thus made plain what before seemed strange and mysterious, viz., the combination of a strong and persistent earache with an apparently uncongested membrana tympani. If a mop made by winding a little absorbent cotton around the free end of a malleable steel cotton-carrier fails to remove the epidermis from such a limited area, the smaller size of smooth-edged ring-shaped curette will be found entirely adequate to accomplish this task.

Still another change, viz., a *thickening and hardening*, is sometimes observed in the tissues *of the membrana tympani*. It is probably the result of some antecedent inflammation, and I will therefore reserve the larger part of what I have to say on the subject for a later chapter. I will merely say here that there seem to be two kinds of such hardening: a milder form in which the membrane becomes converted into a perfectly inelastic tissue like old and very dry parchment; and another in which it assumes the thickness, hardness, and polish of a finger-nail.

Atrophy of the membrana tympani is a lesion which may be observed either with or without the condition known as sclerosis of the mucous membrane of the middle ear. Long-continued atmospheric pressure upon the outer surface of the drum-membrane, when it is not counterbalanced by a pressure of equal power upon its inner surface, causes gradual absorption of the substantia propria to take place. A drum-membrane without any substantia propria is like a piece of thin india-rubber, and may be stretched to an extraordinary degree before a rupture will occur. In extreme cases it may be seen lying like a thin film over the inner wall of the tympanic cavity; and under these circumstances even the most experienced ob-

server may at times be in doubt, for a moment or two, whether he is dealing with a case of this kind, or with one in which the membrana tympani is totally destroyed. After a gentle inflation of the middle ear this delicate elastic membrane will be found blown out far beyond the plane of the normal drum-membrane. As it remains only a very short time—not more than a minute or two—in this condition of extreme distention, the physician, after administering the inflation, must at once make the examination with speculum and reflected light.

Fig. 25.—Appearance Presented by the Tympanic Membrane when Distended by an Excess of Air in the Middle Ear. (After Politzer.)

The lesser degrees of atrophy from pressure are doubtless of frequent occurrence, but they generally escape detection. In cases of sclerosis of the mucous membrane of the middle ear, we find an atrophy of the membrane which seems to differ from that which I have just described. The membrane is apparently just as thin and transparent as in the other form of atrophy, but it seems to retain its substantia propria unchanged; for the membrane is at most very little sunken, and inflation does not cause it to bulge to an unnatural extent. This condition, as it appears to me, may be explained in the following manner: The atrophy is probably limited to the mucous membrane lining the membrana tympani; although perhaps the contraction, which is a fundamental part of the process of sclerosis, may at the same time interfere with the circulation of blood in this membrane to such an extent as to diminish materially its entire blood-supply, and in this way lessen the bulk of the substantia propria.

Closely allied to this condition of atrophy is that of an *abnormally depressed membrana tympani*. So far as I am aware, there are only two forces which are competent to effect this, viz., unresisted, or inadequately resisted, atmospheric pressure upon the outer surface of the membrane, and the retraction of any false membranes which may run from the lower end of the manubrium mallei to the inner tympanic wall. It is doubtful whether mere retraction of the tendon of the tensor tympani muscle can do more than increase the tension of the membrana tympani. When the so-called *adhesions*—bands of newly formed connective tissue—pass from the lower end of the manubrium mallei to the inner wall of the tympanum, they may by their retraction produce a marked inward rotation of the

malleus. But such adhesions are usually found to be associated with other easily recognizable evidences of a former severe inflammation of the middle ear. On the other hand, when the depression is due simply to increased atmospheric pressure (by reason of an obstructed Eustachian tube) all such evidences of a former suppurative disease will be lacking.

FIG. 26.—Tympanic Membrane Adherent to the Promontory Throughout a Limited Area. *a*, The point where the membrane is bound down by adhesions. (After Politzer.)

There are a few trustworthy *signs which indicate whether a drum-membrane is or is not depressed.* It is not safe to concentrate our attention upon the membranous portions of the membrana vibrans, in the hope of thereby determining whether it is depressed beyond the position which it should normally occupy. While such an inspection will sometimes reveal the truth, in very many instances it will leave the observer in a state of doubt. He should preferably observe the following points: the apparent length of the manubrium mallei; its relations to the posterior fold, as it is technically called; the ridge-like prominence of this fold; the distinctness with which the long process of the anvil and the head of the stapes may be seen; the degree of conspicuousness of the processus brevis; and, finally, the condition of the "bright spot." From these six points—and more particularly from the first five—he will be able to learn certainly whether the membrana tympani is materially depressed. In regard to slight degrees of depression, very few observers, I suspect, will feel disposed to express their opinion in very positive terms.

(1.) Under normal conditions the long process of the incus and the head of the stapes should either not be seen at all through the membrana tympani, or they should be just barely visible when the posterior superior quadrant is closely scrutinized. On the other hand, when the drum-membrane is unmistakably depressed, the exposed parts of these two ossicles come into view at once when the membrane is illuminated. In cases of extreme depression they may even push the membrane out a little at the point of contact.

(2.) When the membrana tympani has a normal inclination the lower end of the manubrium mallei reaches down to a point about midway between the upper and the lower borders of the membrane. When the latter, however, is depressed, the manubrium appears to be noticeably shortened. In cases of extreme depression this

foreshortening is a striking phenomenon. In fact, the umbo and the processus brevis may seem almost to coincide.

(3.) The third alteration is the change in the angle which the manubrium makes with the posterior fold. When the relations are normal this angle is one of seventy-five or eighty degrees, but when the membrane is depressed it may be reduced to forty or even thirty degrees.



FIG. 27. Depressed or Sunken Membrana Tympani. The most striking features are the following: the acute angle formed by the foreshortened manubrium mallei; the conspicuously prominent posterior fold; the undue prominence of the processus brevis of the malleus; and the unusual distinctness with which the long process of the ambos may be seen through the posterior and upper part of the tympanic membrane. (After Bürkner.)

(4.) In the fourth place, the fold itself, as the depression of the membrane advances, assumes more and more the character of a prominent horizontal ridge.

(5.) In the natural condition of the parts the processus brevis is a very inconspicuous and shallow spur, and the Rivinian recess is completely hid from view. (See Fig. 22.) The membrana flaccida, or Shrapnell's membrane, which fills this recess, presents no features that distinguish it from the neighboring cutaneous lining of the external auditory canal. But under the influence of excessive atmospheric pressure these soft parts are pushed into the recess—or, more probably, are absorbed—and then the outlines of the notch in the bone become visible. At the same time the processus brevis gains in prominence just in proportion as these soft parts are pushed away from its base. The rotation of the manubrium inward forces the processus brevis outward at the same time, and consequently aids in giving to this spur a greater degree of prominence. The development of a pit or fossa above the processus brevis and the marked increase in prominence of the latter constitute, therefore, the fifth distinguishing feature of a depressed drum-membrane. While this statement is, I believe, true for the great majority of cases, one may now and then see a case in which a markedly foreshortened manubrium mallei and an abnormal conspicuousness of the posterior fold or ridge are not associated with the slightest recognizable pitting of the mem-



FIG. 28. — Another View of a Sunken Membrana Tympani, showing a crescent-shaped depression in the lower and anterior part of the membrane. (After Bürkner.)

brana flaccida. I am not able to explain this unusual combination of conditions.

(6.) The shortening of the "bright spot" completes the list of alterations which may be considered as diagnostic of the condition which is here under discussion. It is such a rare thing to find a perfect "bright spot," even in ears which may fairly be classed as normal, that I never feel disposed to attach much importance to any shortening which it may display. On the other hand, when a well-marked annulus cartilagineus presents itself to view—which is not often the case—this sickle-shaped ledge serves to emphasize the depression of the neighboring less rigid portions of the membrana tympani. The bright spot, in such cases, is often reduced to a slender crescent lying close to and parallel with the annulus (Fig. 28).

There are certain exceptional cases in which the rules which I have laid down in the preceding paragraphs need to be somewhat modified. I refer to those cases in which the increased atmospheric pressure is brought to bear upon the membrana tympani at a time when its central support—the malleus—has become so rigidly anchylosed, from one cause or another, that it cannot rotate about its normal axis, and consequently cannot assume the different positions which I have enumerated as being specially characteristic of a depressed drum-membrane—*i.e.*, of an obstructed Eustachian tube. Broadly, I may say that the rules referred to above hold good for childhood, youth, and the earlier years of adult life. At this period, the mobility of the malleus is rarely impaired, and consequently the increased atmospheric pressure upon the outer surface of the membrana tympani meets with comparatively slight resistance, and the resulting displacement takes place in a more or less symmetrical fashion. Cases like this constitute the great majority, and the picture presented by the drum-membrane in these cases will be found to agree fairly well with that which I have attempted to draw. On the other hand, in the cases which are characterized by an immobile malleus, there will be no foreshortening of the manubrium, nor any diminution of the angle formed by the latter with the posterior fold. The processus brevis, however, will be more conspicuous than it normally is, but yet much less so than we usually find it in the other group of cases. In a word, the membranous portions of the drum-membrane will alone yield to the pressure, and in the higher degrees of the latter those parts of the membrane which lie close to the annulus tympanicus will present a sharp

degree of curving, and the "bright spot," in harmony with this condition of marked incurvation, will be seen as a long and slender crescent lying close to and parallel with the periphery of the membrane, as shown in Fig. 28.

Vascular new-growths are among the rarest pathological changes observed in the intact drum-membrane. In a young lady, twenty-two years of age, who consulted me for a slight general impairment of her hearing, I found in the posterior superior quadrant, just behind the short process of the hammer, and encroaching a little upon this bone, a small, rounded, bright-red, fleshy mass, about as large as a No. 12 shot (*i.e.*, about a millimetre or a millimetre and a half in diameter). It appeared to be quite soft, and was feebly movable when manipulated with the probe; at the same time it was not pedunculate. In a second case, that of a lady, sixty-five years of age, I found, in the central portion of the posterior superior quadrant of the left tympanic membrane, perhaps a trifle nearer the posterior fold than the manubrium mallei, and surrounded by a narrow zone of normal drum-membrane tissue, a dark object which stood out in bold relief from the outer surface of the membrana tympani. I manipulated this object with a slender silver probe, and in this way ascertained that it was sufficiently soft to yield to the pressure of the instrument, that it was shaped like a mole or a teat, that it measured about one millimetre in diameter at its base, and projected a distance of at least one millimetre from the plane of the surrounding membrane, that it was not noticeably sensitive, and that the transition from the black of the tumor to the grayish-white of the healthy drum-membrane was abrupt.

In the right ear I found a similar vascular new-growth in almost precisely the same region of the tympanic membrane. It was smaller, however, than that of the left ear. While the latter represented a perfect vascular mole, of diminutive proportions, the former consisted simply of a low, hemispherical eminence, recognizable more by its dark color than by any change which it caused in the configuration of the drum-membrane.

The complete *absence of the malleus* from an otherwise perfect membrana tympani may always safely be attributed to the fact that it has previously been removed by surgical means. In the first case of this kind which came under my observation (about twenty years ago), I was surprised to see how perfectly the gap left by the removal of the manubrium mallei had been healed over. Four years had elapsed since the operation had been performed, and by that

time the area in question looked and felt exactly like the surrounding original portions of the membrane.

In a case which I saw at the New York Eye and Ear Infirmary, in 1872, the patient, a boy thirteen years of age, presented the extraordinary anomaly of a *hook-shaped manubrium mallei*. He had, in early childhood, passed through an attack of scarlet fever, which left him with a discharge from both ears. That from the left ear had ceased entirely about one year previously. On examination of this ear I found the lower part of the manubrium curved from behind forward in the manner shown in the accompanying cut (Fig. 29). The membrane itself was opaque and somewhat mottled, but it presented no traces of ever having been perforated. There was also nothing to indicate that a fracture had ever occurred. On the opposite side the drum-membrane and handle of the hammer had been entirely destroyed, so that it was no longer possible to institute a comparison between the two ears. The boy was in robust health, and presented no evidences of ever having had rickets. The inference is that the anomaly in question must have been of congenital origin.



FIG. 29.—Hook-shaped Manubrium Mallei.

A somewhat similar case has been reported by Buhl and Hubrich in the *Monatsschrift für Ohrenheilkunde*, II., 1, January, 1868.

Dr. B. Alexander Randall, of Philadelphia, has reported a very unusual case of *horny growth* from the upper part of the drum-membrane, and through his kindness I am permitted to reproduce the illustration of the tumor (Fig. 30) in this place.

FIG. 30.—A blackish conical mass, looking like cerumen, lay in front of the right drum-membrane, with its outer part touching the anterior wall of the meatus. When seized with the forceps it was found to be attached to the short process, but was removed by slight torsion and traction. It proved to be a cuticular horn, 6 mm. long and 2 mm. in diameter, composed of cap-like layers arising from the short process. No reaction or recurrence followed its removal. (Copied from Randall.)

What are called *cicatrices or cicatricial spots* in the membrana tympani represent tissues which have been reproduced for the purpose of replacing those which have been destroyed. In this sense, therefore, they are identical with the cicatrices observed elsewhere upon the surface of the body, and the use of the term is perfectly

justified; but as regards the appearance which they present to the eye of the observer, the two are quite different. The cicatrix of the membrana tympani is simply—so far as its physical characteristics go—a well-defined area of atrophied drum-membrane. There is an entire lack of anything like what is called, in healed wounds of the skin, "cicatricial tissue."

It often happens that a cicatrix, under the influence of increased atmospheric pressure from without (due to an obstructed Eustachian tube), forms a well-marked diverticulum, which projects inward until it comes to rest against the mucous membrane of the promontory. When one examines a drum-membrane in which this condition of the parts exists, the first impression will be that there is an open perforation, leading directly into the tympanic cavity. It is only after the middle ear has been inflated that the true condition of the parts becomes manifest. The sunken cicatrix, under the influence of the inflation, becomes a thin, distended elastic bag upon the outer surface of the drum-membrane. In a very short time, however, it returns to its original resting-place against the promontory.

The amount of substantia propria which is reproduced in these cicatrices seems to vary a good deal. In the smaller ones enough of this tissue is frequently reproduced to prevent the cicatrix from stretching out into a bag or diverticulum when air is forced into the middle ear by means of a Politzer's bag. In the larger ones, however, newly reproduced substantia propria seems to be almost entirely lacking, and there is a corresponding elasticity of the cicatrix.

So far as size is concerned, this may vary from an area no larger than the head of a pin to one which corresponds to nearly the full dimensions of the membrana tympani.

Adhesions.—As a result of inflammatory action the drum-membrane may become attached, at one or more isolated points, or even throughout a large part of its area, to the opposite inner wall of the tympanum or to the ambos or stapes. Under simple inspection it may not be possible to determine the fact that such adhesions exist, but when the membrane is sucked outward by the apparatus known as *Siegle's tympanoscope or pneumatic ear speculum*, the adherent parts will remain unmoved, while those which are free will come forward under the influence of the suction. Through the glass diaphragm, which is set in the mouth of the speculum at an angle which does not permit the formation of an image by reflection, one

may watch the behavior of the drum-membrane under these varying conditions, and in this way readily detect the exact points at which such adhesions exist.

Habitual distention of the membrana tympani in an outward direction is an abnormal condition which is occasionally encountered. Its significance is this: it indicates that air finds its way quite readily from the vault of the pharynx through the Eustachian tube into the middle ear, but that in some way the escape of this air back into the pharynx is hindered. The result of this condition of affairs

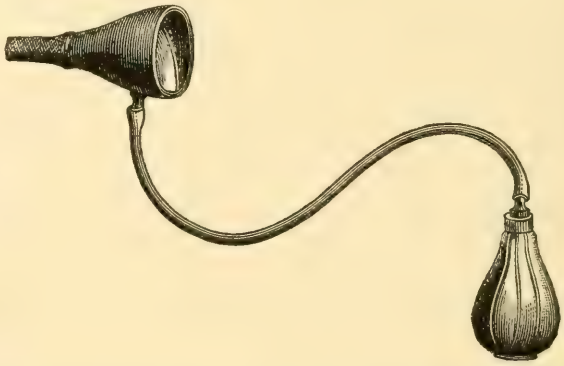

FIG. 31.—Siegle's Pneumatic Ear Speculum. (The speculum is reduced to about ⅔ and the rubber bag to ¼ the natural size.) (After Politzer.) (Many persons prefer to dispense with the rubber bag altogether. In that case the free end of the connecting piece of rubber tubing is held by the observer in his mouth, and the required exhaustion of the air in the air-tight speculum is effected by suction.)

is that an excess of air is habitually imprisoned in the middle ear, and that consequently the membrana tympani is in a constant state of distention. (See Fig. 25.)

My impression is that a swollen condition of the soft parts constituting the tympanic orifice of the Eustachian tube will best explain this peculiar pathological phenomenon. One way of testing the correctness of this view would be to make a fairly large paracentesis opening in the anterior half of the membrane, and then to examine the actual condition of the tubal orifice and surroundings. If this region should be found in a swollen and congested condition, it would be well to apply to it a two-per-cent. silver nitrate solution. In the very few cases of this nature which have come under my observation I have limited my interference to an occasional mopping of the vault of the pharynx with this solution, in the hope of thus indirectly effecting a diminution of the swelling and congestion at

the tympanic end of the tube; and the results obtained have fairly justified the course adopted.

Perforations are among the commonest pathological lesions observed in the membrana tympani. They are usually circular or ovoidal in shape, and it is rare to find more than one in the same drum-membrane. The existence of such a defect in this membrane furnishes unmistakable evidence of the fact that a destructive disease has been at work in the corresponding middle ear, but there is nothing in the appearance, size, shape, or location of the perforation which can surely enlighten us in regard to the nature of the disease which has wrought the damage. In making this statement I exclude those perforations which are of traumatic origin, and whose irregular shape usually suggests at once the thought that ulcerative disease has had nothing to do with their formation.

Ruptures of the membrana tympani will be discussed further on, in a separate chapter devoted to traumatic affections of the ear.

The development of a *cyst-like tumor* upon the outer aspect of the drum-membrane is a comparatively rare lesion. As a matter of course, I exclude from consideration here those cyst-like distentions of the epidermis which are of such common occurrence in the acute stage of an inflammation of the middle ear, and to which I have already referred in the early part of this chapter. These pass away quickly and leave no trace of their recent existence. The more permanent type of cyst, on the other hand, is in reality nothing more nor less than an atrophic or cicatricial portion of the drum-membrane —usually, I suspect, the latter—which is distended by a mucoid or sero-mucoid mass of secretion in the middle ear. The proper treatment is to be found in the restoration of the vault of the pharynx and neighboring nasal cavities to a state of health.

Granulation tissue must certainly be classed among the lesions which are rarely observed upon an intact membrana tympani. So far as I am able to recollect, I have seen it in only two localities, viz., in the vicinity of Shrapnell's membrane and on the posterior half of the membrana vibrans. In the first of these localities it has appeared in the form of a well-defined mass which could be removed with the wire loop. In a few instances I have found it to be large enough to hang down in the form of a pendulous polypus. It is only by a most careful exploration of the area involved, by testing the hearing, and by investigating the previous history of the affected

ear, that we can distinguish these cases from those in which the granulations simply stand at the entrance to a sinus leading into the deeper parts of the middle ear, and owe their development to an irritating discharge from the latter region. It is not always possible to determine with any degree of sureness why granulation tissue should develop in the vicinity of the processus brevis of the malleus in a case of intact membrana tympani. Sometimes the assumption appears to be warranted that prolonged pressure from a hard, scab-like formation has supplied the necessary irritation. In a few cases the previous history justifies us in assuming that the growth of granulation tissue owed its origin, in the first place, to an acute inflammation of the middle ear, with which was associated more or less osteitis in the vicinity of the membrana flaccida. But at the time when the granulation growth is discovered, both the localized osteitis and the inflammation of the middle ear may have entirely disappeared, thus compelling us to speculate as to how the new-growth came into existence.

The posterior half of the membrana vibrans is the only other part of the drum-membrane where I remember to have seen an independent granulating process of limited and well-defined area. The existence of eczematous patches on the neighboring wall of the external auditory canal points clearly in these cases to the nature of the alterations observed on the drum-membrane. The picture presented is very insignificant and may easily be overlooked. A very thin, scab-like film covers the granulating area, and gives to this part of the membrane the appearance of being simply roughened or thickened. When the film has been wiped away, a slightly red and succulent area appears underneath. A two- or three-per-cent. silver nitrate solution applied to the spot will reveal—what the eye might otherwise fail to appreciate—that an actual granulating process, on a minute scale, is going on at this place. In the higher grades of an eczematous inflammation of the external auditory canal, it is not unusual to find the entire drum-membrane, or the larger part of it, involved in the process, which under these circumstances generally falls short of reaching the granulating stage.

These eczematous lesions are, I believe, rightly esteemed to be manifestations of a general lithæmic or gouty condition; and it is not unlikely that in a few instances the granulations observed near the processus brevis of an intact drum-membrane are also the outcome of processes which are essentially gouty in their character.

Syphilitic and tubercular lesions of the membrana tympani rarely, if ever, occur in an isolated and independent fashion; as a rule, they are associated with other lesions affecting the mucous membrane of the middle ear. The few characteristics which they manifest will be discussed further on, in the chapter devoted to Syphilitic and Tubercular Affections of the Middle Ear.

CHAPTER V.

DISEASES OF THE AURICLE.

Eczema.—Among the children of the poorer classes, eczema of the auricle is an extremely frequent disease. If less frequent among the children of the well-to-do classes, it is certainly by no means a rare affection even among them. Again, in old age and in the middle period of life it is quite a common disease. In a certain percentage of the cases it develops on other portions of the skin at the same time, as, *e.g.*, on the hairy scalp or in the mastoid region. In children it is often associated with a conjunctivitis, and the coexistence of the two diseases suggests the probability that the irritating secretions of the auricle have been transferred by the child's fingers to the eyes.

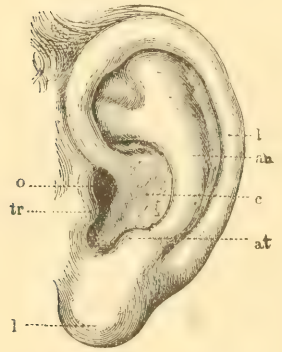

FIG. 32.—Auricle. *ah*, Antihelix; *at*, antitragus; *c*, concha (fossa conchæ); *h*, helix; *l*, lobule; *o*, orifice of external auditory canal; *tr*, tragus. The notch between the tragus and the antitragus is called the incisura intertragica. (After Politzer.)

In its mildest and simplest form, eczema of the auricle manifests itself as a reddening and infiltration of the skin at one or more points. The favorite places are those spots where the skin is folded upon itself, as the fossa helicis, and the angle behind the ear, where the skin is reflected from the auricle upon the mastoid process. The disease is observed at least equally often at the orifice of the external auditory canal, and extending from there forward over the tragus, and downward over the lobule—in other words, at points where there is apt to be a good deal of friction, or where an irritating discharge from the meatus may act as an exciting cause. At a later stage these reddened and infiltrated spots secrete a fluid which soon becomes inspissated, forming crusts or scabs. In many cases actual ulceration takes place beneath the scabs; and this is par-

ticularly apt to occur in the incisura intertragica, in the fossa helicis (see Fig. 32), and in the angle behind the ear. In exceptional cases the entire auricle and immediate surroundings present an almost continuous mass of scabs.

In another group of cases, a desquamative process, confined to certain portions of the auricle, seems to constitute the most characteristic, if not the only, manifestation of the disease. The intervening portions of the skin appear to be perfectly healthy, and even those parts which are desquamating or are covered with scab-like formations often present a pale and uninflamed appearance. The term chronic eczema is usually applied to this class of cases, but it may be applied with equal justice to almost all cases of eczema of the ear in adults.

The prognosis of the disease is good. In the majority of cases we may confidently expect to restore the auricle to an apparently natural condition in a short time. In children, particularly, we may look for a very prompt clearing up of the affected skin, and the cure is likely to prove permanent. In persons past middle life it is well to give a more guarded prognosis; for although we may succeed in promptly restoring the part to a seemingly healthy condition, a relapse is almost sure to come, and that, too, at an early day. The gouty or lithæmic state is the real disease in these cases, and not this limited area of inflammation of the ear. Hence the temporary character of the effects produced by local treatment. When a well-marked gouty attack involves the fingers or toes, a spontaneous and sometimes very striking subsidence of the eczema of the ear is observed. A vigorous purge will also at times produce the same beneficial effects. Every now and then in the course of a chronic eczema, the auricle passes through an attack of what appears to the observer to be erysipelas. The organ becomes uniformly red, swells up to two or three times its natural size, pits on pressure, and is painful to the touch. Gradually the redness and swelling disappear, and the auricle, in the course of four or five days, returns to its former state. Whether these attacks, which recur repeatedly in certain cases—sometimes as often as twice in the course of a month—are really erysipelatous in character or simply represent a diffuse acute exacerbation of the eczema, I am unable to say. As the inflammation does not extend beyond the auricle and external auditory canal, it would seem more proper to look upon it as non-erysipelatous in character.

Treatment.—Careful inquiry should be made, first into the

character of the patient's diet, and then into that of his habits with regard to bathing and outdoor exercise. In children, a complete and permanent cure may often be attained by simply restricting the diet to such articles as milk, oatmeal, hominy, fresh meat and vegetables, and light bread. Pastry, pies, cakes, salt meat and pork, tea and coffee must be rigidly excluded. In adults, it will generally be found easier to induce the patient to take an adequate amount of exercise in the open air, than to persuade him into excluding certain articles of food from his daily fare. If possible, he should be induced to do both.

Local applications form a very important part of the treatment of eczema of the auricle. In the acute stage, if there happen to be pain and tenderness, it may be desirable (though only in adults) to apply leeches (or, better still, Bacon's artificial leech) for the purpose of allaying the pain and diminishing the inflammation. It is rare, however, that local blood-letting seems to be required in these acute cases. If it be resorted to, the region immediately in front of the tragus and that directly behind the auricle are the spots which should be selected. Cloths dipped in some cooling and astringent lotion, such as the lead and opium wash, or in simple water to which alcohol or *eau de cologne* may be added in varying proportions, will generally be found sufficient to allay all the acute symptoms. Afterward, if no crusts have formed in the mean time, we may apply some oleaginous preparation directly to the affected skin. If crusts have already formed, these must first be removed by the aid of soap and hot water; and if the skin is actually ulcerated, I am in the habit of cauterizing such ulcers lightly with nitrate of silver in the form of a bead fused upon the end of a probe or a steel cotton-carrier.

Cleansing the inflamed parts constitutes an important feature in the treatment of eczema of the auricle. About twice a day a lather of Castile soap should be applied with a camel's-hair brush. Then this should be washed off gently with tepid water; and finally, after the skin has been cautiously dried—the minimum amount of friction being used—some suitable oleaginous preparation should be thoroughly applied.

The chief value of the different oleaginous preparations lies, I imagine, in their power to exclude the air from the parts affected, rather than in the medicinal virtues of the drugs which enter into the composition. In the place of simple vaseline, a mixture of boric acid and vaseline (boric acid, 10 grains; vaseline, 1 drachm) may

be employed. By the addition of lanolin in any desired proportion, this bland ointment may be given a greater degree of consistency and adhesiveness.

Of the lead preparations, I have used only one, viz., Hebra's diachylon ointment. The formula for this ointment, as prepared in Vienna, is (according to Gruber)[1] the following:

℞ Olei olivarum optimi . . . . . ℥ xv.
Lithargyri . . . . . ℥ iij. et ʒ vi.
Coq. l. a. in unguentum molle, dein adde:
Olei lavand. . . . . ʒ ij.
M. Ft. unguentum.

The benzoated oxide of zinc ointment is a favorite remedy with many physicians. I have used it a great deal in children, and have been in the main well satisfied with the results. My chief objection to it lies in the fact that it clings to the skin with such tenacity that it is often a very troublesome matter to remove it after it has once been applied.

The resinol ointment—a preparation manufactured by the Resinol Company, of Baltimore, Md.—serves a good purpose in eczema of the external auditory canal, and would probably be found equally serviceable in the treatment of eczema of the auricle. Thus far, however, I have not had an opportunity of testing its use in the latter region.

Finally, in a certain proportion of the thoroughly chronic cases, in which all the ordinary preparations seem to have been powerless to effect even an amelioration of the unsightly condition of the ear, decided good may be accomplished by painting the diseased parts thoroughly (after all oily substances have been removed), from time to time, with acetum cantharidis (British Phar.).

It is a common mistake to stop using the local applications as soon as the ear appears to have regained its natural condition. It will be found safer to continue the treatment faithfully for at least a week or ten days after a cure has apparently been effected.

Simple diffuse inflammation of the entire auricle is observed in its purest type in cases in which hot poultices have been used to excess. After the auricle has been exposed for a certain length of time to the combined effects of the heat and the moisture, it becomes highly congested and slightly tender to the touch. The

[1] "Ueber Eczem am äusseren Ohrtheile." Monatsch. f. Ohrenheilk., Nov., 1867.

appearance of the organ is precisely the same as if it were affected with acute erysipelas. If the exposure is kept up for a still greater length of time, the auricle becomes quite painful and very much swollen. Abscesses, I am told, may even form at different points. As already stated in the earlier part of this chapter, such a general inflammation of the auricle may develop in the course of an eczema, and I have occasionally seen it develop in connection with a circumscribed inflammation of the outer portion of the external auditory canal. In these cases, however, it was not quite clear whether the diffuse inflammation of the auricle was to be interpreted as an actual extension of the more localized process in the meatus, or as the result of the application of hot poultices. Cooling applications and the removal of the exciting cause usually suffice to relieve the inflammation.

Hæmatoma Auris; Perichondritis. (Othæmatoma; Chondromalacia; Chondromalacosis.)—These conditions are so closely allied to each other that it is better, I believe, to consider them together in one section. The term hæmatoma auris, or othæmatoma, is usually applied to a peculiar swelling of the auricle, which is most frequently observed in the insane, and which is chiefly due to the escape of a varying quantity of blood either between the cartilage and the perichondrium, or into the substance of the cartilage. The term perichondritis is restricted to those cases in which the symptoms of redness, pain (usually slight), and slowly increasing swelling point very decidedly to processes that are chiefly inflammatory in their nature. With othæmatoma of the insane I have had no practical experience whatever, and must base my remarks wholly upon information gained through reading; with perichondritis I have also had very little experience, as the disease is comparatively rare. I am persuaded, however, that no sharp dividing-line can be drawn between the two classes of cases, whether considered from an etiological, a pathological, or a therapeutical stand-point.

Exposure to severe cold or extreme heat produces an inflammation to which the term perichondritis may fairly be applied. Violence may also produce the same pathological manifestations. Finally, in a few cases, no exciting cause can be discovered; the disease is then said to be idiopathic. In these cases the patients are generally found to be in a poor state of nutrition, and, in the absence of any other adequate cause, we are almost compelled to assume that some local nutritive disturbances—probably of the same nature as those which are now generally admitted to be the chief

factors in the production of the typical othæmatoma—have given rise to the perichondritis.

The pathology of othæmatoma proper has for many years past been a fruitful subject for discussion. Some advocate the doctrine that this lesion is peculiar to the insane, and depends upon a pathological condition of the brain. This is the view taken by the late Dr. Hun,[1] of Albany, who has written a very interesting paper on the subject of hæmatoma auris. Others maintain that the lesion is always produced by violence, and that it occurs more frequently among the insane, simply because they are peculiarly liable to violence. Finally, a third party maintains that the othæmatoma is not one of the pathological lesions of insanity, but that the surroundings of the insane and the debilitated condition which so generally accompanies insanity are the real reasons for its so frequent occurrence among that class of individuals. This is the view taken by Virchow in his treatise on tumors, and the exhaustive researches of Ludwig Meyer,[2] Pareidt,[3] Gudden,[4] Pollak,[5] and Haupt,[6] confirm it in the strongest possible manner. The essential facts developed by these investigations are the following:

First, degenerative changes are quite uniformly found in the cartilaginous framework of the auricle in cases of othæmatoma of the insane. These changes are of such a nature that Pareidt very properly termed the disease a *chondromalacia*,[7] or softening of the cartilage. The progress of the affection is described by Ludwig Meyer essentially as follows: Hæmatoma auris begins as a degeneration and softening of the cartilage at one or more spots. A gelatinous material takes the place of the hard cartilage. As the degenerative process goes on, newly formed blood-vessels shoot out from

[1] American Journal of Insanity, July, 1870.

[2] Virchow's Archiv f. path. Anat., etc., Bd. xxxiii., Heft 4, 1865.

[3] "De Chondromalacia," etc. Dissertatio Inauguralis, Halle, 1864.

[4] "Ueber den Mikroskopischen Befund in traumatisch gesprengten Ohrknorpel." Virchow's Archiv f. path. Anat., Bd. li., 4, p. 157; lii., 2, p. 303.

[5] Monatsschrift für Ohrenheilkunde, Berlin, July, 1879. (Reviewed in vol. i., No. 4, of the American Journal of Otology.)

[6] Gustav Haupt: "Ueber das Othæmatom." Dissert. Inaugur., Würzburg, 1867. Reviewed in A. f. O., vol. iv., p. 143. (Marked changes found in the cartilage of the apparently healthy ear of an insane person whose other ear had been the seat of a well-marked othæmatoma.)

[7] Loosely used in the sense of chondromalacosis, which means a *softening* of the cartilage. According to Kraus ("Kritisch-etymologisches medicinisches Lexicon," Göttingen, 1844), the term chondromalacia means simply a *softness* of the cartilage.

the perichondrium, or from the vessels that pierce the cartilage at different points, into these softened spots. The newly formed capillary vessels are quite large, and their walls are very thin and richly supplied with nuclei. Thus we have two different processes going on, side by side, at the same time—a softening of the cartilage, and a granulation process on the part of the perichondrium.

In the second place, a careful macroscopical and microscopical examination of a large number of ears, taken from patients who had died from all sorts of diseases in the hospitals, but who had never manifested any symptoms of insanity, reveals the fact that precisely the same changes as those just described take place in the auricles of the mentally sane. According to the statement of Pollak, whose researches are among the most recent, small nodules, varying in size from a mustard-seed to a lentil, are occasionally found in the cartilaginous portion of the external meatus, and especially in the anthelix. In these, when cut open, it is easy to detect, even with the naked eye, a departure from the normal condition of the reticular cartilage; in some cases, in fact, it will be found that a distinct cavity has already formed. Microscopic examination also revelas spots where the cartilage has broken down into a mass of granules, and others where evidences of new growth of tissue are distinctly recognizable.

In the third place, the number of instances of the occurrence of fully developed othæmatomata in persons who are perfectly free from any mental disorder whatever, is constantly increasing.

These facts justify the belief that insane persons are more liable to the disease under consideration, simply because malnutrition reaches a higher grade among them (taken as a class) than among the mentally sound. The new growth of unusually large and thin-walled capillary blood-vessels also furnishes an explanation of one of the most striking phenomena of othæmatomata, viz., the escape of a comparatively large amount of blood, either between the perichondrium and the cartilage, or into the substance of the cartilage. It can readily be understood how a very trifling exciting cause, such as a slight blow, the pressure of a hard pillow, or even the reflex congestion following some mental emotion, may lead to the rupture of one or more of these delicate vessels and produce the characteristic accumulation of blood.

External Appearances.—In a case of well-advanced perichondritis the alterations produced in the external appearance of the auricle are very striking. Where the skin is not stretched by an

abundant exudation of fluid between it and the cartilaginous framework, the surface will be uneven—broken up into furrows and doughy-looking hummocks, as shown in Fig. 34. Sometimes this uneven surface persists even after the skin has been distended by fluid exudation. The color varies. Generally the skin is livid red, or at times even a dark purple.

Course of the Disease in the Mentally Sane.—It rarely happens that the physician has an opportunity of seeing a case of idiopathic

FIG. 33.—Hæmatoma of Upper Part of Auricle. (After Bürkner.)

FIG. 34.—General Perichondritis of the Auricle, with areas of destructive chondromalacosis, resulting in marked diminution in size of the entire organ. (After Benni, in *Comptes Rendus du Troisième Congrés International d'Otologie ;* Bâle, 1885.)

perichondritis in its incipient stage. The patient generally waits until the discomfort or pain is sufficiently great to make him feel the need of medical aid, and usually by that time the disease has reached its highest stage of development. The following case is a good example of an idiopathic perichondritis of a comparatively mild type:

CASE I.—Female, thirty years of age, saleswoman in a retail shop, and in decidedly poor general condition. She presented herself at the New York Eye and Ear Infirmary, on the 1st of November, 1878, and gave the following history: About ten days ago she first noticed some irritation at the upper part of the right auricle, not far from the helix. She had not received any injury at this point, nor could she think of any other cause for the development of the soreness in that particular place. In the course of a few days, a circum-

scribed swelling developed at this spot, and she then consulted her family physician. He made two small incisions into the swelling, one at the upper, the other at the lower limit of the tumor, evacuated the fluid contents, and then passed a seton into one opening and out through the other. After this, the auricle swelled up rapidly and became very painful. At the time of her visit to the Infirmary, the tumor was fully as large as a butternut. It presented a smooth, red, and inflamed appearance, and occupied the anterior aspect of the upper two-thirds of the auricle. There was also some œdema of the skin above and behind the ear. The seton was still in place, and on removing it a thin fluid spurted out from one of the openings. By aid of the probe it was ascertained that a large cavity existed, the posterior wall of which seemed to be formed by the denuded anterior surface of the cartilage. The two openings were converted into one by an incision, the cavity was carefully cleansed, and a tent was introduced to prevent the edges of the wound from uniting. When the contents of the cavity were evacuated, it was observed that the larger part consisted of a thick, almost gelatinous material, while the smaller part was apparently a thin serum. The patient was ordered to take twenty drops of the muriated tincture of iron three times a day, and to lay cloths wet with the lead and opium wash upon the inflamed auricle.

On the second day of November she visited my office, and reported that the pain had very markedly abated. I removed the tent, and in so doing afforded escape to a moderate amount of thick pus and some thin, serous fluid. The parts surrounding the cavity were found to be still very much swollen. From the uniform smoothness of the posterior wall of the cavity it was inferred that no destruction of cartilage had taken place, and that the disease was, strictly speaking, a perichondritis, with effusion between the cartilage and the perichondrium. From this time forward the patient was visited regularly by my colleague, Dr. George B. Hickok. The cavity was daily cleansed, and then mopped out with tincture of iodine; afterward, moderate pressure was applied, for the purpose of keeping the walls of the cavity in close apposition. Two short and flat bits of wood were employed for this purpose, one being placed behind, the other in front of the swelling, and rubber bands being used to exert the requisite pressure. The localization of the pressure was secured by interposing suitable pads of sheet lint between the skin and the bits of wood. In less than three weeks the cavity had completely healed, and the auricle had so nearly returned to its natural condition that there could no longer be any reasonable doubt about the speedy disappearance of all traces of the disease.

Chimani[1] reports an equally typical case of idiopathic perichondritis, which occurred in a young man, twenty-three years of age. The swelling was incised, and complete recovery took place in a little more than four weeks, without any deformity. Wendt[2] reports a similar instance of the development of a "spontaneous hæmatoma" in a strong and perfectly healthy young man, twenty

[1] Archiv für Ohrenheilkunde, Bd. ii., S. 169.
[2] *Ibid.*, Bd. iii., S. 29.

years of age. Brunner[1] also reports a similar occurrence in a perfectly healthy individual, twenty-two years of age. In this case, however, it is quite probable that the cartilage was primarily diseased, as a certain degree of deformity remained after the parts had healed. Furthermore, the patient had already a few years previously experienced a similar inflammation of the other auricle, and an examination revealed the fact that some deformity still remained at the seat of this former attack.

In a second case which came under my observation, almost precisely the same conditions were presented as in the one narrated above. The same plan of treatment was followed, and after the parts had healed scarcely any traces of the disease could be discovered. The two cases, however, differed from each other in the following particulars: a frost-bite was clearly the exciting cause in the latter instance; and, furthermore, the contents of the sac were sufficiently bloody to communicate a bluish tint to the outside of the tumor. As no notes were kept of this case, I cannot say positively whether the fluid contents of the sac were simply stained with the coloring matter of the blood, or whether solid clots were also found to be present.

Dr. Charles J. Kipp, of Newark, N. J., has reported[2] a somewhat similar case of perichondritis—or spurious othæmatoma, as he terms it—of both auricles, the result of a burn.

Case II.—"The auricles were pushed out from the head, and the upper two thirds of both were pear-shaped. The swelling was greatest at the top, and measured about an inch and a quarter from before backward. The auricles were hot and very sensitive to the touch. The surfaces of the swellings were convex and smooth, and the skin of normal color, but it looked as if it had been blistered. Fluctuation could be distinctly felt in both. An incision through the entire length of each swelling gave escape to a considerable quantity of a yellowish, glairy fluid. The swellings did not collapse after the evacuation of their contents. In each was found a cavity of about the size of a hickory-nut, lined by a smooth, shining membrane. The anterior wall of each was about a line thick, and was apparently composed of thickened perichondrium; the posterior wall was formed by the cartilage. Under the daily application of tincture of iodine to the interior and exterior of the swellings, the auricles gradually diminished in thickness, and at the end of two months they had regained their normal size and shape. The only deformity remaining when I last saw him was a wrinkled condition of the fossa helicis." (Dr. Kipp.)

Finally, in a third case which came under my observation, the

[1] Archiv für Ohrenheilkunde, Bd. v., S. 26.

[2] Transactions of the American Otological Society for the year 1873.

conditions found were essentially different from those observed in the two preceding cases.

Case III.—The patient, a man thirty years of age, and in robust health, consulted me on the 11th of December, 1878. He stated that four years previously both of his ears had been frost-bitten, and that from that time to the present he had had four sores on the left ear and two on the right, as the results of the acute inflammation which immediately followed the freezing of the parts. All efforts to make these ulcers heal permanently had failed, although during the summer season some of them would present all the appearances of having spontaneously healed. As soon as cold weather returned, however, these spots again became scabbed over. Upon examination, I found four spots on the left auricle and two on the right, occupied by scabs of moderate thickness. They were nearly circular in shape, and measured from five to eight millimetres in diameter. Five out of the six scabs were located on the outer aspect of the helix, above the level of the orifice of the external auditory canal; the sixth was located on the anthelix, on the same level with the external orifice. The edges of the scabs seemed to rest upon healthy skin. After they had been removed, it was ascertained that they each covered an ulcer with sharply defined and undermined edges. The bottom of each ulcer was smooth, hard, and of a pale color. The undermined edges had a markedly bluish hue, which faded gradually into that of the perfectly sound skin.

Nitrate of silver, tincture of iodine, and pure nitric acid were tried in succession, at brief intervals, but none of these reagents seemed to induce the slightest evidence of a healthy reparative process. I then tried the following plan: with a pair of curved and slender-pointed scissors I cut away the bluish undermined edges; then, as soon as the bleeding had ceased, I applied compound tincture of iodine freely to the base of the ulcer, and to the surrounding raw surface. A very thin layer of cotton-wool was next laid upon the exposed surface, and then liquid collodion was applied for the purpose of supplying an artificial scab. At the end of three or four days the collodion and cotton were removed, and the ulcer was found to be healing slowly both from the edges and from the bottom. The compound tincture was applied a second time and the wound was sealed up again with cotton and collodion. Nine such applications in all were made during the latter part of December, and on the second day of January I found the newly formed skin firm and dry over the spot which before had been the seat of the ulcer. The depression of the surface at this point was too slight to attract attention.

The remaining ulcers were treated in much the same manner as the first one, and with equally good results.

In the cases described above it is reasonably safe to assume that the cartilage itself was either not at all involved, or, at most, only very superficially. The term perichondritis seems therefore more appropriate for this class of cases than either of the other expressions—othæmatoma and hæmatoma auris. It would be better if we could abandon the use of these two terms altogether and employ some term which indicated the essential nature of the disease, and

not merely one of its comparatively unimportant manifestations—the escape of blood into the tissues. Pareidt's *chondromalacia* (or the correct expression, *chondromalacosis*) is certainly the best term that has thus far been proposed. I hesitate, though, to urge the abandonment of terms to which we have all been habituated for so long a time.

I have already said that this chondromalacosis is occasionally observed among the mentally sane. Through the courtesy of Dr. Oren D. Pomeroy, of this city, I once had the opportunity of seeing a very marked instance of this disease.[1]

Dr. Pomeroy's Case.

Case IV.—The patient, a cooper, forty-two years of age, and of perfectly sound mind, gave the following history: In the early part of May, 1874, he experienced a violent pain in the right ear, which continued for eleven days, with very little abatement. A discharge of thick, creamy pus then made its appearance in the external auditory canal. Five days after the discharge began, he presented himself at the Brooklyn Eye and Ear Hospital. Owing to the swollen condition of the canal it was not found possible at that time to determine satisfactorily whether the disease had commenced in that region or in the middle ear. In the course of a few days the swelling extended outward from the canal, and involved the auricle, causing it to become very much thickened. An incision made in the swelling gave exit only to a thin, serous fluid. An opening in front of the meatus and just below the tragus afterward formed, and from this came a discharge which was more purulent in character. On the 1st of September, when Dr. Pomeroy first saw the patient, a large abscess occupied the region of the fossa conchæ, and extended upward, downward, and backward, involving at least half the area of the auricle. In front of the meatus, near the tragus, was a circumscribed swelling, with a fistulous opening in its apex. The large tumor was somewhat nodulated, but fluctuation was easily recognized throughout, both in front and behind. An incision was made posteriorly, where the wall of the abscess was very thin, and a large quantity of pus (about five drachms) was evacuated. On exploration with the finger, it was found that the cavity of the abscess was bounded, both in front and behind, by integument and connective tissue only, the cartilage having entirely disappeared from the region involved. At subsequent times small abscesses made their appearance in other localities, viz.: in the region of the lobule, three; in the tragus, one; in the upper portion of the helix, two. The larger cavity closed in three weeks without special treatment, beyond a thorough daily cleansing with tepid water. The discharge from the abscess in the helix was somewhat glairy in character. Early in November the last abscess healed, and the auricle then presented the deformed appearance shown in the cut accompanying the published report of the case.

[1] This case is reported in detail in the Transactions of the American Otological Society for the year 1875.

This case, when studied in the light of Meyer's and Pollak's investigations, adds strength, it seems to me, to the theory that othæmatomata owe their origin primarily to a softening of the cartilage in spots. An intercurrent acute inflammation of the skin, or of the perichondrium at some one spot, may be required to fan these smouldering fires into a rapidly destructive conflagration, such as that observed in the present instance; but, without the predisposition supplied by the existence of several centres of softening in different parts of the cartilage, it is difficult to understand how an inflammation beginning in the middle ear or external auditory canal, and extending to the auricle, should result in such serious damage to the cartilaginous framework.

Wendt[1] under the heading, "A Case of Subacute Inflammation of the Cellular Tissue of the Auricle," describes a case which corresponds in all essential particulars with the one just narrated. With this exception, I can find no other case on record in which the extent of the destruction of the cartilage and the degree of the deformity resulting therefrom were so great as in Dr. Pomeroy's case.[2]

Diagnosis.—Perichondritis of the auricle presents, in its acute stage, such salient features that no physician would be likely to mistake it for any other form of disease. The conditions presented are practically those of an abscess, generally of large size; but the abscess has peculiar anatomical relations, and its contents are usually different from those of an ordinary abscess. Thus, we find, after an incision has been made, that the cartilage forms one wall of the abscess, and the perichondrium the other. We also find that the contents of this abscess are composed, not of thick, healthy pus, such as is usually found in acutely formed abscesses, but of a glairy yellowish fluid, or of a bloody serum, or partly of thick pus and partly of thin, yellowish serum. From the external appearance alone it is impossible to decide whether the abscess owes its origin to a burn, to a frost-bite, to a blow upon the ear, or to nutritive changes in the cartilage or perichondrium.

If, in addition to the perichondritis, softening processes are going on in the subjacent cartilage, the combined destructive and

[1] Archiv für Ohrenheilkunde, Bd. iii., S. 30.

[2] In the Archiv für Ohrenheilkunde I find the reports of three cases of othæmatoma in mentally sound persons, viz.: one by Schwartze (Arch. f. Ohrenh., Bd. ii., S. 213), in which a blow upon the ear was the exciting cause; and two by Brunner (*op. cit.*, Bd. v., S. 26), in one of which a frost-bite was the exciting cause.

proliferative changes may give to the auricle such a knobbed and distorted appearance as to suggest the presence of cancer. In Dr. Pomeroy's case I frankly confess that I leaned more toward the diagnosis of epithelioma of the auricle than toward that of a chronic inflammation of the perichondrium. I had under my care, a short time previously, a well-marked case of epithelioma of the auricle, and the outward resemblance between that case and the one I have just referred to was so strong that I could not help being struck with it. Besides, I had never before seen a case of chondromalacosis, and was not aware that it could produce such extensive destruction of the cartilage in one part of the ear, and such marked hypertrophy of the perichondrium in another. On closer examination, however, an appreciable difference between the two conditions can be made out even with the naked eye. In cancer, for instance, the skin will be found to have lost its suppleness, and to be rough and uneven on its surface; while in chondromalacosis the skin is either smooth, or is capable of being made smooth by stretching, and it can readily be shown that the unevenness of surface is due to the unevenness of the subjacent parts rather than to any changes in the skin itself. As a matter of course, a microscopic examination of the suspected tissues would set at rest all doubts about the correctness or incorrectness of the diagnosis.

Prognosis.—The prognosis in this class of cases has reference simply to the degree of deformity which is likely to result from the disease. In simple perichondritis the prognosis is good. If the abscess is opened early and freely, very little, if any, deformity will be left after the parts have healed. In chondromalacosis the degree of permanent deformity will depend chiefly upon the extent of cartilage destroyed, and only to a slight degree upon the inflammatory thickening of the perichondrium.

Treatment.—Cases of perichondritis or of chondromalacosis of the auricle rarely come into the physician's hands until a distinct cavity, with fluid contents, has formed. The most urgent indication in this stage of the disease is to relieve the tension and prevent further separation of the perichondrium from the cartilage. This can best be accomplished by making an incision into the swelling; not a small one, which will allow only the fluid portions of the contents to escape, but a liberal one, that will afford ample room for the thorough daily cleansing of the cavity. If the cartilage seems to be in a healthy condition, we may begin at once, on the day following the incision, to bring moderate pressure to bear upon the

separated cartilage and perichondrium, in the hope of thus hastening their union by adhesion. For this purpose Dr. Hickok's contrivance, described on a previous page, will be found very useful; or two pads may be adjusted, one in front of and the other behind the auricle, and a bandage may then be passed over the top of the head and under the chin, in such a manner as to keep the pads in position and exert moderate pressure upon the walls of the cavity. In addition to the daily cleansing of the cavity with a tepid bichloride solution, and the readjustment of the pads and bandage, it is doubtful whether we can do anything that will materially hasten the process of healing. My own preferences would lead me to mop out the cavity with tincture of iodine after each cleansing, but I cannot say positively that this procedure materially hastens recovery. Instead of the simple tincture, the compound tincture of iodine may perhaps be used with equal advantage. In cases of chondromalacosis it would probably be better to omit making pressure until we are confident that the processes of softening have come to an end. If new collections of fluid form in other parts of the auricle, these must each be treated separately, in exactly the same manner as the original collection.

Probably, in a majority of these cases, it will be found desirable to prescribe quinine, iron, cod-liver oil, and a more liberal diet. It is unnecessary, however, for me to enter any more fully into this aspect of the subject.

New-Growths.—*Fibroid tumors* of the auricle are observed quite frequently among negresses, and occasionally among white women, as a result of the operation of piercing the lobule, or of the irritation caused by wearing an ear-ring. Through the kindness of my colleagues I have had the opportunity of examining two or three cases of this form of new-growth, but I have never had a case under my immediate care. The tendency to recur, after apparently complete extirpation with the knife, is perhaps the most interesting feature connected with these growths. In one of the cases referred to above, the extirpated tumor—the second or third return of the growth—was placed in my hands for microscopic examination. To my surprise, the most careful search failed to discover cellular elements in any part of the mass, which was as large as a hickory-nut and slightly lobulated in structure. The growth seemed to be made up entirely of fibrous tissue, which appeared under the microscope in the form of wavy bands.[1]

[1] Cases of fibroid tumor of the auricle have been reported by Bertolet (Trans. Amer. Otol. Soc., 1871), Clarence J. Blake (Arch. Ophth. and Otol.,

Next to the fibroma, *epithelioma* is probably the commonest form of new-growth observed in the auricle. The following is the only case of this nature that has come under my observation:

Case V.—The patient, a coachman, forty-three years of age, and otherwise in excellent health, presented himself at the Infirmary with an auricle which, at first sight, seemed to be affected with eczema. The large part of the upper half of the auricle presented, on its anterior aspect, an almost continuous mass of scabs. On the posterior surface there was also one moderately large scab. Between these crusts, and surrounding them, the skin presented a bright red and infiltrated appearance, with quite sharply defined limits at the points where it merged into the surrounding healthy skin. After the scabs had been removed, it was found that they covered quite deep ulcers. At one spot, corresponding to the location of the crust on the posterior aspect of the auricle, the cartilage was completely destroyed, and a mop of cotton-wool, at least four millimetres in diameter, could readily be passed through the opening from one side to the other. The orifice of the external auditory canal was not involved. The patient gave the following history of the development of the disease: During the previous winter his right auricle had been frost-bitten, and the affected portion had subsequently remained quite sore. Different plans of treatment had been tried, but the area of soreness had steadily increased despite all treatment. As the neighboring glands were not enlarged, I thought the progress of the disease might be arrested, or at least be retarded, by excising the diseased portions of the auricle. The patient's consent having readily been obtained, he was etherized, and, while he was under the influence of the anæsthetic, a V-shaped piece, including the diseased tissues, was excised by means of a strong pair of scissors. The remaining upper and lower portions of the auricle were then fitted to each other as neatly as possible, and held in coaptation by means of several very fine interrupted sutures. The wound healed promptly, but very soon afterward fresh evidences of the disease manifested themselves along the line of the cicatrix, showing quite clearly that all the diseased tissues had not been excised. In 1877 I heard that the man was still alive, but could learn no particulars with regard to the condition of the affected auricle.

The case reported by Dr. J. Orne Greene, of Boston,[1] resembles in all essential particulars the one which I have just described. In his case, however, the disease had made further progress, and complete amputation of the auricle and cartilaginous portion of the mea-

vol. iii., No. 1, p. 87), Burnett ("Treatise on the Ear"), and others. A very interesting case of myxofibroma of the auricle is reported by the late Dr. C. R. Agnew, in the Transactions of the American Otological Society for 1878. In this case the tumor returned four times after the original operation.

[1] Transactions of the American Otological Society, 1870.

tus was found necessary. Roosa[1] and Burnett[2] report each a case, and the latter gives full references to the literature of the subject.

In 1871, at the meeting of the American Otological Society, I reported a case of *cornu humanum*[3] (or *cornu cutaneum*) of the auricle (Fig. 35). The details of this case are as follows:

Case VI.—The patient, a man 55 years of age, and in good general condition, stated that nearly two years previously he first noticed a small sharp point on the top of the ear. He picked it constantly with his nails, until it became sore. At the same time he noticed that what he supposed to be a simple scab covering the spot, grew to be quite thick, hard, and prominent. Whenever it reached such a size as to be an object of disfigurement, he was in the habit of paring it down with a razor. During the past two months it had grown, he thought, rather more rapidly than before, and he was therefore anxious to have it removed.

Fig. 35.—Cornu Humanum of the Auricle. (About ½ natural size.)

At the time when he visited me the growth presented the following appearances: a blunted, horn-like protuberance, three-fourths of an inch long and nearly as broad at its base, springs from the upper and posterior portion of the left helix. Of a whitish color at its base, it gradually grows quite smoky at its summit, which is more or less jagged in appearance. It is distinctly striated, the markings running in a slightly divergent direction from the summit to the base. At the extremity and in the middle portion it is hard like horn, but near the base it can easily be compressed, though yet comparatively hard. The line of demarcation between the growth and the normal skin is very abrupt. There is no tenderness on pressure.

The patient having been brought under the influence of ether, I made two converging incisions on either side of the base of the tumor. The tissues included between these incisions comprised every trace of the new growth, and the wedge-shaped wound which remained was obliterated by approximating the opposite edges of skin and keeping them in close apposition by means of fine interrupted sutures. Union took place by granulation, and at the end of the third week scarcely a trace of the operation could be detected. Six months later the patient was seen again. There were no signs of a return of the growth. A small, sharp point, however—similar, he says, to the one first noticed on the ear—could be distinctly felt and seen on the outer surface of the left eyelid.

I have seen only one other case of a similar character.

Miscellaneous Affections.—Strawbridge,[4] of Philadelphia, reports

[1] "Treatise on the Diseases of the Ear." New York, 1873.

[2] "Treatise on the Ear." Philadelphia, 1877.

[3] See Rindfleisch, "Pathologische Gewebelehre," Leipzig, 1866. § 293.

[4] Transactions of the American Otological Society, 1878.

a case of *lupus* of the auricle, and Neumann[1] makes the statement that the auricle is the favorite seat of this disease.

Syphilitic gummata and *syphilitic ulcerations* are occasionally seen on the auricle. The following two cases are the only ones that have come under my personal observation:

Case VII.—Male, ætat. 26. May 27, 1874. Syphilis (primary) four years ago. Sore throat and eruption on face last December. Three weeks ago he began to have some pain in the left ear, without tinnitus or noticeable deafness. During the past week the pain has been more pronounced, and there has been a slight discharge from the outer canal. Tragus and outer portion of meatus red, swollen, and tender, especially superiorly. Deep ulceration of the auricle at the commencement of the helix just above the orifice of the external auditory canal. It measures fully half an inch in diameter, and extends down to the cartilage.

The ulcer was cauterized with the stick of nitrate of silver, and three leeches were applied in front of the tragus. (Patient did not return.)

Case VIII.—Male, ætat. 32, in a rather poor physicial condition, June 16, 1875. He is now suffering from syphilitic disease of the nasal bones or cartilages, the contour of the nose being already disfigured. A large part of the fossa conchæ of the auricle is occupied by a dry scab, from beneath one edge of which a little pus escapes. The removal of this scab brought to view a roundish ulcer about the size of a three-cent piece. The ulcerated surface, which was not depressed below the surrounding surface of healthy skin, seemed to be composed of a soft, succulent tissue, in places apparently papilliform in structure. A single application of a saturated solution of nitrate of silver caused the ulcer to heal entirely in the course of a few days. It should be stated, however, that the patient had been taking iodide of potassium for some time previously.

Chimani reports an interesting case of *cirsoid aneurism* of the auricle, involving the branches of the superior, anterior, inferior, and posterior auricular arteries.[2] A somewhat similar case is reported by Weinlechner.[3] Repeated injections of a solution of the chloride of iron accomplished a complete cure in the former case, but in the latter it was found necessary to ligate the carotid artery.

In both of these cases a dilatation and perhaps lengthening of existing arterial vessels constituted the chief feature of the disease, while in the case of "angioma cavernosum" reported by Kipp,[4] an actual new-growth of blood-vessels appears to have taken place.

[1] Monatsschrift für Ohrenh., iii., 5, May, 1869.
[2] Archiv f. Ohrenheilkunde, Bd. viii., S. 62.
[3] Monatsschrift f. Ohrenheilkunde, xi., 1877.
[4] Transactions of the American Otological Society, 1875.

The case of an "erectile tumor" of the auricle, reported by Martin,[1] and referred to by Schwartze,[2] was probably of the same nature as that observed by Kipp. In the treatment of these vascular growths, Professor Politzer recommends the employment of Paquelin's thermocautery. If the tumor be of small size he says that it may be destroyed at a single sitting, but that in the larger growths the cauterization should be confined to a limited area, and that the procedure should then be repeated as often as may be found necessary, at intervals of five or six days. He also advises that, if any comparatively large artery (for example, the posterior auricular) be found acting as a feeder to the growth, it should be tied percutaneously. According to the same author, ligature of the carotid should not be resorted to until after the repeated use of the cautery has demonstrated clearly that the tumor cannot be destroyed by its employment. Successful results following ligature of the carotid have been obtained by Dupuytren, Mussey, and Weinlechner.

Cleft lobule, due to the wearing of ear-rings, is a comparatively common deformity of the auricle. I have several times seen a double cleft, but have never observed either the single or the double cleft in a patient who considered the deformity sufficiently great to impel her to have it remedied by an operation.

It would seem as if *wounds and contusions* of the auricle ought to come under the aural surgeon's observation quite frequently, especially in a large city like New York. As a matter of fact, I have seen but one case of this kind. Furthermore, on looking over one of the annual reports of the New York Eye and Ear Infirmary, that for 1878, I find that, out of a total of nearly 2,800 cases of ear disease, there was but one case of lacerated wound of the auricle; from which I infer either that traumatic disease of this part of the body is quite rare, or else that cases of this kind drift more naturally into the general dispensaries and hospitals. In the single case which came under my observation, the patient, a strong, healthy woman, had fallen in such a manner as to strike heavily with the side of her head upon the sharp edge of a tin pail, which was standing upon the floor. She was probably intoxicated at the time. After she had risen to her feet, she discovered that the lower part of the ear (the entire lobule and the lower portion of the helix) had been almost severed from the head. When she appeared at the Infirmary, three days after the accident had happened, the lobule

[1] Gazette des Hôpitaux, 102, 1857.

[2] Archiv f. Ohrenheilkunde, Bd. i., S. 237.

was found to be hanging loosely suspended by a small band of flesh. The raw surface had begun to suppurate, but there was very little redness or swelling of the adjacent parts. At the suggestion of my colleague, Dr. J. N. Beekman, the raw surfaces were kept in close apposition by means of a series of delicate supporting loops or bands of frayed lint held fast by a coating of collodion. By this device the edges of the wound were brought together in as perfect a manner as if a series of fine sutures had been used. The extreme posterior end of the wound was left open for drainage purposes. When the patient returned to the Infirmary, exactly one week later, the dressings were found to be still firmly in position, and the parts presented every appearance of having practically united by first intention; at all events, there was no evidence that further suppuration had taken place. To insure thoroughly firm union, the patient was instructed to wait three or four days more before removing the dressings. As she did not return a third time, it is fair to infer that the desired cure had been effected.

Triquet[1] mentions two well-authenticated instances of restoration of vitality in a severed portion of the auricle, and Schwabach[2] says that this successful result is often obtained after student-duels, in which a part of the auricle has been cut off by the sword.

Severe *burns* of the auricle present either the picture of a decided perichondritis, or that of a localized death or gangrene; both of which conditions have been discussed sufficiently in a previous paragraph. In the milder cases the pain and soreness may be greatly mitigated by the local application of carbolated oil (℥ ij of carbolic acid to ℥ iij of olive oil) or carbolated vaseline. Cooling applications also afford relief.

Frost-bite.—The auricle, by reason of its exposed position, is very apt to suffer from the effects of extreme cold. At first the cold produces contraction of the blood-vessels of the skin, but paralysis of their muscular elements soon follows, and the ear then presents a red or even purplish appearance, and is likely to be somewhat swollen. If actual freezing takes place, the ear assumes a whitish appearance, and may even, under the influence of prolonged cold, become brittle. Under favorable circumstances the frozen auricle (usually only its upper portion) may gradually resume its natural condition, though very commonly a certain degree of paresis of the blood-vessels remains, causing permanent redness of the

[1] Traité pratique des maladies de l'oreille. Paris, 1857.

[2] Eulenberg, "Real-Encyclopädie." 1882.

affected part. The best method of thawing out a frozen ear is to rub it with snow at first, and then afterward with cold water. This must be done gently, as there is danger of breaking the frozen organ. When the circulation seems to have been re-established, tepid water may be used instead of cold. These procedures must be carried on either out-of-doors or in a cold room, the aim being to restore the frozen part very gradually to its proper temperature. In unfavorable cases—those, for example, in which the ear has been allowed to remain for too long a time in a frozen condition, or in which no precautions have been taken to secure its gradual restoration to a normal temperature—inflammation sets in, and, according to its severity, we may have as a final result either gangrene and sloughing away of the part affected, or a perichondritis, presenting the picture of a well-marked othæmatoma. The treatment required for the first of these conditions is amputation of the gangrenous portion; that required for the perichondritis has been already set forth on a preceding page.

Herpes zoster of the auricle is a disease of rare occurrence. Instances of it have been reported by J. Orne Green[1] and C. H. Burnett, in this country, by Anstie in England, and by Anspitz, Gruber,[2] Hermet, and others on the continent. The disease is characterized, according to Politzer, by the development of transparent, confluent vesicles in groups, upon an inflamed skin surface. The favorite locations are the posterior surface of the auricle, the lobule, the region in front of the tragus, and the anterior upper wall of the orifice of the meatus. For several days before the vesicles appear there will be pains shooting through the head and involving the region of the ear. Narcotics, administered internally or by the hypodermatic method, may be found necessary when the pain is unusually severe.

Comparatively few cases of *congenital malformation* of the auricle have come under my personal observation. In one instance (a young infant of the female sex), both ears were deformed, though in a very different degree. The right auricle was perfect in all its parts, but just in front of the tragus, and perhaps continuous with its cartilaginous framework, was a loosely attached, irregular mass, which might perhaps be considered as a supernumerary tragus. It consisted of three distinct lobes, of which the central one was con-

[1] Transactions of the American Otological Society, 1874.

[2] "Die Bläschenflechte am Ohre," Monatsschrift für Ohrenheilkunde, ix., May, 1875.

siderably larger than the other two. The external auditory canal was normal. The left auricle was represented by a small, irregularly shaped, flattened mass, which bore no resemblance whatever to a normal auricle. Very nearly in the centre of this mass, externally, there was a small depression, which ended in a cul-de-sac at a depth of three or four millimetres. Beyond the depression, I could feel a short, solid cord, representing undoubtedly the obliterated or imperfectly developed external auditory canal. In all other respects, the child seemed to be perfectly formed and well nourished.

In another case (female child, nearly three years old) the malformations of the auricles were exactly the same on both sides. The lobe was perfectly formed and of full size, but the upper parts of the auricle seemed to be shrivelled up into a small, shapeless mass. As in the previous case, a small depression indicated the situation of the rudimentary external auditory canal. With the finger the tympanic ring could readily be outlined; it appeared to be of normal size. The parents were positive that the child heard quite well. I was not able myself to determine satisfactorily what degree of hearing she possessed. Apart from the deformities described above, the child appeared to be perfectly formed.

Finally, in still another case, the deformity consisted in an imperfectly developed cartilaginous framework of the auricle. The child, a twin, four years old, and otherwise well developed, possessed two large, but very thin, auricles. The fossa helicis of each ear was obliterated, and the upper part of the auricle drooped, somewhat after the fashion of a dog's ear. The changes noted were more marked on the left than on the right side. The impression made upon my mind at the time was that undue pressure *in utero* had flattened both auricles, and had arrested the development of their cartilaginous frameworks.[1]

Congenital fistula of the ear is an affection which is quite rare and at the same time very easy to be overlooked. Just in front of the tragus a small scab may be seen, and when it is removed there will be brought to light the orifice of a sinus containing creamy pus.

[1] Dr. C. J. Blake reports an interesting case of congenital malformation of the auricle, in the Archives of Ophthalmology and Otology, vol. iii., No. 1, p. 86. Strawbridge reports a case in the Transactions of the American Otological Society, for 1875, and gives some references to the literature of the subject. Dr. Knapp also reports a case in the Transactions of the American Otological Society, for 1870. Further references to the literature of the subject will be found in the treatises of Roosa and Burnett.

Pressure upon the skin from below upward, or from above downward, generally causes an appreciable amount of pus to escape from the opening. The history given by the patient is simply that of a discharging sinus which occasionally heals up for a short time and then breaks open again. Only three cases have come under my observation. In two of these I found the skin surrounding the orifice of the fistula perfectly natural in appearance, and at the time of the examination there was not even a scab to indicate its location. In fact, there was not even a depression of the skin at the point where the orifice existed, and the only way in which I could locate its exact situation was by forcing out pus through pressure. My probe, introduced into this opening, passed directly inward, without encountering any resistance for a distance of about one-quarter inch. There it encountered firm resistance; but when I elevated the outer end of the instrument so as to bring it into a nearly vertical position, it slipped easily downward (no force being used) a further distance of fully three-quarters of an inch. At this point it seemed to reach the natural end of the channel. Cauterization of such fistulæ has invariably, I believe, proved of no avail. It is only by laying open the track with the knife and destroying its pus-secreting surface that one can hope to cure this pathological condition. In not one of my three cases was I able to secure permission from the parents to employ operative procedures.

CHAPTER IV.

DISEASES OF THE EXTERNAL AUDITORY CANAL.

IMPACTED CERUMEN AND CIRCUMSCRIBED INFLAMMATION.

The affections to which this portion of the ear is liable comprise those which may equally well affect the auricle, those which have extended to it from the middle ear, and others which are peculiar to the canal itself.

IMPACTED CERUMEN.

The most frequent affection of the auditory canal is that which is known as impacted cerumen. In the cartilaginous portion of the canal, and also, to a very limited extent, in the osseous portion, there are glands which secrete the peculiar substance known as cerumen, or ear-wax. These glands, when examined under the microscope, in thin sections of the meatus, are seen to be similar in all respects to the sweat-glands. The secretion from these glands is a transparent, yellowish fluid. It is only after exposure to the air that it gradually becomes inspissated and of a darker color. Under certain conditions the ceruminous glands secrete this yellowish fluid in such abundance that it escapes from the orifice of the external auditory canal in the form of a watery discharge. I have several times been told by patients that they had a discharge from the ear, and, on making an examination, have been surprised to find that what both they and I supposed to be a *bona fide* discharge of pus, or sero-pus, was in reality simply an excessive secretion of fluid cerumen. As a rule, however, the rate of secretion is so slow that the cerumen becomes inspissated very soon after it leaves the mouths of the glands. For the further propulsion of this material out of the canal, Nature seems to have made a very curious provision. It is now an established fact that at least the uppermost layer of the epithelium lining the external auditory canal moves constantly from within outward. Thus, for example, if on a certain day we find a scab resting wholly upon the drum-membrane, five or six days from that time we shall find it resting partly upon the

drum-membrane and partly upon the wall of the osseous canal. At the end of another week it will be found to have travelled outward entirely beyond the limits of the membrana tympani. This same surface movement undoubtedly takes place symmetrically throughout the entire length of the canal, and supplies the force required to extrude all ordinary accumulations of cerumen. In the Eustachian tube and in the bronchial tubes we find the epithelial cells provided with cilia which constantly vibrate in such a manner as to propel any mucus or foreign substance that may happen to be in the tube, in the direction of the naso-pharyngeal space or of the larynx, as the case may be. The conditions that exist in the external auditory canal do not require any such vigorous propelling power as that supplied by the movement of the cilia in the other channels mentioned, and, accordingly, Nature supplies a less active power, but, at the same time, one that is better adapted to stand the rough usage to which this part of the body is specially liable.

It is not an easy task to harmonize the existence of such an extruding power in the walls of the external auditory canal with the extremely frequent occurrence of the condition known as impacted cerumen. An abnormal activity on the part of the ceruminous glands is undoubtedly the most important factor in the production of this condition. At the same time hypersecretion alone can hardly be held responsible for the production of the impacted state; other factors must certainly aid in producing it. The sharp bend which the canal makes near the external orifice is often associated with such a marked shortening of one of its diameters that for all intents and purposes the canal is very much narrower at this point than it is at a short distance deeper in, where a large part of the cerumen is secreted. This narrowing of the canal varies greatly in different individuals, and in some no narrowing whatever is found. Where it exists, one can easily conceive how it may prevent a mass of cerumen, of comparatively small size, from being extruded from the canal. When the mass has once been arrested in its movement outward there is no difficulty in understanding how it may grow, by accretions upon its surface, to the full size of the cavity which contains it. Furthermore, it is not unlikely that the individual's own efforts to keep the orifice of the external auditory canal clean, or to relieve the sensation of itching which is so often present in this condition, sometimes result in pushing the accumulation farther inward toward the drum-membrane.

Etiology.—Excessive secretion of cerumen is so often associated

with naso-pharyngeal catarrh that it is hard to resist the belief that the former is a reflex phenomenon dependent upon the latter. On the other hand, in certain cases of well-marked deafness, it is a common experience to hear the patients say, —of their own motion, and not in response to a question, — that they never find wax in their ears, and have not for several months or years past. The few cases that I have examined, since my attention was attracted to the coincidence of deafness with absence of the secretion of cerumen, presented the following conditions: The membrana tympani was usually thin and translucent, though not appreciably sunken; through its posterior half could be seen the darkly shaded niche of the fenestra rotunda, and, above this, perhaps also the faint outlines of the long process of the anvil. The whiteness of the promontory was also easily recognized through the membrane. On inspection of the pharynx the mucous membrane of this region was found to be pale and very thin; apparently the follicles had all disappeared through atrophy. As I shall have occasion to speak of these conditions again further on, it is not necessary to enter more minutely into details in this place. If it be once admitted that increased functional activity of the pharyngeal glandular elements may in a reflex manner increase the functional activity of the ceruminous glands, the question at once suggests itself, Why may not the subsequent atrophy of the pharyngeal glands bring about, in the same reflex manner, a wasting of the glands in the external auditory canal? As long ago as 1872, Dr. Oren D. Pomeroy, of this city, expressed himself as follows in regard to this question: "In view of the fact that frequently an absence of a normal amount of cerumen is observed in old cases of aural catarrh, it may, together with the present observations, cause one to infer that the ceruminous function is greatly affected in catarrhal diseases.

"Perhaps a theory of this kind may sometimes be borne out by a sufficient number of facts; that the earlier stages of catarrh result in hyperæmia and consequently augmented function of the ceruminous glands, which, continued, may result in atrophy with abolition of function, precisely as results in inflammation of the mucous membrane lining the fauces," etc.[1]

It is perhaps more in accordance with established facts to consider atrophy as the natural termination of the prolonged increased functional activity of the ceruminous glands, than to consider it as

[1] Transactions of the American Otological Society for 1872: article on an "Examination of 100 Cases of Impacted Cerumen."

the result of reflex influences. With regard, however, to the first step in this series of changes, I should rather favor the view which refers its origin to a reflex influence, than that which makes the irritation spread directly from the mucous membrane of the middle ear to the skin of the external auditory canal. And in corroboration of this view I may refer to the fact that, in cases of abnormal increase in the secretion of cerumen, we rarely fail to find evidences of active irritation in the vault of the pharynx.

An eczematous inflammation of the skin lining the external auditory canal is also apt to be associated with an excessive secretion of cerumen; and it seems fair to assume that the force which excites this diffuse inflammation—viz., the gouty condition—acts at the same time as a stimulus of the functional activity of the ceruminous glands.

Symptomatology.—During the formation of the mass, before it has reached such a size as to occlude the canal, the patient, as a rule, experiences no symptoms which would be likely to call his attention to the ear. In cases, however, where the canal is slit-shaped, a sense of fulness or discomfort may be experienced long before the canal is actually occluded,—that is, as soon as the accumulation is large enough to bridge the space between the opposite walls. Complete occlusion may take place so gradually that the patient's attention is attracted to only one symptom, viz., the gradual diminution of the hearing. In very many cases, however, the statement is made that the diminution in the hearing came on quite suddenly, as, for instance, after a bath, after washing the head, or after some mechanical interference with the ear (introduction of the end of a towel, etc.). This sudden diminution of the hearing may then pass away as suddenly as it came, to return again after the lapse of a few days or weeks. When the canal has become fairly occluded, other symptoms may develop. In a few cases there will be tinnitus, which may be ascribed to pressure exerted by the ceruminous mass upon the drum-membrane, or possibly to the obstruction of the venous circulation in the external auditory canal, thus causing a passive congestion of the veins of the middle ear, which pour their contents in part into those of the meatus. In any given case, however, it is nearly, if not quite, impossible to determine what share the ceruminous mass, and what the coexisting catarrhal inflammation of the middle ear, take in producing this symptom. Pain can hardly be mentioned among the symptoms of this condition, as it is due to an intercurrent inflammation of the walls of the

canal. Cases are on record which seem to show that impacted cerumen may produce, in a reflex manner, epileptiform convulsions. I have also recently read the report of a case in which a chronic bronchial catarrh seemed either to owe its origin to, or to be kept up by, the presence of a mass of impacted cerumen in the patient's auditory canal. At all events, the removal of the mass caused the cough and expectoration to cease in a very short time. Furthermore, cases have been reported in which a high degree of dilatation of the osseous canal is ascribed to the pressure of a mass of cerumen. I believe that cases have also been reported in which even a fatal issue has been referred back to the gradual increase in size of a mass of impacted cerumen. My impression is, that if all these cases could be carefully analyzed, the great majority of them would be found to be in reality cases of desquamative inflammation of the canal (secondary to middle-ear trouble), or of otitis media purulenta, with hardening of the purulent secretion in the meatus. Inspissated cerumen forms on the outer side of, and becomes mingled with, these purulent and epidermal products, and so the cases come to be classified among those of impacted cerumen. While it may not be possible in all cases to draw a sharp line of distinction between the milder cases of desquamative inflammation of the canal and those of inspissated cerumen, it is of decided practical importance to make the distinction whenever we can. So far as my own experience goes, I may say that I have never seen a case in which the pressure made by a mass of impacted cerumen has caused absorption of the bone and consequent increase in the size of the canal. Nor have I ever seen one in which bronchial catarrh, epileptiform convulsions, or any other equally grave symptoms, could fairly be attributed to impacted cerumen, in the strict sense of the term. Tinnitus and moderate dizziness, due probably to the pressure of the mass upon the drum-membrane, are certainly not rare symptoms, but I have never seen a case in which the impacted cerumen had produced actual fainting or loss of consciousness.

Diagnosis.—Inspection with the speculum and reflected light reveals the presence, in typical cases, of a black or dark-brown mass, filling the canal, and obstructing the view of the deeper parts. Until the contents of the canal have been thoroughly removed, it is not safe to say positively that the case is simply one of impacted cerumen. All sorts of conditions may be found beyond the outer

[1] The case is reported in either the British Medical Journal or the London Lancet, in one of the November numbers (1879).

mass or shell of cerumen, and the physician must therefore withhold or qualify his diagnosis until he can ascertain fully the true state of the ear.

Prognosis.—In cases of impacted cerumen, associated with difficulty of hearing, the physician will do well to express his opinion very guardedly with regard to the question of restoration of the hearing-power. It is such a common experience, as I have already stated, to find a chronic naso-pharyngeal and middle-ear catarrh associated with impacted cerumen, that he should always be prepared to find that the catarrhal affection, and not the obstructing mass, has diminished the acuteness of the hearing. The marked tendency to relapses must also not be forgotten, when a prognosis is given.

Treatment.—The question of treatment resolves itself practically into the question, How can the obstructing mass be removed most thoroughly, quickly, and pleasantly—both for the patient and for the physician? In the earlier period of my practice I pursued the orthodox plan of employing the syringe and warm water for this purpose. Little by little, however, I became satisfied that in the great majority of cases the removal of the mass could be effected much more quickly and pleasantly by the use of the curettes and the angular forceps than by any other plan; and from that time forward it has been my uniform practice to use the syringe only in certain exceptional cases; for instance, in those in which, after the removal of the greater part of the mass by instrumental means, a semifluid or very tenacious cerumen was found plastered over the drum-membrane; and also in those in which the extreme smallness of the canal rendered it unusually difficult to follow the movements of the curette with the eye. The objection raised by some authors against the instrumental plan of removing impacted cerumen, viz., that it requires great skill and may prove highly dangerous in unskilful hands, does not seem to me to be a valid one. Therapeutic methods should be recommended in accordance with their absolute merits, and not because they will be likely to prove the least harmful in unskilled or clumsy hands. The objections to the employment of the syringe, aside from the disagreeableness of the procedure to both physician and patient, are the following: It very often causes an unpleasant sensation of faintness and dizziness, and this is particularly apt to occur in cases in which there is a perforation in the posterior and upper part of the tympanic membrane—a condition which leaves the stirrup and oval window exposed to the direct shock of the stream

of water coming from the surgeon's syringe. And, furthermore, this same stream of water may lodge in the middle ear a mass of decomposing organic material, which is quite competent to excite acute inflammatory processes in that cavity. Still another objection is the loss of time which the syringing method often entails. Thus, for example, in a large proportion of cases, the instrumental plan will accomplish in ten or fifteen minutes what the most skilful employment of the syringe cannot possibly accomplish in even an hour's time. Finally, it is easily possible for a man with average manual skill to acquire such dexterity in the manipulation of the curette and the other instruments mentioned, that he will be able to remove impacted cerumen from the auditory canal with less discomfort to the patient than is usually experienced when the syringe is used.

As the cases of impacted cerumen differ from one another in important particulars, only very general directions can be given with regard to the proper mode of removing the impacted mass with instruments. In the first place, the physician must follow every step of the operation with the eye. He should use as large a speculum as the size of the canal will permit, and the illumination should be good. If the wax is quite soft, a small channel should be cleared, with the curette, for a short distance along the upper wall of the canal, in order to afford room for the introduction of the cotton-carrier armed with a mop of cotton of suitable size. Two or three introductions of the cotton-carrier, armed each time with a fresh mop, will usually suffice to remove all the cerumen lying between the external orifice and the farther end of the channel made by means of the curette. The remainder of the mass is to be treated in precisely the same manner, until the whole of it shall have been removed from the auditory canal. If the wax is moderately firm in consistency, the entire mass may be removed piece by piece with the curette. The occasional use of the forceps will also be found advantageous, especially if the surgeon has succeeded, by means of the curette, in separating the mass, or a large portion of it, from its attachment to the walls of the canal. There are certain conditions in which the slender silver probe will be found a more useful instrument than the curette; as, for example, where a mass of cerumen is wedged in between the drum-membrane and the anterior and lower wall of the canal. By giving to the end of the probe a slight curve, one can readily dislodge the mass and bring it within reach of the forceps. In those cases in which, after removing almost all

of the obstructing mass, I have found the membrana tympani plastered over with soft cerumen, I have usually resorted to the syringe as the quickest and (to the patient) pleasantest means of removing this remainder of the accumulation. So long as the curette is made to pass flatwise over the walls of the auditory canal, and so long as the force employed is applied in the direction from the periphery toward the centre of the canal, the patient will experience no pain and perhaps not even discomfort. If the canal is quite large and straight, the end of the curette may be bent in such a manner as to make the plane of the ring form an obtuse angle with the shank; and the same kind of dissecting manipulation as that to which I have just referred can then also be applied to the surface of the drum-membrane. As a rule, however, a sort of scraping motion is the only effective one that can be communicated to the ordinary curette when brought in contact with the membrana tympani. Such a mode of employing the curette is not to be recommended, and therefore, under these circumstances, the syringe is to be preferred.

If the physician, for any reason, decides not to use the instrumental method, he will find that in exceptional, though by no means rare cases, syringing alone will fail to dislodge the impacted mass. The only course left open to him, under these circumstances, is to employ some chemical reagent which possesses the power of softening masses of inspissated cerumen. Water alone, it is true, possesses this solvent power, but its action is extremely slow. Bicarbonate of soda, on the other hand, is quite rapid in its solvent action, and yet at the same time it may be used freely in concentrated solutions, without fear of injuring the walls of the canal.

Dr. Blake, of Boston, employs liquor potassæ, or a solution of caustic potassa, for the purpose of softening hardened masses of cerumen. He arms the end of a probe or cotton-carrier with a small mop of cotton, dips it into the solution, and then applies it accurately to the centre of the outer end of the mass. Under the influence of such a strong alkali, the cerumen softens very rapidly, and so, little by little, he is able to bore a channel through the centre of the plug. The remaining shell can then be easily broken into a mass of loose fragments which syringing will quickly bring away from the canal.

The practice of employing olive oil as a means of softening hardened wax is not to be commended. Its presence in the external auditory canal, especially when the walls of the latter are somewhat inflamed, is apt to give rise to a troublesome growth of the

aspergillus fungus. (For particulars in regard to this subject, see farther on, in the present chapter.)

Finally, one word more with regard to syringing in cases of impacted cerumen. One of the chief reasons why syringing so often fails to wash out the mass of impacted cerumen, is this: the force of the current is spent upon the broad surface of the outer end of the plug, and tends therefore rather to drive it farther inward. The most effective plan is to direct the stream against one edge (preferably the upper edge) of the mass, in the hope of washing out a channel between the main body of the plug and the upper wall of the meatus. As soon as this has been accomplished, it will be found that the current begins to exert a *cis a tergo*—a force from behind—upon a portion of the mass, and soon brings away fragments of considerable size.

Complications.—It sometimes happens, in these cases of impacted cerumen, that a furuncle develops in the obstructed meatus, or that an acute inflammation is set up in the adjacent middle ear. In the presence of such a complication, the question arises, shall we allow the intercurrent inflammation to run its course before we make the attempt to remove the impacted cerumen, or shall we undertake the latter operation without further delay? The pain attending either of the two combinations mentioned is apt to be very severe, and the inflammation is generally more extensive and of a more serious character than when the auditory canal is free from obstructions. If, therefore, we can, by any means at our command, remove these obstructions at once, it is clear that this is the proper course to pursue. If the orifice of the canal is closed, through œdematous swelling of the soft parts, it will be found comparatively easy to dilate it gradually by means of Wilde's specula, or by the aid of conical mops of cotton, wound firmly around the end of a probe or cotton-carrier, and smeared with vaseline. As soon as the ceruminous mass has been exposed to view, we should proceed in precisely the same manner as if the case were one of a simple nature.

CIRCUMSCRIBED INFLAMMATION.

The external auditory canal seems to possess a special predisposition to furuncular inflammation. Our knowledge of the causes which give rise to the disease is rather limited. An irritating discharge from the middle ear, or from the deeper parts of the meatus (as, for example, in eczema), very often leads to the formation of furuncles in the outer or cartilaginous portion of the canal. It has

also been observed that the disease is sometimes encountered in persons whose general health is not quite up to the proper standard. In a very large proportion of the cases, however, it will be found that furunculosis and a diffuse eczema of the external auditory canal go hand in hand; the latter seeming to be the necessary antecedent of the former.

Some authorities maintain that a circumscribed or furuncular inflammation is caused by micro-organisms—particularly the staphylococcus. This is undoubtedly true, in the sense that without the intervention of these organisms a furuncle could not develop; but it is scarcely true in the sense that staphylococci, for example, are able, under all circumstances, if permitted to gain entrance into a ceruminous or a sebaceous gland, or into a hair follicle, to set up there a furuncular inflammation. There are good reasons for believing that these bacteria easily gain an entrance into these parts of the body at all times, and yet many human beings pass through life without ever experiencing a furuncular inflammation of the external auditory canal. It is plain, therefore, that the determining etiological factor in these cases is not the presence of certain kinds of bacteria in the skin of the meatus, but a certain something else which we can only vaguely designate by such terms as "diminished power of resistance on the part of the tissues," or "alteration of the tissue-juices in such a manner as to rob them of their defensive powers in the presence of certain bacteria."

In a few cases, what seems at first to be a furuncular inflammation of the outer portion of the canal proves, later, to be a localized chondromalacosis. The more decided severity of all the symptoms, the greater depth to which the probe may be made to penetrate after the abscess has ruptured, the longer duration of the course of the disease, and the necessity, oftentimes, of cauterizing the abscess cavity with strong nitric acid before we can cause it to heal,—all these facts, it seems to me, justify the view that we are dealing with something more profound, more destructive, than a simple furuncular inflammation. These unusual cases will receive separate consideration a little further on.

Furuncles of any considerable size are encountered only in the cartilaginous portion of the external auditory canal. They probably originate in the sebaceous or the ceruminous glands, which are very large and very numerous in this region. The base of the tragus, on the anterior wall of the orifice, is a favorite seat. In the osseous portion of the canal there are very few and very small ceruminous

glands, situated chiefly along the upper wall, and, consequently, the furuncles encountered in this part of the ear are very small and insignificant. If a larger abscess is seen in this part of the ear, we may justly suspect that it is connected with disease of the adjacent bone, or with a sinus passing through the soft parts which lie above the drum-membrane.

Course of the Disease.—Furuncles as a rule develop gradually. The patient first notices a little pain in the region of the ear, and, on pressing with his finger upon the parts, finds that they are slightly tender. Gradually the pain increases in severity, and the ear feels full and heavy. Deafness is not observed until the tumor reaches such a size that the meatus is closed at the point involved. The motions of the jaw are apt to cause pain, and in some cases there is well-marked œdema in the neighborhood of the affected ear. Rupture of the abscess may take place spontaneously as early as on the second day, but, as a rule, we must not look for this event before the third or fourth day. Healing and subsidence of all inflammatory symptoms usually soon follow. In those cases in which the cartilage seems to be involved, the abscess may go on developing for a week or longer. The whole course of the disease in these cases is much more protracted, and a depressed scar may remain after the parts have healed.

Diagnosis.—The diagnosis is easily made in the majority of cases. The absence of deafness and tinnitus, or the development of these symptoms only after the pain has lasted for two or three days, points clearly to an inflammation that has originated outside of the middle ear. But when the inflammation is of a violent type, when the case is seen only at an advanced stage, and especially when the patient is not very clear in regard to the mode of onset and sequence of the subjective symptoms, considerable difficulty may be experienced in arriving at a correct conclusion in regard to the nature of the disease. Indeed, often it is simply impossible to make a positive diagnosis, and we are obliged to treat the urgent symptoms without regard to what the origin of the trouble may have been. In certain cases, which are of very rare occurrence, a sinus leading from a focus of disease situated in the deeper parts of the temporal bone may have a furuncle-like outlet, on the lower wall of the canal, close to the external orifice. A case of this character may easily be mistaken for one of furuncular disease, and, even after one's suspicions have been aroused, it is no easy task to demonstrate the real nature of the affection.

Prognosis.—The prognosis is favorable. If there has been no precedent eczema, we may confidently look for a speedy and permanent return of the parts to a natural condition. On the other hand, a chronic eczema renders it highly probable that the first furuncle will be succeeded by others, throughout a reasonably long period, before finally the tendency to such outbreaks is overcome. Permanent damage to the parts, even after the most severe attacks of inflammation of the external auditory canal, is not to be expected.

Treatment.—The chief indication in this disease is to relieve the patient's suffering. It is a disputed point how this may best be accomplished. Some of the highest authorities unhesitatingly advise the early employment of the knife. My own experience, however, leads me to adopt the rule laid down by Wilde: "As soon as we believe matter is formed and come some way to the surface, but not till then, we should make an incision." I prefer, generally, to wait and let the abscess open by natural processes; and, as a means of hastening these, and also for the purpose of mitigating the patient's suffering in the mean time, I am in the habit of prescribing hot poultices. These should be of sufficient size to cover the entire region of the ear (say 5 or 6 inches square), and they should be renewed at frequent intervals. While the flaxseed-meal poultice is perhaps the best that can be used for this purpose, there are various substitutes which will be found to answer almost equally well; for example, a rubber bag filled with hot water, a flannel or muslin pillow filled with dried hops and heated in the oven or in front of a hot open-grate fire, hot bran bags, a large sponge or several thicknesses of flannel wrung out of hot water, and so on.

I have very little faith in the local use of anodynes, and the introduction of glycerine, sweet-oil, or almond-oil commends itself still less to my judgment. Glycerine is by no means a bland and soothing fluid, and the oils may furnish a nidus for the subsequent development of the *penicillium glaucum*, or some other variety of fungous growth, which the surgeon may find it difficult to dislodge. Vaseline, on the other hand, may be used with impunity in the ear.

Local blood-letting by means of leeches (or Bacon's artificial leech) is very apt to fail in this form of disease, and I do not often resort to its use if I am sure of my diagnosis. In acute affections of the middle ear it is a much more valuable remedy.

If the knife be employed, the best pattern for this special pur-

pose is a curved, sharp-pointed bistoury. If the swelling is well defined, the incision should be made through the centre of it, the point of the knife being carried from within outward. The operation should be performed under illumination from the forehead mirror, and the incision should be made of such a length and depth as will afford a free exit to the pus. If the swelling is not well defined, my plan is to introduce a cotton-carrier, well protected with cotton, into the swollen canal, and then to exert pressure in different directions. The region of greatest tenderness is that into which I make the incision. It is well to have at hand a large sponge and a basin filled with hot water. Immediately after the incision has been made, the hot and moist sponge should be held against the ear, for the purpose of quieting the pain, which for a few minutes is generally very acute. When the pain subsides, dry warmth may be substituted for the hot and moist application. The only objection to the prolonged use of moist heat under these circumstances is, that it favors the development of granulation-tissue in the wound, and is also apt to set up a painful inflammation of the auricle.

In addition to these local antiphlogistic measures, it is well to employ other means which exert constitutional effects. A dose of calomel (one or two grains) or a blue pill (five grains) at night, followed by one-half or two-thirds of a tumblerful of Rubinat-Condal water, or two tablespoonfuls of the Carabaña water, or a full dose of Rochelle salts (a tablespoonful in a tumblerful of water), on the next morning (at least half an hour before taking food), will promote the subsidence of the inflammation. Rest in bed constitutes an important part of the general treatment. Finally, it will generally be found desirable to prescribe a tonic (Huxham's tincture of cinchona in teaspoonful or dessertspoonful doses), or even, in the more protracted cases, cod-liver oil (teaspoonful doses of an emulsion with the hypophosphites). If the patient gives a history of eczema, the treatment should be modified by the adoption of such measures as are appropriate for the relief of this condition. These are described elsewhere in this work (see pages 126 *et seq.*).

Course of the Disease in the Unusual Cases.—The following histories, taken from my case-books, will illustrate sufficiently the different types of cases which, while they may be rightly classified under the heading "circumscribed inflammation of the external auditory canal," are nevertheless of a very different nature from that of a furuncular inflammation.

CASE IX.—*Acute circumscribed osteitis (primary) of the inner half of the external auditory canal, resulting in the exfoliation of a small splinter or flake of bone; perfect recovery.*

Female, thirty-five years old, usually healthy, but at the present time feeling the effects of overwork (she belongs to a sisterhood), consulted me on June 9th, 1880, for the relief of a discharge from the left ear. The only history which I was able to obtain was this: three weeks previously she had experienced a little pain in the affected ear, and shortly afterward discovered that a discharge was escaping from the outer canal. This had continued uninterruptedly up to the time when she came to my office. There had been no return of the pain, and the hearing, which before the attack had always been excellent, was affected to only a slight degree. On examination, I found that at the inner end of the auditory canal, close to the membrana tympani, there was a somewhat spherical mass of firm granulation-tissue, which sprang, by a rather broad base, from the lower wall posteriorly. It occupied fully four-fifths of the calibre of that part of the canal, and presented a small depression or pit on its outer surface, close to the summit. This pit, when explored with a bent probe, was found to be the external orifice of a fistula, which led downward and backward to exposed and roughened bone. By means of a blunt-pointed knife, whose blade was curved flatwise, I was able to cut away the larger part of the growth. The membrana tympani, which was then exposed to view, appeared to be normal. Nitric acid was applied to the stump.

On June 20th I found the growth to be as large as it was when I first saw it; and I accordingly removed it a second time. The patient announced her intention to go into the country for a few weeks.

On July 16th I found the ear entirely well in all respects. The patient stated that on or about the first of the month the parts around the left ear became very much swollen, and then shortly afterward a small splinter of bone presented itself at the outer orifice of the meatus. The swelling then disappeared rapidly and the discharge ceased entirely. On examining the ear I found a small hemispherical cicatrix at the point where the growth had previously existed.

Comments.—I am unable to formulate any theory which seems to me to afford a reasonable explanation of how this localized osteitis came into existence. The idea of a minute embolism in the small artery which provided nourishment for this particular area of bone, suggests itself at this late day. And yet no illness of any kind had preceded this localized inflammation, nor were there any symptoms pointing to valvular disease of the heart. No other precisely similar case has ever come under my observation.

CASE X.—*Limited necrosis of the osseous portion of the external auditory canal, without any accompanying disease of the middle ear; perfect healing at the end of a few weeks.*

The present case is that of a healthy boy, seventeen years of age. On the 7th of April, 1877, he consulted me for the first time, and gave the fol-

lowing history of his trouble. During the previous summer he had passed through an attack of typhoid fever, and while he was convalescing a large abscess developed in the right parotid region.[1] This abscess broke and discharged its contents through an opening in the right auditory canal. From that time to the present there had been more or less discharge from the ear, but on the whole it had been diminishing in quantity. He had experienced no deafness with it, except temporarily, when the discharge filled the canal. About three months previously he had discovered a small fragment of bone in the discharge. On examination, I found a flattened, succulent mass of granulation-tissue lying on the lower and posterior wall of the canal, apparently at the junction of the osseous with the cartilaginous portion. This mass, as I ascertained by careful probing, grew from the edge of a not very deep ulcer, at the bottom of which denuded bone was readily felt. A short distance beyond, in the osseous or membranous part of the canal, a second superficial ulcer was found. At all other points the canal presented an uninflamed and natural appearance. The membrana tympani also appeared to be normal.

Treatment was commenced on the 19th of April, and on the 29th, ten days later, the larger ulcer was found to be completely healed. The polypoid mass was first removed with the snare, and then the remaining raw surfaces were freely cauterized (daily) with nitrate of silver, fused upon the end of a cotton-carrier. Five or six such cauterizations were made, and then the rapidly contracting ulcer was completely covered with pellets of powdered burned alum. After two or three such applications, complete cicatrization of the parts was found to have taken place. The more deeply situated, superficial ulcer, which seemed a very trifling affair in comparison with that which lay nearer to the external orifice, proved the more rebellious of the two. In fact, it had not yet entirely healed on the 29th, when the boy returned to his home in the country. A few weeks later, however, he visited me again, and I then found that this ulcer too had completely healed, no further treatment having been carried on in the mean time.

Case XI.—*Proliferative osteitis confined to a transverse, strip-like area of the osseous external auditory canal; cause of the disease not ascertained.*

The patient, a healthy man, twenty-two years of age, sought relief at the New York Eye and Ear Infirmary, on the 25th of October, 1871, on account of an acute affection of the left ear. As a matter of routine, I also examined the right ear, of which the patient had made no complaint, and found the canal blocked by a large and hard plug of cerumen. After the mass had been extracted, I discovered that a ridge of bone, about two millimetres high, crossed the lower wall of the osseous canal, at right angles to its long axis, and only a short distance from the line of junction of the cartilaginous and osseous portions. Along its sides this ridge was covered with small, soft granulations. Quite firm pressure with the probe failed to break off any portion of the irregular, free edge of the ridge. The drum-membrane showed only insignificant changes, and there was simply moderate redness of the canal in the neighbor-

[1] Parotid abscesses are said to be among the many very rare sequelæ of typhoid fever.

hood of the carious region. The watch was heard at a distance of six feet. No evidences of syphilis could be found, and the patient was very positive that he had never had a discharge from the right ear, and had never experienced pain in it. (He was seen again only once, a few days later.)

Case XII.—*Acute suppurative inflammation of the posterior fold, accompanied by distressing tinnitus; relieved by an incision.*

The patient, a policeman, consulted me, on the 10th of March, 1874, for a very distressing tinnitus in both ears. He had experienced no pain in them, and his hearing, so far as he was aware, was perfect. The tinnitus had made its appearance about two months previously. I tested his hearing with my watch and found it to be: R.—$\frac{6}{12}$; L. $\frac{6}{12}$. Both drum-membranes presented a dull and opaque appearance, and were slightly sunken. On the left side there was moderate congestion of the posterior fold (the soft parts above and behind the short process of the hammer). My diagnosis was catarrhal inflammation of both middle ears, and I began treating the patient in accordance with that diagnosis.

On the 14th of March, finding that the redness of the posterior fold still persisted, I painted the parts with a strong solution of nitrate of silver (gr. 120 to the ounce). I interpreted this redness as an evidence of a still more active congestion of the neighboring mucous membrane, and employed the solution of silver simply for the purpose of producing a derivative effect.

On the 16th the patient reported that the tinnitus in the left ear had materially increased: there was, as he described it, a constant ringing of bells in his ear. His face presented the aspect of one who was in suffering, but yet he described the pain in his ear as being only trifling. H.D.W.—L. $\frac{3}{12}$. On inspection I found that the skin immediately above the posterior half of the drum-membrane was red, tense, and glistening. Through the upper and posterior portion of the membrana tympani, which was still translucent, a yellowish area was visible. It conveyed to my eye the appearance as if a yellowish body projected downward from the inner side of the axis-band of the hammer. Suspecting the existence of an accumulation of pus, I incised the inflamed and swollen posterior fold, and afforded escape to a drop of thick, creamy pus. A second incision into the anterior fold, which was also quite red, gave escape only to blood. (The patient bore both of these cuts without flinching.) Inflation by Politzer's method failed to exert the slightest appreciable influence upon the contents of the abscess. After the immediate pain of the incisions had subsided, the patient expressed himself as feeling greatly relieved in the condition of his head.

On the 18th of March the patient reported that he was feeling better, and that no discharge had yet made its appearance; and on inspection I found that no evidence existed of there having been any discharge since the day of the operation.

On the 23d of March only a slight singing noise remained in the left ear.

Comment.—I have seen very few cases similar to the one just narrated. So far as I now know, they are instances of genuine furunculosis, occurring in an unusual part of the external auditory canal.

CHAPTER VII.

DISEASES OF THE EXTERNAL AUDITORY CANAL (Continued).

DIFFUSE INFLAMMATION.

Under this heading may be grouped the different pathological conditions to which the names "otitis externa diffusa," "eczema," "desquamative inflammation," "periostitis," and "otomycosis" or "parasitic disease of the external auditory canal," are commonly applied. It is not always easy to separate these different conditions, and to apply to them satisfactory distinguishing terms. The expression "desquamative," for example, is a very convenient one, because it characterizes at once the most striking feature in a large percentage of the cases of diffuse inflammation; but unfortunately it does not belong to any one group, and therefore cannot well be used as a distinguishing term in any attempt at classification. The same remarks apply measurably to the other terms enumerated—periostitis, eczema, and otomycosis or otitis externa mycotica—and yet we cannot wholly dispense with these convenient expressions. Our best course at present, as it seems to me, is to divide these cases of diffuse inflammation into three groups, viz.:

1. Those in which a direct irritant applied to the skin of the canal has excited the inflammation.

2. Those in which the irritation has come from within the patient's system (either by way of the blood or through faulty metabolic changes in the tissues themselves).

3. Those in which the outward inflammation is simply an expression of an underlying chronic osteitis (the product of some earlier severe inflammation of the middle ear).

Of these three groups, practically only the two last are encountered in practice; for very rarely indeed is an irritating substance introduced into the external auditory canal. Diluted carbolic acid possesses these irritating properties, and it is the only one—so far as I can now call to mind—which is likely to be used for therapeutic purposes. Then, again, it is possible that some of the cases of

aspergillus growth in this canal may belong in this first group, and not in the second. It would be a difficult matter to determine a question of this kind positively; but it is my impression that the aspergillus rarely, if ever, develops upon a normal skin surface. In other words, the skin of the external meatus must first become diffusely inflamed (eczema) and covered with a certain amount of moisture before the aspergillus can take root and flourish. But nobody will deny, as a matter of course, that the growth of the aspergillus in the skin of the canal may seriously aggravate the pre-existing inflammation.

On the other hand, the cases which belong in the second group are very numerous, for the external meatus is one of the spots in the human body where eczema oftenest shows itself.

Then again, in a certain number of instances of acute inflammation of the middle ear, an incomplete recovery follows; that is, after the acute attack has subsided, a low grade of osteitis of that part of the temporal bone which borders upon the external meatus lingers on for years, and the skin in this part of the canal shows a corresponding condition of hyperæmia and infiltration, at times associated with desquamation. On the whole, this is a rare pathological condition—indeed, much more rare at the present time than it was twenty years ago, when a large percentage of the acute cases of middle-ear inflammation were allowed to get well as best they might under the fickle and uncertain operation of natural processes.

Physical Characteristics and Course.—A diffuse inflammation of the external auditory canal presents itself under a variety of forms. The simplest of these is that which is characterized by a diffuse redness and swelling of the skin lining the canal. These alterations may be limited to a fairly well-defined area or patch; or they may extend over one-half of the canal—either the entire cartilaginous or the entire osseous portion (including or excluding the outer surface of the tympanic membrane); or, finally, they may involve the entire canal. In one series of cases, the redness and swelling—accompanied or not, as the case may be, by some secretion from the inflamed skin—constitute the only recognizable alterations. In another series, the inflamed skin may show a strong proliferative tendency, which manifests itself by the development of granulation-tissue, and which, in rare cases, is associated with inflammation of the adjacent bone structures. And, finally, in a third series, a desquamative process may constitute the most striking feature of the disease.

A diffuse inflammation of the external auditory canal is pre-eminently a chronic affection; and even when it seems to have disappeared, either spontaneously or under the employment of suitable therapeutic measures, it is very apt to return again. The most favorable cases, in this respect, are those of children under three or four years of age, in whom some error of diet has brought into existence a most active diffuse inflammation of one or both external auditory canals, involving every portion of the canal, and accompanied by an abundant purulent secretion. The correction of the dietetic error, and perhaps only a single application of a fairly strong silver-nitrate solution to the granulating walls of the inflamed canal, will almost always suffice to put an end to the disease. In older individuals it is occasionally possible to secure equally prompt results from treatment; but in the vast majority of instances no such brilliant cures need be expected.

A characteristic pathological change in all these local eczematous inflammations is a vasomotor paresis—an inability of the muscle cells which envelop these small blood-vessels to contract, and by so doing to prevent the watery elements of the blood which circulates in these channels from escaping into the surrounding tissues. Hence the beneficial influence exerted by nitrate of silver, which, when properly applied, acts as a strong vasomotor stimulant. On the other hand, when this condition of vasomotor paresis persists, certain further pathological changes are likely to take place in the skin of the external auditory canal. Infiltration of the tissues surrounding the vessels and exudation upon the free surface of the skin are the changes which ordinarily first follow the condition of paresis of the blood-vessels. But, later, an actual proliferation of the epithelial and connective-tissue elements is apt to show itself. Desquamation probably represents the mildest degree of such proliferation, while ulceration and the formation of granulation-tissue stand for the highest.

The influences which produce an outbreak of eczematous inflammation in the external auditory canal do not always operate continuously or with the same degree of force. Thus, for example, in a fairly large percentage of cases, the ear gives no trouble whatever during the greater part of the day, and then under some slight provocation—intense mental application, the warmth of the pillow, etc.—a decided sense of heat will be developed in the affected parts, and there will be a watery discharge from the canal. The following case illustrates this point:

Case XIII.—*Circumscribed eczematous inflammation of the external auditory canal, accompanied by a distressing sense of heat in the ear.*

The patient, a lady about forty years of age, and a sufferer from some form of uterine disease, stated that during the preceding two or three weeks she had experienced every night, whenever she lay upon the right side, a distressing sense of heat in the right ear, followed by a slight watery discharge. As she could not lie upon the left side for any great length of time, the symptom complained of interfered seriously with her night's rest. During the daytime she was propped up in bed, and then she experienced absolutely no discomfort in the ear. There was no tinnitus and no impairment of the hearing. On examination with the speculum I found a limited and very small area of barely recognizable redness of the skin, on the floor of the canal, about midway between the external orifice and the membrana tympani. I could discover no other lesions in any part of the ear. On the opposite side of the neck and on the forearms were three small areas of what seemed to be a circumscribed eczema. I prescribed the use of a hair instead of a feather pillow, and advised her to fill the external auditory canal two or three times daily with a fluid preparation which was sold in the shops at that time under the name of "Bacon's Canadian Emollient," and which seems to have been derived—to judge from its agreeable odor—from Canada balsam. I also suggested the free use, internally, of lithia water. In a very few days she was relieved entirely of the distressing nocturnal heat and discharge, and the area of redness in the meatus entirely disappeared.

Diagnosis.—There is no difficulty whatever in recognizing the red, swollen, and perhaps moist condition of the osseous portion of the auditory canal. We can then say positively that a diffuse otitis externa exists. If the drum-membrane presents at the same time a normal, or at least a non-inflamed condition, we can, with considerable confidence, make the diagnosis of a *primary* inflammation of the osseous portion of the canal. The question of its *acute* or *chronic* nature can only be determined after we have heard the history of the case; and even then we may readily be misled, as patients are often not aware of the existence of a chronic or subacute otitis externa diffusa until their attention is called to it by the pain or sense of fulness caused by an acute exacerbation of the inflammation. The point, however, around which the greatest interest centres, is the condition of the middle ear in many of these cases. The drum-membrane being red and swollen, we naturally ask ourselves the question: Is the diffuse inflammation of the auditory canal merely an extension of that which is apparently going on in the middle ear? or, Is the membrana tympani, by virtue of the intimate relations existing between its outer layer and the skin of the osseous portion of the canal, involved secondarily in an inflammation which really began in this latter region? This question, as I have already

stated, cannot be determined by inspection alone. We must test the hearing, examine the condition of the naso-pharyngeal mucous membrane, and ascertain, by auscultation, during the act of inflation, the condition of the middle ear and Eustachian tube. If there is comparatively little disturbance of the hearing, if there is no evidence of an acute naso-pharyngeal catarrh, and if the air enters the tympanic cavity freely and without râles or crackling sounds, we are fairly justified in pronouncing the disease an acute primary diffuse inflammation of the external auditory canal.

The different forms of diffuse inflammation of the external auditory canal are easily distinguishable from one another. For therapeutic purposes, however, it is sufficient to make the following two distinctions: those cases in which the local inflammation can most plausibly be explained upon the assumption of some constitutional disturbance like goutiness or lithæmia; and those in which this persistent diffuse dermatitis is rather the result of an underlying subacute osteitis (itself the product of a former or of a still present middle-ear inflammation). The engrafting of a parasitic vegetable growth upon an ordinary eczematous or gouty inflammation of the skin of the auditory canal does not call for any fundamental alteration of the treatment, and consequently the failure to accurately recognize the presence of such vegetable parasites does not entail any serious consequences for the patient. It is only in cases like that of the sailor (Case XX.) that some difficulty might be experienced in recognizing the true condition of things in the ear. In this particular case the dry, hard, and comparatively smooth cul-de-sac at the inner end of the auditory canal would be very likely, at first sight, to be taken for a greatly thickened drum-membrane. The correct interpretation of the condition observed suggested itself at once as soon as the curette was used. At almost all points the hardened mass that occupied the inner end of the meatus, merged, without any noticeable line of demarcation, into the neighboring skin of the canal. In one or two places, however, a free edge of thin cuticle indicated where the line of separation occurred. The curette was applied at these points, and, with a little cautious dissecting, the fact was ascertained that the thin, free edge of cuticle constantly grew thicker as the dissection was continued farther and farther inward. The desquamative nature of the affection was thus established beyond a reasonable doubt.

In those rare cases in which a gouty inflammation begins in the skin of the external auditory canal and slowly spreads to the sur-

rounding bone structures, the task of making a correct diagnosis may prove to be exceedingly difficult. In Case XIX., for example, I believe that anybody who had not watched the case from the beginning, as I had done, would have been led to make the diagnosis of mastoid disease, of middle ear origin. Indeed, I was more than once tempted to make this diagnosis myself, in the belief that I had perhaps overlooked some of the pathological phenomena as the disease progressed. In another gouty case, which has come under my observation since the manuscript of this book was placed in the printer's hands, I found the adjacent bony structures of the mastoid process involved to such a degree and in such a peculiar manner that I at first felt strongly disposed to make the diagnosis of sarcoma of the cutaneous external auditory canal and temporal bone.

Prognosis.—A diffuse inflammation of the external auditory canal may give rise to considerable discomfort, but it rarely, if ever, threatens serious consequences. So far as life is concerned, therefore, a favorable prognosis may always be given in this class of cases. But when we are called to predict the probable duration of the disease in any given case, it will be found wise to express an opinion very guardedly. This is especially necessary in the markedly desquamative cases of long standing; the outlook here being at best very uncertain. In the more recent cases, and especially in those in which the desquamative impulse is less marked, we may encourage the patient to expect at least decided amelioration. Relapses, however, are very common. In the proliferative (gouty) cases, and especially in those which are accompanied by disease of the neighboring bone, very great caution must be exercised in predicting what will be the ultimate outcome of the trouble.

Treatment.—The local management of this disease must vary according to the stage or condition in which it happens to be at the time. Thus, for example, if pain is a prominent symptom—which is only rarely the case—the warm douche will be found very effective in allaying it. If a fluid secretion has begun to escape from the canal, the proper procedure is to employ one of the astringents; and of these, the best, in my experience, is easily silver nitrate. This remedy should be employed, under these circumstances, in the form of solutions of different strengths. Before applying such a solution to the inflamed canal, it is advisable first to cleanse the latter thoroughly with warm water; then afterward, by means of a dropper, the silver-nitrate solution, of the desired strength, may be introduced into the canal. If the skin is unbroken, a strength of

120 grains to the ounce will answer well; but if the tissues are soft and moist—that is, if they are already beginning to granulate—one of 60 grains to the ounce will be found sufficiently strong. As soon as the solution causes a distinct sensation of warmth, or a stinging sensation, it should all be removed from the canal by means of a syringe and warm water. An ointment of a non-stimulating character—such, for example, as boric acid (10 or 15 grains) and vaseline (℥ i.)—should then be applied freely to the walls of the canal; and the patient should be instructed to use the same ointment two or three times a day at home. After two or three days have gone by it will be possible to determine just how much or how little good has been accomplished by the application of the silver solution. According to the nature of this result, a repetition of the procedure may or may not seem desirable. In some instances it soon becomes apparent that this or any other stimulating application only serves to increase the irritation in the auditory canal. When this proves to be the case, all active interference with the seat of inflammation should be abandoned, and only soothing measures (warm douching, application of ointments) should be employed. It is in cases like this that we must place our chief dependence upon the constitutional treatment (diet; exercise; Carlsbad salts, etc.).

When a case is complicated by the development of the aspergillus fungus, the treatment requires to be modified to only a slight degree. The strong silver solutions do good work in destroying those portions of the fungus which penetrate into the living tissues, and the free use of one of the antiseptic powders now so much employed in otological work (aristol, nosophen, dermatol, etc.) will prevent any new germs from securing a foothold. I have had very little personal experience with absolute alcohol as a germicidal remedy in cases of this nature, and am therefore unable to say very much about its virtues. It is well spoken of, however, and is a perfectly safe remedy to employ. On the other hand, solutions of carbolic acid, although effective in destroying the germs, may very easily cause considerable irritation of the skin of the auditory canal. The two other remedies named are therefore to be preferred as germicides.

As regards the treatment of the various unusual pathological conditions which are sometimes encountered, especially in the later stages of a diffuse inflammation of the external auditory canal, I must refer the reader to the next section, in which I have reported some of these exceptional cases.

ILLUSTRATIVE CASES.

The following brief histories of cases will serve to illustrate at least some of the varying forms in which a diffuse inflammation of the external auditory canal appears:

CASE XIV.—*Chronic eczematous inflammation of the external auditory canal, of gouty origin.*

A gentleman, about thirty years of age, and apparently in robust health, consulted me, in the spring of 1882, on account of an uncomfortable affection of both his ears. The symptoms were: a distressing irritation in both canals, occasional pain, intermittent watery discharge, and decided fluctuations in the hearing-power. Generally, he could hear perfectly well, but often, for two or three days at a time, the ears would seem to close, and then he would experience considerable difficulty in hearing. On examination, I found both auricles eczematous and the external auditory canals very much swollen. The semi-raw surface of the skin, in the latter regions, was bathed with a thin, purulent secretion. Near the tympanic membranes there seemed to be an abundance of room, but farther outward the calibre was reduced to the size of a steel knitting-needle. The cause of the trouble was not far to seek. In the first place, his father was a great sufferer from gout; and in the next place, he himself was very fond of good living, and was well known among his friends as an authority on the places where the best brew of German beer or the best Bass' ale could be obtained. Furthermore, he habitually abstained from anything like vigorous physical exercise.

I gave him momentary relief from the worst aspects of his trouble by the local application of a strong silver-nitrate solution (120 grains to the ounce), and I spoke to him very earnestly in regard to the important topics of diet and physical exercise.

During the past fifteen years I have seen this patient repeatedly. His ears are to-day in precisely the same condition as they were in 1882—no better, no worse. Strange as it may seem, the tympanic cavities appear to have escaped entirely. At all events, when the outer passages are clear he seems to hear as well as anybody. Even an intercurrent severe attack of knee-joint inflammation—presumably gouty—has not accomplished any more than have my repeated sermons in inducing him to alter his habits in respect to eating and taking exercise.

Comments.—The preceding case is a well-marked example of a class of cases with which every aural surgeon in private practice is perfectly familiar. It is one in which local treatment counts for very little; while, on the other hand, the adoption of a more rational mode of life by the patient may be confidently trusted to effect a prompt improvement, if not a decisive cure.

CASE XV.—*Diffuse eczematous inflammation of the external auditory canal, of gouty origin; an apparent cure from the local application of silver nitrate in solution; several relapses.*

The patient, a lady, about twenty years of age, and in excellent general condition, consulted me in July, 1871, on account of a constant watery discharge from both ears. She said that during the previous month of March she had passed through an attack of scarlet fever, and that during convalescence she had experienced pain in both ears, followed by a watery discharge which had continued ever since. There had been no appreciable deafness, and no tinnitus. Once or twice the discharge had ceased entirely for a few days. On examination, I found the inner half of the meatus, on both sides, reduced in size by the swollen condition of its lining membrane. The latter was also moderately red. The manubrial and peripheral portions of the membrana tympani were congested, and the intervening portions presented a soaked and opaque appearance. There was very little fluid in the canals—barely enough to moisten them. The ticking of a watch was heard at a distance of four feet, on both sides. The Eustachian tubes were freely pervious to air, and there was no noticeable catarrhal irritation of the naso-pharynx. Instillations of a solution of sulphate of zinc were prescribed. Four weeks later the patient returned to the city and reported that the discharge had rather increased than diminished under the treatment which I had advised. On examination, I found that no material change had taken place in the condition of the canals. I carefully wiped away all moisture from the inflamed surfaces and then filled the canal with a strong solution of nitrate of silver (120 grains to the ounce), the patient's head being turned well over toward the opposite side. As soon as she felt a distinct sensation of warmth in the ear, I removed the solution from the meatus by syringing it out with warm water. Both canals were treated in this manner Two weeks later I saw the patient for the third time. No discharge whatever had been observed by her during the interval, and the ears then felt perfectly natural in every respect.

On the 11th of September, 1878—that is, seven years later—she again came to see me with regard to her ears. According to her statement there had been a discharge from both canals since the early part of the preceding July. There had been no deafness, and the parts presented very nearly the same appearance as they had seven years previously. After drying the canals thoroughly, I applied powdered iodoform to the inflamed surfaces, and instructed the patient not to syringe the ears unless a discharge showed itself at the outer orifice. On the 14th I found the ears in precisely the same condition as on the 11th, and the patient had not observed any diminution in the activity of the discharge. I again dried the canals, and applied powdered burned alum instead of iodoform. On September 20th, very little, if any, improvement having taken place in the mean time, I mopped out the inner half of each canal with a saturated solution of nitrate of silver; the parts being kept thoroughly moistened with the solution until a distinct sensation of warmth was experienced by the patient. On the 25th of September, I found the walls of the canals and the drum-membranes perfectly dry and free from noticeable redness.

On the 25th of October she came again to see me, as her ears felt full and

the discharge had returned. I again used the saturated solution of nitrate of silver, but allowed it to remain longer (about five minutes) in contact with the inflamed parts. Three days later she reported that she had experienced some pain after the last application of the silver solution, but that on the following day her ears again felt quite natural, and the discharge had not returned since. As the patient never returned after this visit, I infer that the cure proved to be permanent.

In this and similar cases, which passed under my observation about twenty years ago, I looked upon the diseased condition of the skin as something purely local in character, and failed to recognize—what I now believe to be the truth—that this limited inflammation is an expression of some general disturbance of nutrition, or what is conveniently termed *latent gout*. As a consequence, relapses were more common in those days than they are now, when appropriate measures are adopted to correct, at least in some degree, the faulty nutritional processes.

Case XVI.—*Circumscribed areas of eczema in the external auditory canal, and one with sharply defined limits on the membrana tympani.*

The patient, a lady of about fifty years of age, consulted me during the autumn of 1896 on account of the following symptoms: tinnitus, slight impairment of the hearing, and vertigo, together with sleeplessness, anorexia, and "rheumatic" pains in different parts of the body (hands, shoulders, etc.). In both external auditory canals I found circumscribed areas of eczema, and in one ear the posterior half of the membrana tympani was the seat of an oblong, dirty-looking, grayish scab, sharply limited in its outlines, and of only slight thickness. By the employment of a small and very delicately constructed ring-shaped curette this scab was readily removed, and the base upon which it rested was found to present a feebly granulating, moist surface. Under a course of anti-gouty treatment the subjective symptoms nearly all disappeared, but the patch on the membrana tympani persisted for a period of several weeks, despite the fact that I applied a strong solution of silver nitrate to the granulating surface on one or two different occasions. Finally, this lesion disappeared completely (March 19, 1897), leaving the tympanic membrane perfectly smooth and pale.

The following case, which belongs in this category, was reported by me in 1891,[1] and since that date I have seen another which resembled it closely in all essential respects.

Case XVII.—*An eczematous inflammation of the external auditory canal, with a marked proliferative tendency.*

In this patient, an adult, I found the region above and behind the short process of the hammer, and the larger part of the posterior half of the drum-membrane, converted into a mass of tolerably firm granulation-tissue. At

[1] International Clinics, April, 1891.

its lower and posterior border the mass represented little more than a red, succulent, very much thickened tympanic membrane, while at and around the short process the mass projected sufficiently for me to remove a portion of it with the snare. The outer canal elsewhere was only mildly inflamed, and contained but a small quantity of purulent discharge. The hearing for voice sounds was scarcely at all affected. A search was made for a fistulous opening in the vicinity of Shrapnell's membrane, but no trace of one could be found. The previous history of the case pointed rather to chronic eczema of the external auditory canal.

By the aid of the snare at first, and of chromic acid afterward, I soon succeeded in destroying all the exuberant tissue in the region of Shrapnell's membrane; the patient in the mean time employing faithfully Angelo's car-douche, with warm water, two or three times a day. In less than three weeks the tympanic membrane and the surrounding regions had very nearly resumed their natural appearance, and I question whether anybody who might then have seen the ear for the first time would have believed it possible that such gross lesions as I have described above were present in this ear so short a time previously. In only one material respect did the tympanic membrane show a departure from the normal condition: an elongated oval patch, of a silver-grayish color and sharply defined borders, occupied the greater part of the posterior half of the membrane. By suitable manipulations with the tip of the slender silver probe, it was ascertained that the thickening was seemingly confined to the outer surface of the membrana tympani, and that it was perfectly flexible and dry. A patch of psoriasis is the only skin lesion which occurs to my mind as presenting a strong resemblance to the one observed in the present case.

But the picture presented to the eye may be materially modified by the action of other factors, such as pressure upon the inflamed parts, damming up of the products of the inflammation by an obstructing mass of cerumen, etc. The following case, which I saw about twenty years ago, illustrates this point, and also suggests the probability of our being able to demonstrate, at some future day, that even large deposits of chalky material (urates) may occur in the external auditory canal.

Case XVIII.— *Inflammation of the external auditory canal, associated with the formation of a mass of chalky material, and with a small area of superficial bone caries; presumably of gouty origin; complete cure.*

The patient, a very intelligent lady, thirty-eight years old, and in fairly good health, stated that during the previous five weeks she had experienced at times quite severe pain in the right ear. There had been no discharge and very little disturbance of the hearing, so far as general conversation was concerned. Her regular medical adviser had attributed the painful affection of the ear to impacted cerumen, and had syringed the canal very thoroughly with tepid water, but without beneficial effects. On examination, I found the orifice of the right auditory canal tender on pressure, and obstructed by the presence of a moderately large mass of granulation-tissue springing from

the mouth of what seemed to be a furuncular pocket. Beyond this fleshy mass, which I at once removed with the snare, the canal was found to be tightly plugged with a whitish mass which felt as hard as chalk. By means of the curette and forceps, I was able to break down and remove piecemeal the entire mass. It presented, throughout, every appearance of being a chalky substance, and probably represented a calcareous transformation of pus that had first undergone cheesy degeneration.[1] The inner end of the mass extended to within a few millimetres of the drum-membrane. After it had been entirely removed I found that the only lesion in the osseous part of the canal, beyond a moderate degree of redness and swelling, was a circumscribed ulcer, situated posteriorly and superiorly not far from the junction of the osseous with the cartilaginous portion. On exploration with the probe I ascertained that denuded bone surface constituted the base of the ulcer. The membrana tympani appeared to be perfectly normal.

An examination of the patient's left ear, which she had always supposed to be healthy in every respect, revealed the existence of a small, pale, succulent polypoid mass, springing from the posterior wall of the osseous part of the canal, close to the drum-membrane. The secretion from this mass was so scanty that no fluid could be seen in the canal except in the immediate neighborhood of the growth. Exploration with the probe showed that the polypus was simply a superficial outgrowth, not connected with any demonstrable disease of the bone. The membrana tympani appeared to be perfectly natural, and there was no appreciable redness or swelling of the walls of the canal in the vicinity of the growth.

I questioned the patient carefully with regard to the condition of her ears in the past, but could elicit no information that threw any light upon the peculiar lesions found. The pain of which she had complained during the previous five weeks was evidently due to the development of a furuncle near the outer orifice, and the mass of granulation-tissue found in this location was simply the effect of continued irritation from some source or other. These lesions were evidently of comparatively recent date. The presence of the calcareous mass in the right meatus pointed clearly to a discharge of much earlier date; but it was not so easy a matter to define the location from which this discharge came. The middle ear, for instance, could safely be excluded as a source of the pus, as the patient was positive that she had never experienced any pain or discomfort in the right ear until recently, and also because the condition of the drum-membrane, as found after the chalky mass had been removed, showed no trace of any recent or former inflammation of the middle ear. The discharge, therefore, in all probability, came from the auditory canal. The patient, however, it will be remembered, stated distinctly that she had never observed a discharge from either ear. In explanation of this apparently contradictory state of things, the assumption is certainly warranted that in the outer portion of the canal there must have been some obstacle which prevented the escape of pus secreted in the inner portion. Impacted

[1] The present report of this case, it should be remembered, is in the same words which I employed when I first published it in 1880. Further on, it will be seen that I no longer entertain the view here put forward in regard to the mode of development of this chalky mass.

cerumen would present such an obstacle, and, by greatly diminishing the rate of evaporation which would take place in the pus under ordinary circumstances (*i.e.*, in an unobstructed meatus), would favor its gradual accumulation and slow transformation, first into a cheesy, and then into a chalky mass. No cerumen, it is true, was found in the canal at the time when I examined it; but it is more than probable that the thorough syringing which the ear had received at the hands of the attending physician had removed all that was there.

The question relating to the exact source of this assumed discharge, whether the latter came from the circumscribed ulcer described above, or from some previous diffuse inflammation of which this ulcer was the last remaining trace, is one which I am unable to answer.

With regard to the treatment and subsequent progress of the case, there is very little of interest to communicate. Both ulcers healed slowly under the use of nitrate of silver (in the form of a bead) and (later) powdered iodoform. A dry eczema, affecting the orifices of the canals, continued to be present for several weeks after the ulcers had healed, and then finally disappeared. As late as during the summer of 1879 I found both canals still quite natural in appearance.

Comments.—In recent years I have been disposed to adopt an entirely different interpretation of the pathology of the lesions described in the foregoing record. I think that it is highly probable that the ulceration of the osseous portion of the right external auditory canal was a distinctly gouty lesion, such as is seen in the vicinity of certain articulations in the more severe forms of the disease, and that the chalky material which filled the canal came from this source. This lady's father and sister had both been sufferers from gout in a pronounced form, and, as will be noticed in the record, both canals showed evidences of eczema for a certain length of time after the healing of the ulcers. These two facts add strength to the hypothesis that in this particular case the main underlying cause of the peculiar lesions observed in the ears was a well-marked gouty diathesis, active only during a limited period of time.

To the minds of some it may seem strange that the chalky material observed in this case should have been found lying free in the external auditory canal, whereas the gouty tophi observed in other parts of the body are always surrounded by an envelope of skin. This difference may probably be explained in the following manner: In the neighborhood of the small joints of the fingers the skin is very strong and elastic, and only loosely adherent to the underlying fibrous structures. The chalky urates may, therefore, easily accumulate at these points in quite large quantity without rupturing the skin. In the external auditory canal, on the other hand, or more

particularly in its osseous portion, the skin is extremely thin and is quite firmly attached to the underlying bone. It could therefore scarcely serve as a sac for holding any such mass of chalky material as was found in the present case.

It may also seem strange to some that these chalky urates—if such, indeed, they were—should not have escaped from the external auditory canal, instead of remaining there, and gradually forming a solid mass of considerable size. The explanation which seems to me to be the most plausible is the one which I have already given above, viz., that a mass of impacted cerumen doubtless occupied the outer half of the canal at the time when the more active gouty outbreak occurred, and the presence of this obstacle prevented the escape of the solid portions of whatever secretions may have been poured out into the deeper parts of the canal.[1] One can easily understand how, under these favoring conditions, the separate particles of solid matter might, in the course of time, become pressed together into a fairly hard mass, such as was found in the present case.

In the cases of which I have thus far given brief accounts, the lesions have been limited in extent, and have not, with, perhaps, a single exception (Case XVIII.), involved the underlying bone structures. In the following case[2] the gouty influence was so strong and so persisting that both the skin and the underlying bone became involved in the inflammation.

Case XIX.—*Diffuse inflammation of both external auditory canals, at first presenting the characters of a simple and mild eczema, but afterward manifesting a decided proliferative tendency, and eventually being accompanied by well-marked osteitis of the neighboring bone structures; duration of the disease, nearly eight years; death from pneumonia.*

The patient, a rather stout lady, about thirty-eight years of age, consulted me on October 6, 1887, for what seemed to be a subacute catarrhal inflammation of both middle ears, accompanied by almost constant tinnitus, and by an unpleasant sense of fulness in the ears. From the right ear there had been a slight discharge, and the sensation of itching in this ear had at times been almost intolerable. The patient was then also suffering, and had been

[1] This lady's regular medical adviser was in the habit of using the speculum and reflector in examinations of the ear; and, as he first pronounced the condition to be one of impacted cerumen, I think we are warranted in concluding that he based this first diagnosis upon the fact that he actually saw such a mass in the canal.

[2] Reported in part in the International Clinics, April, 1891. Lippincott Company, Philadelphia.

for several years, from well-marked diabetes insipidus. In general conversation with her I observed no evidences of impaired hearing, but on testing this function with the watch, which was a loud ticker, I found that she could hear it at a distance of only two inches on the left side and three on the right. I inquired into her habits as regards eating and exercise, and learned that she practically took no outdoor exercise whatever, and yet she had not modified her diet in the slightest degree.

An examination of the ears revealed the existence of an eczematous inflammation in both external auditory canals. The tympanic membranes showed no noticeable alterations.

I prescribed a restricted diet, more physical exercise, the use of the douche with warm water in the right ear, local applications of the oil of cade and vaseline in both ears, spraying the nasal passages with listerin and water, biweekly applications of a silver-nitrate solution to the vault of the pharynx, and inflations of the middle ears according to Politzer's method. Very little, if any, improvement followed this plan of treatment. My impression is, however, that the advice about diet and exercise was not followed.

From October, 1887, to January, 1890, I saw the patient at irregular intervals. The memoranda in my case-book simply show a record of ups and downs, with no special tendency on the part of the disease to grow materially worse. The discharge from the right ear, although scanty, was almost constant. On the 31st of January, however, she began to suffer from the first of a series of boils in the right external auditory canal. All sorts of local remedies—Hebra's diachylon ointment, silver-nitrate solutions of various strengths, powdered boric acid, etc., were tried, but without any beneficial effect. The sulphide of calcium, administered in small doses, seemed to do a little good, but yet not enough to warrant us in continuing its use. In the mean time the left ear had also begun to discharge, owing to the presence of a diffuse inflammation of the skin lining the inner half of the canal.

On the 14th of May I found, on the lower wall of the right meatus, not far from the outer orifice, a circumscribed patch of granulation-tissue, which I touched freely with a strong (twenty-four per cent) silver-nitrate solution. This application caused the ulcer to heal promptly, and for about one month afterward the ear gave her very little trouble. The left ear had also, by this time, resumed a fairly quiet condition.

On the 16th of June, 1890, when I saw her for the last time before she went away to the country for the summer, there was a little tenderness at the orifice of the right canal, as if a fresh furuncle were developing; but in all other respects both ears seemed to be as free from irritation as they had been at any previous time for several months past.

On the 6th of October, when she returned from the country, I found the left external auditory canal in very much the same condition as I had seen it on the 16th of June; that is, the canal was a trifle narrower than it should be, and there was more fulness of the blood-vessels than is normal. On the right side, however, the condition of the auditory canal had become very much worse. A polypoid growth, about the size of a small pea, occupied the orifice of the canal. By the aid of a bent probe it was ascertained that this growth sprang from the edge of an opening in the skin, at the bottom of which denuded bone could be felt. After the removal of this polypus with the

snare, it was seen that the cutaneous walls of this deeper portion of the canal had been converted into granulation-tissue which completely obliterated the calibre of the meatus. Neither on this nor on any subsequent occasion was I able to determine accurately whether any portion of the cutaneous lining of the canal had escaped this conversion into granulation-tissue. Along the upper wall, down to a point close to the tympanic membrane, the skin seemed still to retain a smooth, firm surface, but I was not able to ascertain positively whether such was the fact or not. The lack of space and the facility with which such tissues bleed when manipulated are almost insurmountable obstacles in the way of a satisfactory examination. The skin covering the mastoid process was red, swollen, and tender, and the auricle was dislocated slightly forward. There was comparatively little pain at this time; no more, in fact, than would be expected from an inflammation of the surface tissues.

Although I inquired carefully into what had taken place during the interval between June 16th, when I last examined the right ear, and the date of the visit to which I have just referred, I failed to discover any facts which would warrant the belief that she was suffering from inflammation of the mastoid process of middle-ear origin, that is, an inflammation which had developed more or less independently of the long-standing disease in the external auditory canal. During this period she had experienced, it is true, a great deal of pain in and around the ear, but it could all readily have come from the presence of a deep-seated furuncle and from the rather vigorous efforts made by the different medical men whom she consulted to effect healing of the furuncular cavity.

I took her temperature (under the tongue), and found it to be normal; and I might add that on no subsequent occasion did it rise above 99.5° F.

During the next three weeks I made various attempts to remove, or materially to reduce in bulk, the granulation-tissue in the right canal, but at most I accomplished very little. On the 31st of October, therefore, she was put under the influence of ether, and I proceeded to remove, partly by means of suitably curved knives and partly by the aid of Hinton's fenestrated forceps, the larger part of the obstructing mass. In this way I obtained a clear calibre, from the tympanic membrane outward, of fully five millimetres in diameter. As the bony floor of the canal seemed to be rougher than natural, I scraped it with a sharp-edged spoon. As a last step I insufflated powdered iodoform and sealed up the orifice of the canal lightly with cotton.

Three days later I found that no unpleasant reaction had followed the operation, and that the canal still retained a calibre of about four millimetres in diameter. In the hope of stimulating these relaxed tissues to contract and resume the firm condition of natural skin, I injected into the meatus, by means of a slender glass pipette, a six-per-cent (30 grains to the ounce) solution of silver nitrate. The result of this procedure was directly the opposite of that which I had expected; at the end of about forty-eight hours I found the calibre of the canal completely obliterated.

By this time I had become thoroughly convinced that I was contending with forces which I could not possibly hope to overcome by mere local interference, and I expressed the opinion that it would be useless to make any further active efforts to benefit the ear in this manner; although variations in

the local conditions might call for some slight therapeutic interference from time to time.

During the early part of November the patient was obliged to keep her bed on account of a rather severe attack of arthritis of the right knee. While this was in progress the pain and swelling in the mastoid region became more marked; but under the influence of frequent poulticing, with hot flaxseed-meal poultices, the swelling and tenderness rapidly diminished and the pain became insignificant.

About one month later (early in December) I was confident that a certain amount of shrinking and a diminution in the hyperæmia had taken place in the granulating walls of the right external auditory canal. The discharge had always been scanty, and this remained unchanged. There were but two things to which I could attribute this change for the better, and these were the increased amount of outdoor exercise which her attending physician had at last succeeded in inducing the patient to take, and the greatly restricted diet which he had prescribed and which she had faithfully adopted. She had even, at his suggestion, dismissed her maid, in order that she might be forced to take many steps which ordinarily had been taken for her by this person, who had heretofore been in constant attendance.

While the right ear, as I have said, showed only to a slight degree the beneficial effects of the judicious treatment inaugurated by the regular medical attendant, the left responded in a much more decided fashion. It was during the month of October that this ear had begun to grow perceptibly worse. The calibre of the canal became smaller and smaller, and the inflamed walls seemed to be taking on the characteristics of granulation-tissue, just as had occurred long before in the right canal. At intervals of a week or ten days a furuncle would appear on the lower wall of the canal near the orifice, break, and then heal up, to be followed in due time by a fresh one at or close to the same spot. The discharge was constant, but rather scanty in amount. Solutions of acetate of lead and of nitrate of silver of different strengths, powdered iodoform and boric acid, and a variety of ointments were tried in succession, but they all failed to produce any beneficial effects. As a matter of fact, they seemed rather to make the ear worse. All through this period the ear was decidedly painful, at times even more so than the right, which certainly seemed to be the more profoundly affected of the two. Then, as I have already stated, there came a decided change for the better in the condition of this left ear, a change which was certainly not due to any local treatment, but could rightfully be attributed to the restricted diet and the increased muscular activity alone. The improvement referred to manifested itself in the following ways: the formation of furuncles ceased, the swelling and discharge diminished, and the pain practically disappeared. By the 13th of December the calibre of this left canal had so increased in size that I was able to obtain a fairly good view of the tympanic membrane.

From this time onward I saw the patient not oftener than once or twice a year; the last time in 1894. Her left ear gave her very little trouble during this period, but the right one never returned to anything like a normal state. The skin of this canal remained in a granulating condition, and the hearing, which at no time had been seriously impaired, varied from time to time according to the variations in the degree of swelling of the granulating skin

The mastoid region continued to be somewhat tender when pressed upon, and there was also more or less pain in this region, but never enough to interfere with her sleep.

Death occurred in 1895, apparently from pneumonia. So far as I could learn, no material change had taken place in the condition of her ears during this last year of her life.

Comments.—I can recall but one other case in which, from an apparently simple eczema of the skin lining the external auditory canal, there gradually developed a veritable mastoid osteitis, involving the more superficial portions of this bone. I entertained doubts for a long time in regard to the correctness of my diagnosis, and was more than once tempted to explore the interior of the mastoid process. At the end of eight or ten months of unsuccessful treatment I induced the patient to visit Homburg, near Frankfort, in Germany. She followed, for a period of six or eight weeks, the course of treatment which is commonly prescribed at these springs, and which is essentially the same as that recommended at Carlsbad, and she returned to New York seemingly cured of her disease.

The preceding examples may be considered as illustrating sufficiently the different phases manifested by a gouty inflammation of the external meatus. In some future case there will doubtless be afforded an opportunity of learning to just what extent the gouty disintegration of bone tissue may involve the deeper parts of the mastoid process.[1]

Desquamative Type of Inflammation.—A certain amount of desquamation almost always takes place in every case of acute diffuse inflammation of the auditory canal. No special importance is attached to the phenomenon, and it passes for one of the regular manifestations of the disease. In those cases, however, to which the term "desquamative" should be restricted, the canal is often found tightly filled with layer upon layer of epithelium. We remove these products, and clean the canal thoroughly, but in a comparatively short time we find it again filled tightly with the same sort of laminated sheets of epithelium. Some of these cases have been under my observation now for a period of several years, but the desquamative tendency is apparently as strong to-day as it was when they were first seen. Furthermore, I have not observed the slightest disposition in any of these cases to change their peculiar desquamative type for one in which the secretion of pus is the predominant feature. It seems to me, therefore, that this form of

[1] See remarks near the top of page 126.

diffuse inflammation of the auditory canal is better entitled to recognition as a separate disease than is any other form of diffuse inflammation of the canal. In some of these cases the underlying etiological factor is simply a gouty diathesis, but in others the latter adds its influence to that of an earlier underlying osteitis (presumably of middle-ear origin). In complex cases like this it is not always possible to determine just how far each of these factors participates in the perpetuation of the desquamative process. As regards the beginning of the latter process, I may say that I have never seen a case in which a perfectly healthy ear became the seat of changes, which I should be justified—in the light of the subsequent progress of the case—in considering as the early manifestations of this disease, and I am therefore unable to describe the conditions which characterize these earlier stages. When the canal has become filled with the exfoliated epithelium, the resulting deafness or discomfort leads the patient to consult a physician, and it is in this advanced stage, therefore, that we first see this form of disease. Occasionally we see cases of diffuse inflammation of the canal which run an acute course, and which are characterized by the exfoliation of very large quantities of moist epithelium in sheets of perfect whiteness. In these cases, however, the canal returns to a normal condition after the subsidence of the acute symptoms, and we can therefore hardly consider the pathological picture presented as that of a commencing (chronic) desquamative inflammation of this region. In an acute desquamative process of this character the causative agency is doubtless an invasion of the skin at this point by bacteria (presumably the streptococcus).

The simpler forms of the disease are undoubtedly of common occurrence, and will be found grouped, by many authors, among the cases of impacted cerumen. The appearances presented to the eye, before any efforts have been made to remove the obstructing mass, are very often those of impacted cerumen pure and simple. As we proceed to dissect out the mass, we find that beyond the outer portion, consisting of cerumen, lies a tough, leathery mass, composed of laminated epithelial sheets at the periphery, and of a conglomeration of dried pus, variously shaped masses of epithelium, crystals of cholesterin, cerumen, etc., in the centre. When we separate the outermost layer from the underlying skin, we find the latter in various stages of inflammation. In the milder cases, the skin will simply present a vivid red color; in the severe ones I have found even well-marked ulceration. In many of

these cases the drum-membrane seems to take no part in the desquamative process, which may be confined to the outer half or two-thirds of the osseous portion of the canal, and the inner third of the cartilaginous portion. In one of the cases of which I kept a careful record, the region of vivid redness ended quite abruptly at a distance of about five or six millimetres from the posterior and inferior margin of the drum-membrane. In another case I found the desquamative process limited to a boat-shaped depression in the lower wall of the osseous portion of the canal. No satisfactory history could be obtained in this case, but it seemed reasonably clear that at some time in the past, probably in the man's boyhood, caries and exfoliation of quite a large portion of the lower bony wall of the canal had taken place. The chronic desquamative inflammation of the skin lining this excavation had caused the patient no pain or discomfort until the steadily increasing laminated mass of epithelium, no longer finding room for itself in the excavation, began to exert pressure. Then the patient experienced moderate pain in the ear, and consulted a physician. The true condition of the parts was fully recognized, and prompt relief was afforded by dissecting the tough mass out from its bed in the bony canal. About once a year, for a period of five years, this patient experienced more or less discomfort in the ear, and each time he obtained entire relief by having the impacted mass removed. In a third case, I saw the patient for the first time in 1875, and for the second in 1877. On both occasions I found the impacted masses to be composed of quite small flakes or fragments of epithelium intermingled with hardened pus. The face, neck, and hairy scalp bore unmistakable evidences of eczema. The walls of the canal, after the impacted mass had been removed, were found to be red and swollen, but comparatively smooth. The drum-membrane had apparently escaped altogether. As the impacted masses, on both the occasions mentioned, were found to consist of only small epithelial flakes, which did not show the slightest disposition to assume a laminated arrangement, and which furthermore were largely intermingled with dried pus, I was disposed to consider this case as distinctively eczematous in character, and quite different from those cases in which the desquamative process shows a disposition to produce chiefly laminæ of epithelium intermingled with very little pus. More recently, however, I have had opportunities of examining this patient's ear, and on each occasion I have found the laminated arrangement of the cast-off epithelium as well characterized as we

ever see it. The last time I examined the ear I found that the inflammation of the canal had produced actual ulceration of the cutaneous surface, especially along the lower wall and near to the drum-membrane. It is therefore clear that a strict separation cannot be made between these two classes of cases—the eczematous and the desquamative.

I have already alluded to the fact that when the desquamative tendency becomes established, it seems to persist for a long time, and to retain its own peculiar type. The following case affords a good illustration of this fact, and also shows how the membrana tympani itself may participate in the desquamative process.

CASE XX.—*Desquamative inflammation of both tympanic membranes, resulting in the accumulation, upon the outer surface of each, of a thick mass of stratified epidermis.*

The patient, a strong, healthy sailor, consulted me at the New York Eye and Ear Infirmary, on the 23d of February, 1876. He complained of constant dizziness, and almost unbearable tinnitus in both ears "for some time past." No satisfactory information could be obtained from him with regard to the condition of his ears in previous years. The deafness was so marked that I was obliged to speak to him quite loudly in order to make myself heard. On examination both auditory canals were found to be filled with cerumen. After the removal of these masses, which were found to be composed entirely of cerumen, it was ascertained that a tough, leathery mass of laminated epithelium covered each membrana tympani to a depth of not less than one millimetre, and completely filled the recess at the lower and anterior portion of the inner end of the meatus. When touched with the probe the outer surface of the mass felt as hard and almost as smooth as parchment. The removal of these epithelial deposits was accomplished by means of the slender probe, the forceps, and the curettes; a solution of bicarbonate of soda having first been employed for the purpose of softening them and loosening their connections. The difficulty of the task was greatly increased by the circumstance that, whenever the instrument touched the wall of the osseous portion of the canal, the patient was seized with an irresistible desire to cough. This "ear cough" interfered so seriously with my manipulations that it was not until the fifth or sixth sitting that I finally succeeded in removing the last layer of epithelium. The pain caused by the manipulations also increased the difficulty which the patient experienced of keeping his head perfectly quiet. After the removal of these masses from both ears, the drum-membrane, on each side, was found to be red, somewhat thickened, and adherent in its central portion to the opposite promontory. The neighboring walls of the canal also presented an inflamed appearance, but no recognizable ulceration or inequalities of the surface. The dizziness and distressing tinnitus were in a great measure relieved by the removal of the obstructions, and there was a little improvement in the hearing.

Between the years 1876 and 1880, I saw the patient twice, and on both occasions I found that the pathological condition described above had reproduced itself.

In still another case, finally, the desquamative process had been allowed to go on unchecked for a long time—probably for a period of twenty years. The bony canal containing the laminated epithelial mass was found to be enlarged to fully twice its normal size. After the impacted mass had been removed with considerable difficulty, the walls of the dilated portion were found to be in an ulcerated and granulating condition, with a limited area of exposed bone surface. The inner wall of this large cavity presented the appearance of a uniform granulating surface, in which not a trace of the membrana tympani, ossicles, or labyrinthine fenestræ could be distinguished. While a great deal of this damage may legitimately be looked upon as the effect of prolonged pressure exerted by a mass located in the auditory canal, and constantly increasing in size, it seems to me scarcely doubtful that the original disease, out of which this desquamative affection subsequently grew, was a destructive inflammation of the middle ear, with probably exfoliation of part of the bony wall of the canal. However, the patient, a woman of average intelligence, and forty-one years old, was positive that she had never had a discharge from the affected ear, but admitted that, for a period of twenty years, she had experienced frequent earaches and more or less deafness in that ear.

Growth of Aspergillus in the External Auditory Canal.—Among the complications which develop in the course of a diffuse inflammation of the osseous or membranous portion of the external auditory canal, the one most often encountered is that of a furuncle, or series of furuncles, usually located in the cartilaginous portion. These lesions have already been considered in the earlier part of this chapter, and I may therefore pass on at once to the consideration of another and much less common complication. I refer to the growth of the different varieties of aspergillus in the inflamed canal. In this connection I may say that I agree entirely with those authorities who consider the presence and growth of this vegetable parasite in the auditory canal or middle ear as simply an accidental complication, and not as an independent cause of disease in either of these localities. The diffuse inflammation of the canal or the chronic inflammation of the middle ear, especially if a large perforation in the membrana tympani leaves this cavity unnaturally exposed to the air, supplies a soil suitable for the growth of the

sporules or germs with which the air is everywhere and at all times filled. An ear in a state of active secretion of pus or other fluid is not likely to furnish more than a momentary lodgment to these germs. The character of the fluid secreted also probably has much to do with their development; certain secretions being better suited for their growth than others. The cases in which the parasitic growth is most frequently observed are precisely these cases of diffuse inflammation of the osseous portion of the auditory canal. In the early stages of this disease the red and swollen skin lining the osseous portion of the meatus, and covering the outer surface of the membrana tympani, secretes just enough fluid to keep the parts moist, but not enough to give rise to a current. The conditions supplied here — moisture, absence of motion either in the fluid or in the surrounding air, and probably darkness—are eminently favorable to the further development of the aspergillus germs. It is also not unlikely that at least a slight degree of decomposition of the secretions is one of the conditions required for the growth of these germs. On two or three occasions I have had the good fortune to examine the ear just at the stage in which the fungus had reached its full aerial development. This happened in the following case:

FIG. 36.—Aspergillus from External Auditory Canal. *M*, Mycelium; *H*, hypha; *S*, spores; *Sp*, sporangium; *G*, gonidium. (After Urbantschitsch.)

CASE XXI.—*Growth of the aspergillus in the external auditory canal; apparently induced by the dropping of sweet oil into the meatus.*

The patient, a female, thirty-five years of age, stated that about four weeks previously she noticed a sensation of fulness in the right ear, and, supposing that it was due to the presence of hardened wax, she dropped some sweet oil into the meatus for the purpose of softening it. In the course of a few days she experienced a little pain in the affected ear, and again quite frequently during the following three weeks, but at no time was there any discharge. At the time I saw her, the hearing for the watch was reduced to $\frac{1}{12}$. On examination with the speculum and reflected light, the outer half of the meatus was

found to be perfectly normal. The lower half of the drum-membrane and the lower wall of the osseous portion of the canal were covered with a continuous, white, fuzzy material, which looked very much like cotton-wool. Here and there the whitish surface was dotted with small black specks. The upper portion of the membrana tympani and the rest of the osseous canal presented a red and moderately swollen appearance. Portions of the material removed from the auditory canal were examined with the microscope and found to be composed of the whitish or yellowish-white variety of the fungus, intermingled with occasional specimens of the black variety.

Under the use of instillations of a weak solution of carbolic acid, the ear slowly improved, and when seen for the last time, about six weeks subsequent to her first visit, the parts had nearly returned to their normal condition.

So far as my experience goes, it is quite common to find the black and white varieties growing side by side in the same ear. The white variety usually preponderates. Besides these two commoner varieties of fungus, there are others with which I have had no personal experience. Those who are interested in the subject will find these rarer varieties fully described in a paper published in 1879 by Dr. Charles Burnett.[1] In former years I made a careful search with the microscope for the fungus in every suspicious case. Perhaps once in five or six times I was successful in finding the parasite; but as the discovery never materially altered my plan of treatment, and as the searches consumed a great deal of time, I soon abandoned the practice altogether.

CASES CHARACTERIZED BY THE FORMATION OF BANDS AND MEMBRANOUS STRUCTURES IN THE AUDITORY CANAL.

CASE XXII.—*Formation of a cord-like, fleshy column at the inner end of the external auditory canal.*

The patient, a female, twenty-five years of age, and in good general health, presented herself for treatment at the New York Eye and Ear Infirmary, on the 30th of August, 1871. She stated that there had been a discharge from the left ear during the previous three years. On examination I found the outer orifice filled with a polypoid growth. With Blake's snare I then removed in succession four distinct polypoid masses, all of them growing from the walls of the auditory canal, and not connected, so far as I could discover, with carious bone.

On the 6th of September I saw the patient a second time, and found that the stumps of the polypi removed on the 25th of August had already markedly increased in size. I used the snare a second time, and cauterized the remaining raw surfaces with nitrate of silver.

On the 23d of September I examined the ear again and discovered that two of the stumps—situated opposite to each other, one on the upper, the other

[1] American Journal of Otology, vol. i., No. 2. New York, 1879.

on the lower wall of the meatus—had coalesced so as to form a distinct, cord like bridge of flesh, stretching from the upper to the lower wall of the meatus. Moderate stretching of this band with the probe failed to produce a rupture, and, being anxious to see whether it would shrivel up and disappear of itself, or what would become of it, I abstained from any further interference, and simply advised the patient to syringe the ear daily with lukewarm water.

On the 4th of October I found that the fleshy band had perceptibly diminished in diameter. There was also very little discharge.

On the 6th of December I found that the discharge had ceased entirely, and that the walls of the meatus were perfectly dry. The fleshy band had diminished to the proportions of a slender cord scarcely one millimetre in diameter; and when touched with the probe it felt dry and stiff, as if it were made of parchment. The mass of granulation-tissue had undoubtedly become completely covered with epidermis, and then the process of contraction, which is common to all newly formed connective tissue as soon as suppuration ceases, had reduced its proportions to those of a slender cord.[1] (The patient did not subsequently return.)

In another case I had an opportunity of watching the same series of pathological changes take place on a much larger scale.

CASE XXI.—*A ring-shaped mass of granulation-tissue in the osseous portion of the auditory canal ultimately becomes converted into a diaphragm-like membrane, completely shutting off the inner from the outer part of the meatus.*

The patient, a rather dull boy of twelve, was brought to the New York Eye and Ear Infirmary by his parents, on the 9th of July, 1873. Three years previously he had passed through an attack of scarlet fever, but no discharge from the ear had been noticed until a short time before his visit to the Infirmary. On examination, I found the entrance to the canal blocked by quite a large mass of granulation-tissue. The removal of this mass by means of Blake's snare brought to view a dark body, which felt hard when touched with the probe, and seemed to be tightly wedged in between the anterior and posterior walls of the canal. Steady traction, by means of a steel hook introduced flatwise between the foreign body and the upper wall of the meatus, and then turned point downward as soon as the inner end of the hard mass had been reached, brought it away entire. It proved to be a prune-pit of moderate size. Neither the boy nor his parents could account for its presence in the ear. That portion of the meatus in which the greatest breadth of the pit lay seemed to be larger than the natural size, while just beyond and just this side of the dilated portion the soft parts of the canal appeared to be swollen.

Nine days later I saw the patient a second time. The inner limit of the dilated portion—corresponding to the junction of the inner and middle thirds of the osseous part of the canal—was then the seat of a ring-shaped mass of granulation-tissue, which encroached very decidedly upon the calibre of the meatus.

Sixteen days later still (August 4th), I found the calibre of the canal

[1] Dr. George T. Engleman, of St. Louis, has reported a very similar case in the Archiv für Ohrenheilkunde, vol. vi., p. 203.

almost obliterated by this mass. Although the probe could still be passed through the centre of the obstructing granulations, the appearance presented was as if the calibre of the canal had been completely obliterated at this point.

During the following week three applications of chromic acid (in crystalline form) were made to the central portion of the mass. This caustic, however, set up so much inflammation that I was obliged to abandon its use. The boy was not seen again until the 2d of September. The canal was then found to be perfectly dry, and the patient said that the discharge had ceased several days previously. The ring-shaped mass of granulation-tissue had become transformed into a solid *cul-de-sac*, completely obliterating the calibre of the canal. The tissues were dry, smooth, and firm, and no longer resembled granulation-tissue. In the centre of the mass, a small scab, about the size of the head of a pin, was visible. After this had been removed, the probe could readily be pushed through to the broad part of the canal beyond.

Efforts at dilatation, by means of small laminaria bougies, were kept up during the following two or three days, but they caused considerable pain and proved of no avail. On the 28th of September fuming nitric acid was freely applied to the centre of the mass. The pain caused by this application was only moderate.

On the 4th of October I found that the acid had made quite a free opening in the mass. The application was not repeated, and yet the tissues forming the annular constriction continued to contract (centrifugally), and the calibre of the canal to enlarge, until on the 22d of November, when I saw the boy for the last time, very little trace remained of the mass,—which, if it had been left to itself, would undoubtedly have formed a permanent obstruction in the canal, in the shape of a diaphragm or false membrane. The discharge, which made its appearance soon after the application of the acid, had entirely ceased. Beyond the narrowed portion of the canal, which was very near its inner limit, the membrana tympani was plainly visible. Its lower half was perforated near the centre.

The following case completes the picture which nitric acid spoiled in the preceding case:

Case XXIV.—*A parchment-like diaphragm in the osseous part of the external auditory canal, not far from the position of the annulus tympanicus.*

The patient, a female, twenty-six years of age, consulted me at the New York Eye and Ear Infirmary, on December 1, 1873. She had been somewhat hard of hearing all her life. In childhood there had been a discharge from both ears, but during recent years there had not been any from the right one. In this ear the watch was heard only when pressed firmly against it. The left ear presented the ordinary appearance of an uncomplicated chronic purulent inflammation of the middle ear. An examination of the right ear revealed the following condition: the meatus was normal; at its inner end it terminated in a smooth, parchment-like membrane, of uniform but slight concavity outwardly, and looking very much like a membrana tympani from which the malleus had been removed. When tapped with the probe this membrane gave forth quite a loud sound, such as is heard when a stiff piece of parchment is bent. It appeared to be considerably thicker than the normal drum-

membrane, and, at every point of the periphery, passed without the slightest break or irregularity into the skin of the auditory canal. A superficial observer might very readily, I think, have taken this strange diaphragm for the membrana tympani. Its greater proximity to the external orifice, however, and the absence of the handle of the hammer, showed almost conclusively that, notwithstanding its dry, membranous character, it was not the drum-membrane, but a new-formation of some kind.

So far as its influence upon the hearing was concerned, such a membranous diaphragm could only act as an obstacle. I therefore had no hesitation in making a free crucial incision through it. The angular flaps thus made showed very little disposition to retract. They were readily bent over toward the walls of the meatus, however, and thus a view of the deeper structures was obtained through the irregular opening. All that could be seen at that time was the red and moist mucous membrane of the promontory, situated about four or five millimetres beyond the plane of the false membrane. As an evidence of the vitality of the latter, I might mention the fact that, a very few minutes after the incisions had been made, a glistening border of bloody serum was noticed along each of the cut edges of the angular flaps. The improvement then observed in the hearing, at least for conversation, was quite marked; for the watch, the hearing distance was increased to four inches.

At the next visit, a week later, the patient reported that there had been a constant discharge from the right ear since the day following the operation. The perforation was then circular in shape, from three to four millimetres in diameter, and through it the relations of the deeper parts could be distinctly made out. It was thus ascertained that the handle of the hammer was still entire, though adherent to and covered up at its tip by the tissues of the promontory. The short process of this ossicle could be distinctly recognized at the inner edge of the base of the false membrane.

When last seen the patient still complained of a slight muco-purulent discharge, and no marked change had taken place in the condition of the parts.

The two preceding cases throw light each one upon the other. In that of the boy, for example, there can hardly be any reasonable doubt that if I had not interfered vigorously with nitric acid, a false membrane or diaphragm, similar in every respect to that which was observed in the case of the woman, would have developed at the seat of the constriction. On the other hand, had I not previously watched the peculiar behavior of the granulation-tissue in the boy's case, and also in that of the first case (Case XXII.), I might have experienced difficulty in explaining the presence of such a parchment-like diaphragm in the osseous portion of the auditory canal. In all three cases the different steps of the process were essentially the same. Under the stimulus of some irritating cause, granulation-tissue was produced. Two granulating surfaces met at a time when there was not a sufficient current of fluid secretion to prevent them from uniting, and they accordingly united into a single mass. The

original irritating cause had by this time been withdrawn, and the absence of a free secretion of pus from the surface of the mass of granulations opened the way for the growth of a protective covering of epithelium from the surrounding healthy skin. As soon as the mass had once become covered with skin, rapid contraction and atrophy of all the connective-tissue elements followed, until finally nothing remained but two horny epidermal layers separated from each other by a thin sheet or cord—as in the first case—of connective tissue, poorly supplied with blood-vessels, and apparently not at all furnished with sensory nerves.

The false membranes observed in the preceding cases were provided with blood-vessels and represented each an integral portion of the living body; that observed in the following case can only be looked upon in the light of something cast off and already dead, though still mechanically connected with the body.

Case XXV.—*Exfoliation of the epidermal covering of the tympanic membrane in its entirety; transportation of this cuticle a distance of a few millimetres from the membrana tympani.*

The patient, a female, fifty years of age, consulted me in the summer of 1876 for deafness of slight degree, referable chiefly to the left ear, and of about one year's duration. Examination with the speculum and reflected light revealed the following condition of things in the left ear: In the osseous portion of the external auditory canal, at a point about one-third of an inch from the drum-membrane, a membranous structure completely occluded the canal. To the eye, this membrane presented all the appearances of ordinary cast-off cuticle. At no point did it show any evidence of being provided with blood-vessels. When touched with the probe it yielded to the pressure in precisely the same elastic manner as would any thin membrane like the cuticle, when separated from its underlying connections. The peripheral portion of the membrane was carefully tested with the probe at all points of the circumference, for the purpose of ascertaining the nature of its attachment to the skin of the external auditory canal. At every point it was found to be continuous with the cuticle of the neighboring skin. The plane of the membrane was nearly at right angles to the axis of the canal.

In order to ascertain the exact condition of the deeper parts of the ear, and also, at the same time, for the purpose of removing from the canal what could only be considered as a hindrance to the perception of sound, I made a crucial incision through the membranous diaphragm, and then, with the forceps, tore away the greater part of the remaining segments. At the points where the attached membrane had been torn off, no evidence of any line of attachment remained beyond at most a diffuse redness of the skin. The drum-membrane beyond presented a fairly normal appearance, and the hearing was somewhat improved by the removal of the obstacle.

This case, which is entirely different in its pathogenesis from

the one last reported, derives its chief importance from the light which it throws upon the question of horizontal or surface motion in the epidermis of the membrana tympani and skin of the external auditory canal. That such a motion exists on the outer surface of the drum-membrane, has been known for several years. Every aural surgeon who has had occasion to perform paracentesis of the membrana tympani has observed how from day to day the scab resulting from his incision moves from its original situation in the posterior half of the membrane, midway between the umbo and the periphery, toward the latter, and eventually, in its outward course, leaves the drum-membrane entirely.

The same motion has been observed in the external auditory canal in the immediate vicinity of the membrana tympani. Dr. Clarence J. Blake, of Boston, in a paper published in the *American Journal of Otology*, speaks of this motion as taking place in a spiral direction. Dr. C. H. Burnett, in his "Treatise on the Ear" (p. 46), speaks of this outward movement of the epidermis of the external auditory canal as affording an explanation of the way in which the superabundant cerumen is extruded from the canal. This surface movement, then, of the epidermis of the drum-membrane and external auditory canal, furnishes, I believe, an explanation of the presence—in the case narrated above—of a cuticle-like, membranous diaphragm in the outer canal of the ear. This membrane, according to this theory, would represent a desquamation—probably the result of an acute congestion of the parts—of the entire epidermal coat of the drum-membrane. That part of the cuticle of the membrana tympani which had separated from the underlying living epithelial cells must, in the present instance, have retained (at all points of the circumference) its connections with the neighboring healthy cuticle of the external auditory canal. The surface motion known to exist in the cuticle of the deeper portion of the canal extends without doubt throughout the entire canal. Hence, in the present case, after the cuticle had separated from the drum-membrane, the centrifugal motion of the remoter parts of the separated membrane—due to the traction exerted by the outwardly moving, healthy cuticle of the external auditory canal—must have produced at first merely a state of tension (equilibrium) in the central portions of the cuticular membrane. At a later moment, however, this outward motion of the healthy cuticle must have exerted a symmetrical outward traction upon the cuticular membrane, eventually lifting it completely off the underlying membrana tympani.

That in this particular case a rupture did not occur at some point must be ascribed simply to the fact that probably all things conspired to favor a separation of the desquamated cuticle in its entirety. After the act of separation had once taken place there was no reason why the separated cuticle (then an independent diaphragm) should not remain unbroken until acted upon by some force from without. If different parts of the healthy cuticle of the external auditory canal travelled outward at different rates of speed, we might look for a rupture, or at least for a distorted cuticular diaphragm. The flatness of the membrane in the present case, and the inclination of the plane which it occupied to the axis of the meatus, would rather favor the view that the rate of speed is the same for all parts of the canal.

Further observations and experimental researches will doubtless some day determine accurately all the facts connected with this peculiar horizontal cuticular motion, analogous to the growth of the nail, which is a cuticular structure.

CHAPTER VIII.

DISEASES OF THE EXTERNAL AUDITORY CANAL (Continued).

SYPHILITIC DISEASE; FOREIGN BODIES; WOUNDS AND OTHER INJURIES; NEW-GROWTHS; CYST-LIKE FORMATIONS.

I. SYPHILITIC DISEASE.

Ulcers and Condylomata.—So far as I can judge from my own experience and from the publications of writers on otology, cases of syphilitic disease of the auditory canal are comparatively rare. I have never seen the disease in this locality in its first stages; the patients have always presented themselves for treatment at a time when the lesions had reached their full development. The following three cases may serve as typical illustrations:

CASE XXVI.—*Syphilitic ulceration of the lower wall of the external auditory canal.*

The first case is that of a man, forty-four years of age, who stated that he had caught cold three weeks previously, but did not notice anything wrong about the ear until about two weeks later. The left ear then began to ache, and very soon afterward a discharge appeared at the orifice of the auditory canal. From that time to the day on which I first saw the patient, the discharge, he said, had been constant. On examination, I found the left membrana tympani red, very much swollen, and perforated anteriorly and inferiorly. The lower wall of the outer half of the meatus was ulcerated for a distance of about half an inch. The ulcer extended outward upon the auricle, and its limits were everywhere quite sharply defined. An examination of the throat revealed the existence of well-marked syphilitic lesions, and, on questioning the patient, he admitted that he had had a chancre one year previously. (This case was not seen again.)

The lesions observed in this patient's ear were not of such a character as to suggest at once a syphilitic origin. It was only after the throat had been examined that the thought of a common origin for the two sets of lesions suggested itself to my mind. And yet, if we reflect for a moment, we shall be obliged to admit that the development of a well-defined ulcer in the auditory canal, after a discharge from the deeper parts of the ear had been going on for

only one short week, is a very unusual phenomenon. In children the external auditory canal is very apt to become ulcerated by the constant flow of an irritating secretion over its surface; in adults, however, this rarely happens, and then almost always in connection with a chronic discharge from the ear. In very rare cases ulceration may take place as a result of goutiness; but in these instances a diffuse eczematous inflammation always precedes, for some time, the actual ulceration. In the present case a comparatively large and well-defined granulating area or ulcer had developed in a canal which presented almost no other evidence of active inflammation, and which had been subjected to no other irritating influence than that which may have been exerted by the flow, for the period of a week, of a purulent fluid over its surface. Furthermore, the discharge was by no means copious, as we should rightly expect it to be if it had been the sole cause of the extensive ulceration observed. These are the points which seem to me to justify the view that this ulcer was a true syphilitic ulcer or gummous degeneration.

Case XXVII.—*Syphilitic papillomata of the orifice of the external auditory canal; entire disappearance, under constitutional and local treatment, in the course of about eight months.*

The second case is that of a man, twenty-eight years of age, of strong frame and apparently vigorous constitution, who stated that during the month of February, 1878, he first noticed a discharge from the right ear. It came on without pain, lasted for a few weeks, and then ceased of its own accord, without treatment. In the early part of the summer the discharge returned, and from that time forward it had been a constant symptom. He had experienced no difficulty in hearing, but for a short time before I saw him he had noticed some soreness of the affected ear. On examination I found the following conditions: The orifice of the right meatus was almost completely obliterated by the presence of an elevated patch of what seemed, at first sight, to be simple granulation-tissue; the dividing-line between this patch, which completely encircled the orifice, and the healthy skin of the auricle, was sharply drawn, the edges of the elevated portion being quite abrupt. When the auricle was pulled upward, backward, and a little outward, the flattened patch opened in the centre and displayed a narrow entrance to the auditory canal beyond. At the same time fissures became visible in the outer surface of the patch. When the auricle was allowed to resume its natural position, these fissures completely disappeared, and the central opening became converted again into a mere depression in the centre of the patch. When examined more closely, this circular patch, which seemed to be composed of granulation-tissue, proved to be made up, in reality, of very numerous minute vegetations or papillomata, the majority of which were of a pale pinkish hue, while a few presented a decidedly red color. A watery discharge oozed from

the lower part of the elevated patch. The fissured appearance observed when the parts were put upon the stretch was found to be due to the fact that the minute papillomata sprang in groups from rather broad trunks, and the fissures corresponded with the spaces which separated these larger trunks. Just inside the orifice were found a few growths which were quite large in comparison with the greater number,—as large, *e.g.*, as a hemp-seed, or even larger. The external auditory canal itself, so far as the eye could see with the aid of a small speculum and reflected light, was filled with similar vegetations. Between the larger masses were numerous smaller and more pointed growths, like those observed at the orifice. When touched with the probe, the larger of these growths were found to be considerably harder than ordinary granulation-tissue. Some of them looked precisely like (on a smaller scale, of course) the warts seen on the fingers of young children, the skin covering them being pale and tough like natural skin. The smaller papillary growths, and one or two of the larger ones near the orifice of the canal, were less firm in structure, and bled readily when they were manipulated with the probe. The membrana tympani was not visible. The gland lying upon the mastoid process of the same side was enlarged to such an extent as to cause a visible swelling in this region. The occipital glands were also moderately enlarged. A diffuse discoloration of the skin, with desquamating surface, was observed on the hairy scalp, and also to a slight extent on the forehead of the left side. Two well-marked mucous patches occupied the left half of the velum palati. On questioning the patient it was ascertained that he had contracted the primary lesion about fifteen months previously.

Treatment was not begun until September 4th. It consisted in daily inunctions of mercury (about a drachm of Squibb's oleate of mercury [5 per cent]), and also in its internal use (one thirty-second of a grain of the bichloride three times a day). The larger vegetations which were within reach were snipped off with the scissors; the smaller ones were touched with nitric acid. The patient was simply instructed to keep the ear clean by syringing it out from time to time with warm water.

September 26th.—The dose of the bichloride was increased to-day to one-sixteenth of a grain three times a day. The patient was also given some calomel with which to dust those vegetations which were within his reach.

October 2d.—Patient feels better in every way, and says that the otorrhœa is diminishing in quantity. The patch of vegetations around the orifice of the external auditory canal has perceptibly diminished in height and in vividness of color.

October 23d.—Patient has gained thirteen pounds in weight since the 4th of September. He has been very faithful in using the remedies prescribed. The squamous eruption on his forehead has almost disappeared. The orifice of the external auditory canal has been steadily increasing in size. Very little change, however, is perceptible in the condition of the deeper portions of the canal. By aid of the probe it was ascertained to-day that the innermost section of the meatus, close to the membrana tympani, was smooth and apparently free from vegetations. The "mucous patches" are still visible on the velum. Iodide of potassium is to be added to the bichloride mixture, in the proportion of ten grains to each dose.

November 6th.—The wart-like growths in the external auditory canal

have become less prominent; they encroach less upon the calibre of the canal, and the intermediate bright-red, pointed condylomata have lost their bright color and well-defined outlines. Nitric acid (undiluted) applied firmly to one of the more prominent excrescences near the external orifice. The pain which followed lasted but a minute or two, and then entirely disappeared. Appetite good. No evidence of sponginess of the gums.

November 13th.—Application of nitric acid repeated to-day. The orifice is now increasing in size quite perceptibly, and the deeper condylomata—simply under the influence of the constitutional treatment—have now shrunk away to mere elevations of the skin. The discharge is also very much less than at first. The inunctions are still kept up. The improvement in the condition of the meatus has been more marked during the past week than during any previous week since treatment was begun. No appreciable change in the condition of the mucous patches on the soft palate. Dose of potassic iodide increased to twenty grains three times a day.

November 20th.—Patient has now gained twenty-six pounds in weight. The discharge from the ear has ceased, and almost every trace of the condylomata has disappeared. Membrana tympani entire.

In a third case, the conditions observed in the auditory canal were in many respects different from those which I have just described.

Case XXVIII.—*Wart-like syphilitic growths in the external auditory canal.*

The patient, a woman, twenty-five years of age, was under the care of another physician, at the time, for syphilitic disease of the vulva. The first symptoms referable to the ear were noticed about eight weeks previously. The ear became painful, and soon a discharge took place from the external auditory canal. Three weeks previously the ear again became painful, and relief was only obtained by making a free incision through the mastoid integument,—leeching and other simple measures having failed to quiet the pain. At the time I saw her the meatus was obstructed by the presence of several wart-like growths, situated on opposite sides of the canal, and bathed with a thin, watery pus. These growths were very firm in texture, being covered apparently with true skin. The largest was equal to a pea in size, and sprang from the base of the tragus by a broad base. The drum-membrane and the deeper parts of the canal were concealed from view by these growths. By aid of the probe, however, I ascertained that the latter were not connected with any fistulous opening in the bone or with any superficial spot of caries. (The case was not seen again.)

In a paper published by H. Schwartze in 1869,[1] he states that in the auditory canal polypoid granulations undoubtedly occur, which must be considered as a local manifestation of constitutional syphilis. "As granulations of this character, however, are exceedingly common in non-syphilitic individuals affected with a purulent

[1] Archiv für Ohrenheilkunde, Bd. iv., Würzburg, 1869, pages 253 *et seq.*

inflammation of the ear, it becomes a very difficult matter to decide, in a given case, whether the growths are or are not of a specific nature. From the anatomical examination alone, no definite conclusion can be drawn. The characteristic papillary structure of the tumor, which sometimes presents the appearance of a perfectly developed condyloma, is also observed in cases where syphilis is not to be thought of for an instant." As no material modification of this view is put forth in his later treatise,[1] I assume that his opinion still remains substantially the same as it was in 1869. It is quite possible that the two cases of syphilitic "granulations" which came under my observation were exceptionally well-marked types of the disease. This view, however, is rendered improbable by the fact that other authorities (Stoehr,[2] Gruber,[3] and Deprès[4]) have reported quite a large number of cases in which well-characterized lesions of syphilis were observed in the auditory canal. I have also never seen, in non-syphilitic individuals, lesions which resembled in any but a very superficial degree those which I have described above. It seems to me, therefore, that Schwartze's statement is too sweeping in its character, and that it may be set down as a fact that well-defined lesions of constitutional syphilis may occur as well in the external auditory canal as in other parts of the body.

II. FOREIGN BODIES.

If we exclude such bodies as sequestra of bone, hardened masses of cerumen, calcareous bodies, and the so-called cholesteatomata—which are essentially laminated masses of epithelium—we may say that foreign bodies in the auditory canal are not of frequent occurrence. Thus, for example, out of 1,652 cases, Dr. Blake found (in 1873) foreign bodies in the meatus 16 times (about one per cent). According to the statistical report of the New York Eye and Ear Infirmary for 1878, the proportion was about the same, viz., 30 cases out of 2,784. My own records show a still smaller proportion, viz., about half of one per cent. With regard to the ages of these individuals, I find that two-thirds of the cases seen

[1] H. Schwartze "The Pathological Anatomy of the Ear." Translated by J. Orne Green, M.D. Boston, 1878.

[2] Archiv für Ohrenheilkunde, 1869, Bd. v., S. 130 *et seq.*

[3] "Ueber Syphilis des Gehörorgans," Wiener Med. Presse, 1870, Nos. 1, 3, and 6.

[4] Annales des Maladies de l'Oreille, etc., December 31, 1878.

were under twenty years of age. The foreign bodies found in the individuals who were under twenty years of age were quite different in character from those found in the adults. They comprised pebbles, glass beads, a cherry-pit, a prune-pit, ordinary beans both black and white, a locust-bean, a coffee-bean, a grain of corn, a piece of lead from a lead-pencil, a piece of slate-pencil, and small rolls of paper. These articles, as will be noticed, are all such as a child would be likely to put into his own ear or into that of another child. Those articles found in the ears of adults were exclusively such as would be likely to find their way into the canal through accident or forgetfulness or else wholly without human agency. In one case, for example, it was a fly; in a second, four flies were found; in a third, two living larvæ of the house-fly; in a fourth, a cockroach or Croton bug; in a fifth, a young bedbug. In several cases a stiff hair was found sprung like a bow between the wall of the canal and the drum-membrane; and finally, in a few cases a forgotten mass of cotton-wool was found impacted in the inner half of the meatus.

Symptomatology.—In many of the cases which come under observation, the patient complains of no symptoms whatever. Some mischievous playmate, or the boy himself, has introduced a bean, or a bead, or some other small object into the canal, and the parents are afraid that some harm may come to their child if the foreign body is allowed to remain in the ear. It is this fear on their part, and not any deafness or suffering on the part of the child, which usually leads them to consult a physician. Now and then the rough manipulations of medical men, who attempt to remove a foreign body from the ear without seeing exactly what they are doing, convert a simple case of this kind into one of a very complicated and painful nature. In former years I saw several cases of this kind, but recently I have not seen a single instance; and I am disposed to consider this fact as an evidence that physicians generally are more careful than they used to be in their management of such cases.

In another class of foreign bodies the patient experiences well-marked symptoms. Thus, for example, in those cases (by no means rare) in which a hair is found sprung between the membrana tympani and the sensitive skin of the outer canal, the sensation of pressure or fulness in the affected ear is sufficiently marked to lead the patient to consult a physician. In other cases in which a piece of dried cuticle is found wedged in between the drum-membrane and the wall of the canal, the patient is apt to complain of a crunching

noise in the affected ear whenever the jaw is moved. Although from an anatomical standpoint it is difficult to comprehend how the motions of the jaw can exert traction upon either the membrana tympani or the skin lining the extreme inner end of the auditory canal, the fact remains that the opening and shutting of the mouth may produce sufficient motion in these parts to cause a slight friction between the foreign body and the drum-membrane. In the cases in which dead flies were found in the meatus, the patients had experienced no unusual symptoms, and were unable to say when or how these insects had found their way into the ear. As both patients were affected with a chronic purulent inflammation of the middle ear, it is quite likely that the flies were attracted to the ear by the odor of the discharge. The presence of living larvæ of the house-fly in the canal of another patient, also a sufferer from chronic purulent inflammation of the middle ear, is probably best explained by assuming that the eggs were actually deposited in the auditory canal by a fly, probably while the patient was asleep. The Croton bug and the bedbug also undoubtedly effected an entrance when the patients were asleep, for in neither of the cases could the patient state at what exact time the insect entered the canal. At a certain time, however, both patients became aware that some living creature had got into the ear, as a sensation of something moving in the canal was felt by each of them. The Croton bug was dead when I extracted it; the bedbug was alive, and when first seen presented the appearance of a small mass of brownish ear-wax adherent to the upper part of the drum-membrane.

Finally, in those cases in which unskilful and unduly violent efforts had been made to remove the foreign body before the patients finally came under my observation, the prominent symptoms were: Marked pain and tenderness in the region of the ear, a bloody discharge from the canal, and a great dread of having the ear touched. In one of these cases I found the pebble lying partly in the meatus and partly in the middle ear, the drum-membrane having apparently been lacerated by the efforts previously made to remove it. In another instance the bony surface of the canal was found to have been laid bare. In a third case the external orifice was found to be in such a swollen condition that the diameter of the foreign body beyond must have been at least twice as great as that of the canal through which it would have to pass while being extracted. Were it not for these, now fortunately rare cases, the

symptomatology of foreign bodies in the external canal might almost be omitted altogether.

I should perhaps mention the fact that women sometimes consult a physician for the purpose of having an imaginary foreign body (generally a pin) removed from the ear. I have seen two or three such cases, and have observed in each instance that the patient seemed to be annoyed by my assurances that the auditory canal was perfectly natural and contained nothing that did not belong there. Judging from their actions, after the results of the examination had been communicated to them, I have no doubt that they ascribed my failure to find the foreign body to lack of sufficient skill in examining the ear.

Treatment.—Hard substances, like beads, pebbles, or buttons, if they do not cause pain, and if they are not actually impacted in the auditory canal, may be allowed to remain there undisturbed for a reasonable length of time. In one of my cases, for example, a glass bead of large size had remained twelve years in the canal without doing the slightest damage that I could discover. As the foreign body, however, may change its position and become wedged in between the drum-membrane and the anterior wall of the canal, and as an intercurrent inflammation of either the meatus or the middle ear might be seriously complicated by the presence of such a foreign body in the canal, it is better not to delay its removal any longer than is necessary to insure a successful result. If the body is impacted in the canal and is causing pain, the sooner it is removed the better. If the operation is postponed, the outer portion of the canal may become swollen, and the task of extracting the foreign body may thereby be rendered materially more difficult. In the case of substances like dried peas and beans, which may swell up in water to fully twice their original size, it is important to abstain from using the syringe; or else, if we fail by means of it to remove a foreign body of this nature, we should proceed, without further delay, to extract it by means of instruments.

Small bodies, which simply lie in the canal without being impacted between its walls, may be removed by means of such instruments as the slender forceps, the curette, or a bent probe, or by means of the syringe and warm water. If the foreign body is of sufficient size to fill the canal, or to press against its sides at two or more points, the use of the syringe seems to me to be thoroughly irrational and unpractical. What is required in such a case is a "force from behind," and not one that spends itself upon the outer

surface of the foreign body, and thus tends to drive it deeper down into the canal. If the shape and position of the body are such that we may with some degree of confidence hope to extract it by seizing it directly with the slender forceps, this plan may be adopted. But it is far better not to make such an attempt, unless we are quite confident of success; for if we lose our grasp upon the body, we may be almost sure that we shall drive it a little beyond the position which it previously occupied, and thus render the problem of removal correspondingly more difficult. The better plan is to explore the circumference of the foreign body with the probe, and thus ascertain whether there is not some point where it is separated by a certain amount of space from the wall of the meatus. This is the point at which we should introduce the instrument by means of which we intend to bring the desired *vis a tergo* to bear upon the foreign body. In the case of a roundish body like a cherry-pit, a pea, or a bean, we shall frequently fail to find such a point. Under these circumstances, if we desire to bring a similar force to bear upon the impacted body, we must employ an instrument that is both slender and strong: slender enough to force its way between the foreign body and the skin of the canal without injuring the latter, and yet strong enough, after it has once been pushed inward the requisite distance, to exert a decided downward and outward pressure upon the inner end of the mass. The smaller curette and a delicate steel hook are almost the only instruments which I have used for the purposes we are now considering. The curette is made of steel, and has been sufficiently described in an earlier section. The hook should also be made of steel, but the shank should be tempered (moderately), and not left in a malleable state like that of the curette-shank. In introducing the curette, which must first be slightly bent flatwise, we must make its ring-shaped end describe an arc of a rather small circle, or we shall cause the patient unnecessary pain, and perhaps fail to carry the end of the instrument beyond the foreign body. In introducing the hook we must follow a somewhat different principle: as in the case of the curette we must introduce it flatwise, but as we push the instrument farther and farther inward, we must make the end of the hook proper hug the foreign body constantly. By pursuing this plan we shall know instantly when the instrument has reached the inner end of the foreign body; for the hook, no longer meeting with the resistance offered by the side of the obstructing mass, will at that very moment perform the rotatory movement which the pressure of our

fingers has tended to give it. We must not allow it, however, to perform more than a quarter of a turn, for fear of bringing the free end in contact with the walls of the canal. When the hook has performed this quarter revolution, we should withdraw it cautiously but firmly, and thus dislodge the impacted foreign body. If that portion of the canal which is external to the foreign body is very much swollen, it will be found necessary to first dilate it gradually, by means of a series of well-polished conical specula, or by means of cotton-wool wound tightly around the end of a cotton-carrier and moistened with vaseline. In the case of older children it will probably not be found necessary to administer an anæsthetic; and even in the younger ones I have only a few times found it impossible to proceed without the aid of such a reagent. Again, let me emphasize the importance of carrying out all these manipulations only when the canal is satisfactorily illuminated.

The after-treatment in the graver cases is based upon the same principles as those which govern the treatment of other acute inflammations of the canal or of the middle ear. In the simpler cases no after-treatment whatever is required.

Before leaving this subject of foreign bodies in the external auditory canal, I must say a few words in regard to the operation of displacing the auricle and cartilaginous portion of the meatus forward, for the purpose of gaining a greater amount of room and a shorter canal. The question of performing this operation can only arise in very exceptional cases, viz.: when all other means have been tried and have proved unsuccessful. My own experience is confined to a single case, the history of which I will give here briefly:

Case XXIX.—*Locust-bean very tightly lodged in the osseous external auditory canal; displacement of the auricle forward, and removal of the bean through the incision.*

The patient, a boy nine years old, was brought to me by his mother with the statement that on the previous day one of his playmates had pushed a locust-bean[1] into his right ear. Efforts were made by the nurse and by a friend to extract the foreign body, but without success. On examination I found that a hard and slippery body was immovably lodged at the inner extremity of the canal, and that at one or more points the skin had been torn

[1] These beans are of a brownish color and vary but little in size. They are highly polished, are exceedingly hard, and do not swell up or grow softer when soaked for a period of several days in water. They are shaped like a hen's egg that has been flattened longitudinally, and they measure 10 mm. in length, 7 mm. in breadth, and 5 mm. in thickness.

from the underlying bone. All the parts were bathed with a bloody secretion. There was no pain, and the parts around the ear were free from tenderness. Sulphuric ether was administered, and repeated efforts were made, both by Dr. Francis Delafield and by myself, to dislodge the bean from its remarkably firm anchorage between the anterior and posterior walls. These efforts were made exclusively with steel hooks, which were passed flatwise between the bean and the wall of the meatus, and then turned through an arc of about ninety degrees, so as to bring the short arm of the rectangular hook directly behind the foreign body, between it and the drum-membrane. No force that we could bring to bear was found sufficient to dislodge the bean. The boy was allowed to regain consciousness, and the mother was informed that it would be necessary to partially separate the auricle from the underlying skull, in order to gain more ready access to the foreign body. Her consent was easily obtained, and it was decided that the operation should take place after the lapse of four or five days. At the time named the operation was performed. The details given here are copied from a report of the case which I published soon afterward. "As a first step the hair above and behind the ear was cut away for a short distance from the latter, and then a semicircular incision about three inches in length was made through the skin and underlying soft parts, above and behind the auricle. This incision began at a point situated in front of and a little above the upper and anterior margin of the auricle, and terminated at the tip of the mastoid process. The soft parts constituting this flap were then dissected from the underlying periosteum until the membranous part of the external auditory canal was exposed to view. The point of the knife was then passed, from without, through the membrane, as near as possible to the bony margin of the meatus, and the incision was continued both upward and forward and downward and forward until the calibre of the canal was fully exposed to view. Up to this point in the operation it had been found necessary to place ligatures around six or seven small blood-vessels, the hemorrhage from which, though not considerable, was sufficient to prevent us from obtaining a distinct view of what we were doing. When the calibre of the auditory canal, however, was exposed to view, the constant welling up of blood from the deeper parts proved very annoying, and some time elapsed before it finally ceased. I was then able to see the bean lying transversely across the long axis of the canal, but its distance from the outer orifice was still so great that in my manipulations with the steel hook I was not conscious that I was operating at a materially greater advantage than when the auricle and cartilaginous meatus occupied their natural positions. After numerous efforts, and when I had almost reached the conclusion that I should fail to dislodge the tightly impacted foreign body, it suddenly yielded to a traction force greater than any I had previously dared to exert. No attempt was made at this time to ascertain the exact condition of the drum-membrane. The raw surfaces were thoroughly washed with a strong solution of carbolic acid, and interrupted silk sutures were used in bringing the edges of the skin together throughout the upper portion of the wound, while the lower portion was left open for purposes of drainage. The ligatures, which had been applied to the bleeding vessels, had been cut off short, and they were left to take care of themselves. Powdered iodoform was blown liberally all over the raw surfaces, into the external auditory

canal, and upon those outside dressings which came in immediate contact with the wound. Over these was then placed a large pad of absorbent cotton, and finally a gauze roller bandage was passed around the head and neck for the purpose of keeping the dressings firmly in position."

Five days after the operation the dressings were removed, and it was found that primary union had not taken place at any point along the edges of the wound. There was no redness or swelling, no evidence of anything like a process of granulation, and only a trace of pus was visible at the lower part of the wound and in the external auditory canal. When the stitches were cut, however, it was found that primary union had taken place in the deeper parts throughout an area sufficiently great to keep the flap very nearly in its proper position. To favor union by granulation with the minimum degree of visible scar, I brought the edges of the upper part of the wound in close coaptation, and then applied rubber plaster in such a manner as to crowd the auricle and skin of the cheek upward and backward. The only other dressings employed were sheet lint and vaseline; a roller bandage being used simply for mechanical support. It was not until three weeks after the operation that the external wound finally healed; the discharge from the external auditory canal continuing about two weeks longer. It was found that a small perforation existed in the drum-membrane—probably the result of the various efforts made to remove the foreign body. It healed soon after the discharge ceased. The diminution of the hearing power was insignificant.

The case narrated above is the first one in which I have known a smooth and symmetrically shaped foreign body to become tightly impacted in the osseous portion of the external auditory canal. Indeed, had I not been a witness to the fact, I should have felt strongly disposed to doubt the possibility of such an occurrence.

Dr. J. Orne Green, of Boston, Mass., thus briefly summarizes the important facts relating to the history of the operation of displacing the auricle forward:[1] "The operation of displacement of the auricle forward for the removal of foreign bodies is by no means new in theory. The whole subject is thoroughly discussed by Von Troeltsch in the seventh edition of his 'Lehrbuch' (1881). The suggestion of the operation is found in 'Paulus Aegineta' (660), and in recent times has been recommended by Hyrtl. Von Troeltsch approves of it where operative interference is imperative and other methods of removal are impossible, but suggests that in children the auricle and cartilaginous meatus be separated from the osseous meatus by a simple incision above the meatus along the squamous bone, and in adults that the osseous meatus be reached by an incision along the lower wall of the cartilaginous canal. Neither of these methods seems to me adapted for giving a thoroughly free and large opening for the extraction of expanded bodies like those in

[1] Transactions of the American Otological Society, vol. ii., part 5, 1881.

this case (one of leaden bullets in the ear), and both seem open to the objection of insufficient drainage after the operation, if such becomes necessary, while the latter method must almost certainly wound the parotid gland and add another element of risk. Von Troeltsch narrates four cases where displacement of the auricle forward was performed,—one by Langenbeck and three by Schwartze. All were successful, and recovered; one healed *per primam intentionem*, and the others by granulation."

On this side of the Atlantic, so far as I am aware, the operation has hitherto been performed only twice, at least for the purpose of facilitating the removal of a foreign body from the deeper parts of the ear, viz., by Dr. J. Orne Green and by Dr. D. B. St. John Roosa.[1] In both instances the foreign body removed from the ear was a leaden bullet. In the case which I have narrated above I was led to perform the operation by the belief that I should thereby gain much more space in which to manipulate hooks or possibly even forceps, and that consequently I should be able to bring a greater dislodging force to bear upon the foreign body. I must frankly confess that in this particular case the gain in space did not materially diminish the difficulty of extracting the bean. The location, size, shape, hardness and polished surface of the foreign body rendered the employment of forceps of any size or pattern useless; and yet the gain in space and the diminution in the length of the canal to be derived from the displacement of the auricle forward prove of the greatest value in precisely those cases which permit the use of forceps. Where the foreign body, however, is hard and polished, and particularly where it is impacted in close proximity to the membrana tympani, and occupies a large part of the calibre of the canal, forceps cannot be used. Under these circumstances, therefore, I believe that the operation is not to be recommended.

In this connection I desire to call attention to the great amount of violence that may be inflicted with impunity upon the osseous part of the external auditory canal and particularly upon its lining membrane of skin. In the present case, for example, there was scarcely any portion of the posterior and upper wall of the osseous meatus from which the skin (*i.e.*, the periosteum) had not been torn; and yet, after the lapse of four or five weeks, all these parts were found to have resumed their natural relations and appearance. I have observed this same regenerative power of the periosteal lin-

[1] Trans. Amer. Otol. Society, p. 447 of vol. ii., part 5.

ing of the auditory canal in other cases, and believe that we may safely trust nature to repair any injuries that we may be compelled to inflict upon this part of the ear in our operative procedures.

III. WOUNDS AND OTHER INJURIES.

Injuries to the external auditory canal are, according to my experience, of comparatively rare occurrence. I have seen only a few cases, and they were all of minor importance. In one of these the patient had introduced the rather pointed end of a penholder into the right ear, just as he rose from his seat to get something at the other end of the room. Passing too near an unusually high stove, he suddenly felt a sharp pain in the right ear, as if a pointed object had been violently driven into it. Slight bleeding followed, and the patient almost at once experienced a decided sensation of faintness, which lasted, however, but a short time. For a period of five days the ear gave him scarcely any trouble, and then it began to be decidedly painful. About a week later still I had an opportunity of examining the ear, and then found that an abscess had formed in the posterior wall of the canal, not far from the external orifice.

From the appearances presented to the eye there could be no reasonable doubt that a distinct collection of pus existed at this spot. The patient, however, declined to have it lanced at that time, and I never saw him afterward.

In another case it was not ascertained exactly how the injury was received, owing to the fact that the patient was intoxicated at the time. The blow or the fall, however, produced unconsciousness for a short time, and when the patient recovered his senses he observed that blood was escaping quite freely from the right ear. The accident occurred on the 9th of March, 1875, and from that time until the day on which I first saw him, viz., March 13th, an intermittent, but in the main abundant, hemorrhage had continued. On examination, I found a rather deep irregular wound in the cartilaginous wall of the canal, a short distance from its junction with the osseous portion. The bleeding had at that time ceased, and as the patient seemed to be free from pain, I advised him simply to leave the ear alone. Four days later I found the wound healing naturally by granulation.

In a third case the rib of a steel umbrella-frame had been accidentally thrust into the external auditory canal, causing a small lacerated wound. Nevertheless the hemorrhage was quite free;

and even after the lapse of twenty-four hours, I found the blood still trickling from the ear in a steady stream. Upon the application, however, of a very small piece of styptic cotton to the bleeding spot, the hemorrhage instantly ceased.

The persistent bleeding which seems to characterize these lacerated wounds of the external auditory canal is undoubtedly to be attributed to the fact that those blood-vessels which pierce the cartilaginous framework—as many of them do—are not capable of contracting and retracting beyond a very limited extent; their physical relations being essentially the same as those of the blood-vessels which traverse bony structures.

Of the other injuries which may be inflicted upon the external auditory canal, there are only two which possess any special importance, viz., gunshot or pistol wounds, with lodgment of the bullet in the canal or in some part of its bony walls; and fracture of the plate of bone which constitutes the anterior wall of the meatus, through a blow or a fall upon the chin.

Gunshot injuries of the external auditory canal are not so very infrequent. Accounts of two such cases will be found further on, in the chapter relating to Fractures of the Temporal Bone. Much more rare, on the other hand, are the cases in which a blow upon the chin causes a *fracture of the anterior bony wall of the auditory canal*. I have seen only one instance of this kind, but I have read the published accounts of a few cases. Thus, for example, in a recent number of the *Archiv für Ohrenheilkunde* (February 4, 1897)[1] there will be found the report of a man who fell and struck his lower jaw against an iron bar. The pain in the ear which resulted from this blow soon subsided, but the tinnitus persisted. An examination of the ear was then made, and it was found that there was a little fresh blood on the floor of the left meatus, and that on the front wall, not far from the tympanic membrane, there was a circumscribed tumor which moved backward and forward with each opening and shutting of the patient's mouth. When the mouth was opened widely the tumor receded a certain distance, and then returned to its former position when the mouth was again closed. On further examination it was ascertained that this tumor contained a piece of loose bone, thus showing distinctly that a fracture had occurred at this spot. In Wagenhäuser's case[2] the fracture was

[1] Article by Dr. Alfred Denker. The literature of the subject is given in this article.

[2] Archiv für Ohrenheilkunde, Bd. xxi., S. 269.

produced by the kick of a horse; and ultimately two exostoses were found at the spot in the anterior wall of the meatus where the bone had been splintered.

At the end of his article Denker quotes Bezold as saying that out of 20,000 cases of ear disease, he had found only two in which there had been a recent fracture of the wall of the auditory canal.

IV. NEW-GROWTHS.

Osteoma.—The commonest form of new-growth in the external auditory canal is the *osteoma*. It is encountered both in the form of an exostosis and in that of a more diffuse hyperostosis. The latter variety is more frequent than the former. As the child at birth has simply a rudimentary osseous canal, a mere ring of bone (the annulus tympanicus), we may safely assume that an exostosis or a diffuse hypertrophy of the bony canal is never a congenital, but always an acquired condition. Out of thirteen individuals in whose auditory canals I found hypertrophy of the bone (in the form of exostoses), the youngest was eighteen years of age. In two cases I was able to trace the development of well-marked exostoses to the local irritation accompanying a purulent inflammation of the middle ear. A symmetrical hyperostosis, however, is a much commoner result of this local irritation. The resulting stenosis, or narrowing of the calibre of the canal, is sometimes so great that it is impossible to see the drum-membrane and deeper parts of the canal. In a large proportion of the cases of exostoses, however, no exciting cause whatever can be found. The presence of the bony tumors is discovered by accident, and their development seems to take place independently of any appreciable local irritation. Syphilis, gout, and rheumatism are mentioned by some authors as predisposing causes, but I have not been able, in a single instance, to trace such a connection.



FIG. 87.—Exostoses nearly filling the lumen of the external auditory canal. (After Gruber.)

One of the most interesting questions connected with these bony tumors relates to their rapidity of growth. So far as my own experience goes, I can throw but little light upon this important question. All but four of the patients were seen only once. In each of these four cases the ear was examined repeatedly during a period of several years, and it was clearly established that the bony

tumor was slowly but steadily increasing in size. In the first case (that of a young girl, about eighteen years of age) the new-growth of bone took place in the form of a symmetrical encroachment upon the calibre of the inner end of the osseous canal. At first this stenosis was slight, and the deeper parts could still be seen under good illumination. The drum-membrane had been entirely destroyed; at one or two points in the middle ear, exposed bone was felt with the probe; near by were areas of granulation-tissue, and there was a constant flow of pus over the walls of the canal. In less than three years the hyperostosis had made such progress that it was utterly impossible to see anything of the deeper parts of the ear through the contracted canal. In this case the growth of bone seems to have been a gradual one, and if it had continued at the same rate, complete obliteration of the canal, at the region of the stenosis, in the course of two or three years more, might have been safely predicted. This case passed out of my hands, and I am unable to report its subsequent progress.

In a second case, which was in all respects similar to the one just described, my associate, Dr. Robert Lewis, removed the bony outgrowth, in order to gain the space required for effective cleansing of the middle ear. The case had been under observation for a period of about two years, and, up to within six months of the time when the operation was performed, no special difficulty had been experienced in thoroughly cleansing the cavity. Then the difficulty steadily increased until it became evident that the cleansing would soon be an impossibility. It is now nearly four years since the operation was performed, and during all this period the reproduction of bone has been going on steadily at this same spot (the floor of the canal, not far from the insertion of the tympanic membrane), until the present dimensions of the bony tumor are nearly equal to those which the original one attained.

In a third case, three or four large confluent exostoses developed in the comparatively short period of three years, and then made no further progress during the following two years. When these exostoses ceased growing, the diminution in the size of the auditory canal had progressed so far that I could barely pass a slender silver probe through the constricted part. That no further diminution in the size of the canal took place during the next two years, was shown by the fact that I was still able at the end of that time to pass the same probe through the narrow part of the meatus. I

watched this case with considerable interest, fully expecting that the previous rate of growth of the exostoses would be maintained, and that the resulting obstruction to the discharge of pus from the middle ear would necessitate an operation. As the patient (a dry-goods clerk, thirty-five years of age) promised to come and see me as soon as he observed any material change in the condition of his ear, and as I have not seen him now for several years, I think it quite probable that no further growth of the bony masses has taken place during this period.

Finally, in a fourth case, the rate of growth of the exostoses was apparently more rapid. The patient, a physician, thirty-four years of age, had always heard well, and had never experienced any unnatural sensations in either ear, until toward the end of 1871. He then, for two or three successive days, experienced severe pain in the right ear, and Dr. Hackley, an experienced aurist, who examined the ear, after the severe pain had subsided, found in the meatus a circumscribed swelling which presented the appearance of a furuncle that had not yet reached maturity, or had already begun to subside. In September, 1872, about a year after this condition of the right auditory canal had been observed, the patient consulted me for a troublesome tinnitus in the same ear. On examination I found the canal narrowed by the presence of two broad-based exostoses, situated exactly opposite each other, the one on the anterior, the other on the posterior wall, close to the junction of the cartilaginous with the osseous part of the meatus. Deeper in, was a third exostosis, which overhung the drum-membrane, and apparently pressed against it. Smaller exostoses, occupying almost the same positions as those observed in the right ear, were found in the left meatus.

FIG. 38. — Exostoses springing from the upper wall of the external auditory canal, in close proximity to the short process of the hammer. (After Politzer.)

In March, 1873, I examined both ears a second time, and found that the exostoses in the right auditory canal, at least the two outer ones, had increased noticeably in size. Their summits approached within a millimetre of each other, and the outlines of the walls of the canal presented a perfect resemblance to the old-fashioned hour-glass. On the left side, apparently no change had taken place in the size of the bony tumors.

In October, 1876, I examined the patient for the third time, but

could find no evidence of further growth on the part of the exostoses in either meatus.

It seems reasonably clear, therefore, that there is no fixed law governing the growth of these exostoses. At one time they increase in size at a relatively rapid rate, and then, for a period of years, without any perceptible change in the condition of the immediate surroundings, they show no further signs of growth. An irritating purulent discharge seems to be an exciting cause of their growth in many cases, and yet in others (*e.g.*, the last case mentioned) the growth of bone proceeds without any demonstrable exciting cause.

The prevailing shape of the exostoses which I have seen has been that of a hemisphere, or low, broad-based cone. I have only twice seen a distinctly pedunculate exostosis, and in only one of these cases was the peduncle noticeably smaller than the body of the tumor. In the majority of cases I have found more than one exostosis in the auditory canal. If at first the growths are more or less separate and distinct, at a later stage they will be found to merge so completely the one into the other that a mere undulating surface is presented to the eye of the observer.

The bony character of the tumor is easily ascertained by means of the probe, or, better yet, by means of the paracentesis needle, or the curved, sharp-pointed bistoury. As a rule, the surface of these exostoses is very slightly sensitive, and the sharp point of a knife is felt even less than the pressure of the comparatively broad end of a probe. The skin covering them is exceedingly thin.

There are only two conditions, it seems to me, which justify the surgeon in *recommending* operative interference with these bony tumors. For instance, if there is marked or total deafness in one ear, and the growth of an exostosis in the other auditory canal shuts it up and deprives the individual of the use of his only available ear, operative interference would, it seems to me, be perfectly justifiable and proper. It should first be clearly established, however, that a useful degree of hearing had existed in the ear before the canal became entirely closed by the bony growth. Again, if a chronic purulent inflammation of the middle ear is associated with exostoses, or with a diffuse hyperostosis, of the osseous auditory canal, and if, through the gradual growth of these masses, the canal becomes so narrow that the pus can no longer escape with sufficient freedom, it is clear that the only remaining natural outlet for the pus is through the Eustachian tube. This channel, however, is very often so narrow that comparatively little pus can escape through it.

Stagnation follows, and yet pus continues to form in this closed cavity. Under such circumstances the indications for operative interference are very clear and somewhat urgent. It is rare, however, that either of the conditions described above occurs. Among my own cases, that which was operated upon by my associate is the only one in which operative interference has seemed to me to be plainly indicated.

Dr. J. Orne Green, of Boston, reports[1] the case of a young man in whose auditory canal two exostoses so nearly closed the meatus that the pus secreted in the middle ear could no longer escape freely enough, and death soon followed from the meningitis set up by the retention of the pus. Four days before the patient's death, Dr. Green was sent for. By means of a hand-drill he established a channel, 3 mm. in diameter, through the exostoses. With a larger drill he made an opening behind the ear into the mastoid antrum, and, by means of a syringe, passed a current of warm water from the meatus into the middle ear and antrum, and thence out through the external wound. The operation, however, had been performed too late, and the meningitis went on to a fatal termination. In the case reported by Dr. Mathewson,[2] a large exostosis almost entirely closed the auditory canal, and materially diminished the patient's hearing. Through this mass, which proved to be as hard as ivory, Dr. Mathewson established quite a broad channel by means of drills driven by the so-called dental engine. The operation was completed in less than thirty minutes. To judge from this single experience, this form of motive power presents decided advantages over that supplied by the hand. The drill can be guided with at least equal accuracy, and it can be equally well prevented from penetrating suddenly to a greater depth than is desired. In cases such as that described by Dr. Green it is likely that the doctor would now recommend the more radical plan of removing, by operative interference, not only the exostoses in the meatus but also all those parts of the temporal bone which might be found in a diseased state. The necessity, or lack of necessity, for adopting this more radical course will depend chiefly upon the degree of success attained in cleansing the deeper cavities of the ear, through the re-established meatus, and also upon the degree to which the mastoid process appears to be involved in the inflammation.

[1] Boston Medical and Surgical Journal, April 18, 1878.

[2] Transactions of the First Congress of the International Otological Society. New York, 1877.

Carcinoma.—Instances of the primary development of a carcinoma in the external auditory canal are extremely rare; and, besides, some of the cases which have been reported as such are certainly open to criticism. I know of but three published records which present the facts in such a manner as to really convince the reader that the cases in question were instances of primary carcinoma of the external auditory canal. I refer to those published respectively by Jurka in 1891,[1] by J. Orne Green in 1893,[2] and by Haug[3] in 1894. The one reported by Kessel at a much earlier date[4] can scarcely be accepted as a clearly proven instance of this disease. Prof. von Biesiadecki gave him, for microscopic examination, twenty-two specimens of polypi that had been removed from the ears of different individuals. No histories accompanied these specimens, and no other data were known to Dr. Kessel beyond the scanty information which he could glean from the labels on the bottles that contained the polypi. One of these growths, which was labelled as coming from the external auditory canal, presented to the naked eye all the features of a medium-sized, knobbed wart. A microscopic examination showed it to be provided with hairs, and with sebaceous and ceruminous glands. It therefore, in all probability, grew from some portion of the outer half of the meatus. Its outer surface was composed of a thick layer of epidermis cells which sent prolongations of epithelium deep into the substance of the wart. The presence of numerous balls of concentrically arranged epithelial cells and of nests of these elements seemed to Dr. Kessel to establish the cancerous nature (epithelioma) of the growth beyond a shadow of a doubt. Such a conclusion, however, does not appear to me to be warranted by the facts. The minute anatomy of a perfectly benign wart is so like that of the malignant epithelioma, that without other data (the history of the case, the condition of the neighboring glands, etc.), one would hardly be justified in expressing so positive an opinion. The same elements of doubt surround the case which has been re-

[1] Jurka: "Ueber einen Fall von Carcinom des aeusseren Gehörgangs, mit tödtlichem Ausgange." Inaugural Dissertation, Halle, 1891. (A full review will be found in vol. xxxiii. of the Archiv für Ohrenheilkunde.)

[2] J. Orne Green: "Cases of New-Growths of the Ear," Archives of Otology, vol. xxii., 1893.

[3] R. Haug: "Klinik und mikros. Anat. der Neubildungen des aeusseren und mittleren Ohres," Archiv für Ohrenheilkunde, Bd. 36, Heft 3; 1894.

[4] Kessel: "Ueber Ohrpolypen," Archiv für Ohrenheilkunde, Bd. 4, S. 184; 1869.

ported by Delstanche, fils,[1] as one of primary cancer of the external auditory meatus. I have read this account carefully, and am by no means satisfied—nor, for that matter, does Delstanche himself seem to be—that the disease may not have developed first in the middle ear.

Finally, it is also possible that one of Danziger's two cases of carcinoma of the temporal bone[2] may have originated in the external auditory canal.

Even cases of secondary cancer of the auditory canal are by no means common. Of the two which have come under my observation, one was preceded by a cancer of the middle ear, the other by one that originated in the glands of the neck behind and just below the ear. The former case will be narrated in detail in the chapter on diseases of the middle ear. The facts of interest in the latter case are as follows:

Case XXX.—*Secondary carcinoma of the external auditory canal; operative interference not attempted; death.*

The patient, a female, thirty years of age, and in rather poor general condition, was seen for the first time on the 3d of June, 1872. She stated that nine years previously a hard swelling showed itself on the left side of the neck, close behind the ear. It came without pain, and gradually increased in size until, at the end of five years, it had reached the dimensions of a large egg. It was then removed by Dr. Thomas Markoe, of this city, who found it to be a cystic tumor. The wound healed promptly, and for a period of about three years she remained free from any evidence of a return of the growth. Then, after the birth of her last child, the parts around the ear became swollen and painful. At the end of two weeks the swelling gradually subsided without the formation of pus; the pain disappeared, and the patient remained free from all symptoms referable to the region of the ear for a period of several months. Early in July, 1872, she passed through a second attack of acute swelling of the parts around the ear, and again the attack passed off without giving rise to the formation of an abscess. Unfortunately, it is not stated in my notes whether complete subsidence of the swelling followed both of these attacks, or whether after each a certain degree of permanent swelling remained. It is stated, however, that throughout both of these attacks no appreciable deafness and no tinnitus or other subjective aural symptoms were present. During the following March she experienced a third attack, more severe than any previous one. On this occasion there were both deafness and tinnitus, and at the end of a few days an abundant, and at times bloody, discharge made its appearance in the external meatus. From that time onward the discharge was constant, and the swelling behind and below the ear steadily increased. Early in May Dr. James

[1] Archiv für Ohrenheilkunde, Bd. 15, S. 21; 1880.

[2] Danziger: "Beitrag zur Kenntniss des Felsenbeincarcinoms," Archiv für Ohrenheilkunde, Bd. 41, Heft 1; 1896.

Little, through whose kindness I had an opportunity of examining the patient's ear, opened an abscess situated immediately over the left mastoid process. By aid of the probe he ascertained the existence of a sinus, leading from the cavity of the abscess into the external auditory canal. No denuded bone was found. At the time when I saw the patient, about four weeks later, the opening behind the ear still existed, and pus could easily be forced out through it by pressure made upon the skin in the vicinity. Just in front of the tragus an irregularly shaped hard mass could be felt, which extended backward to the mastoid region. The skin was freely movable over the mass. The outer orifice of the auditory canal was filled with a reddish, mulberry-like, fleshy mass, bathed with a thin, pinkish pus. When manipulated with the probe it bled easily, but yet was quite firm in texture. By grasping the body of the tumor beneath the auricle, and moving it in different directions, I was able to satisfy myself that the fleshy growth in the meatus was simply an outgrowth from it. By means of the probe I ascertained that the cartilaginous wall of the meatus had been pierced (as already discovered by Dr. Little) at a point situated posteriorly and below, and not far from its junction with, the osseous portion of the canal. One of the fibrous gaps in the cartilage (fissure of Santorini) had probably been the place through which first the pus of the abscess and then the offshoot of the tumor had forced their way.

No attempt at an operation was made. The tumor steadily increased in size, and eventually caused the patient's death.

Sarcoma.—Primary sarcoma of the external auditory canal is also a disease of comparatively rare occurrence. Only one case of this nature has passed under my personal observation; and in looking over the different otological text-books and the leading periodicals devoted to diseases of the ear, I have been surprised to find how few instances have been recorded where the tumor unmistakably originated in the walls of the external auditory canal. The first case of which I can find any record is that of Dr. J. Orne Green, of Boston.[1] The patient was a young girl, about seventeen years of age; and the evidence furnished by Dr. Green in regard to the primary character of the tumor seems to be perfectly clear. In the case reported by A. Marmaduke Sheild, one year earlier,[2] the evidence is far from convincing, both as regards the location of the spot where the tumor first began to develop, and also as regards its histological character. This case, therefore, should not be quoted as an instance of primary sarcoma of the external auditory canal, but rather as one of a polypoid growth which has developed at the orifice of a fistula leading

[1] J. Orne Green: "Cases of New-Growths of the Ear," Archives of Otology, vol. xxii., 1893; pp. 284 *et seq.*

[2] A. Marmaduke Sheild: "A Case of 'Sarcomatous' Growth in the External Auditory Canal," Archives of Otology, vol. xxi., 1892; pp. 4 *et seq.*

from the external meatus into the depths of the mastoid process. On the other hand, the case reported by Cohen Tervaert and de Josselin de Jong[1] clearly belongs in the present category. The growth, which sprang from the upper wall, in the middle portion of the auditory canal, was believed to have been thoroughly removed in 1893; but in January of the present year (1897) a new-growth of the same character was found to have developed at about the same spot as that from which the previous tumor had been removed. The first growth had been examined by Dr. Josselin de Jong and pronounced to be a lymphangio-sarcoma; while the second one, which was also examined by the same gentleman, was termed by him a sarcoma plexiforme, or endothelioma.

The third instance on record is that which I published in the autumn of 1880.[2] The history of this case is as follows:

CASE XXXI.—*Primary osteo-sarcoma of the external auditory canal; operation; permanent cure.*

The patient, a strong, healthy girl, fourteen years of age, consulted me on the 25th of May, 1880, for an affection of the right ear, of recent date. About two weeks previously she noticed a sensation of fulness and perhaps very slight pain in the right ear. This was the first intimation that she received that her ear was not perfectly sound in all respects. She had never previously experienced either pain, discharge, deafness, or any other symptom referable to the ear. In the course of a few days a slight discharge was discovered at the outer orifice, and as the sensation of fulness still persisted, the family physician, Dr. A. A. Smith, was called in to see the child. On examination with the speculum and reflected light he discovered that the canal was blocked, near the outer orifice, by a rather solid, fleshy mass, which bled quite freely when he removed a part of it with the snare. Being convinced that the case was not one of ordinary polypus of the ear, Dr. S. referred the patient to me for further treatment. The tumor at this time extended outward almost, if not quite, to the plane of the outer orifice of the auditory canal. It presented a smooth, but slightly uneven surface, felt very firm when pressed upon with the probe, was not at all sensitive, and seemed to spring by a very broad base from the upper and posterior wall of the osseous portion of the auditory canal. The cervical glands were not enlarged. The left ear was perfectly healthy. Twice in succession I surrounded the mass with a loop of No. 37 malleable steel wire, but both times the wire broke when I attempted to make it do the work of cutting through the tissues of the tumor. I then employed a blunt-pointed, curved (flatwise) bis-

[1] Cohen Tervaert and de Josselin de Jong: "Ein Lymphangio-Sarcom (Epithelioma) des aeusseren Gehörganges," Archiv für Ohrenheilkunde, Bd. 43, Heft 1, 1897. (The patient was 57 years of age when the growth was removed the second time.)

[2] "Diagnosis and Treatment of Ear Diseases." New York, 1880. Pp. 120–123.

toury, and endeavored to cut away the growth close to its base. The cutting edge of the knife, however, encountered bony resistance, and I was obliged, for the moment, to remain satisfied with the removal of two fragments, both together equal perhaps to one-third of the entire tumor. Moderately abundant bleeding followed this operative interference, but it ceased in the course of a few minutes. Exploration with the probe failed to discover any central channel or sinus, such as is found in those very similar tumors of the auditory canal which depend upon a limited area of carious bone. As soon as the bleeding had ceased, the patient noticed that her hearing was as perfect as it had ever been. The fragments removed were placed at once in alcohol (90 per cent.), and were then intrusted to Dr. William H. Welch for examination. His report reads as follows: "The larger specimen consists, for the most part, of closely compacted, small, round cells, between which is an ill-defined basement substance or stroma, constituting a reticulum when the cells are shaken out. There are also some larger, endothelial-like cells scattered irregularly among the round cells. The smaller fragment consists more of spindle-shaped cells, with a more distinctly fibrous stroma. The growth is rich in vessels, whose walls are embryonic, being composed simply of an endothelial lining and the surrounding tissue. In some parts of the fragment the epidermis is preserved. From the microscopical appearances the specimen is probably to be regarded as round-celled sarcoma, but the possibility of its being granulation-tissue cannot be wholly excluded."

On the 26th of May I succeeded, by means of as strong a wire as I could pass through Blake's double-mouthed cannula, in removing another portion of the growth. This, too, was submitted to Dr. Welch for examination, with the following results: "The specimen presents in some places the same structure as that which characterized the first fragment; but, in addition, it presents certain points of interest. The central part of the specimen is hard, and, under the microscope, is found to consist of osseous tissue, with wide medullary spaces in which the tissue is rich in cells and fibrillated. The rest of the specimen is composed of a tissue containing numerous round and some irregular cells. Near to the bone the cells are less numerous, more irregular in shape, and have between them a homogeneous, glistening basement substance containing some elastic fibres. Peripherally the cells are more numerous and the intercellular substance less glistening and more fibrillated. There are places where the tissue is of an osteoid character; that is, the cells, with fine processes, are enclosed in spaces in a homogeneous, bony-looking matrix. These seem to represent transition-stages between the sarcomatous tissue and the osteoid tissue on the one hand, and the osteoid and osseous tissue on the other. There are no cells which can be positively claimed as cartilage cells. The tumor seems to be an ossifying sarcoma (osteo-sarcoma), taking its origin, most probably, from the periosteum."

The patient was then examined by Drs. Robert F. Weir and D. B. St. John Roosa, separately—both of them experts in diseases of the ear. They both agreed that the tumor was not an ordinary connective-tissue growth, and favored an early operation for the purpose of extirpating it as thoroughly as possible. They thought it advisable, however, that a microscopic examination should first be made by another expert; and accordingly I removed (June 7th) another moderately large fragment and submitted it to Dr. Francis

Delafield. His report, which was made on the 9th of June, fully confirms that previously made by Dr. Welch. It reads as follows: "The specimen is a small, rounded mass, about the size of half a pea. It was removed from the wound left by a previous operation. It is evident that the specimen consists of a portion of new-growth situated at the edge of the wound. Part of the specimen is covered by a layer of epithelium, and beneath the epithelium is connective tissue with an excess of cells and mucous tissue. The portions of the specimen not covered by epithelium are composed of connective tissue infiltrated with round cells—granulation-tissue. Part of the specimen, therefore, represents a new-growth—part granulation-tissue from a wound. If we compare this specimen with those already examined by Dr. Welch, it is evident that the tumor is one of those composite growths which sometimes grow from the periosteum. It is composed of connective tissue, mucous tissue, bone, and sarcomatous tissue. The prognosis of such a tumor is bad, but not very bad. If the growth can be completely removed, and if the bone is not involved, there may be no recurrence."

In this connection I should state that, during the short period of ten days that elapsed between the two partial operations, the tumor had again fully reached its former size, but not its former degree of hardness. The fragment submitted to Dr. Delafield represented largely this fresh growth.

On the 10th of June the patient was brought under the influence of an anæsthetic (sulphuric ether), and by means of suitable knives (blunt-pointed and curved flatwise) and a sharp-edged steel scoop I removed the entire tumor, together with a zone of apparently healthy skin surrounding its base on all sides. The growth apparently sprang from the periosteum, as the underlying bone felt smooth and hard. A small nucleus of osteoid tissue was found in the centre of the growth. The bleeding was trivial in character. The denuded bone was thoroughly scraped, and, in addition, a solution of chloride of zinc (forty grains to the ounce of water) was painted over all the exposed surfaces. Dr. A. A. Smith and Dr. Robert F. Weir assisted me in the operation.

For about three hours after the operation the patient experienced a moderate degree of pain in the ear. After that she fell asleep and had a good night's rest. On the following morning she said that the ear felt perfectly natural. I examined the canal and found the parts covered with healthy pus and moderately swollen. The deeper part of the meatus and the membrana tympani appeared to be perfectly natural. The watch was heard at a distance of nearly four feet.

On the 19th of June the patient went with her mother to Newport, R. I., and placed herself under Dr. Rankin's care. The treatment consisted in daily cleansings, followed each time by an application of powdered iodoform to the exposed surface of the wound. At the time of her departure from this city only a small depressed ulcer remained; and about the 28th of June Dr. Rankin reported that this had healed and that no further treatment was required. On the 7th of July I had an opportunity of examining the ear. A slight excavation alone remained to indicate the spot from which the growth had been removed. At the very centre of the depression a small dry scab was still visible, but everywhere else the skin was pale, smooth, and perfectly natural in appearance.

A careful inquiry into the family history revealed no instances of cancer or any form of tumor among members of the immediate family. Both parents are strong and perfectly healthy. The maternal grandmother, however died of some uterine disease which may have been cancerous in its nature. An aunt had a tumor removed from her neck. A grandaunt had cancer of the breast. Two second cousins also had cancers.

Several years have elapsed since the removal of the growth, and there have been no evidences of its recurrence.

Myxo-Fibroma.—Two cases of primary myxo-fibroma of the external auditory canal have quite recently been reported by Dr. Haug.[1] In the first of these cases the growth sprang from the upper wall of the cartilaginous portion of the meatus. According to the patient's statement it was first discovered four years previously, and had increased very slowly in size. A microscopic examination revealed it to be a myxo-cysto-fibroma. In the second case the growth was larger: it measured 2½ centimetres in length. After it had been removed with the snare it was ascertained that it sprang partly from the upper wall of the canal and partly from the peripheral portion of the tympanic membrane. A similar growth, it was learned, had been removed from his ear two years previously. On microscopic examination it was found that this polypoid tumor was a myxo-fibroma, highly vascular, and containing two separate collections of cartilage cells embedded in a hyaline substance.

Cysts.—Cyst-like formations, entirely independent of any middle-ear disease, are rarely encountered in the external auditory canal. Only two such instances have come under my personal observation. In one of these cases a small, yellow body, about the size of a No. 6 shot, and consisting apparently of cheesy or sebaceous material, surrounded by a thin envelope of epidermis, projected from the anterior and upper wall of the osseous portion of the meatus, just beyond the junction of the latter with the cartilaginous portion. In the second case a somewhat larger cyst, with cheesy or almost chalky contents, and slightly constricted at its base, sprang from a point on the upper wall of the meatus not more than one or two millimetres distant from the upper limit of the drum-membrane. It was slightly sensitive to pressure made with the end of the probe, and seemed to be quite solid, though of course not so solid as an exostosis. As isolated glands (ceruminous) are sometimes found in the osseous portion of the auditory canal, and especially along the

[1] R. Haug: "Weitere Beiträge zur Klinik und pathologischen Anatomie der Neubildungen des aeusseren Ohres," Archiv für Ohrenheilkunde, Bd. 43, Heft 1; 1897.

upper wall, I think that these cysts with cheesy contents should be placed in the same category with the sebaceous cysts observed in other parts of the body. Their significance in the ear is simply that of pathological curiosities.[1]

In the vicinity of the membrana tympani, cyst-like tumors are occasionally met with, but they are, I think I may safely say, invariably secondary to some affection of the middle ear. In some instances, however, the primary disease recedes so completely that the cyst-like formation in the meatus gains proportionately in individuality, and may even be taken for a tumor of primary development. As the description of these secondary cysts belongs more properly under the heading of diseases of the middle ear, I will say nothing further on the subject in the present section.

[1] The possibility that these cyst-like formations might have been of gouty origin did not occur to me at the time.

CHAPTER IX.

METHODS OF EXAMINING THE MIDDLE EAR.

The symptomatology, in any given case, furnishes information of a certain value in regard to the condition of the middle ear; but there are not a few occasions when it is impossible to derive any aid from this source, and we must then depend wholly upon what we can learn from a direct inspection of the tympanic membrane, from auscultation of the middle ear while air is being forced into it through the Eustachian tube, and from certain alterations in the skin and subcutaneous tissues that lie in close proximity to the pneumatic spaces which form a part of the middle ear. The information that may be derived from these sources is generally sufficient to render perfectly clear the nature of the pathological changes that are going on in this cavity.

Direct Inspection.—Direct inspection is almost always accomplished by means of the speculum and reflected light. In a very few cases it is possible to dispense with the speculum, owing to the large size and unusual straightness of the external auditory canal. This simple inspection of the drum-membrane usually furnishes us with all the information concerning its texture, degree of vascularity, position, etc., that it is possible to obtain. Now and then, however, a doubt arises in the mind of the observer in regard to the correct significance of parts of the picture presented to his eye. These doubts are perhaps more likely to arise in the mind of the experienced observer than in that of a person who has examined comparatively few ears; for he will have already learned by humiliating experience how extremely easy it is to mistake one thing for another in interpreting lesions of the membrana tympani. Hence the importance, in these doubtful cases, of ascertaining how the lesions in question act and look when they are touched and handled, so to speak, with the probe or the curette, and when they are subjected to the influence of air forced into the tympanic cavity by way of the Eustachian tube, or to alternate rarefactions and condensations of the air in the external meatus. As regards the *probing of the drum-membrane* and adjacent parts under illumination, very little need be said. Inasmuch as the eye

of the observer is watching the effects of the instrumental manipulations, no possible harm can be done to the ear. The amount of discomfort caused by such manipulations is very slight, provided they be performed with reasonable gentleness. The Valsalva's experiment, described elsewhere, affords the simplest and most convenient means of inflating the middle ear when it is desired to watch the behavior of the tympanic membrane under the influence of a pushing force exerted from within. But if, as sometimes happens, air cannot be forced in this manner into the middle ear, it will be necessary for an assistant to inflate the cavity either by means of Politzer's method or by aid of the Eustachian catheter. When it seems desirable to rarefy the air in the auditory canal, in order that the observer may have the opportunity of witnessing the behavior of the drum-membrane when moved alternately outward and inward, Siegle's pneumatic speculum must be employed. This instrument consists of a central cylindrical chamber (about an inch and a half in diameter and two inches in length), of either metal or hard rubber, to which is attached a flexible rubber tube about one foot in length. To one end of the chamber a conical speculum is fitted; the opposite end is closed by a glass plate which is placed at such an inclination to the axis of the cylinder that the rays of light used for illuminating the drum-membrane may readily pass through it without any portion of them being reflected back to the eye of the observer. The free end of the speculum is sheathed with soft-rubber tubing, and may therefore be made to fit air-tight into the auditory canal. When the instrument is in actual use the observer, by holding the free end of the rubber tube in his mouth, has it in his power to condense or rarefy the air in the auditory canal, and, while doing so, to watch the effects of these procedures upon the drum-membrane and handle of the hammer.

The methods of studying the condition of the middle ear which I have described above are based upon the direct observation of the drum-membrane. The procedures which I am now about to describe have for their object the introduction of air into the middle ear in such a manner that the physician may hear what takes place in that cavity during the procedure.

Methods of Inflating the Middle Ear.—There are three ways of forcibly introducing air into the middle ear: Valsalva's method, Politzer's method, and that by means of the Eustachian catheter. In inflating the middle ear by *Valsalva's method*, the patient closes both nostrils by grasping the nose with the thumb and forefinger

of one hand, shuts his mouth firmly, and then makes a strong expiratory effort. In this way he compresses the air in the pharyngeal and nasal cavities to such an extent that it seeks an outlet through the Eustachian tubes. If the effort is successful, the physician, who has previously established a communication between his own ear and that of the patient, by means of a flexible auscultation tube, will hear a slight puff or thud, as the air enters the middle ear and distends the drum-membrane. Of the three methods at our command, this is altogether the most unsatisfactory, at least for the purposes of auscultation. Whether the fault lies with me or with the method, I am unable to say positively; but it has disappointed me so often that I rarely use it now when I desire to learn by auscultation what is the condition of the Eustachian tube and tympanic cavity. When I wish to observe the changes that take place in the membrana tympani while air is being forcibly introduced into the middle ear, I still give the preference to Valsalva's method. For this purpose it is undoubtedly more convenient than either of the other two methods. For therapeutic purposes, as will be explained further on, Valsalva's method must be placed third on the list; or, better yet, it should be omitted altogether from the category of therapeutic agents.

Politzer's method is very little better, for auscultation purposes, than that of Valsalva, unless the physician can avail himself of the services of an assistant. If he attempts to inflate and auscultate at the same time he will find the task an extremely difficult one, more so in adult patients than in children. In the latter, as a rule, so little force is required to inflate the middle ears, that one can often perform both acts (auscultation and inflation) with comparative ease. So far as the method itself is concerned, it is in principle essentially the same as that of Valsalva; that is to say, in both methods the middle ears are inflated by compressing the air that is imprisoned in the nasal and naso-pharyngeal cavities to such a degree that it overcomes the resistance offered by the walls of the Eustachian tube, and forces its way into the tympanum.[1] There are two respects, however, in which these methods differ from each other very widely. In the first place, Valsalva's plan necessitates a degree of venous congestion of the head and neck that is directly proportionate to the force used in compressing the air contained in the naso-pharyngeal space. It therefore promotes, in a certain measure, the very pathological condition which, in nine cases out of

[1] Occasionally the air also forces its way through the lachrymal ducts.

ten, constitutes the leading characteristic of the disease. (I refer to the paretic, that is, the dilated condition of the blood-vessels of the middle ear.) Then, in the second place, it furnishes no aid whatever—aside from mere air pressure—toward the opening of the tube itself. Quite the contrary; by increasing the fulness of the blood-vessels it tends to diminish the calibre of the Eustachian tube. Politzer's method, on the other hand, is not less efficient than that of Valsalva in compressing the air contained in the naso-pharyngeal space, while at the same time it is entirely free from the two objections which I have just mentioned. It produces no fulness of the blood-vessels, nor does it diminish the permeability of the Eustachian tube; but, on the contrary, it makes the patient open that channel as widely as he can (by the aid of the muscles which naturally perform this task), just at the very instant when the compressed air in the vault is seeking an outlet through it in the direction of the middle ear.

The apparatus which is ordinarily used in carrying out Politzer's method of inflation consists of three parts, viz., a rubber bag, provided at one end with a hard-rubber nozzle, and of such a size and shape that it can readily be grasped with the hand; a short piece of rubber tubing, of such a small calibre that the nozzle of the bag will fit it tightly; and, lastly, either a curved cylindrical or a bulbous nose-piece. So many modifications of this apparatus have been introduced during recent years that one can no longer send to an instrument-maker for a Politzer's apparatus, and be at all sure that he will receive an instrument bearing a reasonably close resemblance to that which Politzer introduced about thirty years ago. In my judgment, Politzer's original instrument, or, at all events, that which he was in the habit of using in 1869, is more thoroughly practical and efficient than any of the later modifications. The bag, which is made of soft black rubber, is pear-shaped, and ribbed longitudinally at intervals of about one inch (see Fig. 40). The egg-shaped white-rubber bags and the flask-shaped green-rubber ones are much more difficult to manipulate successfully, especially if the operator's hand is rather small. The bag which I have used habitually since the spring of 1870 was purchased of Leiter in Vienna, and is to-day apparently as perfect as when it left the maker's shop.[1] A second one, purchased at the same time, was injured by being left in an exposed closet during the coldest part of

[1] This sentence was written in 1889. Shortly afterward, the rubber began to show signs of cracking, and I was obliged to purchase a new one.

the winter. The rubber became hard and brittle, and the manipulations to which the bag was then subjected caused it to crack open.

Some of the rubber bags are provided with a small opening protected by a valve, which closes the aperture the instant the bag is compressed. The advantage claimed for these bags is that the danger of suction is thereby prevented. The truth is, that the suction-power exerted, when our grasp upon the bag is relaxed, is simply diminished in degree, but not entirely counteracted or rendered null. Personally, I prefer the original form of rubber bag, which has no opening except that which is provided at the nozzle. To prevent suction when this form of bag is used, it is simply necessary to acquire the habit of never relaxing our grasp upon the bag until we have finished wiping the nose-piece with the towel (in Politzer's method), or until we have withdrawn the nozzle of the bag from the mouth of the catheter (in catheterization of the Eustachian tube).

With regard to the rubber tubing which connects the nose-piece with the nozzle of the bag, I may say that it is not an indifferent matter what sort of tubing is used for this purpose. In the first place, it is a very common error to use too long a piece. The advantage of a long piece is, that the operator, in the act of compressing the bag, can swing his arm freely without risk of violently twisting the nose-piece in the patient's nose. This advantage, however, is more than offset by the loss of power which is spent upon the elastic walls of the tubing. A piece of black-rubber tubing, six or seven inches in length, with a calibre of about four millimetres, and walls at least a millimetre and one-half in thickness, will be found to answer the desired purpose very well. It must be remembered, however, that a bag provided with such a short piece of rubber tubing is more difficult to manage successfully than one with a piece ten or twelve inches long. The arm must be kept almost perfectly still, and the muscles of the forearm and hand must do the entire work.

Not the least important part of a good Politzer's apparatus is the nose-piece. In adults the slightly curved, cylindrical, hard-rubber nose-piece will be found entirely satisfactory in the great majority of cases. In children under four or five years of age, in whom the nasal orifice is quite small and tender, a nose-piece consisting of a spherical or cone-shaped glass bulb will usually be found preferable to the cylindrical one. I have always found it a difficult matter to purchase ready made a good hard-rubber cylindrical nose-

piece. It makes very little difference whether the proper curvature has been given to the instrument or not, as by means of heat we can readily obtain any curve that we may desire. The chief difficulty lies in the smallness of the calibre given to the rubber cylinder of the desired size externally. Thus, for example, I selected, from a large number of nose-pieces kept for sale by one of our best instrument-makers, the one having the largest calibre. The measurements were as follows: internal diameter, $1\frac{3}{4}$ mm.; external diameter, $4\frac{1}{2}$ mm. The nose-piece of the Politzer's apparatus which I use habitually gives the following measurements: internal diameter, $2\frac{1}{4}$ mm.; external diameter, $3\frac{1}{2}$ mm. A simple comparison of these

Fig. 39.—Nose-piece of Politzer's Apparatus. (Natural size.)

figures will show at once the superiority of the latter nose-piece. It occupies less room in the patient's nose and allows a much greater quantity of air to be forced into the naso-pharyngeal cavities in a given period of time and with a given expenditure of force used by the hand in compressing the rubber bag. The proportions of the longer and shorter arms of the nose-piece, and the degree of curvature which it should possess, are correctly given in the accompanying cut (Fig. 39). As already stated, if the instrument offered for sale does not possess the proper degree of curvature, the desired shape can easily be obtained by heating the instrument over the flame of a spirit lamp until it becomes perfectly pliable. In his treatise on otology,[1] Politzer states that he is now in the habit of using exclusively an elastic nose-piece (as suggested by Löwenberg) in the place of the curved hard-rubber one. He remarks, however, that a certain degree of practice is necessary in using such a nose-piece, as one is very apt, in closing the nostrils over the soft-rubber tube, to obliterate its calibre entirely. The advantages claimed for this form of nose-piece are, that it is pleasanter for the patient (that is, less painful than where the hard-rubber one is used) and less likely to produce nose-bleed. Furthermore, the argument is brought forward that in suspicious cases the patient can, at a trifling expense, be provided with his own special nose-piece. I have tried

[1] "Lehrbuch der Ohrenheilkunde für praktische Aerzte und Studirende," von Dr. Adam Politzer. Stuttgart, 1878.

this flexible form of nose-piece, but cannot say that I like it. I have also tried the plan of slipping a short piece of soft-rubber tubing over the ordinary curved hard-rubber nose-piece, and find it useful in cases where the unprotected instrument causes nose-bleed. In the great majority of cases, however, I find the curved, cylindrical, hard-rubber nose-piece less troublesome to manage, and more effective, than any other instrument of which I have any knowledge.

Before entering into the details of Politzer's method of inflation, I ought to state that this operation of suddenly inflating the middle ears, although in the great majority of cases a perfectly safe procedure, should never be performed until after the condition of the

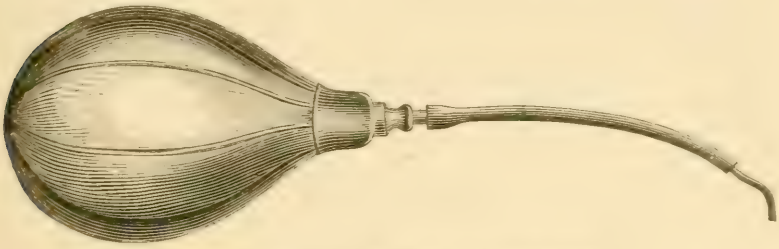

Fig. 40.—Politzer's Bag (one-third natural size).

drum-membranes and middle ears has been ascertained by direct inspection with the speculum and reflected light. I can recall the case of a gentleman, an army officer, in whose middle ear there were bands of adhesions which bound the membrana tympani down upon the promontory, and probably connected it, by some groups of fibres, with the stapes. I did not at that time appreciate the danger of forcibly inflating the middle ear under such circumstances, and consequently made no special effort to moderate the pressure exerted upon the bag. The immediate effect of the inflation was to rupture some small blood-vessel in the middle ear and fill the cavity with blood, which speedily must have become clotted; and, furthermore, it is not unlikely that the stapes was torn from its connections with the foramen ovale. The patient, who depended chiefly upon that ear for his power of hearing, at once noticed that the ear felt full, and that everything sounded less distinct than before. He never came to see me afterward, and I accidentally heard, about a year later, that the hearing in that ear had not returned to its previous degree of acuteness, and that my interference was looked upon by the patient as the cause of this aggravation of his disability. On more than one

occasion, in former years, I have ruptured a highly atrophied drum-membrane or a so-called "cicatricial spot," by employing too great force in compressing the rubber bag. I have never known any harm to come from such ruptures of an atrophied or cicatricial drum-membrane. At the same time the effect of an accident like this upon the mind of the patient would be very likely to be of a character prejudicial to the physician who happened to be responsible for its occurrence.

Fig. 41.—Proper Method of using Politzer's Inflation Apparatus. (After Politzer.)

Politzer's Method of Inflating the Middle Ear.—With regard to the different steps of Politzer's method of inflation, very few words will suffice to explain the entire procedure. The patient is told to take a little water into his mouth, and to hold it there, with closed lips, until the physician says, Swallow! At this signal[1] he should forthwith swallow the water. The physician, on his part, is to hold the bag in his right hand, and then, as soon as the patient has taken the water into his mouth, he is to introduce the nose-piece into the patient's left nostril, using, if necessary, the left hand to aid him in accomplishing this. When the nose-piece of the instrument is in its proper position on the floor of the nasal passage, the physician should at once compress the nostrils over the rubber nose-piece, and give the patient the signal to swallow (Fig. 41). The act of compressing the bag and forcing air into the nasal cavities should follow the signal almost instantly.

This whole procedure, which seems to be a very simple affair, is found by many physicians to be at first quite difficult of execution. It may therefore prove useful to some if I mention in detail the difficulties which beset the operation. In the first place, it is a common mistake to allow the patient to take too large a quantity of water into his mouth. As the water is taken merely for the purpose of facilitating the act of swallowing, a mere sip is all that

[1] If the patient is very deaf, the operator may use some other signal, such as a nod of his head, or a nudge with his knee.

is necessary. If a mouthful is taken, the act of inflation is just as likely to force water out of the patient's mouth, over the physician's clothes, as it is to drive air through the Eustachian tube into the middle ear. Then again, the accident of "swallowing the wrong way" is much more likely to occur when a large than when a small quantity of water is taken.

In the second place, beginners are very apt to delay giving the signal to the patient too long a time after the nostrils have been compressed. The signal should be given and air should be forced into the naso-pharyngeal space as soon as possible after the operator has closed the nasal passages; for it must not be forgotten that, with both nose and mouth closed, the patient is unable to breathe, and consequently is rapidly approaching a condition of discomfort in which a prompt performance of the act of swallowing in response to the physician's signal is no longer possible. Some patients find it very difficult not to open their mouths at the instant of performing the act of swallowing; others, and especially children, do it purposely, in order to escape the unpleasant sensation caused by the sudden compression of air in the nasal cavities. The main purpose of the act of swallowing, in Politzer's procedure, is to render the naso-pharyngeal cavity a closed space by interposing the soft palate as an air-tight diaphragm between the oral and naso-pharyngeal cavities. There are other ways, however, in which the same result may, in large measure, be attained. For instance, the patient may be told to say "hic" or "hoc," or to distend his cheeks, by either of which means the desired shutting off of the naso-pharyngeal cavity will be effected just as perfectly as by the act of swallowing. On the other hand, it must not be forgotten that these substitutes do not open the Eustachian tube as does the swallowing procedure. Consequently, in every-day practice the latter plan will be found to give greater satisfaction than either of the other two methods.[1]

[1] In not a few cases difficulty is experienced by the physician in timing rightly the compression of the rubber bag. If he compresses it an instant before the proper moment, the advancing column of air will enter the patient's mouth and drive out all the water before it can be swallowed. But if, on the other hand, the compression take place an instant or two later than it should, the larger part of the compressed air will find its way into the patient's stomach. In either case the physician will probably fail to inflate the middle ears. The proper way of overcoming this difficulty is to watch the movements of the thyroid cartilage after the patient has been told to swallow. The proper moment for compressing the bag is while this cartil-

In the next place, if we wish to spare our patients unnecessary pain or the discomfort of a nose-bleed, it is necessary that we should introduce the nose-piece of Politzer's apparatus with some degree of care. The large conical glass nose-piece can scarcely be used in such a clumsy or rough manner as to cause either pain or nose-bleed; but the curved, cylindrical, hard-rubber instrument is very well adapted to cause both, unless introduced gently and in one particular way. Thus, for example, in each nasal orifice there is but one spot where the instrument can properly be allowed to remain while the nostrils are firmly compressed over it, viz., on the floor of the canal, as far as possible from the median plane (the septum narium). In this position, the instrument, if it has not been pushed in too far, will cause very little discomfort. If the nose-piece is properly curved, it is an easy matter to avoid the danger of pushing it in too far, by always allowing the straight portion of the instrument to rest against the patient's upper lip, in the direction of a line running from the outer angle of the nasal orifice to the outer angle of the mouth.

Finally, the question remains to be considered, how far we should modify the different steps of Politzer's procedure when the patient is a young child. I have already alluded to the fact that a spherical or cone-shaped glass nose-piece will be found better adapted to young children than the curved hard-rubber instrument. The pressure employed in compressing the bag must also, as a rule, be decidedly less than that usually employed in adults. The device of having the patient swallow a little water at a given signal can scarcely be resorted to in children under four years of age. In an infant it is simply necessary to adjust the glass bulb to one nostril, and then, while the other is kept closed by a finger of the same hand that holds the bulb in position, to compress the bag. It makes no difference whether the child's mouth is open or shut; the inflation seems to succeed equally well in both cases. In children of three, four, or five years of age, it is often an easy matter to teach them to distend their cheeks at the moment the signal (blow!) is given. If pain or a sense of fulness in the ear is complained of immediately after the inflation, it is a good plan to let the child swallow two or three mouthfuls of water, in order to facilitate the

aginous box ("Adam's apple") is rising to a higher level, this phenomenon corresponding accurately with the application of the soft palate against the posterior pharyngeal wall and with the opening of the Eustachian tubes by muscular action.

escape of air that may have become as it were imprisoned in the middle ear.

Finally, the operator must not forget to give the nose-piece a thorough cleaning before he puts the instrument away. Under ordinary circumstances I always place this part of the instrument in scalding water; and whenever I use it upon a suspicious case I first place it in scalding water for a few moments and then allow it to remain for a longer time in a strong bichloride of mercury solution.

The employment of Politzer's method for therapeutic purposes might properly be discussed in this connection. For practical reasons, however, I think it will be better to take up this subject in connection with the individual diseases in the treatment of which this procedure plays an important part.

Catheterization of the Eustachian Tube.—Of the three methods of inflating the middle ear mentioned at the beginning of this section, Valsalva's and Politzer's have been sufficiently described, and there remains still to be considered that by means of the Eustachian catheter. For purposes of auscultation this method is justly preferred to both the other methods. When the catheter is used, the air passes through the Eustachian tube into the middle ear in a continuous current of one or two seconds' duration. This steadiness and long duration of the current afford the physician ample opportunity to listen deliberately to the character of the sounds which it produces. For purposes of diagnosis, therefore, this method possesses a decided superiority over the other two.

The Eustachian catheters offered for sale in the surgical-instrument shops are made of hard rubber, of German silver, or of coin metal. Those made of German silver have nothing to recommend them besides their cheapness. A well-made hard-rubber catheter is an excellent instrument, and leaves very little to be desired. It is very difficult, however, to find a well-made hard-rubber catheter; the calibre is rarely as large as it should be, or else, if the calibre is sufficiently large, the total diameter of the instrument is so great that we can use it only in exceptional cases. A good serviceable Eustachian catheter should have a calibre of about two and one-fourth or two and one-half millimetres, and a total diameter of not more than three and one-half millimetres. This proportion of calibre to total diameter is scarcely attainable in an instrument made of hard rubber. The largest rubber catheter that can ordinarily be bought in the shops measures nearly four and one-half millimetres

in its total diameter, while its calibre measures only two millimetres. For the majority of patients this instrument is too large, and yet its calibre is barely large enough to allow a current of air of the requisite force to reach the orifice of the Eustachian tube. On the whole, therefore, the silver catheter, if made of coin metal and properly proportioned, will be found to give the greatest satisfaction. I warn my readers, however, that very many of the silver catheters sold in the shops are even less serviceable than those made of hard rubber. The calibre is not one whit larger, in proportion to the total diameter, than that of the average rubber catheter; and when such is the case the latter instrument has decided advantages over the former. There is also another respect in which the silver instrument may be defective: the rim of the free end is often so sharp as to cause the patient pain, either during its passage through the nose, or while it lies in the mouth of the Eustachian tube. This defect, however, can easily be remedied.

Fig. 42.—Eustachian Catheter. (Natural size.)

With regard to the curve which a good Eustachian catheter should have, I may say that the one represented in the accompanying cut is that which I have found suited to the great majority of adult patients. Some of my colleagues use a straighter instrument, and others, one of even greater curvature; from which facts it is proper to draw the conclusion that the middle ear may be successfully inflated by variously curved catheters. To secure the most effective inflation, however, we should give the catheter such a curve that, when it is in position and air is forced through it, the direction of the escaping current will be the same as that of the Eustachian tube itself. The common error, so far as my observation goes, is to give the instrument a curve of too short a radius, which causes a large part of the force of the current of air to spend itself upon the upper wall of the Eustachian tube. In children from five to about twelve years of age, it will be found better to use a catheter that is even less curved than that represented in the cut; or one, at all events, in which the curve begins at a point considerably nearer the free end than is the case in this instrument.

The rubber bag used for inflating the middle ear according to Politzer's method answers equally well for inflating this cavity through the Eustachian catheter. These bags are almost always provided with a rounded or somewhat olive-shaped end-piece, which may be screwed on or off at pleasure. When the catheter is to be used, it is a very common custom to substitute for this end-piece one that represents accurately a section of a cone, and that can therefore be made to fit air-tight into the cone-shaped orifice of the Eustachian

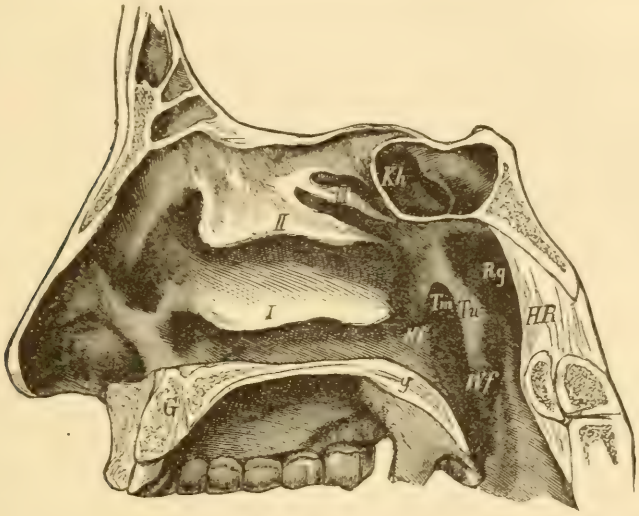

FIG. 43.—Anatomical Relations of the Nasal Passages and Pharynx to the Eustachian Tube. I, II, III, Lower, middle, and upper turbinated bones; *HR*, posterior wall of pharynx; *Rg*, Rosenmüller's fossa; *Tu*, prominence separating the tubal orifice from Rosenmüller's fossa; *Tm*, orifice of Eustachian tube; *G*, hard palate; *g*, velum palati; *Kh*, cavity of sphenoid bone. (After Hartmann.)

catheter. I have tried both of these end-pieces, and give the preference unhesitatingly to the rounded or olive-shaped one. When this is applied to the mouth of the catheter it simply touches the circular rim of the latter at all points, but does not in any sense fit into the opening. Nevertheless, the closure thus effected is sufficiently air-tight for the desired purpose, viz., that of inflating the middle ear. On the other hand, this loose sort of a fit gives the rounded end-piece a decided advantage over the tight-fitting conical one—viz., it can be removed instantly from the mouth of the catheter without disturbing the latter's position in the slightest degree, without causing the patient any of the discomfort which is very apt

to accompany our efforts to disengage the tightly fitting conical end-piece, and, finally, without risk of exerting suction-power upon the mouth of the Eustachian tube.

While I believe that a written or *vivâ voce* description of the proper course to pursue in introducing the catheter into a patient's Eustachian tube may aid a beginner in his efforts to perform this operation successfully, I am quite positive that the greater part of the lesson must be learned by actual experience. It is of comparatively little use to say: at this point, turn to the left; at that, to the right, and so to direct the beginner's manipulations from the commencement to the end of the operation. For the beginning, it is true, we can lay down a sharply defined rule, which will hold good for all cases; for the end, also, we can give directions which will secure success in certainly the great majority of cases; for the intermediate portion, however, we can simply say: follow the course taken by the instrument, even if it perform a complete revolution in its progress to the naso-pharyngeal space. These different steps of the procedure I may briefly describe as follows:

The physician should sit directly facing the patient, and on his right hand, within easy reach, should be his rubber bag, auscultation-tube, and a bowl or goblet, partially filled with water, and containing five or six catheters of different sizes and degrees of curvature. He should have his forehead-mirror in position, ready for use, as he may at the very beginning find it desirable to examine, under illumination by reflected light, the patient's anterior nares. Everything being in readiness, the operator should place the fingers of his left hand firmly upon the patient's forehead, and with the end of his thumb he should elevate as much as possible the end of the patient's nose—the object of the latter procedure being to straighten the entrance to the nasal passage and in so far to facilitate the introduction of the catheter. This instrument should be held lightly by the physician, between the thumb and forefinger of his right hand, and at no time should force be used in overcoming any obstacles that may be encountered. Just within the nasal orifice, the floor of the nasal passage rises up in the form of a ridge, the inner or deeper side of which is more abrupt than the outer one. When the catheter is first introduced into the nasal orifice, its outer end should be at a somewhat lower level, though in some cases we may begin at once with the instrument in a nearly horizontal position. To pass it beyond the ridge, and engage it in the lower nasal passage, the physician must elevate the ring end of the instrument until

it occupies a nearly horizontal position. It is at this stage of the operation that the beginner is very apt to make a mistake. Instead of passing the catheter along the floor of the nasal canal, he slips it over the upper surface of the inferior turbinated body, and, on approaching the naso-pharyngeal space, wonders why his efforts to turn the instrument into the mouth of the Eustachian tube cause the patient such great distress. A glance at the illustrations of this region, in some good treatise on anatomy, will show how easy it is to make this mistake. It is only necessary to push the beak of the instrument a short distance beyond the summit of the ridge, and we shall find it slipping only too easily along the wrong channel. When the catheter has been pushed beyond the ridge, and is actually resting upon the inferior turbinated body, the elevation of the ring end of the instrument will not correct the error unless the catheter be withdrawn a certain distance. In the first stage of the operation, therefore, it is important to hug the floor of the nasal passage with the beak of the catheter, at least until the instrument has passed beneath the inferior turbinated body, and is well engaged in the lower channel. As already stated, it is better, from this point onward, to let the instrument find its own way. By this I mean that if the catheter encounters some obstacles, we should abandon the attempt to push it onward in a certain fixed manner,—*i.e.*, with the beak always pointing downward and backward,—and should rotate the instrument slowly, while keeping up a gentle pressure from behind, until we find a position in which it no longer encounters opposition, but yields to the pressure which tends to drive it farther inward toward the naso-pharynx. As we wish the instrument, on first reaching the cavity, to lie with its beak turned directly downward, we should begin at once, after passing the obstacle referred to, to rotate the catheter back toward the desired position. If we fail in our efforts to overcome the obstacle encountered, we must either resort to an instrument of smaller diameter, or try to reach the Eustachian tube by way of the nasal passage of the opposite side. The latter course will usually be found the preferable one. When the catheter is in the naso-pharyngeal space, with its beak turned directly downward, we should first make sure of our bearings by pushing the instrument onward until we feel the resistance offered by the posterior pharyngeal wall. When the catheter is in this position, we know that if we rotate it far enough we shall carry the beak into what is known as Rosenmüller's fossa, a slight depression located just behind the mouth of the Eustachian tube. Hence, if we

wish to introduce the instrument into the latter cavity, we must draw it back a distance of two- or three-eighths of an inch, and then rotate it through an arc of about one hundred and thirty-five degrees (or until a line drawn through the plane of the ring attached to the catheter shall pass through the outer angle of the patient's eye). If we rotate the beak of the catheter first into Rosenmüller's fossa, and then draw it back a short distance, we can often feel the end of the instrument pass over the rounded eminence (*Tw*, in Fig. 43)

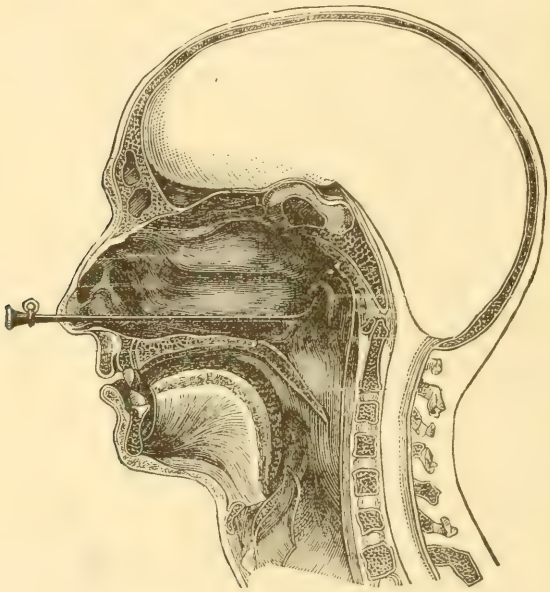

Fig. 44.—Eustachian Catheter in position. (After Politzer.)

which constitutes the inner lip of the mouth of the Eustachian tube. As the distance of the tubal orifice from the posterior pharyngeal wall varies in different individuals, the method last described, of guiding our movements by aid of the sense of touch, rather than by rough estimates of distance, is the one to which most aurists, I think, give the preference. In some individuals the landmark which I have just described is so feebly developed, or the surrounding parts are so swollen, that the operator feels doubtful whether he has reached the mouth of the tube or not. In such cases the Giampetro-Löwenberg method will be found useful. According to this method, the catheter is to be rotated toward the Eustachian tube of the op-

posite side, and when its beak occupies a horizontal position, as indicated by the metal ring, the instrument is to be drawn forward until the resistance of the posterior edge of the septum is encountered. The catheter is then to be rotated in the opposite direction through an arc of at least one hundred and eighty degrees, into the mouth of the Eustachian tube which if is desired to reach. In all three methods, but especially in the one last described, the physician would do well to grasp the body of the catheter with the thumb and forefinger of the left hand before he performs the act of rotation with his right hand. In any event he will have to grasp it in this manner after the instrument finally reaches its proper position, as the right hand will be required for other purposes. The support thus afforded to the catheter is a very firm one, as the last three fingers of the left hand find a strong resting-place on the bridge of the patient's nose, or on the lower part of his forehead (Fig. 45). So long as the operator's fingers press firmly against the patient's skull, he need have very little fear of the disturbing influence of a sudden motion of his head upon the position of the catheter.

FIG. 45.—Showing how the Catheter is to be held in a firm position and how the inflation bag is to be used in forcing air into the catheter. (After Politzer.)

When the physician believes that the beak of the instrument is lying in the mouth of the Eustachian-tube, he should give the patient one end of the auscultation-tube to place in the meatus of the corresponding ear, and should fix the other end tightly in his own auditory canal, preferably the left one.[1] With his right hand he should then grasp the rubber bag, and apply the hard-rubber nozzle of the instrument to the mouth of the Eustachian catheter. If the latter instrument is in the right position, and the Eustachian tube is not unnaturally contracted, he will hear the air streaming as it

[1] If the presence of the instrument in the naso-pharyngeal space causes the patient great discomfort, and especially if the act of swallowing is accompanied by pain, the physician may safely assume that the beak of the catheter is not lying in the mouth of the tube.

were into his own ear; and if, while he is thus inflating the tympanic cavity, the patient should perform the act of swallowing, the physician will suddenly notice a marked increase in the sound produced by the in-rushing air—a phenomenon due to the sudden enlargement of the tubal channel. If the catheter, however, occupies a wrong position, he will probably still hear the air streaming out of the end of the instrument, but it will no longer seem to be escaping into his own ear; the sound will appear to be more distant and less distinct.

In withdrawing the catheter from the nasal cavities, no special precautions are necessary. The instrument is first to be rotated back to its original position, with the beak pointing downward, and then it is to be withdrawn gently from the nose.

So far as the operation of crossing over from one nasal passage to the Eustachian tube of the opposite side is concerned, very little need be said in addition to the preceding account. It is simply necessary to use a catheter with a curve of slightly greater length, in correspondence with the greater distance of the tubal orifice from the nasal passage through which the instrument is passed. In all other respects the precautions to be taken are precisely the same as those which have been recommended for the more direct operation.

In former years I experimented with catheters having a double curve, and thought at the time that in certain cases they enabled me to accomplish that which I had failed to do with the ordinary single-curved instruments. As time went on, however, I became convinced that these double-curved instruments possessed no special advantages over the ordinary type. Those interested in the subject will find a full description of these double-curved catheters, by Dr. Henry D. Noyes, of this city, in the Transactions of the American Otological Society for 1870. In the volume for 1872 a description will also be found of the so-called "faucial catheter," an instrument devised by Dr. Oren D. Pomeroy, of this city. I have had no personal experience with the use of this instrument, and must confess that I am prejudiced, on *a priori* grounds, against its employment.[1]

[1] I believe that every physician who proposes to devote himself exclusively or largely to the treatment of diseases of the ear should acquire the power to pass a Eustachian catheter, not only successfully—in the sense of lodging its beak in the niche of the pharyngeal end of the Eustachian tube—but also gently. But I also believe that he may practise his specialty for a period of several years before he will stumble upon a case in which the employment of this instrument may be said to be strictly necessary—either for diagnostic or for therapeutic purposes.

Other Methods of Investigating the Condition of the Eustachian Tube.—Besides the methods I have already mentioned, there are other ways of ascertaining the condition of the pharyngeal end of the Eustachian tube. Thus, for example, in a few cases it is possible, by means of a Gruber's speculum introduced as far as possible into the nasal passage, and reflected light, to obtain a fair view of the mouth of the Eustachian tube. The mirror, however, must not be used in the manner which I have recommended (p. 15) for examinations of the ear; success can only be obtained when the eye of the observer is placed at the central aperture. This direct method of observation has been still further perfected by the invention of what are known as Zaufal's specula, which may be carried in even to the very entrance itself of the tube. In many cases a good view of the tubal orifice and adjacent parts can be obtained by means of the laryngeal mirror and reflected light. Finally, a very good idea of the condition of the naso-pharyngeal mucous membrane, and of the relations of the surrounding parts to the tubal orifice, may be formed from an exploration of this region with the forefinger (by way of the mouth).

CHAPTER X.

CLASSIFICATION AND ETIOLOGY OF DISEASES OF THE MIDDLE EAR.

CLASSIFICATION.

The vast majority of the diseases of the middle ear which come under the physician's observation may most conveniently be placed under one or the other of the two great subdivisions—*Suppurative Inflammation of the Middle Ear* and *Non-Suppurative or Catarrhal Inflammation of the Middle Ear;* and those which cannot be placed in one of these two large subdivisions will be found to belong under some one of the following heads: *Syphilis*, *Tuberculosis*, *New-growths*, and *Traumatic Influences*. The classification of middle-ear inflammations as suppurative and non-suppurative or catarrhal is based entirely upon the fact that in the first of these a purulent exudation takes place in the tympanic cavity, while in the second the exudation consists of serum or mucus, or else there is no perceptible amount of exudation. In the first class the pus, as a rule, finds an outlet for itself through the tympanic membrane into the external auditory canal; but in exceptional cases the discharge may take place by way of the Eustachian tube, the tympanic membrane remaining intact.

So far as the etiological factors are concerned, there is often no fundamental difference between these two classes. Furthermore, it is scarcely possible, in the present state of our knowledge, to make a classification of diseases of the middle ear upon the basis of the different etiological factors which produce them. In all the active inflammations, for example, it is tolerably certain that either a single species of micro-organism, or a combination of several varieties, is the exciting agent of the disease.

But there are other grounds upon which a classification may be constructed. Thus, for example, there is very often a localization of the inflammation in some one part of the complex system of cavities which together constitute the middle ear. The locality affected may be the Eustachian tube, or the vault of the tympanum, or the

mastoid region; and the recognition of this fact furnishes a sufficient warrant for establishing a classification which is based upon these anatomical differences. Then again, the lesions produced by the disease may be taken as a basis for still another classification. Thus, for example, when the bone structure is invaded and a portion of it dies, we speak of the case as one of bone caries or necrosis; when the mucous membrane manifests a decided tendency to produce new connective tissue, we term the inflammation proliferative, or hypertrophic, or hyperplastic; and when this same mucous membrane, in its character of a periosteum, produces new bone tissue, we qualify the inflammation as an ossifying or hyperostotic otitis. Finally, the differences in the products of a middle-ear inflammation may furnish a convenient basis for establishing certain distinctive classes. Thus, for example, when this product consists mainly of serum, the term otitis media serosa is often employed; when blood forms a noticeable part of it, the expression otitis media hæmorrhagica is preferred; and, finally, when stringy mucus constitutes a prominent characteristic, we speak of the case as one of otitis media mucosa. All these different terms are used to a greater or less extent by writers on otological subjects, and they certainly serve a most convenient purpose.

GENERAL ETIOLOGY.

The causes of inflammations of the middle ear are recognized to-day as being more numerous than they were supposed to be a few years ago; and it is reasonably certain that in any given case several of these causes co-operate at the same time to bring the disease into activity; but we are as yet unable to assign to each of these different factors its proper share in the work. *Micro-organisms*, as I have already stated, undoubtedly play a very important part in the etiology of middle-ear inflammations, but it is equally certain that unless the mucous membrane of this system of cavities, or of some contiguous region like the pharyngeal vault, be previously put into a vulnerable condition, these micro-organisms will be powerless for evil. An inflammation of the middle ear, for example, often results from "taking cold." This is the apparent cause in a very large percentage of all such inflammations. If we analyze what takes place in the nasal and pharyngeal mucous membrane when the heated and generally perspiring surface of the body is adequately chilled—which is the first step in the process of "taking cold"

—we shall find that this membrane becomes the seat of a well-marked hyperæmia. The blood-vessels are greatly distended, and in consequence they become, for a certain length of time, paretic. This is doubtless the time when the micro-organisms which are known to be almost constantly present in the mucus of the pharyngeal vault are able to gain an entrance through the epithelial structures into the lymphatics and the blood-vessels of these parts. In other words, this mucous membrane, which, in its ordinary state of health, cannot be invaded by these pathogenic micro-organisms, now lacks the power to successfully resist such an invasion; in brief, it has now become vulnerable. The establishment of such a *vulnerability* in the naso-pharyngeal mucous membrane is, therefore, the first stage of the disease in a very large proportion of cases of middle-ear inflammation. The next and later stages follow very naturally upon the first one. The pathway leading to the middle ear is not always the route chosen by the advancing horde of pathogenic organisms, and so this particular region may escape. They are very likely, for example, to travel downward along the bronchial tubes. But in other instances—and these constitute a large percentage, though scarcely a majority, of all cases of "cold in the head"—they advance along the Eustachian tube and give rise to some form of middle-ear inflammation. This advance, doubtless, follows the course of the blood and lymph channels, and does not take place over the surface of the mucous membrane.

There are unquestionably other ways in which a condition of vulnerability may be established either in some part of the middle ear or in the pharyngeal vault; this latter being the more common starting-point of such middle-ear inflammations. Thus, for example, the exanthematous diseases may, in some way at present unknown to us, confer upon the tympanic mucous membrane a high degree of vulnerability to the attacks of at least some of the pathogenic micro-organisms (the streptococci, for example). The same is true, in perhaps a lesser degree, of such diseases as typhoid fever and the grippe (or epidemic influenza). Then, again, the diabetic condition robs the tissues of various parts of the body—and of this region among the rest—of its normal defensive powers against bacterial invasion. Finally, the entrance of salt water into the middle ear—either as a result of sea-bathing or from the employment of a solution of salt in a nasal douche—often prepares the way for an inflammation of this region which may prove to be of the most serious nature. Under these circumstances the salt alone can scarcely

be held responsible for an inflammation of such severity. Its direct power for evil probably extends no further than to cause a marked degree of hyperæmia; but, then, on the other hand, this latter condition of vaso-motor paresis is the very one which I have already mentioned as being, in all probability, one of the prerequisites for a successful bacterial invasion.

In addition to these more direct causes of inflammation of the middle ear, there are others which might be designated as collateral causes. While in most cases it is probably correct to speak of them as playing only an indirect part, in a large minority they should be credited with the higher rôle of direct predisposing causes. I refer more particularly to the presence of *hypertrophied lymphoid tissue* in the vault of the pharynx. This pathological condition, as is well known, often keeps the blood-vessels of the middle ear for weeks or months at a time in a dilated condition, and in this manner predisposes this region to inflammatory attacks which are often of the most serious character.

When we come to consider the question of tubercular disease of the middle ear, we find that another factor—one that plays in all the other forms of inflammation an insignificant, if not an altogether negative part—assumes here a good deal of prominence. I refer to the influence of *heredity*. There is no reasonable doubt at the present day that tubercle bacilli, when carried into the middle ear by the air which passes through the Eustachian tube, cannot effect a lodgment in this cavity, provided the mucous membrane which lines it be in a healthy condition. If this were not the case, tubercular disease of the middle ear would certainly be much more common than it is. As a matter of fact, it is comparatively rare—at least as a primary disease. But when the mucous membrane of the tympanic cavity has, through inherited influences, lost its normal defensive powers against the various inimical micro-organisms ever present in the air, then a colony of tubercle-bacilli may establish itself in some part of that cavity.

Up to the present time our knowledge of the precise part played by the other micro-organisms found in inflammations of the middle ear has not advanced very far. We know positively[1] that the following *varieties of micro-organisms* are the principal etiological factors in all such inflammations: the streptococcus pyogenes, the staphylococcus pyogenes aureus, the staphylococcus pyogenes albus,

[1] Consult chapter xii. (by Prof. S. Moos) of vol. i. of Schwartze's "Handbuch der Ohrenheilkunde." Leipzig, 1892.

the diplococcus pneumoniæ of Fraenkel and Weichselbaum, the pneumobacillus of Friedländer, and the bacillus pyocyaneus. The first four varieties are those which are the most often found in inflammations of the middle ear. It appears, from the examinations which have thus far been made, mainly by culture tests, but also in part by aid of the microscope, that the infecting agents may all belong to one species, or the invasion may be participated in by different micro-organisms; and it has also been established that there are several sub-varieties of Streptococcus. Clarence J. Blake, in a recently published article[1] on the subject of mastoid operations, refers in the following terms to the question of bacteria in the ear: "In pursuance of the purpose to determine both the character and course of the infection, cultures were carefully made in all cases. In 23, but 1 germ was found; in 12 there was a mixed infection; and from 2, no growths were obtained:

Streptococcus was found pure in	12
Staphylococcus was found pure in	5
Diplococcus was found pure in	6
Streptococcus and diplococcus was found pure in	5
Streptococcus and bacillus fœtidus was found pure in	3
Streptococcus and bacillus pyocyaneus was found pure in	1
Streptococcus and diplococcus was found pure in	1
Streptococcus, staphylococcus, and diplococcus was found pure in	2

"The streptococcus cases were by far the most serious, although one healed by first intention. An interesting fact was noted in the series of cultures in regard to the infection of the mastoid from the middle ear; as a rule, the same germ was obtained by paracentesis as was later found in the mastoid. In one case cultures from paracentesis gave staphylococcus and diplococcus, while from the mastoid a pure culture of diplococcus was obtained, thus showing that the germ in the middle ear, to commence with, was diplococcus, which infected the mastoid, and that, later on, the middle ear was infected with streptococcus."

Beyond this point our knowledge does not go. Ziegler,[2] however, speaking of the behavior of these different bacteria (in general, and not with reference to the ear in particular), says: "Staphylococci generally cause localized inflammation; streptococci, on the other hand, phlegmonous." In the absence, therefore, of any more precise knowledge, we may claim more or less plausibility for the

[1] The British Medical Journal, November 27, 1897.

[2] Ernst Ziegler: "General Pathology," New York, 1895; p. 278.

following beliefs: Inflammations of the middle ear which are characterized by great and persistent pain, by a comparatively rapid spread of the disease to outlying regions (antrum, pneumatic spaces, lateral sinus, dura mater, etc.), and by extensive destruction of the bony framework that surrounds the pneumatic spaces, may be ascribed to the *streptococcus*: and, furthermore, when the disease pursues an equally destructive, but perhaps not so rapid course, and at the same time is accompanied by little or no suffering on the part of the patient, it is not unlikely that the active etiological factor is a different variety of streptococcus from that which gives rise to the painful type of the disease—a variety whose toxine products act like opium upon the sentient nerve fibrils of the inflamed tissues.

The *anatomical relations* of the different channels and chambers of the middle ear (in the comprehensive sense of that term) are not always the same even in individuals of the same age. For example, in early infancy the tympanic cavity proper is already developed to nearly its full size, while the adjacent pneumatic spaces of the mastoid portion of the temporal bone are still in a markedly undeveloped state. In fact, the mastoid antrum is virtually the only pneumatic cell which then exists. This single cell, furthermore, is separated from the periosteal covering of the mastoid process by a lamina of bone tissue which varies considerably in thickness in different individuals. Finally, the channel of communication between this antrum and the tympanic cavity is sometimes quite narrow; as a result of which condition it may easily become closed through inflammatory swelling of its lining mucous membrane. Already at this early age, therefore, the anatomical relations of the cavities of the middle ear may exert a decided influence upon the course which an acute inflammation of this region is to follow. In the fully developed mastoid process these relations may vary, in different individuals, to an even greater degree than they do in infancy. For example, in one person the pneumatic spaces may be so numerous and so large, and they may intercommunicate so freely, that an acute inflammation of the tympanic cavity can scarcely fail to become complicated by mastoid disease. In another person the cells in question may be so poorly developed and so few in number that even the severest attack of tympanic inflammation may run its course without producing a single symptom indicative of mastoid involvement. Then, again, the course of the disease may be materially influenced by still other anatomical relations—such, for exam-

ple, as that which the lateral sinus bears to the pneumatic cells, or the extent to which small blood-vessels pass from the middle ear to the membranes of the brain, etc. Besides these anatomical variations which are of congenital origin, there are others which at almost any time of life may be developed through the action of disease. I refer here more particularly to the obliteration of large numbers of pneumatic spaces through the new-production of bone-tissue. I shall have occasion, in another chapter, to consider this question more fully. For the present, what I have already said will suffice to show that the character of an inflammation of the middle ear is determined, not simply by the particular kind of micro-organisms which may have gained a foothold in that cavity, but also in no small measure by the anatomical relations which may, in any given case, happen to be present at the time of the attack.

I have already shown, in a previous chapter, how a *latent gouty condition* may give rise to a diffuse inflammation of the external auditory canal. I may now add that this same insidious force is competent, as I believe, to perpetuate, if not actually to create, a catarrhal inflammation of the middle ear. It has not yet been shown whether a deposit of the salts of uric acid in the tympanic mucous membrane or something faulty in the protoplasmic chemistry (metabolism) of its component tissues furnishes the immediate starting-point of such a gouty or lithæmic inflammation. But whatever may be the correct local pathology of these tissue alterations, there can be no reasonable doubt that they primarily owe their origin to a gouty diathesis. Further on, I shall be able to give some instances of what I believe to be a gouty inflammation of the middle ear.

CHAPTER XI.

NON-SUPPURATIVE OR CATARRHAL INFLAMMATIONS OF THE MIDDLE EAR.

EUSTACHIAN CATARRH; SIMPLE ACUTE CATARRHAL INFLAMMATION OF THE MIDDLE EAR; SEROUS OR MUCOUS EXUDATION INTO THE TYMPANIC CAVITY.

General Remarks.

The non-suppurative inflammations of the middle ear constitute a majority of all the ear diseases encountered in practice. The features which chiefly distinguish them from the purulent inflammations are the following: they run their course more quietly; they cause either no secretion whatever, or simply one that consists of serum or of mucus; micro-organisms play only an insignificant part or no part whatever in the process; and in nearly every case it is safe to assume that some nasal or pharyngeal vault lesion is the immediate active cause of the disease. The pathological alterations which are often present are: first, hyperæmia and œdematous swelling of the mucous membrane, sometimes limited to the Eustachian tube alone, at other times involving both the tubal and the tympanic mucous membrane; second, a certain amount of proliferation of the connective-tissue elements; and, third, after the preceding stages have lasted for months, or perhaps even for years, an atrophy and hardening (sclerosis) of the previously inflamed mucous membrane. As further results of these pathological changes the tympanic membrane will be found to occupy an abnormally depressed position, and, as time goes on, the ossicular joints are apt to lose their normal degree of mobility. Impaired hearing, subjective noises, and a stuffy or tight sensation in the affected ear, with occasionally a little vertigo or light-headedness, are the usual symptoms belonging to a non-suppurative inflammation of the middle ear.

While there are no sharp dividing-lines between the different types of catarrhal inflammation of the middle ear, it is desirable, for the purposes of description, to treat them as distinct groups. Four such separate subdivisions may easily be established, viz.: 1.

Eustachian Catarrh; 2. Acute Catarrhal Inflammation of the Middle Ear; 3. Serous or Mucous Exudation into the Tympanic Cavity (Otitis media serosa sive mucosa); 4. Chronic Catarrhal Inflammation of the Middle Ear.

I. EUSTACHIAN CATARRH.

The ordinary "cold in the head" rarely runs its course without involving at least one of the Eustachian tubes to a greater or less extent. The patient experiences a stuffy or a tight sensation in the corresponding ear, perhaps also at the same time some tinnitus, and a certain degree of resonance of his or her own voice in that ear. The hearing is very little, if at all, affected. On inspection with the mirror and speculum it will be found that the membrana tympani is altered in only one or two respects. In the first place, it is depressed to a degree proportionate to the narrowing of the tube; and, in the second place, it may show a little hyperæmia

FIG. 46.—Normal position of Drum-Membrane. (After Hartmann.)

FIG. 47.—Drum-Membrane drawn inward markedly. (After Hartmann.)

along the manubrium mallei or in the neighborhood of Shrapnell's membrane. When we find a higher degree of hyperæmia of these parts, we may be sure that the disease has invaded the tympanic cavity and is not confined to the Eustachian tube. If in a simple case of tubal catarrh the middle ear be cautiously inflated, the tympanic membrane will return not merely to its normal position, but to one which is appreciably nearer to the eye of the observer (see Fig. 49). It will present an outwardly convex appearance. If the narrowing of the tube be well marked, this hyperdistention (after inflation) will continue for a period of several minutes, or even for a longer time; while in the ordinary cases the very first act of swallowing which the patient may perform usually permits the excess of air encaged in the tympanic cavity to escape back into the vault of the pharynx.

In most cases of Eustachian catarrh the pathological alterations are doubtless most conspicuous at the pharyngeal end of the tube. In a few instances, however, I have had reason to believe that the

most marked lesions were located at the tympanic end of the tube. In these cases the most striking feature is the apparently contradictory relationship which exists between the evident patency of the tube and the tensely bulging condition of the drum-membrane. This protrusion outward of the membrane, in the cases to which I have reference, was clearly due to the presence of an excessively large volume of air in the cavities of the middle ear. In one of these cases I pricked the bulging membrane, whereupon it instantly resumed a perfectly natural position. As already intimated, no difficulty whatever was experienced in forcing air into the middle ear, and its entrance into that cavity did not give rise to râles. A swollen condition of the tube at its pharyngeal orifice or at any point along its course would have interfered materially with the entrance of air into the tympanic cavity, and would have caused the drum-membrane to occupy a depressed or sunken position rather than a bulging one. The presence of a small mass of mucus at the tympanic orifice of the tube, where it might perfectly well play the part of a valve, suggested itself as a condition that would explain the peculiar conditions observed. While I should not be justified in rejecting this hypothesis unconditionally, I am disposed to believe that a swollen condition of the mound-like tympanic orifice of the tube is the pathological condition which harmonizes best with all the symptoms and conditions observed in these cases. In the first place, in the case in which I incised the membrane, the patient had, for a period of nearly two weeks, experienced almost constantly a sensation of fulness or pressure in the affected ear. The prick made with the myringotome afforded instant relief, but it lasted only for a few hours. As this peculiar condition was associated with a marked naso-pharyngeal catarrh, I limited my treatment to tri-weekly paintings of this region with a solution of nitrate of silver, to counter-irritation over the mastoid process with tincture of iodine, and to inflations according to Politzer's method. During the third week the improvement was so rapid and so marked that treatment was discontinued. This experience, it seems to me,

Fig. 48.—Another Instance of a Drum-Membrane markedly drawn inward. (After Politzer.)

Fig. 49.—The same Membrane after Inflation. (After Politzer.)

tallies with the hypothesis which I have put forward rather than with that of the accidental presence of a mass of mucus at the tympanic orifice of the tube. Had the latter been the true cause, the forcible inflations of air ought to have dislodged the mass at a much earlier period.

The *prognosis*, in all recent cases of Eustachian catarrh, is good. In fact, in most cases the disease is of short duration, and passes away without any treatment. But if *treatment* should seem to be required, a few applications of a ten- or a fifteen-grain silver-nitrate solution to the vault of the pharynx will soon overcome the difficulty in all uncomplicated cases.

II. SIMPLE ACUTE CATARRHAL INFLAMMATION OF THE MIDDLE EAR.

What I have described in the previous section as a Eustachian catarrh proves, in very many cases, to be simply the onset, the first stage, of a catarrhal inflammation of the middle ear. The hyperæmia extends beyond the strict domain of the tube, and involves, to a greater or less degree, the entire tympanic cavity. If it persists for a few hours or an entire day, the watery elements of the blood will begin to escape from these distended vessels into the tissues of the mucous membrane and even out upon its free surface. When this latter effusion is sufficiently copious, enough intratympanic pressure may be developed to cause pain. The boundary-line between such cases and those which eventually develop into the suppurative variety is not distinct; and this fact naturally suggests the thought that the two varieties may, after all, depend upon precisely the same etiological factors; the clinical differences being due to the fact that in the milder catarrhal attacks the microorganisms are less numerous or less virulent than they are in the suppurative. However this may be, we cannot as yet dispense with our present method of dividing these cases into two distinct classes.

The cases of acute catarrhal inflammation of the middle ear vary markedly in severity. In the mildest ones there may be a few twinges of pain in the affected ear, but nothing more; and even in the most severe the pain does not last longer than a few hours, although it may return on several successive days. Very many of the "earaches" of young children, from two to ten years of age, are due to such an acute catarrhal inflammation. The pain is very apt to come on during the night or late in the afternoon, while during

the earlier part of the day the child may be quite free from pain. In the milder forms the picture presented by the tympanic membrane differs very little from that which I have described as belonging to an attack of Eustachian catarrh; at most, the evidences of hyperæmia of the tympanic mucous membrane will be more pronounced than they are in that condition. On the other hand, the picture presented by the tympanic membrane, a few hours after the onset of a fairly severe attack, is often of a most striking character. It is a picture of obstructed venous circulation of a high degree. In the region of Shrapnell's membrane there is apt to be a purplish-colored sac, composed of the stretched epidermal covering of these parts, and filled with bloody serum or even with a soft black or dark purple clot. I have known such a sac to attain the dimensions of a full-sized bean, filling the entire inner half of the meatus. Oftentimes the purple-colored serum will dissect its way under the epidermis throughout the entire extent of the tympanic membrane. When this happens, the membrane will present a dusky and œdematous appearance. In less severe cases a well-marked hyperæmia —most pronounced in the vicinity of Shrapnell's membrane, and shading off gradually from there in a downward direction—is all that we shall be able to see when we examine the region with the speculum and reflected light.

The *prognosis* is almost invariably good in this form of catarrhal inflammation of the middle ear. Generally, in the course of two or three weeks the inflammation entirely disappears, and the hearing returns to its previous normal condition.

So far as the *diagnosis* is concerned, an error is scarcely possible. The evidences of inflammation are too plainly marked for a careful observer to be easily misled in his interpretation of the conditions presented. The questions which suggest themselves to his mind are, first: Is this a simple catarrhal inflammation, or is it the beginning of a severe purulent inflammation? Mere inspection will not suffice for the settlement of this question; the subjective symptoms, and especially that of pain, must be weighed in connection with the condition of the drum-membrane. In children, the thermometer may aid us materially in arriving at a correct conclusion; in adults, it is of comparatively little value. The second question is, Is the red and swollen condition of the membrana tympani the expression of an inflammation which began originally in the middle ear, or is it due to an extension of a diffuse inflammation of the canal on to the drum-membrane? This is sometimes a difficult

question to answer. If an inflammation of the middle ear has progressed so far as to involve the inner end of the external auditory canal, we may be quite sure of two things: there will be marked diminution of the hearing, and a history of rather severe pain. On the other hand, the insignificance of the pain and the slight impairment of the hearing are very striking features in those cases in which the inflammation of the auditory canal is the primary affection, and that of the drum-membrane merely a secondary affair. In exceptional cases, marked pain and decided impairment of hearing may characterize the type of disease last mentioned. Under such circumstances it may not be possible to arrive at a correct diagnosis without further observation of the course which the disease pursues.

Finally, it must not be forgotten that in these cases, as in all others in which the middle ear is the seat of some pathological process, our task as diagnosticians is not completed until we shall have fully ascertained what is the state of the pharynx, vault, and nasal passages.

When we are sure of our diagnosis, the question of *treatment* becomes a very simple matter. Very little interference is necessary. The breaking down and removal of any clotted blood that may be encysted at the inner end of the meatus, the use of the simple hot douche or of poulticing when there is pain, paracentesis of the membrana tympani if it be found to be unduly tense, the reduction of the hyperæmia of the pharyngeal vault by the employment of a mop saturated with a suitable silver-nitrate solution, and the occasional employment of Politzer's method of inflating the middle ears *after the pain has entirely disappeared*—these are the therapeutic measures which will generally be found useful in the management of this class of cases.

As regards *the manner of applying silver nitrate in solution* to the œdematous and hyperæmic mucous membrane of the pharyngeal vault, I may say that I have a decided preference for the method which I first saw employed by Dr. Robert F. Weir, of this city, in 1870. His mode of procedure was the following: He wound absorbent cotton around the end of a malleable steel cotton-carrier, about 6½ inches long, and then bent the armed end of the instrument at a right angle, or at an angle a little less than a right angle. This mop was next saturated with the remedial solution, and then, after the patient's tongue had been pushed down out of the way with a tongue-depressor, and he had been told to fill the chest with

air, it was introduced flatwise into the mouth and turned up behind the soft palate to the very summit of the vault.

To this brief description it is perhaps desirable to add a few practical details. In adults the shorter arm of the instrument—that around which the cotton is wrapped—should not exceed one inch in length; in children it should be a little shorter, say three-fourths of an inch. To a distance of about three-eighths of an inch from the end the sides of the instrument should be slightly rough-



FIG. 50.—Malleable Steel Cotton-Carrier, armed with cotton and bent at an angle suitable for applying remedial solutions to the vault of the pharynx.

ened, in order that the cotton-wool may cling firmly to it. Before dipping the mop into the solution of the remedy the physician should always pass his finger over it, for the purpose of ascertaining whether the sharp end of the instrument is thoroughly well covered by the cotton. It is scarcely possible to lay down any well-defined rule with regard to the proper size of the mop. As a rough estimate, I may say that, at the spot where it is broadest, it should measure seven or eight millimetres (about one-quarter of an inch) in diameter for adults, and five or six millimetres for children. When the mop is ready, the next step should be to saturate it to the proper degree with the solution. Here again care must be exercised; for if we dip the entire mop into the solution, and without further ado introduce it into the naso-pharyngeal space, we must not be surprised if the patient objects to a repetition of the procedure. The mop filled with the remedy is precisely like a sponge saturated with water. The moment the naso-pharyngeal muscles contract, they squeeze the mop just as a person would a sponge, and cause a stream of the silver solution to run down into the larynx, or to a point very near its entrance. The symptoms thus caused are always extremely unpleasant, and, in a few instances, they may be decidedly alarming. On more than one occasion, in former years, I have completely demoralized both the patient and the patient's friends by the spasm of the glottis which had been provoked by my careless mode of applying the remedy. To avoid these unpleasant symptoms either we should saturate the entire mop, and then, by

pressure, carefully remove the excess of fluid, or we should saturate only one-half of the mop, leaving the other half to serve the purpose of a receiver into which the excess of fluid, pressed out of the moist half of the mop by the naso-pharyngeal muscles, may escape. This latter method is the one which I usually employ, and even then I endeavor to remove as much of the fluid as I can by pressing the saturated end of the mop against the neck of the bottle.

The steps of this operation of applying silver nitrate to the walls of the naso-pharyngeal cavity are the following: The patient should sit in such a position that the source of light which is to be used in illuminating his pharynx shall be on his right side and a little behind him. The physician should sit directly facing the patient, and he should first of all adjust his forehead-mirror in such a manner as to secure a satisfactory illumination of the pharynx. Then, holding the mop in his right hand and pressing the patient's tongue down firmly with the tongue-depressor held in his left, he should introduce it flatwise into the mouth and, on reaching the posterior pharyngeal wall, turn it up behind the soft palate until it comes in contact with the roof of the vaulted cavity. In a child or young person this is all that is generally required, but in adults it often happens that we must resort to some device for securing an open passageway from the fauces to the vault of the pharynx. In most patients it is instinctive to keep this channel closed when they are aware that an instrument is about to be passed through it. The employment of force, for the accomplishment of the purpose in hand, is decidedly objectionable, and, furthermore, it is not necessary. By exercising a little patience and perseverance the physician will usually find an opportunity of introducing his mop without crowding it against the swollen and hyperæmic mucous membrane. Thus, for example, the mop may be held close to the posterior pharyngeal wall, in readiness to be introduced instantly into the vault when the opportune moment arrives. Or the patient may be taught, after drawing in a long breath, to breathe out through the nasal passages. As this can only be done when the muscles of the soft palate are relaxed, an opportunity will thus be afforded for the easy introduction of the mop. Comparatively few patients succeed in actually sending air through these passages, but in the great majority of instances the mere effort to accomplish the act results in the desired relaxation of the muscles and the consequent opening of the pharyngeal vault. The moment the physician observes this relaxation of the muscles he should at once pass the mop high up

behind the soft palate, first toward one Eustachian orifice, and then across toward the other. If only one ear is affected, it will often be found sufficient to introduce the mop only on that side of the naso-pharyngeal cavity.

Sometimes, when the attempt is made to carry the mop across from one tubal orifice to the other, quite a decided obstacle is encountered in the form of a hemispherical projection of the mucous membrane at a point situated exactly in the median line of the posterior pharyngeal wall. If the instrument be pulled forward a little, no difficulty will be experienced in carrying the mop past the obstacle.

In certain patients the mere act of pressing with an instrument upon the tongue causes them to retch so persistently that all attempts to introduce the mop into the naso-pharyngeal cavity by way of the mouth have to be abandoned. It is often possible, however, in such cases, to accomplish the desired object by performing the operation with great speed. If this plan be adopted, the physician should be careful to protect his person, lest the contents of the patient's stomach be suddenly showered upon him. Finally, by wrapping a towel around the end of the patient's tongue, and instructing him how to pull that member well outside of his mouth, the physician may be able to reach the naso-pharyngeal cavity without producing the unpleasant results just mentioned.

In making remedial applications to the naso-pharynx the physician must notice particularly whether, and to what extent, the mucous membrane of that cavity is covered with mucus. On simple inspection he may very easily fail to discover the presence of any appreciable amount of mucus, and yet, on introducing his mop, be surprised to find that region well coated with a tough, tenacious, dirty-looking material which clings like a false membrane to the underlying tissues. It is not difficult to estimate the effectiveness of say a ten-, twenty-, or even a forty-grain solution of nitrate of silver when introduced into the naso-pharynx under such circumstances. Very little of it, as a matter of course, ever reaches the mucous membrane, and consequently little or no benefit results from the procedure. It is therefore important to first remove this coating of mucus from the naso-pharyngeal mucous membrane before we undertake to bring our remedies to bear upon it. For this purpose I am in the habit of employing simply dry mops of cotton. A single introduction usually suffices to bring away any free mucus that may be present. However, I ought to add that the presence

of such a mass of tough mucus points to the existence of a stage of disease much further advanced than that which is now under consideration.

As regards the strength of the silver solution, I have very little to say. In young children a ten- or a fifteen-grain solution will generally be found sufficiently strong, while in adults, one of fifteen or twenty grains to the ounce may be required. The applications can probably be made to the best advantage on alternate days.

If some of the solution happens to trickle down into the larynx and cause violent coughing or a spasm of the muscles of the glottis, I immediately give the patient cold water to drink.

It is in the form of disease which we are now considering that *inflations of the middle ear* by means of compressed air are especially beneficial. It is a common belief that a large part of the good effect which is thus produced is to be attributed to the restoration of the membrana tympani and the attached ossicles to their normal relations. I am not at all sure, however, that we should not attribute an equally large share of the benefit—or possibly even a larger one—to the diffusely distributed pressure which these inflations exert upon the œdematous mucous membrane of the middle ear and Eustachian tube; a pressure which must promote the absorption of the infiltrated fluid and cellular elements to whose presence the swollen state of the mucous membrane is due. Then, besides, if there happen to be some free fluid exudation in the tympanum, it is not unlikely that the sudden passing of air into, and then out from, this cavity may effect a dislodgment of at least a part of the fluid.

The first practical question which presents itself in connection with the therapeutic employment of inflations is this: Shall we use the catheter, or shall we trust to what is known as Politzer's method? Inasmuch as good results are obtainable by both methods, it is not strange that the question should be answered differently by different authorities. On the continent of Europe, for example, there is, I believe, a widespread preference for the catheter, while here in the United States both methods seem to be used to an equal extent. My own preference is strongly in favor of Politzer's method of inflating the middle ear, and for the following reasons: As patients have a much greater repugnance to catheterization than to inflations by Politzer's method, and as the latter procedure is generally just as effective as the former, I always endeavor to dispense with the catheter, if circumstances will permit. Furthermore, it

must be remembered that the presence of this instrument in the nasal passage and in the mouth of the Eustachian tube produces a certain degree of irritation. In a few cases I have observed that this irritation was sufficient to counterbalance the effects of the inflations; at all events, appreciable improvement in the condition of the ear and in the acuteness of the hearing did not appear in these cases until after I had abandoned the catheter, and had restricted myself to the employment of Politzer's method. There are cases, however, in which, for various reasons, Politzer's method fails to drive air with adequate force into the middle ear. Under these circumstances our course is clear: we must employ the catheter. In Chapter VII. I have described in detail the different steps of these two methods of inflating the middle ear.

The next practical question is this, How often should we employ either of these two methods? To this question I can only give a more or less arbitrary answer. I really do not know whether it is better to inflate the ear several times daily, or only once a day, or even only on alternate days. I do know, however, that in the class of cases which we are now considering, I obtain reasonably good results by resorting to the inflations—four or five successful ones at a sitting—only every other day. Too frequent inflations may undoubtedly do harm, especially if the practice be continued for a period of several weeks or months; but it would be a difficult matter to define the limit beyond which inflations begin to be harmful.

It is equally difficult to lay down rules with regard to the proper duration of such a course of treatment. In subacute cases of recent origin, two or three repetitions of the inflations on alternate days may be found sufficient to restore the drum-membrane permanently to its normal position, to remove every trace of congestion or swelling, and to bring back the hearing to its former degree of acuteness. In other cases—and these perhaps represent the average—a course of treatment covering a period of from two to four weeks will be found necessary for the accomplishment of the same results. Even in the more stubborn cases I very rarely keep up systematic treatment beyond the fourth or fifth week. I prefer to give the parts an absolute rest of two, three, or four weeks, and then, if necessary, resume the inflations and the applications to the naso-pharynx.

Finally, if the patient is a tobacco-smoker, I think it is wise to have him abstain from the habit during the continuance of the treatment; not because—as some seem to believe—the absorption of

nicotine is likely to exert a harmful influence, but because the frequent contact of particles of tobacco smoke with the naso-pharyngeal mucous membrane tends to promote a condition of hyperæmia. By this remark I do not wish to convey the impression that I deny entirely the injurious influence of nicotine poisoning upon a congested pharyngeal mucous membrane, but simply that this particular phase of the effects produced by tobacco smoking is of minor importance when compared with that attributable to direct mechanical or chemical irritation.

In those cases which do not make satisfactory progress under treatment we shall generally find that one of two things is true, viz., either that we have overlooked some nasal or vault lesion which is perpetuating the ear difficulty, or that the metabolic processes of the body are not going on in a normal manner. In the former case, upon discovering our error in diagnosis, our proper course is to adopt whatever measures are necessary for the cure of the causative nasal or vault lesion. These are described in a later chapter. On the other hand, if a disordered metabolism is the factor which is interfering with a full recovery, we must recommend such dietetic and hygienic measures as will tend to restore the metabolic changes to their natural degree of vigor. A short sea trip or a visit to the country for a week or two will often accomplish promptly what we have sought in vain to accomplish by local treatment. And when for any reason such a change in climate, food, and surroundings cannot be secured, equally good results may sometimes be obtained by the administration of cod-liver oil, iron, Calisaya bark, etc. When the disordered metabolism is of a more fundamental nature, then we must assign the case to the category of chronic catarrhal affections of the middle ear, and adopt the therapeutic measures which are laid down in Section IV. of the present chapter.

In addition to the therapeutic measures which I have here recommended, there are others which, although they do not commend themselves to my judgment, are nevertheless favored by many excellent authorities. I refer to the practice of injecting remedial fluids and vapors into the Eustachian tube and middle ear. A personal trial of these procedures led me to two conclusions: first, that they not infrequently increased the local irritation which I was endeavoring to allay; and, second, that in no instance were the completeness and promptness of the cure any more marked than in those cases which I had treated in the manner described above (viz., by simple pharyngeal applications and by inflations). Further-

more, I was always conscious that I was employing a method over which I could exercise but little control; in fact, I never knew whether the small quantity of fluid which I had injected through the catheter had entered the cavity of the tympanum, or had merely bathed the walls of the pharyngeal portion of the tube. With the view of removing this element of uncertainty from our efforts to apply remedies to the Eustachian tube, I suggested the employment of small mops which could readily be passed through the ordinary Eustachian catheters.[1] I gave this plan a fair trial, but I did not secure any better results than I had previously obtained by means of the simpler method of leaving the Eustachian tubes alone. Furthermore, the procedure, as I am now convinced, is not a perfectly safe one, unless we abstain from using the stronger solutions of nitrate of silver. In the case of one of my patients, a gentleman, thirty-eight years of age, and in vigorous health, I found the tubes so obstructed that the drum-membrane on both sides appeared to rest against the promontory. I carried out the simpler plan of treatment for a few days, and then, failing to accomplish the desired result, I resorted to the use of the bougie, armed with a mop of absorbent cotton, which had been dipped in a strong solution of nitrate of silver (exact strength not remembered). I passed the bougie, armed with this medicated mop, about a quarter of an inch into one tube, and then, after saturating the mop a second time, pushed it about the same distance into the other tubal orifice. While I was cleaning my instruments I noticed that the patient had grown very pale. I asked him if he felt ill, and he replied in the affirmative. I then took him by the arm for the purpose of assisting him to walk to the sofa, but by that time he had lost consciousness, and simply slid from his chair down upon the floor. His breathing rapidly became stertorous, and he passed into a violent convulsion which lasted fifteen or twenty seconds. The muscles then became relaxed, and perfect consciousness returned, the patient expressing great surprise that he should be lying stretched out upon the floor. His urine was examined, but it was found to be perfectly normal. The unconsciousness and convulsions were probably due in this case to a reflex spasm of the arteries of the brain, dependent upon the irritation supplied by my introduction of the bougie (saturated with a strongly irritating solution) into the Eustachian tube.

The employment of bougies is said to be attended by another

[1] "A Method of Using Medicated Eustachian Bougies," Transactions of the American Otological Society, 1875.

danger, viz., that of lacerating the parts, and thus opening the way for the development of emphysema. This accident can only occur, I believe, when undue violence is employed in the manipulation of the bougie; for at one time (1874–75) I used this instrument very frequently in private practice, in young children as well as in adults, and yet I never saw a case of emphysema following its employment. The free end of the whalebone bougie was always well wrapped in cotton, so that it presented a perfectly blunt, soft mass; and if this precaution be taken, it is difficult to comprehend how laceration of the parts can result from the introduction of the bougie unless positively rough manipulations are employed.

The introduction of vapors into the middle ear is recommended by some authorities as an excellent therapeutic procedure in cases of subacute catarrhal inflammation of the middle ear. Some, for example, extol the beneficial effects of "steaming" the middle ear; others recommend highly the introduction of the vapor of menthol, of iodine or of camphor, or the fumes of sulphuric ether or of chloroform. With regard to all these methods of treatment, I think we should put to ourselves the question, Do they accomplish better results than can be obtained by the simpler methods which I have described above? In answer to this question I may say that I am satisfied, partly from personal experience and partly from that of my colleagues, that no such superiority can be claimed for them. If, then, they are not superior to the simpler methods, I am at a loss to see why—in view of the fact that they are more complicated, and more distressing to the patient—we should continue to use them.

It is not an uncommon occurrence for the patient to ask the physician whether he or she cannot carry out the requisite treatment at home. Self-inflation—if I may so designate the act of inflating one's own middle ears according to Politzer's method—is not a very difficult procedure to learn; but the effective application of a remedial solution to one's own naso-pharyngeal space is a far more difficult task and one that very few patients succeed in learning. In my experience, the results obtained by self-treatment, even when the patient is a physician and thoroughly conversant with the procedures to be employed, are rarely satisfactory in the class of cases which are here under consideration.

III. SEROUS OR MUCOUS EXUDATION INTO THE TYMPANIC CAVITY.

(*Hydrotympanum : Otitis media serosa sive mucosa.*)

The form of middle-ear disease which I have just described in the previous section is often associated with an exudation of fluid into the tympanic cavity; but it is not to this kind of accumulation of fluid in the middle ear that the terms enumerated in the title of the present section have reference. The condition which I am about to describe is one in which a comparatively normal tympanic cavity is found to contain a variable amount of serum or mucus, or of a fluid which represents a combination of the two. Such a condition may be explained in the following manner: At first a closure or decided narrowing of the Eustachian tube is produced by what is commonly termed a "cold in the head," and yet the direct effects of this "cold" do not extend to the mucous membrane of the tympanic cavity. At the moment when the tubal closure occurs, there is a normal amount of air in the latter cavity. But it is a well-known fact that air imprisoned in a closed cavity of the living body soon undergoes absorption. Hence the air imprisoned in the middle ear, after its channel of communication with the outer world has become closed, must soon undergo absorption; or, in other words, a partial vacuum will soon be created in this cavity. The yielding of the tympanic membrane under the force exerted upon its outer surface by the imperfectly resisted atmospheric pressure will compensate, for a very brief period, for this condition of a partial vacuum. But, finally, when the compensation from this quarter fails, the blood-vessels of the tympanic mucous membrane give up enough of their watery contents to restore the equilibrium. In other words, a genuine hydrotympanum—a *hydrops e vacuo*—is established. This, I believe, is the correct pathology of an exudation of serum into the tympanic cavity; and such an exudation, I should add, may develop as well in a middle ear which has been the seat of a chronic catarrhal process as in one that is normal.

When stringy mucus is found in the middle ear in the place of serum, its presence there may be explained—although I do not feel entirely sure that this explanation is the true one—by assuming that, at the moment when a vacuum is created in the middle ear, there must be a certain amount of mucus lying in the Eustachian tube, and that this mucus is drawn into the tympanum through the

suction power exerted by the vacuum (or, more correctly speaking, is pushed into the tympanum by the atmospheric pressure which operates from the direction of the pharyngeal vault). According to these explanations, both of the conditions which are now under discussion are fundamentally one and the same; the difference which exists between the two kinds of fluid exudation being due simply to an accidental circumstance, viz., the presence or absence of mucus in the Eustachian tube. The idea that the mucus is derived from certain glandular structures located in the tympanum itself, does not commend itself to my judgment.

As a rule, the exudation which is poured into the tympanic cavity during the acute stage of a catarrhal inflammation is soon absorbed; and by the time that the membrana tympani has resumed its normal thinness and translucency, every trace of such a free exudation will have disappeared. It is possible, however, that in some exceptional cases this fluid continues to linger in the tympanum for an abnormally long time, and that this mode of origin is the one which must be accepted for a few of the cases of hydrotympanum encountered in practice.

In the main the *symptomatology* of these cases is the same as that of the ordinary cases of subacute catarrhal inflammation. There are certain symptoms, however, which of themselves are almost sufficient to warrant a diagnosis of fluid exudation into the middle ear. One of these is the sudden change from somewhat poor to good hearing, or the reverse. This change is not like that which so often occurs in cases of impacted cerumen, where the brief return of the hearing is accompanied by an explosive sound, due to the sudden restoration of a communication between the body of air lying between the drum-membrane and the ceruminous mass, and that which lies outside the latter; the hearing either simply becomes clouded, or, in an equally quiet manner, the cloud seems to disappear. These changes in the hearing are clearly due to changes in the position occupied by the fluid. In a few cases the patient is able to state definitely in what positions of the head the hearing seems to be normal. These are most commonly the position with the head thrown far backward (fluid escapes into the antrum), and that with the head bent far forward. In both of these positions the fluid, if not too viscid and if not too copious, will, in obedience to the law of gravity, flow away from the oval and round windows, thus leaving the ossicles and the membrana tympani secundaria free to perform their functions properly.

Another symptom which is peculiar to these cases is the sensation of something moving in the ear. This, as a matter of course, is not felt when the head is quiet, but simply when the head is moved rather suddenly. Sometimes the patient gives a correct diagnosis of his condition in the very first words of his complaint: "I went in bathing, and got some water into my ear; and I am unable to get it out." He imagines that the water found its way into the ear by way of the external auditory canal; whereas the chilling of the surface of the body, or the accidental entrance of water into the middle ear by way of the Eustachian tube, has caused an exudation of fluid to take place in the tympanum in one of the ways already described. Finally, subjective crackling, squeaking, and bubbling sounds may be due to the presence of free fluid in the middle ear; they are just as likely, however, to owe their origin to an abnormally moist condition of the Eustachian tube. Of more decided value is the symptom of hearing gurgling sounds in the ear during the acts of coughing, sneezing, and swallowing.

The *course of the disease* is a very variable one, although in the majority of instances the fluid exudation is soon absorbed and the ear returns to a normal condition. Among the following cases will be found instances of probably all the types of serous exudation into the middle ear which the physician is likely to encounter in practice.

CASE XXXII.—*Exudation of serum into a tympanum which had previously been in a healthy state; prompt recovery under treatment.*

The patient, a man thirty-five years of age, had a few days previously caught a slight cold in the head, and had thenceforth experienced a sensation of fulness in the left ear. When he consulted me on the 13th of May, 1879, I found the left drum-membrane slightly congested at the periphery. Just below the umbo (the lower end of the handle of the hammer) a curved line was visible, which stretched from the anterior to the posterior periphery of the membrane. In whatever position the patient's head was placed, this curved line (with its concave side looking upward) maintained its horizontal position, thus showing clearly that it represented the upper boundary of a mass of free and rather thin fluid. Under treatment this pathological condition disappeared in about two weeks, and the hearing returned to its normal degree of acuteness.

CASE XXXIII.—*Exudation of serum into a tympanum which had previously been the seat of a chronic catarrhal inflammation.*

The patient, a boy eight years of age, had been somewhat hard of hearing, as the mother believed, for about one year. At times, she said, he seemed to hear quite well, and then the deafness would return and last for a variable period. When I saw the boy at the Infirmary, on the 12th of October, 1870,

his right membrana tympani presented no features worthy of special note in this connection. On the left side, the drum-membrane was noticeably sunken, but not congested nor lacking in a fair degree of transparency. In the posterior half of the membrane there was a sharply defined "fluid line," running from the umbo across the intervening space to the posterior periphery. Anteriorly, the limits of the fluid could not be defined. Moist râles were heard during inflation. "Fluid line" disappeared after inflation. Decided naso-pharyngeal catarrh. Hearing distance for the watch before inflation: R. 2 in., L. 2 in.; after inflation: R. 24 in., L. 15 in. Whispered words were heard distinctly a much greater distance after inflation than before it.

The boy visited the Infirmary for treatment twice a week, for a period of four weeks. The fluid had by that time disappeared from the left middle ear, and the hearing, for the watch, remained steadily at twenty-four inches. On the right side, however, no perceptible improvement in the hearing had taken place.

These two cases are placed side by side because the former represents a purely fresh attack in a person whose ears had been previously healthy, while the latter furnishes a good instance of the development of hydrotympanum in an individual whose ears had been for months affected with chronic catarrhal inflammation. Furthermore, they both represent the slighter degrees of fluid exudation into the middle ear.

Case XXXIV.—*A case similar to the preceding two cases, but displaying certain peculiarities in the "fluid line."*

A gentleman, sixty-nine years of age, but in vigorous health, consulted me on the 9th of December, 1876, for a decided loss of hearing in his right ear. He first discovered the defect about six weeks previously, while suffering from a severe cold in the head. On examining the ear I found that the membrana tympani was decidedly sunken. Anteriorly, a "fluid line" ran directly across from the umbo to the anterior periphery of the membrane. Posteriorly the uniform dark coloring of the membrane showed clearly that the fluid in this region rose to at least the height of the upper limit of the membrane. As the long process of the anvil lay almost in contact with the membrana tympani, its whitish body stood out in marked contrast with the deep slate color of the surroundings. Inflation by Politzer's method changed the entire picture. The "fluid line," which before was visible only in the anterior half of the membrane, now stretched like a festoon from periphery to periphery. The long process of the anvil had also completely disappeared from view.

Under treatment this mass of fluid was dissipated—whether wholly by absorption, or partly by absorption and partly by dislodgement, I am unable to say—in less than two weeks, and the hearing returned apparently to its former standard of acuteness.

On first thought it may seem rather strange that in the posterior half of the cavity of the tympanum (in the case just narrated) the

level of the fluid should rise at least to the height of the upper boundary of the drum-membrane, while in the anterior half the level should correspond with that of the umbo or central point of the membrane. This difference, however, is simply due to the effects of capillary attraction. The close proximity of the long process of the anvil to the posterior half of the membrana tympani supplies precisely the conditions which are necessary to develop the effects of capillary attraction, that is, to lift the apparent level of the fluid in this region to the highest limits of the drum-membrane.

CASE XXXV.—*Bubbles of air intermingled with the serum in the cavity of the tympanum.*

This patient, a young man twenty-eight years of age, contracted a bad cold in the head ten days previously, and shortly afterward began to experience a sense of fulness in the right ear, and diminished acuteness of hearing. When I examined his right ear at the Infirmary, on the 2d of November, 1870, I found the drum-membrane of a peculiar, dull hue, and almost directly in the centre of the posterior half the perfectly round outlines of a bubble of air, perhaps a millimetre and a half in diameter, were distinctly visible. This bubble seemed to be prevented from rising to a higher level by some unseen object—undoubtedly the end of the long process of the anvil and the head of the stirrup. The motions of the patient's head caused it to move slowly from one position to another, but only a very short distance. (No further notes of the case.)

It is perhaps more common to find several bubbles lying behind the drum-membrane. I remember, in a few instances of hydrotympanum, to have seen (after inflation) the cavity of the tympanum apparently filled from top to bottom with bubbles, which glided over each other like so many balls of some polished metal. (See Fig. 54.) The first time I saw this phenomenon I was persuaded that I must have overlooked a minute perforation in the membrana tympani, and that the mass of bubbles lying before me was resting against the outer and not the inner surface of the membrane. By employing a small mop of cotton, however, I was able speedily to satisfy myself that the bubbles were confined within the tympanic cavity.

CASE XXXVI.—*The "fluid line" takes the form of a broad yellow band, caught up like a festoon at the umbo.*

The patient, a marketman, thirty-one years of age, came to the Infirmary on the 4th of February, 1874. He complained of deafness and occasional tinnitus, of several months' standing. Recently, he said, he had sometimes observed gurgling sounds in the left ear, and had also noticed that when he threw his head far backward he could hear decidedly better than when he

held it in the natural upright position. I examined the left ear and found the membrana tympani appreciably sunken. Instead of a delicate, hair-like "fluid line," a rather broad yellow band crossed the lower half of the membrane. At the umbo this band was caught up like a festoon. Below it the color of the drum-membrane was like that of slate. Changes in the position of the head caused corresponding changes in the position of this band. A free vertical incision was made in the posterior half of the membrane, and inflation by Politzer's method was resorted to. In this way quite a large quantity of fluid was evacuated from the tympanic cavity,—fluid which, in no respect that I could discover, differed from that found in cases which are characterized by the presence of the delicate, hair-like "fluid line." The evacuation of the fluid contents of the middle ear increased the acuteness of the hearing very noticeably, and three days later, when he returned to the Infirmary, I found that this gain had increased rather than diminished.

FIG. 51. — Collection of Serous Exudate in the Lower Part of Right Tympanum. The glistening curved line which crosses the picture represents the upper level of the fluid. (After Politzer.)

In all the five cases which have just been described, the fluid found in the tympanic cavity was almost purely serous in character. So far as my experience goes, it is only in comparatively few cases that the exuded fluid is found to consist largely or entirely of tough, tenacious mucus.

Diagnosis.—The appearances presented by the tympanic membrane when a collection of serum, muco-serum, or mucus, lies behind it, vary greatly. The simplest picture is that which is seen when the fluid contained in the tympanic cavity is comparatively small in quantity and consists of a thin serum. The upper level of this mass of fluid can then be seen like a hair crossing the tympanic membrane in a more or less horizontal direction; and as the patient moves his head backward or forward, this slightly curved or undulating line will be observed to maintain constantly its horizontal position. (Compare the two pictures, Figs. 52 and 53.) The various positions which this line may occupy, and the different curves which it may present, have already been sufficiently discussed. I will simply add here a few remarks in regard to the differences in coloring, and also in regard to the question of differential diagnosis.

FIG. 52.—The Same Condition, as seen in another patient. In this case the line of the upper limit of the fluid is wavy. (After Politzer.)

When the fluid contained in the tympanum rises to a level higher than the upper limit of the membrana tympani, our diagnosis will have to be made with the aid of other data; for there will be no "fluid line" in the picture to indicate that serum is imprisoned in the middle ear. When this is the situation of affairs, the history of the case may afford us some assistance in ascertaining the truth. Or, if experience has taught us to observe closely the differences in the apparent coloring of the tympanic membrane, our suspicions may be aroused by the peculiar greenish or purple or slaty color which it presents. These different shades of color may be explained in the following manner: The light thrown into the external auditory canal by the concave mirror first passes through the membrana tympani, and then through the mass of serous fluid, before it strikes upon the somewhat congested mucous membrane covering the inner wall of the tympanum. The color of such a congested mucous membrane is not always the same. It may be a shade of red which is only a little more pronounced than the natural pinkish hue of the membrane; or it may be a decided purple, as when there is some interference with the venous circulation of the part. But the rays of light which are reflected back from this red or purple surface to the eye of the observer must first pass through the intervening mass of yellowish serum and then through the tympanic membrane; and there can be little doubt that the influence of this yellow medium is competent to convert the red into a dull green, and the purple or blue into a slaty hue. Unfortunately, however, the diagnostic value of these departures from the normal coloring of the membrana tympani cannot always be depended upon. The deep greenish or slaty color may come, not from a mass of serum lying free in the tympanic cavity, but from some which is entangled in the meshes of the tympanic mucous membrane; for the passage of the reflected rays through even this comparatively



Fig. 53. — Appearance of the Drum-Membrane (same case as that shown in Fig. 52) when the patient's head is thrown far backward. The line of the fluid now runs nearly parallel with the handle of the hammer, instead of at right angles to it. (After Politzer.)

Fig. 54.—Foamy Secretion in the Tympanum after Inflation, in a case of serous accumulation. From a patient with acute naso-pharyngeal catarrh. (After Politzer.)

thin medium of yellow seems to be sufficient to transform their original red or purple into these same darker shades of green or gray. But if the peculiar color be really due to the presence of free serum in the tympanum, the inflation of that cavity will make the presence of this fluid known by the appearance of bubbles of air or of the "fluid line" where before nothing could be seen but a uniform, unbroken surface. Auscultation during the act of inflation may also aid us in arriving at a correct conclusion. In cases of an accumulation of mucus, it is perhaps the exception for râles to be heard; in fact, the air, forced into the Eustachian tube by inflation, does not seem to reach the cavity of the tympanum at all. In the second place, the appearance of the drum-membrane in cases of otitis media mucosa is usually quite different from that observed in well-marked cases of otitis media serosa. It often has a peculiar dead, milky, opaque appearance, which, unfortunately, is sometimes also observed in cases of the serous variety. Hence, without paracentesis of the membrane, we can scarcely do more than entertain a strong suspicion that the case is one of an accumulation of mucus in the tympanic cavity. After paracentesis has been performed, and the exuded material has been forced through the perforation into the auditory canal, it becomes, of course, an easy matter to make an absolute diagnosis. Further on, I shall have occasion, in speaking of the treatment of these cases of otitis mucosa or of otitis serosa, to advise against the making of a paracentesis of the tympanic membrane. In this place, therefore, I will simply say that nothing of value is to be gained by settling beforehand the question whether there is or is not an accumulation of fluid in the middle ear, or whether the fluid is of a mucoid or of a serous character. It is enough for our purposes, in the proper management of the case, to have ascertained the fact that we are dealing with a catarrhal inflammation of the Eustachian tube and with certain vault or nasal lesions which have caused the tubal catarrh.

In rare instances the tympanic membrane may be the seat of pathological alterations which imitate very closely the conditions presented in some of these cases of otitis media serosa. As an illustration of this, I am permitted to introduce here a reproduction (Fig. 55) of one of Dr. B. Alexander Randall's drawings. The accompanying description of the cut explains sufficiently the nature of these alterations.

This is perhaps the proper place in which to say a few words in regard to *hemorrhagic exudations into the middle ear*. There are

two classes of cases to which the expression just employed may be applied with equal justice, viz., those of acute catarrhal inflammation in which, during the first onset of the disease, a hemorrhage occurs from some vessel in the middle ear, and those in which a serous fluid, deeply tinged with the coloring matter of the blood, finds its way into the tympanic cavity through other than inflammatory causes. Instances of the latter form of disease are very rarely met with, and then usually in connection with a depraved state of the general nutrition (morbus Brightii). I once published[1] what I believed at the time to be a well-marked instance of this form of hemorrhagic exudation. It occurred in a person who was affected with œdema of the lower extremities and who presented the characteristic facies of Bright's disease. When the patient was seen a second time, a few years later, an intratympanic, pulsating, vascular growth occupied the position of the former hemorrhagic exudation, and my previous error in diagnosis became at once apparent.[2]

FIG. 55.—Marked partial Retraction of the Middle of the Right Membrana Tympani, in a case of chronic catarrhal otitis. The lower portion is in about normal position, and the manubrium and upper part are not greatly indrawn; while the middle portion is so abruptly retracted as to form a sharp "knee" overhanging the dark depressed area above it, and give rise to a glistening line across the membrane near its middle and closely simulating the surface line of an exudate in the cavity. In front of the manubrium is visible a whitish undefined thickening. (After Randall.)

In the other form, that is, as an accompaniment of an acute congestion of the middle ear, hemorrhagic exudations are by no means common. I refer, as a matter of course, to well-defined exudations, the red color of which is sufficiently pronounced for them to be readily distinguished through the membrana tympani. Serous exudations, slightly tinged with blood, are, on the other hand, often seen, and require no special consideration. The blood-vessels of the tympanic mucous membrane seem rarely to rupture under the strain to which they are subjected in acute congestion of these parts. It is far more common for the vessels which lie near the dermoid surface to break and afford escape to their contents. Occasionally, as a result of violence, both accidents may occur; some of the blood-vessels in the tympanic

[1] Medical Record, New York, October, 1871.

[2] Schwartze has reported (Archiv für Ohrenheilkunde, Bd. 4, S. 12) a case of Bright's disease in which a distinct hemorrhage into the tympanic cavity occurred.

cavity as well as some of those on the outer surface of the membrana tympani affording escape to their contents. This happened, for instance, in the following case:

CASE XXXVII.—*Bluish-black color of the tympanic membrane due to the presence of blood in the middle ear.*

The patient, a carpenter, in robust health, drank to excess one night, got into a fight, and was probably struck on the head. At all events, he remembered waking up, on the following morning, with a loud, ringing noise in the head, marked deafness, and blood oozing from both ears. Two or three days later I saw him at the Infirmary, and found both external auditory canals partially filled with clotted blood. I removed the clots and exposed the drum-membranes to view. The right one was pale and slightly œdematous on its outer surface, but no trace could be found of the spot from which the hemorrhage came. While the outer surface of the left drum-membrane presented the same appearance as that of the right, its deeper tone of color was bluish or bluish-black, indicating the presence of dark blood in the tympanic cavity. The man refused to have an incision made in the drum-membrane, and my notes furnish no further details with regard to the progress of the case, which was undoubtedly one of fracture (or diastasis) of both temporal bones.[1]

The mere fact that serum or mucus has accumulated in the tympanic cavity, in the course of either an acute or a chronic catarrhal inflammation of the middle ear, does not call for a different *prognosis* from that which would properly be given in the same case before this particular symptom had developed.

As regards the *treatment*, there is only one point that calls for special consideration in this place. I refer to the practice of evacuating the fluid contents of the tympanum through an artificial opening in the tympanic membrane. In former years I followed, for a time, the practice of always incising the drum-membrane and evacuating the fluid, as soon as I discovered a sufficient amount of it in the tympanum to apparently half fill that cavity. I very soon found, however, that relapses were exceedingly frequent. I accordingly modified the rule to this extent: I postponed making the incision and evacuating the fluid until after I had materially diminished the naso-pharyngeal catarrh, and had re-established a free passage through the Eustachian tube. Under this régime I observed now and then a case in which the fluid contents of the tympanum gradually disappeared coincidentally with the improvement in the condition of the naso-pharynx; thus rendering paracentesis unnecessary.

[1] For further information in regard to this class of cases, consult the chapter on Traumatic Affections of the Middle Ear.

This suggested to me the idea that the treatment employed in the ordinary cases of catarrh of the middle ear, without effusion, would probably be found equally successful in those with effusion. I accordingly dismissed from my mind the idea that paracentesis was either necessary or desirable, as a means of getting rid of the effusion in the tympanic cavity, and adopted the practice of treating these cases in precisely the same manner as I do the ordinary cases, in which there is no appreciable amount of effusion. I have followed this practice now for many years, and am well satisfied with it. It is only in rare cases now that I yield to the temptation to make an incision and evacuate the fluid; and even in some of these I have afterward arrived at the conclusion that the case would have got well just as quickly if I had not had recourse to the knife.

CHAPTER XII.

NON-SUPPURATIVE OR CATARRHAL INFLAMMATIONS OF THE MIDDLE EAR (Continued).

CHRONIC CATARRHAL INFLAMMATION.

General Remarks.

The expression "acute catarrhal inflammation of the middle ear" is rightly employed when it is applied to a case in which the underlying cause is of a transitory nature—as, for example, a "cold in the head," a mild attack of influenza, perhaps also an attack of hay fever, and still other causes which do not, at the present moment, occur to my mind. It is also rightly employed when it is applied to the early stages of those cases in which a latent goutiness or certain nasal or vault lesions of a fixed character are the cause of the middle-ear inflammation. But when these etiological factors of a more permanent character are not removed by treatment, and as a result the middle ear continues for an indefinite period to be the seat of all sorts of vascular, nutritional, and aërostatic disturbances, the combination of these various pathological phenomena very properly receives the name of "chronic catarrhal inflammation of the middle ear" (otitis media catarrhalis chronica).

If we analyze the pathological phenomena which occur in the middle ear in cases of chronic catarrhal inflammation, we shall find that they may readily be subdivided into three groups, which correspond more or less closely with the three stages through which every chronic inflammation of a mucous membrane passes. The chief characteristics of these three groups are: 1, hyperæmia, or abnormal fulness of the blood-vessels; 2, hyperplasia of the connective-tissue elements; and 3, sclerosis and atrophy of the previously hypertrophied tissues. In most instances a period of several years must elapse before the affected ear, in the natural progress of the disease, reaches the last of these three stages, but no definite period of time can be allotted to any one of them. Furthermore, in many cases, there are particular circumstances which hinder or favor an advance of the disease, and by reason of these the duration of one

or both of the first two stages may be materially lengthened or shortened, as the case may be. My impression is, that the third stage, when once initiated, pursues a direct and more or less regular course, which cannot be influenced by treatment or any extraneous circumstances. It is the expression of a law which governs newly created connective tissue, and therefore must advance in strict obedience to that law. But, in so far as we may prevent or diminish the new-formation of connective tissue, to precisely the same degree does it lie in our power to prevent or diminish the effects of the sclerosis and atrophy which characterize the third stage.

Etiology.—The most important factors in the causation of a chronic catarrhal inflammation of the middle ear are unquestionably the various pathological processes and lesions which are located in the upper pharynx, the naso-pharyngeal vault, and the nasal passages. The chief of these are the following: hypertrophy of the lymphoid tissue which is located in the vault of the pharynx (Luschka's tonsil), hypertrophy of the faucial tonsils, deviations of the septum narium, hypertrophy of both the middle and lower turbinated bodies, and hyperostosis or hyperchondrosis of the nasal septum.

In a few cases the general condition known as goutiness plays a more or less active part in the production of a chronic catarrhal inflammation of the middle ear, or in the aggravation of one which had primarily been called into existence by some vault or nasal disease.

Finally, there are various collateral factors which exert an appreciable — sometimes even a very marked — influence upon the course of the disease which we are now considering. Such are, for example: an occupation which subjects the patient's ears to frequent and somewhat violent concussions of the air; certain climatic conditions; and excessive tobacco-smoking.

NASAL AND VAULT LESIONS.

As the nasal and vault lesions will receive full consideration by my associate, Dr. Robert Lewis, Jr., in the next chapter, I do not need to say very much about them in this place.

There are four ways in which they may perpetuate a chronic catarrhal inflammation of the middle ear, viz., first, by a direct mechanical interference with the circulation, ventilation, and drainage of the Eustachian tube; second, by the direct extension of the

proliferative inflammation which is going on in the mucous membrane of the vault; third, by the frequent establishment of a partial vacuum in the Eustachian tubes; and, fourth, by the indirect provocation of such a middle-ear inflammation through reflex influences.

Direct Interference with the Ventilation and Drainage of the Eustachian Tube.—The lesions which may interfere with the free access of air to the middle ear by way of the Eustachian tube are: unusually voluminous hypertrophied lymphoid tissue, a polypoid hypertrophy of the posterior extremity of the middle turbinated body, and a greatly enlarged faucial tonsil. If it be remembered, however, that there is a great distance between the mouth of the Eustachian tube and the upper edge of the faucial tonsil when in a normal condition, it will be appreciated at once how enormously the latter must increase in size in an upward direction before it can actually obstruct the tubal orifice. On the other hand, the hypertrophied glandular tissues are apt to be surrounded by a good deal of ropy mucus, and it is not unlikely that the obstruction observed in these cases is due in some measure to this product.

Direct Extension of the Proliferative Inflammation from the Vault of the Pharynx to the Middle Ear.—The close anatomical relationship which exists between these two regions makes it almost impossible that an inflammation, or at least a process of hyperplasia, should go on for any length of time in the larger area of the vault without involving the smaller one of the Eustachian tube and tympanic cavity; and there can be no reasonable doubt that this is precisely what does take place in a large proportion of all the cases that belong in this category. As instances of a similar extension of catarrhal inflammation from a larger to a smaller related area, I might mention the catarrhal involvement of the gall and tear ducts.

The Frequent Establishment of a Partial Vacuum in One or Both Eustachian Tubes.—In individuals who have nasal passages of a normal calibre the act of swallowing is not associated with any appreciable disturbance of the aërostatic conditions in the vault of the pharynx or in the Eustachian tubes; for, at the instant when the swallowing begins to create a vacuum in the vault, air rushes in through the nasal passages and makes good the deficiency. If anybody, however, wishes to appreciate how effective the act of swallowing is, as a means of exhausting the air in the vault, he has only to close his own nasal passages and then to perform the act of swallowing. By so doing he will be painfully reminded that the act in question—in the presence of closed nasal passages—produces almost

as perfect a vacuum in the vault as would a successfully applied dry cup. Between this extreme and the normal aërostatic conditions of the vault, it is possible, during the act of swallowing, to obtain all possible degrees of a vacuum in that cavity. The various degrees of swelling of the turbinated bodies, deflections of the nasal septum, and spurs of bone or cartilage projecting from the side of this septum, are all capable of narrowing to a greater or less extent the nasal passages, and, consequently, of producing, with every act of swallowing, corresponding degrees of a vacuum in the vault. Hyperæmia of the naso-pharyngeal mucous membrane is the immediate result of the establishment of such a partial vacuum, and the degree of this hyperæmia will be directly proportionate to the amount of narrowing which the spur of bone, or the bending of the septum, or the hypertrophied turbinated body, has caused in the nasal passages. In the higher degrees of nasal stenosis even the simple act of breathing (with the mouth closed) is competent to create a partial vacuum in the vault. Swallowing is an act of such frequent recurrence that one can easily understand how, in these cases of nasal stenosis, the hyperæmia of the vault—and necessarily also of the Eustachian tubes—must gradually become a more or less constant feature.

The Indirect Provocation of a Catarrhal Inflammation of the Middle Ear through Reflex Influences.—It has been observed that a spur of bone, growing out from the nasal septum and impinging upon the opposite and generally swollen turbinated body (either the middle or the lower one), is very apt to be associated with well-marked catarrhal disturbances in the corresponding middle ear; and, furthermore, that these disturbances are greater than would naturally be expected to result from the same degree of narrowing of the nasal passage *without* the added feature of pressure upon the mucous membrane. The conclusion is naturally drawn that it is the irritation caused by this pressure, which, through reflected nerve action, produces the higher degree of disturbance in the middle ear. And the correctness of this hypothesis is strengthened by the fact that the removal of the spur and the reduction of the swelling of the turbinated body often effect a marked improvement in the condition of the ear.

Combined Action of Two or More of the Nasal and Pharyngeal Lesions. In infants and young children hypertrophy of Luschka's and the faucial tonsils are practically the only local etiological factors with which the aural surgeon has to contend. The

strictly nasal lesions, on the other hand, predominate very decidedly in adult life. Associated with these, however, are sometimes found enlarged faucial tonsils and occasionally a remnant of a formerly enlarged Luschka's tonsil. In rare cases there will also be found some pathological condition of the ethmoid or frontal cells, or of Highmore's antrum; and our attention will then have to be devoted to the cure of these, as being the primary sources of the entire chain of pathological phenomena.

GOUTINESS.

I believe that the sentiment among otologists is quite general that while gout may play a certain part in the etiology of various disturbances of the ear, the facts which have thus far been ascertained are too few or of too doubtful a character, as matter of evidence, to warrant us in establishing a distinct class of cases to which we may apply the term gouty. It is therefore not surprising that modern otological text-books—more particularly those of Germany and the United States—say little or nothing on this subject. It does seem a little strange, however, that in England, which has always been looked upon as the home of gout, and which has supplied the world with the best treatises on the subject, no otological writers of authority, with the exception of Wilde and Toynbee, should have furnished any data in regard to gouty ear disease. Wilde refers to the subject in the following words: "That gouty otitis may exist, I have no doubt, but I myself have never seen a well-marked example of it; neither have I yet read a description of that disease which afforded any one pathognomic [*sic*] which could be relied upon."[1] Then, on a previous page (170), he says; "Gouty inflammation of the external ear has been fully established. Dr. Graves, who was the first to describe this affection, says that the state of congestion of the auricle seldom lasts long, and generally subsides on the occurrence of the disease in the extremities."

Several years later, Toynbee, on page 362 of his work,[2] makes this statement: "The poison of gout may also give rise to deafness and other peculiar symptoms in the head." Then, by way of illustration, he gives the history of a case which he believed to be of

[1] "Practical Observations on Aural Surgery, and the Nature and Treatment of Diseases of the Ear," p. 259 of the American edition. Philadelphia, 1853.

[2] "The Diseases of the Ear; Their Nature, Diagnosis, and Treatment." London, 1868.

gouty origin. As it is the only thoroughly typical case of gouty ear disease of which I have been able to find a record, I make no apology for reproducing the account here in its entirety.

CASE XXXVIII.—[Toynbee's case.]

"D. T——, Esq., aged fifty-four, consulted me in June, 1857. He said that for the last four or five years he had been subject to attacks of gout, which had at times caused him great inconvenience, and the disease had recently made so much progress as to make him fearful that his brain was weakened by its influence. He added that he was never really clear-headed excepting just after an attack of gout, when he supposed his blood was temporarily freed from the poison. He had rapidly aged in the course of the previous two years. An extremely distressing symptom had lately presented itself in the form of a peculiar sensation of vacancy in the ears, accompanied sometimes by a low, humming sound. There was no deafness, and the patient applied to me only on account of the sensations in the ear. On examination, small deposits of gouty matter were observed in the substance of the right upper eyelid; the surface of the meatus externus was of a bright red color; the circumference of the membrana tympani and of the long process of the malleus were also red; while the surface of the tympanic membrane was very bright. Air passed freely, and with the natural sound, into the tympanic cavity. The hearing power was perfect. By what, therefore, could the distressing symptoms be caused? Were they the result of congestion of the nerve?—a condition which, it seemed to me probable, might render the nerve so exquisitely sensitive that the ordinary sounds ever floating in the air might become a source of excitement to the ear. Being aware also, from previous experience in similar cases, that pressure upon the external meatus so as to shut out or diminish the sound in the meatus would remove the symptom complained of, I closed with my fingers each external meatus, and the unpleasant symptoms at once disappeared. On subsequently exerting a gentle pressure on the ears by the introduction of cotton steeped in water into each, the patient was enabled to leave in comparative comfort. For the purpose of preventing the recurrence of the symptoms, it was of course requisite to diminish the congestion, for which purpose two leeches were applied below each ear, small doses of colchicum administered, and strict attention to diet enjoined. The quantity of wine was decreased from four to two glasses daily, and in lieu of beef and mutton, of which he had been in the habit of partaking very abundantly, he was ordered to live principally on poultry, game, and fish, with abundance of farinaceous food and vegetables. The result of this treatment was the removal of the distressing symptoms in the ears, and the gradual disappearance of the attacks of gout."

It is clear, from this account, that Toynbee based his belief in the gouty nature of both these lesions—those seen in the external auditory canal and those assumed by him to exist somewhere in the course of the auditory nerve—partly upon the other pathological phenomena which the patient manifested, and which would be ac-

cepted by all authorities without dispute as being of gouty origin, and partly upon the beneficial results of the anti-gouty treatment adopted.

So far as the older otological literature is concerned, the data given above comprise, as I have already stated, all the information which I have been able to obtain. But in Garrod's classical treatise on gout[1] I find certain statements which may be quoted here, as they bear directly upon the question of the correctness of Toynbee's diagnosis in the case just cited, as well as upon the general subject of gouty affections of the ear. In speaking of the irregular forms of gout—and it is among these that all the ear cases of this disease must be classed—he says (p. 32): ". . . They occur in subjects who have never experienced a true fit, but who either inherit gout, or at least have been much exposed to its predisposing causes. When at any time we can demonstrate that these symptoms depend upon the same diathesis as leads to the inflammation of the joints, we are certainly justified in considering them irregular manifestations of gout." Further on, he says: "On the other hand, there can be no question that the same systemic condition which ordinarily leads to the development of regular gout may at times produce symptoms altogether apart from the joints, but which are essentially of a gouty character." Then again, in speaking of eczema, he says: "Eczema is also a form of skin disease constantly met with in gouty individuals, either localized to a few spots in certain parts, as behind the ears, or on the external ear," etc. The only mention which he makes of any gouty manifestations in the deeper parts of the ear is the following: "Deposits are not unfrequently found upon the drum and the ossicles of the ear, but I have failed to discover uric acid in any which I have examined. I am inclined to regard the alterations which I have now and then seen in the bones of the ear as indicating the presence of rheumatoid arthritic disease rather than true gout."

Finally, Lyman, of Chicago, in his admirable treatise on gout, in the first volume of the "Twentieth Century Practice of Medicine,"[2] mentions a number of alterations in the organ of hearing which have been attributed to the arthritic diathesis; but, as no details of individual cases are mentioned, the reader cannot form an independent judgment in regard to the correctness of these deduc-

[1] Edition of 1876 (London).

[2] Published by Wm. Wood & Co., New York, 1895; Thomas L. Stedman, M.D. editor.

tions. Personally, however, I am confident that at least some of these alterations have been rightly attributed to goutiness.

During the past eight or nine years the conviction has been steadily growing stronger in my mind that a gouty diathesis plays an important part in a very large percentage of the cases of ear disease which we encounter in private practice. I start out with the premise that a patch of eczema, of spontaneous development, signifies the existence, in the individual possessing it, of a gouty diathesis. Garrod's statement, just quoted, is my warrant for this broad rule. As it happens, the floor of the external auditory canal is apt to be the very first spot on the surface of the body where an eczematous inflammation develops. That this should be the favorite spot for the first outbreak of an eczematous inflammation is probably due to two facts: first, that the blood-vessels in this locality are very small; and second, that rarely, if ever, is the skin at this spot disturbed in its quietude. Every other part of the surface of the body is moved at brief intervals, and this motion is unfavorable to stagnation of the blood-current. The spontaneous development of this condition of stagnation in the blood-current of some limited area of the skin constitutes, therefore, a valuable guide-post, pointing, as it does, at a very early stage, to the existence of that disturbed state of the metabolic processes to which the terms goutiness, gouty diathesis, and lithæmia, are applied. It would be extremely interesting to know whether any deposit of the urates occurs at these spots where a stagnation of the blood-current is observed, and where ultimately an infiltration of the tissues takes place. At present, we possess no information in regard to this question, so far, at least, as it relates to the external auditory canal or the middle ear; but the presence of these crystals has been demonstrated in other localized inflammations of a gouty character, and it is therefore permissible for us to believe that they may also here be the exciting causes—or at least contribute to the development—of the pathological changes observed.

I have already, in a previous chapter (Chapter VII.), described what I believe to be the characteristic features of a gouty inflammation of the external auditory canal, and it now remains for me to furnish some instances of a gouty middle-ear inflammation, or at least of the influence which gout may exert upon the course of an otitis media that owes its original start to other influences. Unfortunately, it is not practicable to demonstrate, as may easily be done in the case of the external auditory canal, the precise location, extent, and gen-

eral character of any lesions which may develop in a middle ear that still possesses an intact membrana tympani. Nevertheless, our inferences in regard to these points are not based upon guesswork; they rest upon substantial supports. The following is an example of what I believe to have been a gouty inflammation of the middle ear:

CASE XXXIX.—*Gouty inflammation of the middle ear, with lesions located mainly in the vicinity of the fenestra ovalis; nasal complications; beneficial effects of a visit to Carlsbad.*

The patient, a young woman of twenty-three, and previously of fair average health, consulted me on April 8, 1895, on account of difficulty in hearing. All winter long she had been working hard at her studies, being anxious to graduate with honor from one of the leading colleges for women. Slowly but steadily her hearing had grown more and more imperfect, until finally she experienced great difficulty in hearing what was said to her. Of her general health she had no special complaint to make, but her facial aspect revealed clearly the existence of well-marked anæmia.

On testing the hearing I found that she was almost totally deaf in the right ear. She could distinguish words only when they were spoken in a loud tone of voice almost directly into that ear. On the left side the hearing was still fairly useful; that is, she could distinguish words spoken in a loud tone of voice at a distance of eight feet.

The right external auditory canal was considerably narrowed by an eczematous inflammation of its cutaneous walls; and the corresponding tympanic membrane showed, in its upper posterior portions, decided evidences of hyperæmia and infiltration. (No memoranda relating to the condition presented by the left tympanic membrane were preserved, but it is more than likely that the lesions in this ear were of the same character as those observed in the right.)

An examination of the pharyngeal vault and nasal passages (by Dr. Lewis) revealed the existence of a small spur of bone on the left side of the nasal septum, and a moderate-sized mass of hypertrophied lymphoid tissue in the vault of the pharynx.

In addition to the local treatment (removal of both the nasal spur and the hypertrophied lymphoid tissue in the vault, mopping of the latter region with a fifteen or twenty grain silver-nitrate solution, inflations of the middle ears by Politzer's method), a certain amount of constitutional treatment was inaugurated. Restricted diet; decidedly increased amount of outdoor life; abstention from all studying; massage and the cold pack; the daily taking of iron and the Carlsbad Sprudel salts (a single morning dose); these were the more important constitutional measures which we adopted.

Under this treatment a certain amount of improvement took place, but only at a very slow rate. Toward the end of July it was found that the swollen condition of the right external auditory canal had almost disappeared, and the congested and infiltrated condition of the upper and posterior region of the tympanic membrane had diminished to a noticeable extent. Her general condition had also materially improved. But so far as her hearing was

concerned, the result was certainly not satisfactory. The variations in hearing-power were very striking. For two or three days at a time she would be able to hear general conversation fairly well, and then the hearing would go back almost to the point where it was when we first saw her.

At our urgent request her father then took her to Carlsbad, and she there underwent a stricter course of dieting and drinking of the waters than was practicable at her home near New York.

The patient was seen again on December 14th, a few weeks after her return from abroad. She reported that within twenty-four hours after leaving this port her hearing came back to her, and that all through the voyage she had experienced no difficulty in this respect; a fact which led us to infer that the treatment to which she had been subjected (by Dr. Lewis) had really accomplished more than appeared to be the fact when she left the city. She had gone through the prescribed course in Carlsbad, and up to the date named (December 14th) she had experienced nothing like a relapse. We tested her hearing, and found that she could hear the ticking of the watch fifty inches on the left side and twenty-two inches on the right. For whispered words the hearing-distance, right ear, was twenty feet. Her general health seemed to be excellent.

In January, 1896, the watch test showed: left ear, fifty-five inches; right ear, twenty-two inches. At a still later date (March 5th) the hearing, for the left ear, was found by the same test to be: left, fifty-seven inches (after inflation by Politzer's method, it rose to twelve feet); right, twelve inches (after inflation, twenty-two inches). Then, a short time afterward, her hearing began again to give her some trouble, and her parents determined, upon their own responsibility, to send her for the second time to Carlsbad.

Since the date last named we have not seen the patient professionally. But through other members of the family we have learned that she visited Carlsbad, as already stated, and that during the following winter her hearing had been quite good, although occasionally she would have a slight relapse; but that all through the summer and autumn of 1897 she had experienced no trouble whatever with her hearing.

In this case, which should, as I believe, be classified as gouty, the lesions actually observed in the external meatus and those rightfully assumed to exist in the tympanic cavity are doubtless one and the same in all essential respects. Dilated and therefore paretic blood-vessels; retarded circulation; escape of the watery elements of the blood both upon the free surface of the mucous membrane and into the interstices of the tissues; proliferation of the cellular elements of the connective-tissue stroma; and the swelling or increase in bulk of the tissues thus affected—these are the alterations which a gouty diathesis commonly produces in the skin and mucous membrane of the human ear. That even more profound alterations of the tissues may, in rare cases, take place, is shown by the facts observed in Case XIX. (p. 134). Not only was the skin, in this extraordinary case, involved in a proliferative inflammation of the

most active type, but even the underlying bone structures showed evidences of a disorganization not unlike that observed by Garrod in the knee-joint.

In the case just narrated the gouty attack was a late development, which occurred in an ear that was already seriously threatened by (if not actually suffering from) the hypertrophied condition of the lymphoid tissue in the pharyngeal vault. Cases like this are certainly not common, but they are probably more common than they appear to be at the present time. It is safe to assume that very many of them are classified as simple cases of chronic catarrhal inflammation of the middle ear, and that the important part—yes, often the decisive part—played by the gouty diathesis is overlooked or considered as fanciful.

One point more remains to be considered. I refer to the tendency of the gouty inflammation—as shown in this instance—to localize itself in one part of the tympanic cavity, viz., in that part of the mucous membrane which borders upon the two fenestræ. Then, as regards the gouty nature of these alterations, I can do no better than to call attention to the successful results obtained by an anti-gouty course of treatment, and to the comparatively insignificant results—indeed, sometimes even harmful in their nature—which often follow purely local measures.

In looking over the records of those cases in which I have made the diagnosis of a gouty inflammation of the ear, I find the following memoranda of symptoms or conditions which appear to me to furnish a certain amount of corroborative evidence in favor of this diagnosis: tophi at the finger-joints; occasional stiffness and painful movements of these joints; "rheumatic" pains in different parts of the body; inflammation of one of the joints of the big toe; formication and a sensation of heat, and afterward numbness of the skin, along the outer sides of one or both thighs; a persistent lame sensation, or a sensation of heat in the top of the head; occipital neuralgia; cramps in the muscles of the calf of the leg; painful action, with more or less paresis, of the muscles of the shoulder; disturbances of digestion; sleeplessness; depression of spirits; etc.

COLLATERAL AND INFREQUENT EXCITING CAUSES.

In a large percentage of the cases of chronic catarrh of the middle ear there are other etiological factors at work besides the more important or the more frequent ones which have already been

enumerated. Among these the following may be mentioned: climate, tobacco-smoking, the pollen of certain plants, occupation, and certain bodily diseases.

Climate.—We possess no precise data in relation to the influence of certain climatic conditions upon an otitis media catarrhalis. In a general way we know that a locality in which the air is often surcharged with moisture, and in which sudden and marked changes in temperature are frequent, favors the perpetuation of a catarrhal inflammation of the nasal and aural channels. It is a common experience that when a sufferer from naso-pharyngeal catarrh leaves the damp and changeable climate of his home for one that is more dry and sunny, and less liable to violent changes of temperature, he is very apt to experience an appreciable diminution of his catarrhal symptoms. This beneficial influence, however, is not so great that we can utilize it as a full substitute for certain more radical therapeutic measures. Furthermore, when we come to the practical question, Where is this desirable dry climate to be found? —we discover that the answer is not so readily forthcoming. In the section devoted to the subject of treatment I will throw what little light I can upon this question.

Tobacco-Smoking.—There is a diversity of opinion in regard to the manner in which this habit exerts a harmful influence upon the naso-pharyngeal and aural mucous membrane. Some, like the English authority, Woakes,[1] attribute this injurious effect to the entrance of the tobacco poison into the system. The words of this writer are the following: "Now, while the foregoing is the course of symptoms in a typical case of tobacco poisoning, there can be no doubt that habitual smokers who affirm they experience none of these effects, do notwithstanding manifest some evidence of the physiological action of the drug in the induction of what may be termed a very mobile state of the vaso-motor centres primarily affected by it, rendering them peculiarly susceptible to any superadded disturbing influence. In this way may be explained the peculiar liability to post-nasal catarrh and noises in the ears to which smokers are liable, as well as the difficulty of getting rid of these troublesome ailments as long as the habit is continued. It is, moreover, probable that this peculiar mobility of the vaso-motor centres is transmitted by great smokers to their offspring, giving rise to the tendency to ear disease, croup, and extreme liability to nasal catarrh seen in the children of some families. I entertain

[1] "On Deafness, Noises, and Giddiness in the Head," London, 1879.

very little doubt that there exists a tobacco cophosis just as there is a tobacco amaurosis. Where excess in alcohol obtains, as well as of tobacco, all these proclivities will be intensified; the effects on the succeeding race will then be most manifest. The experience of every medical man in extensive family practice will justify these observations."

Other authorities maintain that the injurious effect is to be ascribed rather to the local irritation excited by the tobacco smoke as it passes repeatedly over the naso-pharyngeal mucous membrane. I am disposed to believe that this latter view is in the main correct. In the first place, I have never observed the red and infiltrated mucous membrane (velum and pharynx), which is so characteristic of the excessive smoker, in tobacco-chewers who do not smoke. Then, in the next place I have frequently been obliged to allow patients who were excessive smokers the privilege of chewing *ad libitum*: for in no other way could I wean them, even for a period of two or three weeks, from the smoking habit; and in these cases I have seen the redness and infiltration subside as rapidly as it does in those who entirely stop the use of tobacco in any form. Tobacco smoke, therefore, I believe, may properly be classed as a direct irritant of the naso-pharyngeal mucous membrane.

The Pollen of Certain Plants.—My knowledge in regard to this branch of the subject is indeed very limited. I have simply observed that not a few of the patients who suffer from chronic catarrhal inflammation of the middle ear experience every summer, between certain more or less fixed dates, an aggravation of the naso-pharyngeal catarrh and a corresponding increase of their deafness and perhaps also of their tinnitus. These periodical exacerbations are by many ascribed to the influence of the pollen of certain plants.

Occupation.—So far as I know, the only occupations which tend directly to aggravate an existing chronic catarrhal inflammation of the middle ear are those of the boiler-maker and the worker in a stamp-mill. It is not entirely clear to what extent each of the two regions supposed to be affected—the membranous lamina spiralis, with its superposed organs of Corti, and the mucous membrane of the middle ear—suffers during the active career of a boiler-maker. It is not unlikely that both of them are affected to a greater or less extent. But the prevailing belief is, that the repeated and violent jarring of the cochlear structures is the main cause of the resulting deafness. The few cases of this character

which have come under my notice have all presented marked evidences of a chronic catarrhal inflammation of the middle ear; and, furthermore, it is well known that *all* boiler-makers do not, even after they have followed this occupation for a period of several years, grow deaf. For these reasons it seems to me permissible to entertain the belief that the violent concussions produced by the hammering are particularly harmful to those ears which are already the seat of a chronic catarrhal otitis media, and that the harm consists in a mechanical disturbance which is sufficiently great and sufficiently prolonged to establish proliferative processes both in the stapedio-vestibular ligament and in the tympanic mucous membrane—more particularly in that part of it which is subjected to the greatest amount of disturbance, viz., the portion which envelopes the stapes.

Certain Bodily Diseases.—In rare cases a chronic purulent disease of Highmore's cave (antrum maxillare) may serve to perpetuate, through the irritation which it excites in the neighborhood of the Eustachian tube, a chronic catarrhal inflammation of the middle ear. Pain in the region of the upper maxilla, sometimes swelling of the soft parts which cover it, and a distinctly purulent discharge into the naso-pharyngeal cavity—these are the symptoms which are most likely to call our attention to the real centre of active disease.

Equally rare, so far as my observation goes, are the cases in which an organic disease in some remote part of the body seems to be competent, through a reflex mechanism, to aggravate a catarrhal inflammation of the middle ear. The following is a case in point:

CASE XL.—*Chronic catarrhal inflammation of the middle ear, with distressing tinnitus; disappearance of the latter symptom when the patient's uterine and pelvic inflammation had been subdued.*

A lady, about forty years of age, and otherwise in good health, consulted me for the relief of a distressing tinnitus involving both ears. She had experienced the symptoms of a mild naso-pharyngeal catarrh from time to time during a period of many years. Her hearing had not been affected, and there were times when she was almost entirely free from the tinnitus. Her digestion had always been good. I saw her at intervals of a few months, and always succeeded in giving her prompt relief by applying a moderately strong silver-nitrate solution, with a mop of absorbent cotton, to the vault of the pharynx, on alternate days. There came a time, however, when these applications failed to give the desired relief. The tinnitus became almost unbearable. I then learned from the patient that she had been a sufferer, for many years, from pain in the pelvic region and back, and that at this particular time she was suffering to a more marked degree than usual. I urged her

to consult a specialist with regard to the suspected uterine disease, and she finally but very reluctantly consented to do so. In this way it was ascertained that the fundamental trouble was a retroversion of the uterus, associated with a chronic subacute parametritis which, from time to time, under the provocation of too much running up and down stairs, etc., became acute. Under proper treatment the parametritis was subdued, the uterus was restored to its proper position and kept there by means of a suitable pessary, and finally, without any further local treatment of the vault of the pharynx, the tinnitus gradually disappeared altogether.

Prognosis.—During the past ten years the prognosis, in cases of chronic catarrhal inflammation of the middle ear, has been steadily growing more favorable. The reasons for this are not far to seek. In former times we—by which I mean aural surgeons in general—did not appreciate, as we have since learned to do, the great importance of nasal and vault lesions in originating, as well as in perpetuating, chronic affections of the middle ear. Then, besides, it required a period of several years before we had learned fully how far it was safe to go in our interference surgically with these unfamiliar parts, and what were the best methods of solving the therapeutic problems which were here presented to us. In large measure these various difficulties have now been overcome, and as a result we are able at the present time to report as materially benefited many cases which in the earlier period would have been dismissed as incurable. It is only in those which have distinctly reached the stage of progressing or completed sclerosis that we are warranted in withholding all encouragement. There is also another aspect of the question which must not be overlooked. If it be admitted that these nasal and vault lesions are the chief causes of a chronic catarrhal inflammation of the middle ear, it must also be conceded that in removing these lesions, especially in the earlier years of life, we are performing a valuable piece of prophylactic work; that is, we are warding off a worse degree of deafness than that which may happen to be the patient's lot at that particular time.

Treatment.—The great majority of cases of chronic catarrhal inflammation of the middle ear owe their origin chiefly to some one or more of the nasal or vault lesions already mentioned. Consequently the rectification of these lesions constitutes the larger and the more important part of the treatment. A detailed account of the different therapeutic procedures which are required for the accomplishment of this purpose will be found in the next chapter. In the present section, therefore, I shall confine myself to a simple

enumeration of the collateral measures which play a more or less important part in effecting an amelioration of the patient's condition.

For our present purposes, then, we may assume that the nasal cavities, the vault of the pharynx, and the fauces have received all the local surgical treatment which their respective pathological conditions demand. The question then arises, whether any further local measures, directed to the vault, Eustachian tube, and tympanic cavity, may or may not advantageously be undertaken. I will recapitulate briefly the different pathological conditions which are likely still to be present after the more conspicuous vault and nasal lesions have been remedied. They are as follows: more or less hyperæmia of the vault of the pharynx, the Eustachian tube, and the tympanic cavity; possibly a little free secretion in the latter cavity; more or less rigidity of the different ossicular joints or connections; abnormal dislocation inward of the tympanic membrane and connecting ossicula; and perhaps also a somewhat dilated condition of the labyrinthine blood-vessels. We cannot say positively, in any given case, whether it be or be not practicable to diminish some or all of these abnormal conditions. In a general way, however, it may be said that when these alterations have existed for a long time, and particularly if the process of sclerosis has already set in, our efforts to improve them will almost surely be in vain. But in a fair number of cases the pathological alterations consist, to a greater or less extent, of lesions which are amenable to treatment: such, for example, as a paretic condition of the blood-vessels, and an infiltration of the connective tissue of the part with a serous fluid. Our methods of examination do not always furnish us with accurate information in regard to these conditions, and so we are occasionally obliged to undertake treatment tentatively—*i.e.*, without a positive knowledge that the lesions which impair the hearing are, to a certain extent, amenable to treatment.

The collateral measures which may sometimes be used to advantage in the cases which we have just been considering are the following: inflations of the middle ear, continuance of the silver applications to the vault of the pharynx, and the adoption of certain general measures which have for their object an acceleration of the metabolic changes—an improvement in the processes of assimilation and retrograde metamorphosis of waste materials.

Inflations.—The tendency of these is to diminish—probably through pressure—the hyperæmia and infiltration of the tubal and tympanic mucous membrane, and at the same time to gradually

give greater mobility to the ossicular mechanism. I possess no facts which would warrant me in stating for just how long a period this part of the treatment should be kept up before we can safely determine that it is useless to persevere any longer. I must confess frankly that on this point my former teaching has perhaps erred somewhat on the side of abandoning them too early. While it is still true that in most instances nothing is to be gained by pushing the experiment beyond the third week, there are undoubtedly a few cases in which the improvement does not begin to show itself until during the fourth or fifth week. Then, on the other hand, there must always be a certain amount of doubt, in the mind of a candid observer, as to how much of this improvement which begins at such an abnormally late date ought rightfully to be attributed to the inflations, and how much to the other therapeutic measures which may have been adopted. In any event, it is better to continue the former for an additional week or two needlessly (as may prove to be the case) than to abandon them prematurely.

Silver-Nitrate Applications to the Vault of the Pharynx.—So long as any recognizable degree of hyperæmia continues to be present in this region it is advisable not to abandon the silver applications. Their beneficial influence, as I have stated in a later chapter, is not confined to the area of mucous membrane upon which the drug is applied, but extends—doubtless through reflex influences—to the congested tympanic cavity.

General Measures.—Limited areas of hyperæmia may be influenced beneficially by all those various general measures which have for their object the acceleration of the metabolic changes in all parts of the body. In this category belong active outdoor exercise (horseback-riding, mountain-climbing, bicycle-riding, rowing, etc.), massage, the use of the Russian bath and even of ordinary hot baths, dieting, and the drinking of the Carlsbad Sprudel and other similar waters. In some instances greater benefit may be obtained from the administration of such remedies as iron, strychnine, and cod-liver oil, and from a residence in a dry climate, especially if the locality chosen is situated at a fairly high altitude (4,000–5,000 feet above the sea-level).

CHAPTER XIII.[1]

THOSE PATHOLOGICAL CONDITIONS OF THE FAUCES, VAULT OF THE PHARYNX, AND NASAL CAVITIES, WHICH PLAY AN IMPORTANT PART IN THE CAUSATION OF EAR DISEASES.

I. METHODS OF EXAMINING THE PARTS

Inasmuch as a large percentage of the cases of ear disease owe their origin to pathological conditions of the vault of the pharynx or of the nasal cavities, it is plain that a complete and satisfactory diagnosis, in cases of this nature, cannot, as a rule, be made without a thorough examination of these regions.

The Kind of Light Required.—To make a proper and thorough examination it is necessary to have a bright light, and for this purpose there is nothing better, as I believe, than the electric light. A 16-candle-power electric lamp, with a ground-glass bulb of cylindrical shape, mounted inside the metal cylinder of a Mackenzie bull's-eye condenser which is supported by a swinging bracket (see Fig. 56), will be found to furnish admirable illumination. The Welsbach light

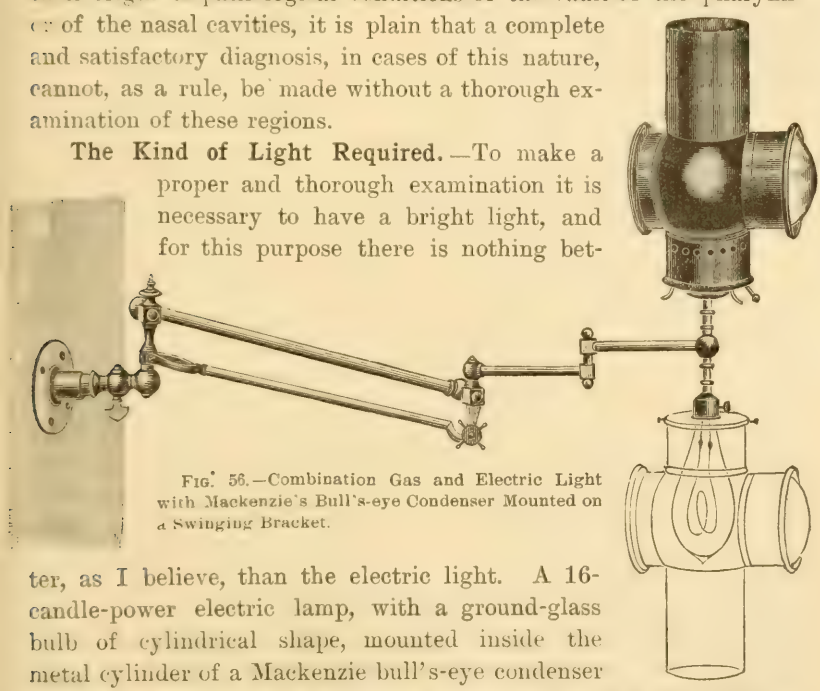

Fig. 56.—Combination Gas and Electric Light with Mackenzie's Bull's-eye Condenser Mounted on a Swinging Bracket.

[1] Contributed by Dr. Robert Lewis, Jr., Instructor in Otology in the College of Pysicians and Surgeons, Medical Department of Columbia University, New York.

also affords good illumination. The form of mounting (with a bull's-eye condenser, swinging bracket, etc.) should be the same as that used with the electric light. It is possible to have both of these mounted on the same bracket, as shown in the cut. The Welsbach light is very white and more powerful than the 16-candle-power electric light. It also has the advantage of not necessitating the employment of an alcohol lamp or other means

Fig. 57.—Phillips' Photophore.

for heating the rhinological mirrors. On the other hand, it is very objectionable on account of the heat which it produces, which, on a warm summer's day and during a long séance, becomes alike unbearable to the patient and the surgeon. When neither electricity nor gas can be obtained, a German student lamp, fitted with a Mackenzie condenser, makes a very useful artificial light for nasal and pharyngeal work. As we cannot expect to have these convenient forms of light outside our offices, we must often get along at the patient's bedside, as best we may, with whatever light is obtainable—an awkwardly placed gas bracket, a lamp, an ordinary candle, or the sunlight. But in these days it is a possible thing to avoid any such inconvenience, for one may obtain a storage battery of four cells, weighing less than three pounds, which will illuminate a 4-candle-power light. This light

may be mounted on a metal headband, as shown in Phillips' photophore (Fig. 57). The lamp, as now made, is much less clumsy than that shown in the illustration. It possesses a double joint, which allows the light to be thrown in any direction; and at the same time a lens, which is attached to a slide, permits the focus to be adjusted as desired. In fact, this direct means of illumination would be almost ideal if it were not for the expense and uncertainty of its source of light, the storage battery, as also for the fact that after a time—say from thirty to forty-five minutes—it becomes so hot as to necessitate its discontinuance for a short period. If desired, it can be used in our offices by means of the device shown in Fig. 58. With all sources of light except the last it is necessary to reflect the light from the forehead-mirror. The headband that I prefer is the one depicted on the next page (Fig. 59). It is composed of a steel band connecting two concave cross-pieces at either extremity, on the anterior one of which is mounted the socket for the mirror. The advantages of this device are these: it comes in contact with the head only on the forehead and on the occiput, and consequently it does not encircle the head in a tight band; it



FIG. 58.—Apparatus by Means of Which the Street Supply of Electricity may be Utilized for a Variety of Surgical Purposes.

[1] In this series of instruments the electricity is conveyed first to a motor, which may be used, independently of the rest of the apparatus, to run a trephine or drill. This motor acts also as an electric transformer to change the direct current into an alternating current, and the latter is then conducted from the motor or transformer to two induction-current controllers—one for cautery, the other for illuminating purposes. These controllers also act as rheostats to vary the amount of electricity allowed to either the lamp or the cautery point. This is accomplished by means of a ratchet movement, which slides the outer coil on or off the inner one, as takes place in the induction coil of a faradic battery. Thus this instrument serves the triple purpose of furnishing a motor for operative work, heat for cautery purposes, and light for illumination.

is cool; and it requires no adjustment of band and buckle, thus being always ready for use, no matter what may be the size of the surgeon's head. It is also very durable, and can, if desired, be



Fig. 59.—Forehead-mirror with Steel Headband.

obtained jointed for folding purposes. The mirror itself should be backed with aluminum, for when thus constructed it is much lighter, and therefore does not cause fatigue so readily as when it is made of a heavier metal. Among ordinary headbands I find

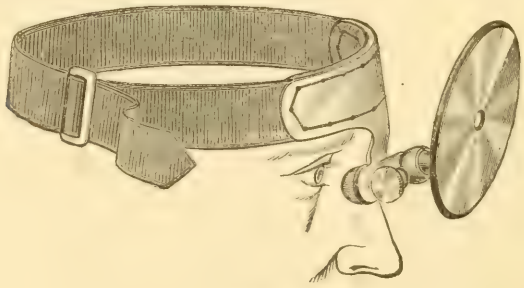

Fig. 60.—Schrötter's Headband.

that which is known as Schrötter's headband (Fig. 60), which is made with a ball-and-socket joint, the most serviceable.

Tongue-Depressors.—For a tongue-depressor I prefer the pattern known as Sass' tongue-depressor (Fig. 61), which has a narrow and smooth blade, with a fairly long handle. The blade of this instrument will not hurt the patient's tongue, and the handle will permit of a firm grip with a maximum amount of leverage. A tongue-depressor with a broad blade which covers the whole surface of the tongue is more apt to cause retching than one with a narrow

blade; and a blade with ridges running transversely across its under surface is very unpleasant, if not painful, for the patient, especially if any degree of pressure is required in order to hold down a resisting tongue.

Nasal Specula.—Of all the forms of nasal specula which I have tried, Duplay's bivalve speculum (Fig. 62) has given me the most satisfaction. It is easily manipulated, and, when inserted into the nostrils and opened, it holds them firmly and widely opened, and is itself easily held in position. The so-called self-retaining specula I have found to be either misnamed, or, if they are really self-retaining, they hurt the patient by reason of the extreme pressure

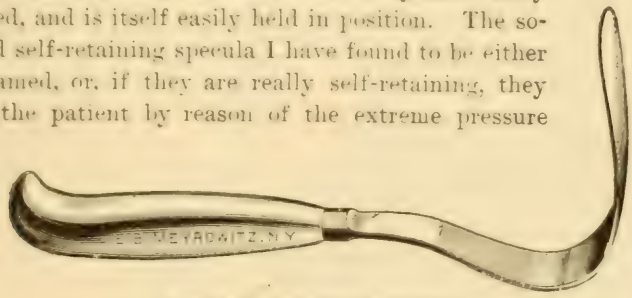

Fig. 61.—Sass' Tongue-Depressor.

which must be employed in order to render them self-retaining. This is not the case, however, with the smooth oval surfaces of the bivalve speculum of Duplay.

Anterior and Posterior Rhinoscopic Examinations.—Having at our command the means of making anterior and posterior rhinoscopic examinations, we proceed to do so in the following manner: The patient should be seated in front of, and, if possible, on a level with the surgeon; his head should be tilted a trifle backward and his mouth should be wide open; then the light should be thrown into the buccal cavity, and he should be ordered to breathe in slowly and as naturally as the circumstances will permit. Insert the tongue-depressor and pass it gently along the dorsum of the tonuge until a sufficient surface is covered to hold the organ firmly in position. If this be done slowly and gently an otherwise sensitive patient may remain passive without retching throughout the examination. The rhinoscopic mirror requires to be heated (to prevent cloudiness of its surface) before it is introduced into the faucial cav-

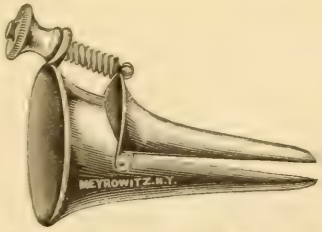

Fig. 62.—Duplay's Bivalve Speculum.

ity; and, in order to make sure that it is not too hot, the surgeon should adopt the inflexible rule of testing the instrument upon his cheek or the back of his hand. Otherwise he may severely burn his patient, and so give rise to a very serious inflammation of some part of the fauces. When the mirror has been satisfactorily heated it should be introduced behind the uvula, in such a manner—if possible—as not to touch the parts. If this be accomplished without causing the patient to retch, it is likely that the examination will then be rapidly made. The mirror is to be moved in a rotatory manner, so as to gradually bring all the various anatomical or pathological parts, as the case may be, into view. An endeavor should be made to first bring the vomer into the field of vision, as by the aid of this the other landmarks can be located. Then, in succession, the turbinated bodies, the vault of the pharyx, the fossa of Rosenmüller, the mouths of the Eustachian tubes, and the posterior surface of the uvula should all be examined (see Fig. 63).

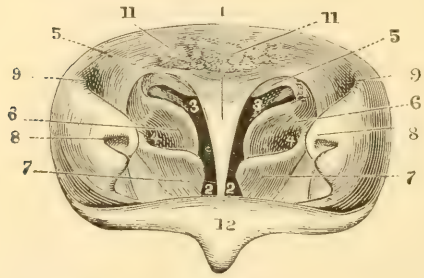

Fig. 63.—Rhinoscopic Image (from Cohen's "Diseases of the Throat"). 1, Vomer or nasal septum; 2, free space of nasal passages; 3, superior meatus; 4, middle meatus; 5, superior turbinated body; 6, middle turbinated body; 7, inferior turbinated body; 8, pharyngeal orifice of the Eustachian tube; 9, fossa of Rosenmüller; 11, glandular tissue; 12, posterior surface of uvula.

If the patient is unable to control the uvula and faucial muscles, the experiment may be tried of having him breathe through the nose or utter a nasal sound. By this expedient the muscles may often be brought under control. If the experiment fails, a four-per-cent solution of cocaine may be sprayed over the fauces, or the patient may be given a small piece of ice to suck; both of these measures tending to render the parts less irritable. But even after all these different measures have been tried, much patience and perseverance may be required before a satisfactory examination can be obtained. Thus, for example, it may be found necessary to ask the patient to practise regularly at home with a spoon, introduced into the mouth as a tongue-depressor. He should stand in front of a mirror while doing this, and should watch the movements of the uvula. Then, when he finds that he can do this without causing retching, he should practise with a cotton-tipped appli-

cator until he can make an application to the pharynx without provoking retching. There are some patients, however, in whom all these means fail, and then our only available way of learning what is the condition of their pharyngeal vault is to resort to palpation a method of investigation which will be described under the subject of Hypertrophy of the Pharyngeal Tonsils (p. 268).

To make an anterior rhinoscopic examination is a task much less difficult than the one just described. The following are the various steps required: The light should be thrown into the patient's nostril, after lifting up the tip of the nose to a slight extent. The speculum should then be inserted and opened by means of the screw

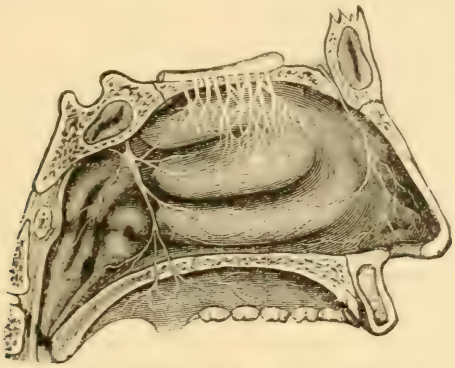

Fig. 64.—Relations of the Turbinated Bodies to One Another and to the Pharyngeal Cavity.

and nut. If there are any short hairs which obstruct the view, rotate the speculum round an entire circle and this will flatten them down out of the way. Then carefully observe the color, shape, and condition of the turbinated bodies, as well as of the septum. If the turbinated bodies are swollen, take a probe and ascertain to what extent the mucous membrane is movable upon the framework of bone. Also look for ridges or spurs or deviations of the septum, and, if they exist, note their situation, their size, and the probable thickness of the septum at the site where they are located. If any discharge exists, determine its probable source and note its character, amount, and odor. When satisfied with the view obtained in this manner, spray the nasal cavities with a solution of cocaine, and, after the lapse of about five minutes, again repeat the examination. Note any change which may have taken place in the tissues—as, for example, a change from a previously red and swollen

condition to one in which the parts are pale and reduced in size. The probe should also be used a second time, in order that further information may be gained in regard to the condition of the mucous membrane covering the turbinated bodies. In this way, for example, it is possible to determine whether an apparent enlargement of the parts is due to mere vascular dilatation or to a true hypertrophy. Furthermore, after the spraying with a cocaine solution, it will be possible, in most cases, to obtain a better view of the posterior nares, as well as of the pharynx, than before.

Fig. 64 gives a fair idea of the size of the turbinated bodies and of their relations one to the other and to the neighboring parts of the nasal pharynx. The antero-posterior diameter of the pharynx is, in this cut, unusually short.

II. HYPERTROPHY OF THE LYMPHOID TISSUE IN THE VAULT OF THE PHARYNX.

(Hypertrophy of the pharyngeal or Luschka's tonsil; Adenoid vegetations in the vault of the pharynx; Enlarged third tonsil.)

The pathological condition which is designated by these various terms plays a part of the first importance in the etiology of diseases of the ear. It is responsible, directly or indirectly, for a large percentage of both the acute and the chronic diseases of the middle ear. In view of the importance of the subject, therefore, it seems to me a desirable thing that I should treat it at some length.

Czermak was the first (1860) to see this glandular structure in the living subject. Shortly afterward Türck, Löwenberg, and Voltolini reported cases in which they had observed an enlargement of the gland. Sir Andrew Clark,[1] in 1864, described the lesions which we are now considering, under the name of "Naso-Palatine Gland Disease"; but it was not until Meyer of Copenhagen published, in his classical treatise,[2] the results of his investigations upon this glandular growth, that general attention was called to this important pathological condition.

Etiology.—This hypertrophy of Luschka's tonsil, as is generally the case with glandular enlargements, is a condition which belongs essentially to early life, and it occurs much more frequently than is commonly supposed. The larger number of cases are seen

[1] Vol. I., London Hospital Reports.

[2] Medico-Chirurgical Transactions, 1870; also Arch. für Ohrenheilk., 1874, Bd. viii., p. 241, Vol. 53, p. 191.

in children between five and fifteen years of age; beyond twenty years it is uncommon; but under five years it is often found, and probably is present much more frequently at this age than statistics would lead us to believe. Their failure to show this is doubtless due to the fact that at this early age there is a lack of pronounced symptoms, and consequently they are not recognized. It has been observed so early in life (cases have been operated upon as early as at the age of three months) that it must, in many instances, be congenital. As to the influence of sex, statistics show a slightly greater proportion of male over female cases. The distribution of the disease throughout the world is very general. Meyer, of Copenhagen, in an elaborate article[1] upon the antiquity and distribution of these growths, arrives at the following conclusions: Adenoid vegetations are to be found with varying frequency in at least three parts of the world, viz., in Europe, in America, and in Asia; a cold climate is more favorable to their growth than a warm one; and, from an examination of ancient sculpture and more modern paintings, he believes the human race to have been afflicted since the beginning of history.

Hereditary influences are an important factor in the development of the disease. Either parent of a child suffering with this hypertrophied gland-tissue will often be found to be a victim of chronic pharyngitis, or of chronic catarrhal otitis media with sclerotic membrana tympani, and with a history which points clearly to the presence of adenoid enlargement in childhood. H. Beckman, of Berlin, relates an instance[2] of a family in which there were eleven children, five of whom resembled the father, while the other six resembled the mother. The father was afflicted with chronic naso-pharyngeal disease, which was also hereditary with him; and the five children who resembled him had well-marked "adenoids." The other six were quite free from this condition. In at least sixteen families, in private practice, I have found it necessary to remove adenoids in two, three, four, or five members of the family. The condition is to be found among the wealthy as well as among the poor. The environment seems to have no effect upon its occurrence.

Early life is more prone to disease of the lymphatic structures; and, as this gland is the first one with which the germ-laden air comes in contact during the act of respiration, an acute inflamma-

[1] "Adenoid Vegetations; Their Distribution and Antiquity." Hospitals Tidende, 1895, No. 6.

[2] Monats. für Ohrenheilk., No. 9, 1897.

tion, dependent upon bacterial action, is more likely to occur here than in any other lymph-gland. Furthermore, a first attack predisposes to a second, and so on, especially if an inherited tendency exists. After a number of such attacks, the resulting inflammatory activity of the epithelial and lymphatic elements of the gland soon gives rise to a true hypertrophy.

Anatomically, "the pharyngeal tonsil is a sessile collection of lymphoid bodies"[1] occupying the posterior and upper pharyngeal wall and connected by lymph ducts with the inner cervical lymphatic glands. It is made up of a reticulated framework of fibrous connective tissue, which supports the lymphatics, their ducts and blood-vessels; its free surface is covered, as are also its interlobular surfaces, with columnar ciliated epithelium, which is continuous with that lining the adjacent mucous membrane of the naso-pharynx. Mucous glands, whose ducts open upon the surface, and clusters of leucocytes are imbedded in the connective tissue. The fissures between the lobes—some shallow, some deep—divide the gland into a number of longitudinal ridges.

"Embryonically, it is the lower portion or stalk of the pituitary body, from which it has become separated by the ossification of the base of the skull. Not infrequently, in early life, a fibrous cord still runs up through the body of the sphenoid, connecting the two glands."[2]

Physiologically, some of the leucocytes formed in this gland pass into the blood from the lymph stream, while others pass outward, mingle with the mucus on the surface of the gland, and perform their phagocytic function in the destruction of the bacteria carried in with the inspired air.

Pathology.—As noted above, especially in cases in which there is an hereditary tendency, the bacteria of influenza, diphtheria, or some other form of disease will set up a purely local inflammation, and cause an inflammation of the epithelial and lymphatic tissues of the gland which in time produces a genuine hypertrophy. The gland may become so large (Figs. 65 and 66) as to occupy the entire vault of the pharynx, blocking the posterior nares, covering the pharyngeal mouths of the Eustachian tubes and the fossæ of Rosenmüller, and extending as far down, on the posterior and lateral walls of the pharynx, as to present itself to view, behind the velum, whenever the patient opens his mouth widely. The act of swal-

[1] Harrison Allen's "Human Anatomy," vol. ii., p. 636.

[2] Woods Hutchinson, Medical News, January 16th, 1897.

lowing and the efforts to breathe cause friction between the epithelial surfaces of the lobules of the enlarged gland as well as between those of the walls of the pharynx and the free surface of the glandular mass. This friction and pressure produce, in time, a change in the glandular structures, and especially in its epithelial covering. The latter first loses its cilia, gradually assumes the characters of squamous epithelium, and in the course of the process may become either thickened or thinned. While this change is taking place the fibrous framework becomes hypertrophied, presses on and constricts the blood-vessels and lymph ducts, and so gradually causes them to become obliterated. Ultimately, the lymph cells diminish in number as the blood-supply becomes less in quantity; in other words, the glandular mass gradually atrophies.

FIG. 65.—Adenoid Vegetations at the Vault of the Pharynx. The orifices of the Eustachian tubes are completely concealed by the growths. Copied from nature by means of the rhinoscopic mirror. (After Meyer.)



FIG. 66.—Another Case of Adenoid Vegetations Springing from the Upper Wall of the Vault. The large, smooth, rounded masses represent jelly-like hypertrophies of the mucous membrane of both lower turbinated bodies. The larger of the two completely fills the posterior end of the corresponding nasal passage. (After Meyer.)

When we take into consideration the fact that the larger number of contagious diseases are conveyed into the system through the medium of the air, the abnormal condition of the portal to the respiratory system must be looked upon as a very important factor in the pathology of this class of diseases. In the hypertrophied state of the pharyngeal tonsil the physiological flow of the leucocytes outward toward its surface is interfered with, and consequently its phagocytic function is destroyed, thus permitting disease germs to invade its tissues, and finally to pass into the blood circulation. May not the coryzas and general pharyngo-nasal catarrhs which

are so often the precursory signs of one or the other of the infectious diseases be accounted for by the direct invasion of the system through this gland, which, through the influence of inflammatory changes, has lost its protective powers?

A number of authorities have subjected this gland, when in an hypertrophied condition, to a bacteriological examination. Among this number may be mentioned Goure, who found, in 201 examinations, the streptococcus present 37 times; the staphylococcus unassociated 60 times, associated with other germs 69 times; the coccus pure 41 times, associated 94 times; the pneumococcus 3 times; the leptothrix buccalis twice; Koch's tubercle bacillus not at all, though there was a tubercular history present in 67 of the cases, in 17 of whom there was a lung or other organ involved.[1] The importance of this glandular element in tubercular infection has been studied by Strassmann, Dmochowski, and Krückmann,[2] who have demonstrated the existence of tubercle-bacilli in the tonsillar tissues. Pilliet found giant-cell systems and caseous degeneration in 3 cases out of 40 examined, though he found no tubercle-bacilli. Dieulafoy[3] inoculated 35 guinea-pigs with a solution obtained from the macerated adenoids of as many individuals, and 7 of the guinea-pigs, or 20 per cent, became tubercular. Pluder and Fisher,[4] out of 32 cases examined, found the bacilli in 5 of the cases, or 15.6 per cent; Brindel,[5] out of 64 cases, in 8, or 12.5 per cent. Gottstein found, in 33 cases, 4 (or 12 per cent) affected.

Acute purulent rhinitis of children is undoubtedly a sequela of an acute inflammation of Luschka's tonsil, the gland involvement being the primary lesion. Friedrich endeavored, in repeated instances, to inoculate the healthy mucous membrane of the nose with secretions obtained from cases afflicted with a "cold in the head," but he did not succeed. When later, however, he rubbed the secretion over the region of the pharyngeal tonsil, a typical "cold in the head" developed.[6] Chatellier[7] studied the microbes which are ordinarily to be found in adenoid vegetations, and he found that they were identical with those found in the ears in purulent otitis and in

[1] Annales des Maladies de l'Oreille, etc., No. 5, 1897.

[2] Reported in Edinburgh Medical Journal, April, 1897, by McBride and Turner.

[3] Bull. de l'Acad. de Méd., April 30th, May 7th and 14th, 1895.

[4] Arch. für Laryngol. und Rhinol., Berlin, 1896, Bd. xiv., September 3d.

[5] Rev. Hebd. de Laryngol., July 26, 1896.

[6] Berlin. Klin. Wochenschr., Parts 31 and 32, August, 1896.

[7] Journal of Laryngol. and Rhinol., etc., 1891, p. 340.

the nose in attacks of coryza. It is not difficult to understand how an invasion of the nasal cavities may involve the ethmoid, the sphenoid, or the frontal cells, and even ultimately the cranial cav-

FIG. 67.

FIG. 68.

FIG. 69.

FIG. 70.

FIG. 71.

FIG. 72.

FIGS. 67-72.—Photographs Taken from Three Individuals, showing the facial expression both before and after the removal of the adenoid growths. (After Meyer.)

ity (meningitis). Then again, the inflammation may extend down the respiratory tract, giving rise to a tonsillitis, a bronchitis, or even possibly a pneumonia. Lennox Browne relates the case of a child, the subject of frequent attacks of bronchitis, in whom he removed the hypertrophied pharyngeal tonsil. During the seventeen years which had elapsed since the operation she had had no further chest or throat trouble. Finally, the inflammation may extend through the Eustachian tube to the middle ear, causing an acute otitis media purulenta; and this in turn may extend to the mastoid cells or even to the cranial cavity, causing a pachymeningitis, a meningitis, a sinus phlebitis, or a brain abscess.

Symptoms.—The symptoms, which depend largely upon the size and situation of the growth, are primarily those of nasal obstruction. In a typical case the facial expression (see Figs. 67, 69, and 71) will present certain striking characteristics. The open mouth, the hanging lips, the irregular teeth, the narrow and high-arched palate, the drooping eyelids, and the pinched or flat nose give to the patient somewhat the appearance of an imbecile. The sufferer breathes almost entirely through the mouth and with a noisy respiration, which is especially marked when sleeping. Sleep is restless and associated with disturbing dreams, or, in some particularly aggravated instances, with nightmare. Children who have adenoids not infrequently cry out in their sleep. The moisture of the buccal cavity is absorbed by the inspired air more rapidly than it is secreted, and consequently the mouth and throat are dry. A constant desire to swallow, as if in an endeavor to get rid of a foreign body, exists. A purulent discharge forward into the nares and downward into the throat is frequently present; this discharge giving rise to a fetid breath. Nose-bleed is an occasional symptom in some cases. Enunciation is very indistinct: *b* is substituted for *p*, *d* for *t*; *m* and *n* are pronounced as *eb* and *ed*. It is not necessary for the growth to be very large to give rise to this faulty pronunciation. The singing voice is especially interfered with. The voice, instead of striking against a smooth, hard, concave substance—as is the normal pharynx, which is admirably adapted to act as a sounding-board—strikes a soft, irregularly spherical mass, which deadens the voice. In infants there is a difficulty in sucking, it being impossible for the child to breathe while feeding. Consequently an infant with adenoid hypertrophy is likely to be poorly nourished; for not only is its blood insufficiently oxygenated (owing to the diminished air supply), but

the pituitary reflex (which is explained further on) is also disturbed. In an extreme case the child will be found to be narrow-chested, anæmic, of feeble muscular power, and with a system incapable of resisting morbific influences. Another striking peculiarity in the patient's physiognomy—one which has been observed in a number of instances—is an unusual distension of the transverse nasal vein at the root of the nose. This is caused by the pressure on the pharyngeal veins with which it anastomoses.

In addition to the symptoms described above we sometimes encounter other reflex disorders, such as nocturnal enuresis and attacks of laryngismus stridulus. Lennox Browne[1] expressed "a tolerably sure conviction that in almost every case of laryngismus, as well as in those of tetany and convulsions, the subject would be found to be a mouth-breather; and that, if sought for, adenoid growths would always be discovered." He has removed adenoids from a patient in whom the only symptom was that of laryngismus. He is also reported to believe that the same fact exists in regard to rickets. H. Beckman[2] states it as his belief that there are two diseases which bear a close relationship to hypertrophy of the pharyngeal gland, namely, rachitis and laryngismus stridulus; and he accounts for this relationship by a reference to the fact that the whole lymphatic system is closely related to growth, and especially to growth of the bones. Consequently any interference with the function of the lymphatic system, such as occurs in hypertrophy of the pharyngeal tonsil, is capable of causing the pathological conditions enumerated. Walker Dowine[3] relates the histories of four patients who were subject to convulsive seizures and who possessed enlarged pharyngeal tonsils. In all these cases he removed the adenoids, and the results were as follows: In one case, an interval of several months had elapsed since the operation, and there had been no return of the convulsions; in the second case, in the place of several attacks every week, there had been only one attack during a period of two months; in the third, the number of attacks had diminished; while, as regards the fourth case, the patient had been lost sight of. A. J. Gillette[4] reports three cases of torticollis due to hypertrophy of this tonsil, and relieved by operation. Arslau, of Padua, claims to have cured a case of Jacksonian epilepsy by re-

[1] British Medical Journal, February 15th, 1890.
[2] Monats. für Ohrenheilk., No. 9, 1897.
[3] Glasgow Medical Journal, January, 1896.
[4] New York Medical Journal, August 1st, 1896.

moval of this gland. Bosworth[1] cites a case of asthma in which he obtained a complete cure by removal of the growth; and he speaks of Fraenkel and Chatellier as having also made similar observations. Headaches, deficient cerebration, or aprosexia[2]—as Guye, of Amsterdam, termed it—are very common symptoms. The latter authority explains this symptom by pointing to the fact that the large lymph-vessels leave the cranial cavity along with the fibres of the olfactory nerve. Structural changes in the naso-pharyngeal or nasal mucous membrane will, by reason of the amount of pressure which they exert upon the lymphatics, cause a retention of the products of metabolism in the cerebral tissues. This retention of the products of metabolism in the brain (due to interference with the lymph current) will lead to results which are essentially the same as those of physiological exhaustion—or, in other words, of fatigue. Pressure upon the lymphatics may be due, however, to other causes besides permanent changes in the tissues of the nasal mucous membrane. Thus, for example, a temporary local hyperæmia, the effect of a vaso-motor reflex action—such as is likely to take place when a person goes from the cold air outside into a warmed room, or is exposed to sudden changes of temperature—may cause a paroxysmal attack of aprosexia. I presume that this is the explanation why an intense drowsiness often comes over certain individuals when they pass from the cold outdoor air into that of a warmed house. Guye mentions the case of a boy, who, after a year at school, had learned only the first three letters of the alphabet. Adenoids were found in this boy's pharyngeal vault and were removed, and in the course of a week after the operation he had mastered the entire alphabet. William Hill, of London, confirms the above statements of Guye from the results of his own observations, and claims to have examined many imbecile children, nearly all of whom he found to be "mouth-breathers, night-snorers, and the victims of some kind of nasal or pharyngeal obstruction."

Another reflex disturbance with which, according to Woods Hutchinson, hypertrophy of the pharyngeal tonsil may be closely associated, is that of acromegaly and giantism. The following quotations are from an article on this subject published by him in *The Medical News* for January 16th, 1897:

[1] "Diseases of the Nose and Throat," by Francke H. Bosworth, p. 550.

[2] Inability to fix the attention upon any definite subject.

[3] British Medical Journal, vol. ii., p. 709.

"One other suggestion of a possible bearing on the problem has been made from a clinical standpoint, and that is whether the extraordinary disturbance of growth and general nutrition in children, associated with adenoids in the vault of the pharynx, 'post-nasal growths,' may not in some way depend upon the fact that this pharyngeal tonsil is, embryonically, simply the lower portion, or stalk, of the pituitary body, from which it has become separated by the ossification of the base of the skull. Not infrequently, in early life, a fibrous cord still runs up through the body of the sphenoid, connecting the two glands, and it is not unreasonable to suppose that structures which were originally continuous may yet retain reflex sympathy with and influence each other's condition. All who have studied this condition are agreed that the obstruction to respiration or other mechanical effects of these growths are [*alone*] utterly inadequate to account for the tremendous disturbance of nutrition, both bodily and mental, associated with their growth and relieved by their removal; their *pituitary reflex* action has been suggested by no less an anatomical authority than Harrison Allen, and indorsed by Osler and Dana. . . . It [the pituitary gland] is now regarded as the remains of, first, the primitive gullet, round which the entire brain was developed; secondly, of a canal which connected the alimentary tube with the central nervous system. . . .

"We venture to tentatively conclude: First, that the pituitary body is still functional. Second, that disturbances of its metabolism are the principal factors in both acromegaly and giantism. Third, that it is not improbable that a similar factor exists in *dwarfism*, *rickets*, and *cretinism*. Fourth, *that a reflex disturbance of its function may possibly underlie the dystrophy accompanying adenoids*."[1] "Fifth, that it would appear to be a sort of 'growth centre' or proportion-regulator of the entire appendicular skeleton."

J. Pierre[2] says that "scrofulous inflammation of the eyes, ears, and naso-pharynx are local diseases depending ordinarily upon another local disease, viz., adenoid vegetations. They are not the result of so-called scrofulous temperament, but of antecedent and primitive marasmic conditions of childhood. The recurrence and persistency of these attacks of otitis, blepharitis, and rhinitis are due to numerous micro-organisms to be found in the crypts of the

[1] Italics mine.—R. L.

[2] "Nature of Scrofulous Diseases of the Eyes, Ears, and Naso-Pharynx"; Thèse de Paris, 1895.

hypertrophied gland. Ablation of the gland is the only treatment, combined with sea air."

H. Beckmann[1] agrees with the above statements. Robertson, Browne, and others have noted the existence of adenoids in cases of inflammation of the lymphatic glands of the neck, and consider it to be due to the absorption of septic matter from this tumor.

Our chief concern, in the present article, is with the hypertrophied pharyngeal tonsil as it affects the aural apparatus. This pathological condition may act first by causing an obstruction of the pharyngeal mouth of the Eustachian tube, and thus preventing it from performing its proper function of draining and ventilating the middle ear. This is much more apt to occur in those cases in which the Eustachian tube is situated high up in the vault of the pharynx. Then, in the second place, the mass of adenoid tissue may furnish a nidus of infection from which the invasion extends up along the mucous membrane of the Eustachian tube or follows the course of the lymphatic current, which flows through the lymphatics from the pituitary membrane to the middle ear. In the third place, the mass may, by pressure upon the pharyngeal veins, induce a local congestion in the middle ear, and, in the course of time, this will be likely to assume a chronic character and to inaugurate those changes—cell-proliferation, new-formation of tissue, etc. —which eventuate in the much-feared sclerosis of the middle ear. I believe also, with Dr. Albert H. Buck, that, through the presence of such a mass of hypertrophied adenoid tissue in the pharyngeal vault, the intralabyrinthine pressure is interfered with; this interference being brought about by the retarded circulation as well in the lymphatic vessels as in those which carry blood. In support of this view I may state that I have observed—in a number of instances of children who were markedly deaf, and from whose pharyngeal vaults I removed hypertrophied adenoid tissue—that a decided but transitory improvement in the hearing takes place shortly after the operation; and the only explanation that I can give for this fact is that the excessive bleeding during the operation materially diminishes—unfortunately, only for a few hours—the intralabyrinthine pressure. To cite one very marked instance, a boy ten years of age was operated upon about three o'clock in the afternoon; at about seven o'clock that evening his aunt, who was the boy's guardian, sat near his bedside, at a distance of about four feet from him, and in an ordinary tone of voice read to him continuously for an hour

[1] *Op. cit.*

He heard everything readily, and was not obliged to ask her to repeat a single sentence. Previously to the operation his aunt had always been obliged, when reading aloud to the boy, to raise her voice to such a pitch that she could read but a short time without becoming very much exhausted; and then besides, she had very often found it necessary to repeat a sentence. On the day following that on which the operation had been performed the boy's hearing was found to have lost some of the acuteness noted above, nor did it ever again reach this same degree of acuteness, although a very gratifying degree of improvement was permanently secured by the operation.

For the purpose of showing to what extent this hypertrophied tonsil exerts a baneful influence upon the organ of hearing, I will give the following statistics. They demonstrate very conclusively that a much larger number of cases of hypertrophied pharyngeal tonsil are to be found among deaf-mutes, or those with partial deafness in one or both ears, than among the apparently healthy. Thus, for example, Meyer[1] examined 2,000 school-children, for the purpose of ascertaining, simply by looking at their faces and hearing them speak, how many of them were suffering from this affection. He found 20 children (1 per cent) in whom he verified the diagnosis by a digital examination. In England he found 13 out of 700, or nearly 2 per cent. Doyer, in Leyden, found these growths in 5 per cent of the children he examined; Schmiegelow, of Copenhagen, in 1886 found among 581 children 29, or 5 per cent, with well-marked hypertrophy, and 75, or 13 per cent, with a moderate hypertrophy (*i.e.*, a total of 104, or 18 per cent). Wroblewski,[2] among 650 apparently healthy individuals, found the growth to be present in 45 of the cases, or in 7 per cent. W. F. Chappell[3] examined 2,000 children; 645 of this number being members of one of New York's public schools, while the remainder were inmates respectively of a juvenile asylum and an orphan asylum of New York. Out of this number he found 60, or 3 per cent, with enlarged pharyngeal tonsils. The above cases were all found among those in apparent good health. The fact that some of them were also more or less deficient in their hearing does not add strength to my argument; it simply emphasizes the comparison

[1] A. H. Buck: "A Manual of Diseases of the Ear," Second Edition, pp. 187 *et seq.*

[2] Revue de Laryngol., 1892.

[3] American Journal of Medical Sciences, Vol. xcvii., p. 48.

which I am endeavoring to make. The following statistics are gathered from among those who were both deaf and dumb or in some way affected in their hearing. Wroblewski,[1] among 160 inmates of a deaf and dumb asylum, found this hypertrophied gland present in 92 of the number, or in 57.5 per cent. Lemcke found adenoids present in 58 per cent of the deaf-mutes whom he examined, and Peisson found them present in 50 per cent of a hundred patients whom he examined in a Parisian asylum. Frankenberger,[2] of Prague, who examined the 158 inmates of the Prague Deaf and Dumb Asylum, found in 94 (59 per cent) well-marked hypertrophy. He was careful to exclude cases in which the hypertrophy was only moderate. On the other hand, among patients not deaf-mutes, but suffering from various diseases of the ear, Halbeis found 53 per cent with hypertrophy of the pharyngeal tonsil, and Meyer 75.8 per cent.

The following facts illustrate still other aspects of the subject under consideration. Dr. Y. Arslau, of Padua, is reported, in *The Journal of Laryngology*, to have found, among 4,080 patients suffering from disease of the throat, nose, or ear, 426 (*i.e.*, 10.44 per cent) with adenoids; and of this number, 251, or 59 per cent, were already the victims of some form of ear disease. Hartmann found 74.8 per cent of his adenoid cases complicated with some affection of the ear. The above statistics, furnished by different observers, show that adenoids are to be found among the children of the population at large in from 1 per cent (Meyer) to 18 per cent (Schmiegelow); among deaf-mutes, in from 50 to 58 per cent; among those suffering from some form of ear disease, in from 53 per cent to 75.8 per cent. On the other hand, those who were afflicted with adenoids also suffered from some form of ear disease in from 59 to 74.8 per cent. In other words, considerably more than half of the adenoid patients also manifested evidences of ear disease. Even assuming that among Schmiegelow's 18 per cent of cases no form of ear disease existed—which is not true—the great difference between these figures and the others showing the large percentage of cases of adenoids associated with aural disease, or of aural disease with adenoids, proves most conclusively the importance of their pathological relationship. These growths, acting as harbingers of disease germs as well as carriers of these germs into the deeper tissues through the lymphatics, must therefore be responsible for a very large proportion of those cases of labyrinthine disease and of

[1] *Op. cit.* [2] Monats. für Ohrenheilk., October, 1896.

middle-ear disease which cause complete or partial deafness. Adenoids should always be looked for where deaf-mutism is hereditary.

The description of symptoms which I have given above applies to the most marked type of cases. There is another type, however, in which, despite the presence of well-marked adenoids, there is an entire absence of any of the characteristic symptoms. In this type, which is observed in robust, well-developed children, the adenoid tumors seem at the time to exert no harmful influence, either upon the ears or upon the general health. Nevertheless, this harmlessness is more apparent than real, for in many of these cases—in exactly what proportion of the entire number, it is not possible to state—there develops insidiously, later in life, a deafness or a distressing tinnitus, which may rightfully be attributed to a low form of inflammation set agoing and perpetuated by the earlier adenoid disease of the pharyngeal vault. Hence, the only safe course is to assume that the presence of such a mass of hypertrophied gland-tissue in the pharyngeal vault is always a source of danger, a something which ought to be removed.

Dr. D. Bryson Delavan[1] says that, as a general rule, these growths do not disappear spontaneously if left to themselves. The hypertrophy, he maintains, may persist for many years and cause serious injury, or the enlarged gland may waste away and give place to an atrophied condition of the pharyngeal mucous membrane.

Dr. Greville MacDonald[2] says that the instinct of nose-breathing is so strong as to overcome the difficulties established by the presence of a serious nasal obstruction. He states further that while buccal respiration is acquired but slowly and with difficulty, many marked cases of adenoids in children under four (infants included) are overlooked because the child breathes through the nose. Consequently absence of buccal respiration is not a trustworthy indication that adenoids are not present.

Diagnosis.—In marked cases the facial expression of the patient is a sufficient basis upon which to found a diagnosis; but nevertheless an opinion should never be given upon such a diagnosis. Either a digital exploration or a rhinoscopic examination should be made. If the patient is sufficiently tractable and possesses a fairly deep throat, it may be possible, by means of the mirror, to obtain a view of the vault of the pharynx and gain positive proof of the

[1] Medical and Surgical Reporter, August 11th, 1894.

[2] Journal of Laryngology, Rhinology, and Otology, vol. xii., p. 306.

presence or absence of this gland. However, this method is not always possible, and in fact is never as reliable as the diagnosis made with the finger. In a normal pharyngeal vault the sensation conveyed to the finger, as it presses against the upper and posterior wall, is that of a smooth, hard, resisting body. When the finger is pressed in an anterior direction it gets the impression of an oval cavity with firm edges and divided into two lateral halves by a thin bony edge—the vomer. Laterally, the finger encounters a semi-elastic, conical elevation with a central depression—the pharyngeal mouth of the Eustachian tube; and behind and a little above this it slips into a depression—the fossa of Rosenmüller—which, in young subjects, barely admits the tip of the finger. On the other hand, when the finger is introduced into the vault of a pharynx in which the third tonsil has become hypertrophied, it encounters a soft, yielding, jelly-like mass, which bleeds easily on pressure and which either extends over only a small portion of the pharyngeal vault, or else entirely fills that cavity. The sensation has been very graphically likened to that which the finger would experience if it were passed over a bunch of earth-worms hanging from the roof of the pharynx.

Mode of Making a Digital Examination of the Pharyngeal Vault.—Before making a digital examination the toilet of the index finger should be carefully attended to, and the examination should be conducted as expeditiously as possible, for the operation is a very unpleasant procedure, which the patient generally resists, unless he or she possesses an unusual degree of self-control. The examination should be conducted as follows: The surgeon, standing on the right of his patient, should pass his left arm across the back of the patient's neck, to aid in steadying the uplifted head and to prevent as much as possible the struggle which is almost sure to occur in children. Then, with a couple of fingers of the left hand, press gently the patient's left cheek in between the jaws of the widely opened mouth; the object of this being to save the examiner's fingers from being bitten, as the patient would be compelled —if he attempted to close his jaws—to first bite his own cheek. As a third step the index finger of the examiner's right hand is to be rapidly introduced into the patient's mouth and up behind the uvula. After it has gained an entrance, the finger should be rapidly swept over the vault, and during this period of a few seconds the surgeon should have no difficulty in ascertaining the amount, consistency, and position of whatever hypertrophied tissue may

be present. It is possible, in certain cases, to see the enlarged Luschka's tonsil through the nares.

There are three pathological conditions which it is possible to mistake for hypertrophy of the pharyngeal tonsil, viz., a retro-pharyngeal abscess, a mucous or fibroid polypus, and a syphilitic gumma. In a retro-pharyngeal abscess the surface would be smooth and symmetrical, and fluctuation would be felt. There would also doubtless be pain and fever, probably with dyspnœa and choking. Furthermore, there would be a rapid onset of the symptoms, and the tumor would be located well down on the posterior wall of the pharynx. Nasal mucous polypi will be found to spring from the nasal cavity, and not from the walls of the vault; and fibroid tumors are very firm, with a smooth surface, and they do not yield under the pressure of the finger as adenoid growths always do. Specific gummata are smooth and hard before they break down, and afterward they are indurated and friable, and besides are very rarely found in this region.

Prognosis.—The prognosis, which has reference to the results of operative interference, is almost uniformly good. The only serious danger which exists is that from hemorrhage, primary or secondary; and this danger is very slight. The cases of this accident of which I can find any record in literature, or which have come to my knowledge through conversations with my fellow-specialists, amount to not over a dozen. I have never myself seen an alarming case of hemorrhage from this operation. Scharffer[1] operated 1,000 times without any severe hemorrhage; and Lange 700 times with only one severe hemorrhage. Hooper, of Boston, reports a fatal case of hemorrhage—in a hæmophilic subject—caused by simple digital exploration.[2] The danger of an acute inflammation of the middle ear following the operation is but slight if proper antiseptic precautions are taken at the time of operation. An acute exacerbation of an otitis media residua chronica is more apt to occur, but it is only of short duration. On the other hand, the progress of many of the acute aural conditions cannot be arrested while the hypertrophied adenoid tissue remains *in situ*.

Danger from any of the exanthemata, through infection of the open wound resulting from the operation, cannot be very grave if the proper steps are taken to prevent needless exposure. I know of but one case of this character, and that is a doubtful one. McBride

[1] Berlin. klin. Wochenschr., July 15th, 1891.

[2] New York Medical Journal, October 12th, 1889.

and Turner report a case of scarlet fever which occurred on the fourth day following that on which the operation was performed. The patient, it is reasonable to suppose, must have been infected already at the time when the operation was performed.

Castex and Malherbe[1] report observations on the growth of children after the removal of adenoids. Measurements were taken before operation and at varying intervals afterward. Thirty-five cases were traced for periods of three, six, nine, and twelve months. The general conclusion which they draw from these observations is that, during some months after the operation, the rate of growth, as estimated by increase of height, weight, and chest measurement, was three times as great as the average rate mentioned in the statistical tables of Quitelet for height and weight, and of Pagliani for chest girth.

Treatment.—As to the treatment of this condition—which, considered in all its aspects, is one of the most important ailments of childhood—there is but one course to pursue, and that is to remove the hypertrophied glandular tissue; and the course here advocated applies as well to adults as to infants; to those individuals who have only a moderate degree of hypertrophy as well as to those in whom the pathological condition is well marked; and finally to those in whom the existence of certain symptoms calls for the operation as a curative measure, as well as to those in whom, by reason of the absence of any such symptoms, the operation is indicated simply as a prophylactic measure. It is erroneous to reason that because a patient has reached the age when an atrophic change has already begun in the gland, it is unnecessary to operate. The pathological conditions induced by the presence of the hypertrophied gland will continue to advance as long as the hypertrophied tissue remains, and even a slight amount of adenoid tissue may take years to atrophy. Dr. D. Bryson Delavan operated with marked benefit upon a patient forty-four years of age.

The use of chemical caustics or electro-cauteries, except in patients with a hemorrhagic tendency or in those who have notably weak constitutions, is not to be recommended as a means of destroying these glandular tumors. It is both a very tedious and a very painful method to pursue. The only conditions which should cause one to hesitate about operating are those which it is feared may exist in cases with a family or personal history of hæmophilia;

[1] Le Bulletin Médical, Paris, March 4th, 1894; British Medical Journal, June 9th, 1894.

those which are apt to exist in persons who have valvular lesions of the heart, and who consequently are less able to bear the shock (slight though it be) which may result from the hemorrhage that follows the removal of the glandular mass; and, finally, those which prevail in a patient affected with syphilis, in whom the wound might degenerate into an active syphilitic ulcer. It is a question whether the operation should be postponed in a subject who has been exposed to the contagion of any of the infectious diseases, or who is actually suffering from an attack of acute tonsillitis. To quote Lennox Browne[1] on this point: "I may also usefully allude to the presence of adenoids not only as a strong predisposing cause of diphtheria and other infectious fevers liable to attack the throat, but also to the beneficial effects of their removal, even in the acute stages of these diseases, as a preferable alternative to a probable tracheotomy or intubation, when the upper air passages are obstructed by their presence." Again, H. Beckman[2] claims to have removed, since 1893, the adenoids in 285 cases of otitis media catarrhalis acuta, with a success which was in no way approached by any other means; and in these cases paracentesis and Politzerization were found to be unnecessary.

The logical deduction from all these facts is that every infant should be examined for this hypertrophic condition of the pharyngeal tonsil, and should be re-examined at least once a year up to its seventh year, whether symptoms dependent upon this condition are present or not. It would be extremely difficult, I admit, to carry out properly a measure of this nature. It would be entirely practicable, of course, to establish the rule that every child, before being admitted to a school, should be subjected to an examination for the purpose of ascertaining whether it had or had not an enlarged pharyngeal tonsil. But it is very doubtful whether it would be possible to enforce the second rule which would follow the first one as a logical sequence, viz., that those children who were found to have adenoids should be excluded until the growths had been removed by operative procedures. Possibly some good might result from the plan of notifying the child's parents that such a growth had been discovered, and that in the child's own interest, as well as in that of its school companions,[3] the hypertrophied gland should be extirpated.

[1] Journal of Laryngology, Rhinology, and Otology, vol. xii., p. 317.

[2] *Op. cit.*

[3] Such a child, as I have already stated, is more liable than is one with

Operation for the Removal of Adenoid Growths from the Pharyngeal Vault.—By way of preparation for the operation the heart, lungs, and kidneys should be carefully examined; loose milk teeth, if present—as in the case of a child—should be extracted; the bowels should be thoroughly opened, and no food should be allowed for five hours previous to the time set for the operation.

The instruments required are the following: two or three adenoid forceps of different sizes, large and small, Gottstein's curettes, a



FIG. 73.—Brandegee's Adenoid Forceps.

Dwyer's mouth-gag, a tongue-depressor, a nasal speculum, a forehead-mirror, a few rhinoscopic mirrors, a post-nasal syringe, an atomizer, a Bellocq's cannula or a male rubber catheter, a hypodermatic syringe (with the necessary heart-stimulants), a couple of sponge-holders, and a laryngeal forceps. Perhaps a tracheotomy set should be added to this list, if the operator wishes to be prepared for every

FIG. 74.—Gottstein's Curette.

possible contingency. As a matter of fact, one seldom needs anything but the mouth-gag, the forceps, the curettes, and the tongue-depressor.

Of the different patterns of adenoid forceps, I prefer Gradle's or Brandegee's (Fig. 73). In the latter instrument the upper and posterior edges of each blade are sharpened, so that when they come together they make a clean cut. The anterior edge of each blade is blunt, and when both blades are closed a space is left between them (anteriorly), of sufficient breadth to prevent any possible wounding

a normal pharynx to contract one of the infectious diseases, and therefore to that extent increases the risk of these diseases being introduced into the little school community of which it is a member.

of the septum. The blades themselves, between the lock and the cutting edges, are so bent outward as to leave an oval space when the instrument is closed; and the presence of this space protects the uvula from all danger of being mutilated during the operation.

Two sizes of Gottstein's curettes will be found sufficient for all our needs.

In the case of an infant we may advantageously substitute a cork, or a portion of a roll of gauze bandage, for Dwyer's mouth-gag.

The laryngeal forceps may be required in the event of a piece of adenoid tissue falling into the larynx, as happened in Helme's case. Such an accident, however, is of very rare occurrence.

The operation should be carried out under strict antiseptic precautions. The patient should be placed, if possible, on a high, narrow table and in the prone position, with his head near the upper and right-hand edges of the table, so that it may be easily depressed backward over the upper edge or turned forward over the side, as the exigencies of the case may demand. I operate in the standing posture, and place myself on the left of the patient as I face him.

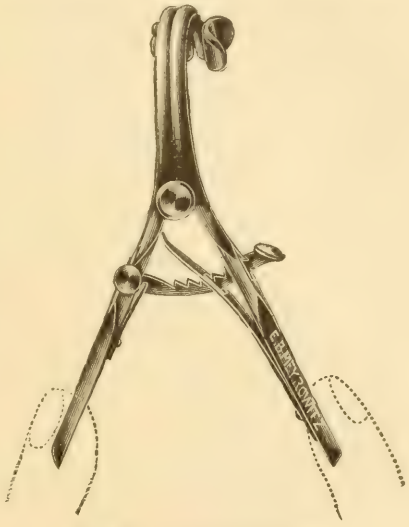

Fig. 75.—Dwyer's Mouth-gag.

An anæsthetic should be used, unless there are some special reasons which render its employment inadvisable or extra-hazardous. The anæsthesia should be complete, and sufficient time should be allowed to remove every vestige of the growth—which, of course, would scarcely be possible without complete anæsthesia. The operation is a very painful one, and therefore, from a humane point of view, an anæsthetic should be administered. An exception may be made to this rule in the case of a patient who has passed beyond his sixteenth year and in whom the growth is small. In such a case cocaine anæsthesia may be used. For this purpose a four-per-cent solution may be sprayed on the parts, or the remedy may be applied

in the form of a powder (composed of milk of sugar and cocaine) which is to be blown upon them through a suitable insufflator.

As to the choice of an anæsthetic, I prefer sulphuric ether, although I have frequently used chloroform in young children. I have had no personal experience with Schleich's mixture, although I have seen Dr. Emil Meyer use it a number of times at the New York Eye and Ear Infirmary, and with satisfactory results. He claims for it no stage of excitement, no asphyxia or cyanosis, no after-vomiting, and a very rapid return to consciousness, *i.e.*, in from three to five minutes. An average of six drachms was used in each case.

Between chloroform and ether the preference should be given, as it seems to me, to ether for the following reasons: first, because it will sustain the heart even when the respiration is temporarily interfered with, as is apt to happen in operations about these parts; second, because hemorrhage is more rapidly arrested, although it may be more marked while the operation is in actual progress; and third, because secondary hemorrhage is not so apt to occur. The unpleasant after-effects of ether narcosis—vomiting, nausea, and headache—are the only drawbacks which are associated with the use of this anæsthetic.

The employment of nitrous ether as an anæsthetic is objectionable because the patient is likely to recover consciousness before the operation—if performed with the desirable degree of thoroughness—is completed.

When the patient has been fully anæsthetized the jaws should be gently forced open and the mouth-gag should be introduced well back in the angle of the left side of the mouth. After the latter has been opened as far as possible, the index finger of the right hand should be inserted for the purpose of mapping out the growth. If the uvula seems likely to get in the way, it is well to introduce the index finger of the left hand and lift it to one side. Generally, however, this is unnecessary. The next step is to introduce the forceps or the curette. I generally prefer to use the forceps first, and especially so if the growth is very large or fibrous. This instrument, with its blades closed, should first be introduced sideways (the handles turned toward the left angle of the mouth). Then it should be turned up behind the velum until the blades occupy a vertical position in the median line, high up in the vault of the pharynx. The blades are next to be opened as widely as possible and pressed upward and backward so as to seize as much of the

hypertrophic tissue as possible. The blades should be closed firmly, and the instrument (with the amputated mass of tissue) should be withdrawn. But, just before withdrawing it, the operator should rotate it first to one side and then to the other, as far as the narrow space will permit, and then should extend it as far upward toward the patient's forehead as he can. The object of this last manipulation is to prevent the tearing off of a strip of mucous membrane from the posterior pharyngeal wall. If these directions are followed closely, there will be no danger of injuring the Eustachian eminences, of bruising the uvula, or of seizing the vomer between the blades of the instrument.

After the forceps has been withdrawn, turn the patient over on his right side or allow the head to hang over the upper edge of the table, so as to prevent the blood from flowing into the larynx. At the same time care should be taken not to extend the head too far back, as by pressure on the veins of the neck it would be an easy matter to increase the amount of the hemorrhage. Without waiting for the latter to diminish, introduce the curette sideways, rotate it, and bring it into the median line, as was done with the forceps. The next step is to force the upper part of the ring forward as far as the vomer will permit; this being accomplished mainly by depressing the handle of the instrument. Then press the ring firmly against the pharyngeal wall (in the median line) and sweep it downward over the mucous membrane in such a manner as to cut away all adenoid tissue well down to the normal plane of the pharyngeal vault.

The curette, as I believe, should be a cutting, and not a tearing instrument. Consequently the curving blade should have a keen edge.

After the curette has been withdrawn the operator should introduce his index finger into the vault in order to ascertain whether any adenoid tissue still remains behind. The fossa of Rosenmüller should be carefully explored, especially in the case of young children; for no instrument can be depended upon to remove all the glandular tissue from this locality. Under these circumstances the surgeon must trust to his finger for the removal of any glandular tissue which may still remain at this point. But if remnants of adenoid tissue are found elsewhere, he should reintroduce the forceps or curette and remove them.

Owing to the fact that the curette cuts the adenoid tissue free, instead of sweeping it forward into the mouth, small portions of it

are occasionally caught between the pharyngeal muscles and forced into the œsophagus during an act of deglutition. This is a harmless accident, for the digestive tract is amply able to take care of these masses of tissue. As a matter of fact, however, they are generally vomited, in the course of a few hours, with the blood, which is swallowed at the same time.

The hemorrhage, immediately after the growths have been excised, is quite brisk for a few moments, but it generally ceases without the necessity of using any means to check it. If it persists, hot water (temp., 103° or 104° F.) may be used with the post-nasal syringe, or an iced antiseptic solution may be injected through the same instrument, or it may be injected, in the form of a spray, through the anterior nares. A four-per-cent. solution of antipyrin is an excellent hæmostatic. It does not often happen that one is compelled to resort to any of these measures, or to pack the vault with gauze; and it is only in rare cases that the necessity for intravenous saline injections arises. Aside from the necessity of employing them for the purpose of arresting a hemorrhage, no sprays or powders or applications of any kind should be used immediately after the operation.

Post-Operative Treatment.—The patient should be placed in bed, and the nurse or the parent should be warned—in order that they may not be unduly alarmed thereby—that one or two attacks of vomiting of coagulated blood are likely to occur. It is a wise plan to have the patient, if it be a child, sleep on its abdomen as much as possible, as in this posture the head will be brought forward, and consequently, if a secondary hemorrhage or a slight oozing of blood occurs, it will easily run out of the nostrils and thus attract early attention. As a precaution against secondary hemorrhage the child should be kept very quiet in bed for at least thirty-six hours, and quiet in the house for from four to five days after the operation. Then for a period of say two weeks it is best to keep the child from school or other assemblage where an unhealed wound might be more than ordinarily exposed to the influence of harmful germs. The diet, during the first two days following the operation, should consist of iced milk and cold bouillon. Then, during the next forty-eight hours, it should be restricted to eggs, custards, cooked fruits, milk, ice cream, and similar cold but easily assimilable preparations. After that, the usual diet may be resumed.

Cod-liver oil and the iodide of iron may be given to advantage in many cases; in others, iron, arsenic, and strychnine will be found

useful. In addition to these direct remedial measures, certain hygienic precautions may be recommended. Such, for example, are the following: a morning cold sponge-bath; careful attention to the temperature of the sleeping and living rooms (65° F. or under for the former, and 70° to 72° F. for the latter); avoidance of too heavy clothing indoors; the wearing of woollen underclothing; the systematic exercising of the muscles (light calisthenics, frequent expansion of the chest); etc.

In those cases in which the enunciation is imperfect, pains should be taken by the parents to gradually overcome this defect by means of systematic exercises in the use of the voice and speech.

III.—HYPERTROPHY OF THE FAUCIAL TONSILS.

The faucial tonsils are situated on either side of the entrance to the pharynx, in the triangular space between the anterior and posterior pillars of the fauces. They are oval in shape, and measure about three-fourths of an inch in their vertical diameter and half an inch in the horizontal; in a normal condition they should not extend beyond the level of the faucial pillars.

The tonsils are essentially large lymphatic glands made up of lymph follicles, mucous glands, and lymph spaces with their blood-vessels and nerves; all bound together by a delicate fibrous tissue, and the whole covered with pavement epithelium. On the surface of the glands are numerous openings, the orifices of the lacunæ or crypts in the substance of the gland. These crypts are involutions of the mucous membrane, and range from twelve to eighteen in number, those of greatest depth being found in the centre of the tonsil.

Hypertrophy of this gland, as I remarked in speaking of hypertrophy of the pharyngeal tonsil, is a disease of childhood, and it is so often preceded and accompanied by hypertrophy of the pharyngeal tonsil that enlargement of the latter would seem to have a causal relation to enlargement of the former. However this may be, the etiological factors which are potent in hypertrophy of the pharyngeal tonsil are equally so in hypertrophy of the faucial tonsils.

The symptoms, which depend largely upon the degree of hypertrophy present, are very similar to those which accompany hypertrophy of the pharyngeal tonsil; the only difference being that they are less marked. In a typical case the patient, especially if a child, is a mouth-breather and manifests the usual signs of insufficient

oxygenation of the blood, viz., pallor of the skin, puny development, etc. The respiration is apt to be noisy; sleep is disturbed with annoying dreams and sometimes with nightmare, caused by sudden attacks of dyspnœa; headache is common; the patient is easily fatigued; the appetite is impaired; the throat is parched and the breath fetid; and the voice is nasal and lacks resonance. A child with enlarged faucial tonsils is more liable than other children to contract infectious diseases and diseases of the respiratory organs. The effect of the hypertrophy upon the organs of hearing is often very pernicious, and is due to the general catarrhal condition of the nasal pharynx by which the affection is accompanied. This catarrhal inflammation almost necessarily involves the Eustachian tube, and from this follows, in due time, a catarrhal inflammation of the middle ear. In the minor degrees of hypertrophy of this tonsil the interference with the ventilation of the middle ear is undoubtedly in some measure due to an interference with the proper action of the muscles which control the mouths of the Eustachian tubes. The harmful effects upon the hearing may also be attributed in part to pressure upon the neighboring blood-vessels, especially the veins; this pressure doubtless interfering with the tympanic and labyrinthine circulation.

Pathologically, the tonsillar enlargement is a true hypertrophy, and it may be either an hypertrophy of its lymphoid elements or one of its fibrous structure. The former is usually encountered in childhood, while the latter is more common in adult life.

The diagnosis is easily made by simple inspection. As regards prognosis, it is not safe to predict that, as the patient grows older, the enlarged glands will be likely to undergo atrophy. Such an atrophy undoubtedly does occur in many cases; but while it is in progress, and before the enlarged glands have undergone a material diminution in size, a great deal of irreparable harm may be done to the physical and mental development of the child. Even in those cases in which the hearing seems at first to have escaped, there may develop, later on in life, a deafness which must be attributed to the earlier inflammatory (hypertrophic) processes in the middle ear—processes which were originated and perpetuated by the presence of the enlarged faucial tonsils. Finally, due weight must be given to the fact that a child with hypertrophied faucial tonsils is more liable to an attack of one or the other of the infectious diseases.

Treatment.—Treatment other than by excision by means of a tonsillotome is tedious and painful, and only too often ineffectual.

In certain cases—as, for example, that of a patient with a hemorrhagic diathesis, or that of an adult with very fibrous tonsils, or, again, that of a person in whom it is impossible to encircle the tonsils with the knife or wire loop, the enlargement being chiefly in an antero-posterior or a vertical diameter—it is probably necessary to resort to such means as the insertion of the electro-cautery point into the substance of the gland, and especially into its crypts. Not more than two or three such applications should be made at each visit, and they should not be repeated oftener than once in eight or ten days, as otherwise there is liability of causing an acute tonsillitis. This operation should be done under cocaine anæsthesia, a spray of a four-per-cent solution generally benumbing the parts to a sufficient degree.

Removal by means of the electro-cautery loop is sometimes resorted to in a case of malignant disease or in one of a hard, fibrous tonsil. The operation is itself not only very painful, but is apt to be followed by an inflammatory action which usually lasts for many days, and is also the cause of much pain. When this method is employed the tonsils should be cut through slowly, the electric current being interrupted frequently. The actual amount of tissue removed does not represent the full benefit of this method of operation, for the parts remaining are cauterized to some depth, and the subsequent cicatrization will cause a further diminution in the size of the glands as healing takes place.

The cold wire écraseur is also used in this class of cases, but, unless the operation is performed with the aid of a general anæsthetic, the pain accompanying it will be found almost unbearable.

Excision of the tonsil by means of one of the various modifications of Physick's tonsillotome, is, on the whole, the most thorough, least painful, and quickest way of removing this gland when hypertrophied. I use Quinlan's modification of this tonsillotome (see Fig. 76). It is a simple instrument of comparatively few parts, is easily cleaned, and is made in such a manner that the surgeon who is not ambidextrous can change it in a few seconds so that it may be used upon either tonsil. Hemorrhage, after the use of this instrument, is not so copious as generally takes place after the use of one of the modifications of Fahnestock's guillotine, which cuts the tonsil through from behind forward. Then, besides, the latter instrument is open to another objection. The harpoon which is a part of the guillotine is very liable to get under the blade of the instrument, causing it to become locked, and necessitating the use of

a scalpel to cut it free—a procedure which, as may be imagined, is most disagreeable to both patient and surgeon. The pain caused by the use of the tonsillotome is very slight, the chief annoyance being due to the placing of the instrument in position. In order to obviate this to some extent, the fauces should be sprayed before the operation with a four-per-cent solution of cocaine. A general anæsthetic is seldom required; but if, as in the case of a nervous or unmanageable child, it should be thought best to administer one,

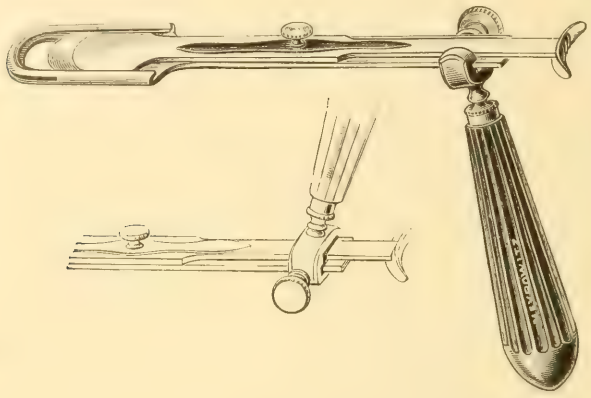

Fig. 76.—Quinlan's Modification of Physick's Tonsillotome.

nitrous oxide will be found to produce sufficient narcosis for the work in hand. A decided objection to the use of a general anæsthetic lies in the fact that the active co-operation of the patient in clearing the throat is not to be had.

Tonsillotomy; Steps of the Operation.—When the surgeon is about to operate, the patient should be placed sitting nearly upright and facing the operator, who, by means of his forehead-mirror, illuminates the seat of operation. An assistant should place two of his fingers under the angle of the patient's jaw, and by pressing upward, inward, and forward should push the tonsil well into the field of operation. The operator then rapidly inserts the tonsillotome into the mouth, encircles the gland, pushes the blade home, and then withdraws the instrument. If the opposite tonsil also requires to be removed, the operator at once makes the requisite changes in the position of the blade, and then proceeds in the same manner as he did in removing the first one. If he happen to be ambidextrous, he simply transfers the tonsillotome from one hand to the other, and then removes the second tonsil without any delay

whatever. Care must always be taken to hold the blade parallel to the median line; otherwise it will be found that only a wedge-shaped slice of the tonsillar tissue is removed, the posterior portion being left *in situ*. The general tendency is to carry the handle of the instrument too close to the angle of the mouth on the side which is to be operated upon, while it ought to be kept on a plane parallel to the median line, or even perhaps carried a little beyond it toward the opposite side. In the case of a small child it may be necessary to have it held by an assistant. This can be best done by seating the patient on the assistant's right side, its legs being grasped between his two thighs. At the same time the child's body and head should be turned to face the operator, while the back of its head should rest against the assistant's chest, where it is held firmly by him with one arm, while the other is thrown across the child's chest. In this way it is possible to thoroughly control the child's arms and body. It is also necessary to have another assistant, whose duty it shall be to force the tonsils into position.

Hemorrhage is sometimes alarming, but as a rule it is very slight. If it should continue for an unduly long time, small pieces of ice may be given to the patient to suck, or a powder consisting of equal parts of tannic and gallic acids may be insufflated upon the cut surface. One or the other of these measures will generally suffice to check the bleeding. In a few cases pressure aided by styptic cotton may be required before the bleeding will cease. In a still smaller number of instances the hemorrhage may become really alarming, and may call for such a radical measure as the application of a ligature to the common or the external carotid artery. A few such cases have been recorded in literature, but in these—it should be noted—the operation was done with a scalpel, and not with the tonsillotome. Syncope usually puts an end to the alarming hemorrhage.

After the operation the patient should be placed upon a diet of cold liquid or semi-solid food for a period of three or four days, and special care should be taken to prevent the eating of anything like bread, with its hard crumbs, or oatmeal in which the husks are present, for these might lodge in the tonsillar tissues and give rise to a hemorrhage or an abscess. It is better for the patient to remain indoors for a few days following the operation. Attention to the general health, including suitable calisthenic exercises, is the only after-treatment required.

IV.—HYPERTROPHY OF THE NASAL MUCOUS MEMBRANE.

The nasal mucous membrane is a very vascular structure, and very prone to inflammatory attacks from such exciting influences as changes in temperature and in humidity and the inhalation of irritating substances. It is also prone to participate in acute inflammations of the pharyngeal tonsil. These acute attacks may last a few days or several weeks, and while they last the patient is troubled with all the symptoms that accompany difficult breathing and increased nasal secretion. Repeated attacks of such an inflammatory character usually lead to pathological changes in the nasal mucous membrane, especially that covering the inferior and middle turbinated bodies. Under the influence of these attacks the blood-vessels gradually lose their elasticity, and soon become permanently dilated; the glandular and connective-tissue elements become thickened through the formation of new tissue; and so, in the course of time, a genuine and permanent hypertrophy is developed. The engorged tissues obstruct the nasal passages, and this state of affairs produces the train of symptoms which we found in hypertrophy of both the faucial and the pharyngeal tonsils, and which are to be attributed to imperfect nasal respiration. Patients affected with these nasal lesions also suffer from insufficient oxygenation: they are often anæmic and insufficiently nourished; their sleep is disturbed; they suffer from headaches, restlessness, and general lassitude; the voice is nasal; the sense of smell is interfered with or lost; and the hearing is notably diminished, and at times there may be a distressing tinnitus. The nasal hypertrophy prevents a sufficient amount of air from entering the pharynx, and consequently, with every act of swallowing, rarefaction of the air in the Eustachian tube results, in the manner already described by Dr. Buck on page 233. Under these circumstances, the atmospheric pressure upon the outer surface of the membrana tympani will exceed that upon its inner surface, and will therefore tend to force the membrane abnormally far inward; and besides, the bloodvessels of the tympanic mucous membrane will undergo dilatation. Then again, hypertrophy of the turbinated bodies acts injuriously upon the organ of hearing in another manner: the engorgement of these bodies causes a damming up of the blood in the large sinuses at the base of the brain, and this latter condition, in turn, obstructs the escape of venous blood from the labyrinth, and consequently causes increased labyrinthine pressure.

Diagnosis.—A diagnosis is readily made by inspection. Upon the introduction of the nasal speculum one or both of the turbinated bodies will be seen to obstruct the view along the nasal passages. These bodies will be red and inflamed in appearance, and on examination with a probe they will be found to be flabby and dependent from the bony framework. The hypertrophy is generally more marked at the anterior and posterior extremities of the turbinated bodies. As seen with the rhinoscopic mirror the posterior hypertrophied extremity of a turbinated body presents a reddish-gray or, in advanced cases, a gray color, and is frequently mammillated in character. Marked hypertrophy is, in the majority of cases, found to be associated with a deviated nasal septum, and the hypertrophy is on the side on which the concavity of the septum exists. To ascertain to what extent true hypertrophy exists, and how much of the swelling may be due to simple engorgement, a four-per-cent solution of cocaine should be thrown into the nares by means of the spray apparatus. The cocaine, in the course of a few minutes, causes the blood-vessels to contract; whereupon the tissues present an exsanguinated appearance. If any swelling still remains after an effective application of the cocaine has been made, this may safely be attributed to hypertrophy of the connective-tissue elements. By means of pressure with a fairly stiff probe we may still further establish the correctness of our diagnosis.

Chronic pharyngitis is usually an accompaniment of hypertrophic rhinitis—the term by which the condition last described is commonly designated.

Treatment.—The patient should be given for home use a cleansing wash, which is to be used with an atomizer. (Douching, syringing, or the snuffing up of solutions into the nasal passages is fraught with danger to the ears and should never be used.) Of the cleansing solutions I like nothing better than a proprietary article called Borolyptol, which contains five per cent of aceto-boro-glyceride and two-tenths per cent of formaldehyde, together with eucalyptol, benzoin, and oleum pini pumilionis in small quantities. Of this I use one part to four parts of water, and to this solution I sometimes add, when the mucus is very thick and hard to remove, about twenty grains each of sodium benzoate and sodium biborate. This mixture is to be used three or more times a day, in the form of a spray. I am also in the habit of prescribing the following mild stimulating and protective solution:

℞ Menthol, . . . gr. ij. to vi.
Ol. pini pumilionis, . ʒ i. to ʒ ij.
Benzoinol, . . ʒ i.
M. To be atomized in the nares immediately after the use of the cleansing solution.

When the patients visit me at my office I first thoroughly cleanse the nasal cavities with pledgets of cotton and spray solutions, and then, by means of a mop of cotton, wound around the end of a cotton-carrier, I apply some of the following mixture to the walls of the nasal passage:

℞ Iodi, ... gr. xvi.
Potass. iod., ... gr. xlviij.
Glycerinæ, ... ʒ i.
M.

At the same time I make an application of a solution of nitrate of silver (strength, from 10 to 30 grains of the silver to one ounce of distilled water) to the vault of the pharynx. In certain cases, however, I obtain better results from the use of the following solution:

℞ Iodi, ... gr. v. to x.
Potass. iod., ... gr. x. to xx.
Zinci iod., ... gr. xx. to xl.
Zinci sulpho-carbol., . . . gr. x. to xx.
Glycerinæ, ... ʒ iss.
Aquæ, ... q.s. ad ʒ iij.
M.

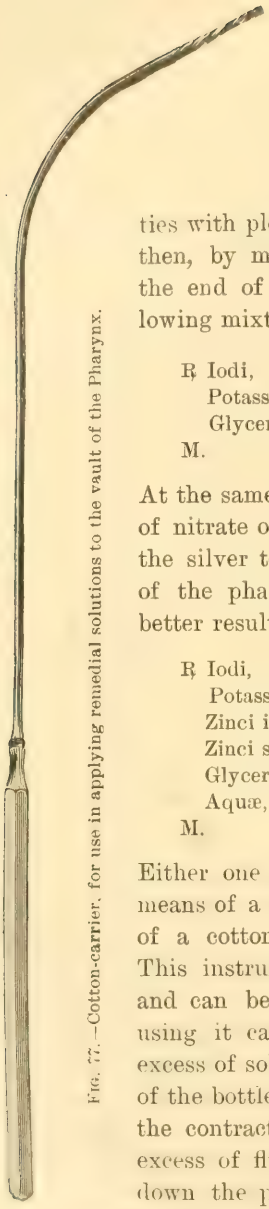

Fig. 77.—Cotton-carrier, for use in applying remedial solutions to the vault of the Pharynx.

Either one of these solutions can be best applied by means of a pledget of cotton twisted around the end of a cotton-carrier like the one shown in Fig. 77. This instrument is made of copper (nickel-plated), and can be easily bent to any desired shape. In using it care must be always taken to press off the excess of solution against the inner surface of the neck of the bottle; otherwise, when the application is made, the contraction of the muscles will squeeze out the excess of fluid in the mop, and it may then trickle down the pharynx, or even drop into the larynx, and cause much unpleasant strangling and irritation. Before making the application, have the patient inhale deeply, and then pass the cotton-tipped carrier up behind the soft palate to the vault of

the pharynx. If these two precautions are adopted our patients will be spared much annoyance.

The remedies mentioned above are only of service in the milder types of cases; in the more marked ones we shall be obliged to resort to cauterizing agents. Of these, chromic acid is the best chemical agent, its area of destruction being fairly limited to the point of application. I prefer, however, to use the electro-cautery point. This may be used in connection with a storage battery; but if one has the electric current in his office, the device illustrated and described on page 249 can be used. It possesses the advantage of being ready for service at all times. Before the cautery is applied to the parts which require to be cauterized, these should be thoroughly cocainized. The easiest way to accomplish this is to wrap a pledget of cotton around a Goodwillie's plug-placer (Fig. 78) and

FIG. 78.—Goodwillie's Plug-placer.

then to introduce it—after thoroughly saturating it with a cocaine solution—into the nasal passage up to the point where it will lie in contact with the hypertrophied parts. Then, by means of the slide, hold the saturated cotton in position while the instrument is being withdrawn. After the parts have been thoroughly cocainized, dry the tissues, then insert the cautery point—having ascertained beforehand, by testing, that it will heat to the proper degree, namely, a cherry-red color,—turn the electricity on, and, with a slight moving action (to prevent adhesion), apply the point to the tissues to be cauterized. It is also well, if the hypertrophic tissues are freely movable upon their bony support, to run a blunt, needle-like cautery point through this tissue down to the bone. The resulting cicatrix will act as a band to keep the tissues in closer contact with the bone. As a matter of course, these punctures should not be made close together, for if this should be done there would be danger of destroying the function of the mucous membrane. Sometimes it is impossible to reach the posterior hypertrophy through the nares. In such a case it becomes necessary to use the rhinoscopic mirror. With its aid it is possible to insert a properly curved cautery behind the uvula into the posterior nares, by way of the pharyngeal vault. This procedure, with some patients, is a very difficult one, and it may be found necessary, before it can be accomplished, to first educate the patient to tolerate the instrument. In pendulous hy-

pertrophies which are to be found at the posterior ends of the turbinated bodies, it is a much better surgical procedure to remove them by means of a snare or cold wire écraseur. There are many forms of these snares. I have found Wright's snare (Fig. 79) a very convenient and reliable instrument. Piano wire (No. 3 or No. 4), which is very elastic and strong, is used with it. With

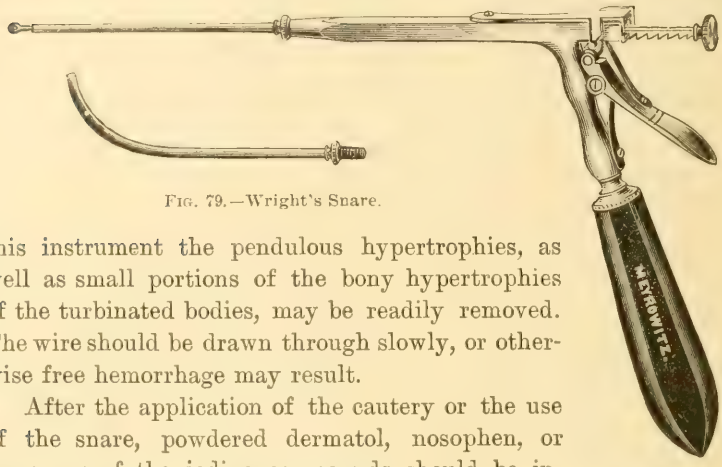

Fig. 79.—Wright's Snare.

this instrument the pendulous hypertrophies, as well as small portions of the bony hypertrophies of the turbinated bodies, may be readily removed. The wire should be drawn through slowly, or otherwise free hemorrhage may result.

After the application of the cautery or the use of the snare, powdered dermatol, nosophen, or some one of the iodine compounds should be insufflated into the nares, to act as an antiseptic protection. I generally give my patients a little device consisting of a piece of rubber tubing into both ends of which a quill toothpick is inserted. By dipping one of the quill ends into one or other of these powders and then inserting it a short distance into the nasal cavity, while the other end is placed between his lips, the patient, with a quick, expulsive breath, will be able to blow the powder into the nares. I instruct my patients to use this several times a day, especially after blowing the nose.

The parts heal quickly, as a rule, and there is very little reaction.

V.—DEFORMITIES OF THE NASAL SEPTUM.

Deformities of the nasal septum are very common. Dr. D. Bryson Delavan[1] collected the figures of six observers (who had examined dried specimens), and in a total of 3,446 cases he found 2,095, or about 60 per cent, in which there was a deviation of the septum.

[1] "Reference Handbook of the Medical Sciences," vol. v., p. 211.

In his own observations of 700 skulls he found only 19.2 per cent with deviations of the septum, but he did not record any in which "the deflection did not amount to an absolute obstructive deformity."

The deviation may occur in the cartilaginous or in the bony portion of the septum, or the entire septum may be involved. The deformity may be an angular one, or, as in some cases, most irregular in character, with a curve in both the vertical and the horizontal planes (sigmoid deflection). Associated with deviation of the septum we very often have longitudinal ridges which are produced by marked thickening of the septum at the point of greatest deformity; or, instead of a ridge, we may find a spur (an irregularly or pyramidal shaped hyperostosis). We also find occasionally associated with these deviations synechiæ existing between the septum and the turbinated bodies, and these may be either membranous or osseous in character. Associated with deviations of the septum we generally have marked hypertrophy of the turbinated bodies on the side of the greatest concavity of the septum; and, as a result of this, both nasal passages are often found obstructed. Here again it will be observed that the general health suffers from the lack of an adequate supply of oxygen, and the hearing apparatus is likely to show the harmful effects of the pathological conditions in the nose —as already explained in the earlier part of this chapter.

Treatment.—The treatment of these cases depends very much upon the nature and extent of the deformity. If the deformity is

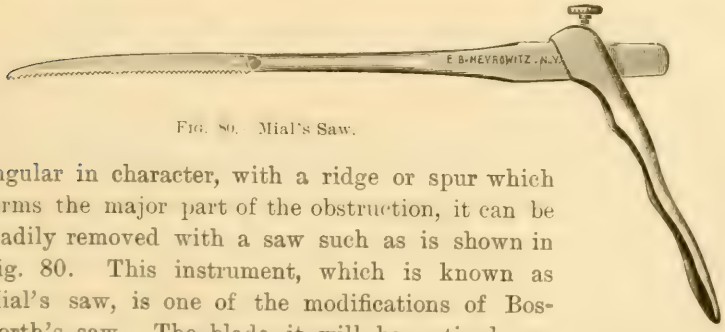

Fig. 80. Mial's Saw.

angular in character, with a ridge or spur which forms the major part of the obstruction, it can be readily removed with a saw such as is shown in Fig. 80. This instrument, which is known as Mial's saw, is one of the modifications of Bosworth's saw. The blade, it will be noticed, can be readily reversed, so as to cut upward or downward. In some of these cases the saw may not be applicable, and it may be found that the trephine or burr, run by an electric motor, will more readily remove the obstruction. In other cases we may prefer to use a gouge-shaped osteotome. Still another in-

strument, which may be used for the same purpose, is the cutting forceps, of which there are various modifications. One of these is Fraenkel's cutting forceps (Fig. 81), which is made in pairs—right

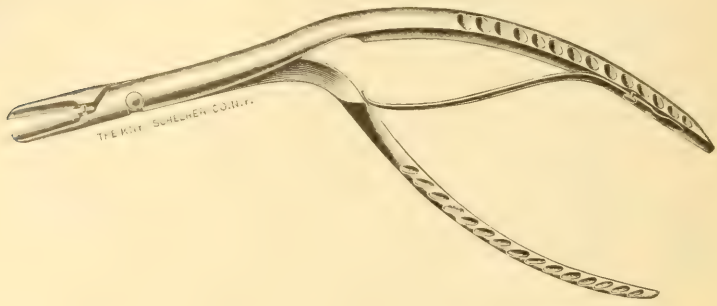

Fig. 81.—Fraenkel's Cutting Forceps.

and left. This instrument will be found to be very useful for the removal of cartilaginous ridges or projections; and the cautery may with advantage be called into service to cut down some of these small projections, and for trimming the edges which may have been left after some other instrument has been used. Each case will demand its own solution and every operator will have his preferences.

For the correction of a deflected cartilaginous septum, Dr. Morris J. Asch, of this city, has devised a set of instruments which



a

b

Fig. 82.—Asch's Nasal Gouge (*a*) and Blunt-pointed Elevator (*b*).

render the operation a comparatively easy task and one which is productive of satisfactory and permanent results. While most operations upon the nasal septum can be performed under cocaine anæsthesia, this one is so painful as to require the employment of a general anæsthetic.

For this operation the patient should lie upon his back with his head over the upper edge of the operating-table, so that the blood

may freely escape through the nose. When complete anæsthesia has been secured the operator should introduce his little finger into the nostril and should locate the point of greatest convexity. Then the blunt elevator (Fig. 82, *b*) is to be introduced for the purpose of ascertaining if there are any adhesions between the septum and the lateral nasal wall. If any are found they are to be broken up with either this instrument or the gouge (Fig. 82, *a*). As soon as this has been accomplished the surgeon should next introduce either one of Asch's scissors (Fig. 83), giving the preference to

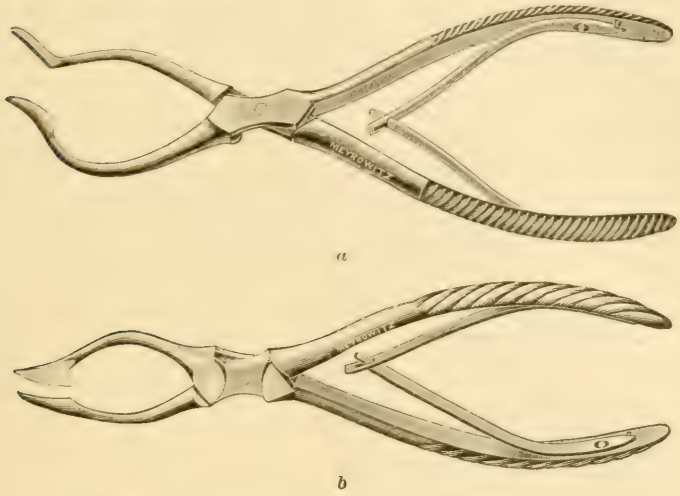

a

b

FIG. 83.—Asch's Scissors; two different patterns (*a* and *b*).

whichever of the two patterns seems best suited to the particular case in hand, and inserting the concave or blunt blade into the stenosed nostril, while the cutting blade must enter the other nostril. The scissors having been carefully applied over the point of greatest convexity, the blades are brought together and the septum is cut through. The line of this first incision should be, as nearly as possible, parallel with the floor of the nasal fossa. Then the instrument should be turned, and a second incision should be made at right angles to and crossing the first. Upon the withdrawal of the scissors the operator should again introduce his finger and force the septum over to the free or concave side, and then Adams' septal forceps (Fig. 84) should be introduced for the purpose of still further restoring the septum to its correct position. The four sections resulting from the crucial incision made with the scissors

are to be forced, by means of Adams' forceps, over toward the non-stenosed side, and this forcing process is to be discontinued only when the resiliency of the cartilage has been entirely overcome, even if it should become necessary—for the accomplishment of this end—to loosen the cartilage from its articulation. If the resiliency



Fig. 84.—Adams' Septal Forceps.

is not overcome, the operation will probably prove unsuccessful. The bleeding is quite profuse, but, as the patient's head is depressed, there is no danger of asphyxiation.

The next step in the operation is to provide some sort of splint which can maintain the septum in its corrected position until firm

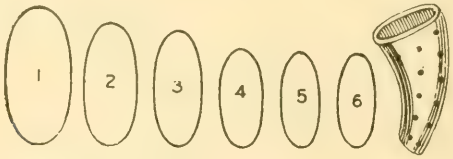

Fig. 85.—Asch's Vulcanized Rubber Nasal Tubes.

healing shall have taken place. For this purpose a perforated vulcanized rubber tube of the proper size—either Asch's (Fig. 85) or Meyer's (Fig. 86)—should be introduced into the nostril in which the stenosis existed, and another but smaller one should be placed

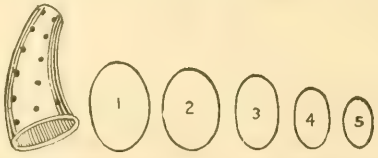

Fig. 86.—Meyer's Vulcanized Rubber Nasal Tubes.

in the opposite nostril. These generally stop the bleeding; but if they fail to do so, an iced Dobell's solution may be sprayed into the nostril, and this will be found to effectually stop all hemorrhage.

After the operation the patient is to be placed in bed, and he should remain there for from twenty-four to thirty-six hours. Ice compresses are to be kept applied to the nose, and the mucous surfaces are to be sprayed with an iced boric-acid solution every few hours during the next twenty-four. At the end of this time the tubes should be removed and cleaned, the nostrils cleansed, and the tubes reintroduced. The same steps should be repeated at the end of the following twenty-four hours, when the tube on the non-stenosed side may be left out altogether. At this stage it is well to instruct the patient how to remove and reintroduce the tube; for this instrument should be cleansed morning and night. He should visit the surgeon's office every other day for the first few weeks. During the second and subsequent weeks I am in the habit of dusting the parts—after the nasal passages have been thoroughly cleansed—with a small quantity of nosophen or dermatol. The tube in the formerly stenosed side should be left in for a period of from four to five weeks. The wearing of this tube is, of course, very annoying during the first days, but after a time the patient becomes somewhat accustomed to its presence, and bears the burden during the allotted period of one month. This sacrifice is well worth making when one takes into consideration the future years of relief from distressing symptoms that the operation will afford. In the course of a few months it may be necessary to trim down, with the scissors or the electro-cautery, a little of the thickening that sometimes remains.

In this chapter I have only covered, in a very cursory manner, the principal lesions of the nose and nasal pharynx that are the primary causes of so many of the disturbances of the middle ear which come under the aurist's observation. It would scarcely be possible, as everybody will understand, to treat the subject in any more thorough fashion within the limits of a single chapter.

CHAPTER XIV.

ACUTE SUPPURATIVE INFLAMMATIONS OF THE MIDDLE EAR.

GENERAL REMARKS.

A SUPPURATIVE inflammation of the middle ear is one in which, at a comparatively early stage of the disease, the free exudation assumes a purulent character. At the onset of the attack the mucous membrane of the Eustachian tube and tympanic cavity becomes first hyperæmic and afterward œdematous. Then a serous or a sanguineo-serous fluid is poured out into the tympanum; and, finally, this assumes all the outward characteristics of pus. In a few exceptional cases this purulent fluid will find a sufficient outlet for itself along the channel of the Eustachian tube; but in the great majority of instances the latter passageway becomes closed almost at the very beginning of the attack, and then the exudation, under an ever-increasing pressure, forces an outlet for itself directly through the tissues of the membrana tympani. The subsequent history of the disease—both when the outlet is formed in this spontaneous manner and when it is established artificially by the surgeon's knife—is determined by a variety of circumstances, some of which are fixed (individual anatomical peculiarities) while others are of a purely accidental character (the special variety of micro-organism which has given rise to the suppurative inflammation; the patient's general condition of health at the time; the favorable or unfavorable character of his surroundings, etc.).

Influence of Anatomical Peculiarities.—When Nature, in any given case, provides easy pathways along which the inflammation (that is, the pyogenic micro-organisms) can travel from the tympanic cavity to various remote parts of the temporal bone, we shall not be surprised if the very first attack of acute middle-ear disease which that individual experiences should prove to be a particularly serious one. The following anatomical conditions may be considered as furnishing the easy pathways to which I have referred: free communication between the tympanum and the antrum, as well as

between the latter and the surrounding system of air-containing cells; unusually large and unusually numerous pneumatic cells; unusually numerous anastomoses between the blood-vessels of the vault of the tympanum and those of the cranial cavity; and perhaps even the absence, over a small area, of the lamina of bone which separates the dura mater from the tympanic mucous membrane. All these are anatomical conditions which render it easy for the pathological germs to reach outlying regions, and to establish new and perhaps more serious foci of inflammatory action. In still other cases the peculiar behavior of the disease—I refer here more particularly to the persistence of pain after a large opening has been made in the tympanic membrane—warrants us in drawing the conclusion that the entrance into the antrum from the tympanum is abnormally narrow;—not so narrow as to interfere with the travelling of micro-organisms from the latter into the former cavity, but yet so narrow that it may easily become closed by the mucous membrane which lines it, whenever the latter swells up under the irritation supplied by the invading bacteria. A similar narrowing of some or all of the passages leading from the antrum into the pneumatic cells is the only other condition, as it seems to me, which is competent to explain the peculiar behavior to which I have just referred.

Influence of Bacterial Organisms and Other Factors.—I can add here very little to what I have already said in the early part of Chapter X. in regard to the part played by micro-organisms in exciting a suppurative inflammation of the middle ear. The evidence thus far collected shows very clearly that the infection may be either pure or mixed in character; or, in other words, that several varieties of bacterial organisms may take part in the invasion, or that it may be confined strictly to only one variety. It is reasonable to suppose that when the infection is of a mixed character the several varieties of micro-organisms are present in different proportions in different cases, and that to this fact we must in large measure attribute the varying degrees of severity manifested by these cases. But we are not yet able to grade the different varieties of bacteria according to their power to interfere with the life of the tissues. At most, we can assign to the streptococcus the rôle of possessing the greatest power to injure them.

It is a fairly well-established fact that these organisms possess their maximum power of doing harm when the tissues which they invade are under an abnormal degree of pressure—one which must

necessarily retard, if it does not arrest, the circulation of the part. This circumstance suggests the idea that an active circulation of blood affords great protection to tissues which have been invaded by these micro-organisms. It also explains the success which often follows paracentesis of the membrana tympani—an operation which, if properly performed, puts an end to the increased intratympanic pressure, and so permits the blood to again circulate freely. But if the entrance to the antrum happens at this time to be blocked—or if the entrances from the antrum into individual mastoid cells happen to be blocked—the paracentesis of the tympanic membrane will not put an end to any increased pressure which may exist in these more remotely situated cavities, and thus the bacteria are permitted to continue their harmful work in these particular regions.

Occasionally a case is encountered in which the disease seems to advance by regular stages up to a certain point, and then to quiet down spontaneously; not altogether to a normal condition, but yet to one which gives no cause for any anxiety. Then the local conditions remain apparently unchanged for days or weeks together, growing neither worse nor better. Finally, operative interference reveals the existence of a limited amount of purulent fluid and some pale granulation-tissue in a few of the pneumatic spaces; all active inflammation having apparently come to an end. The most natural explanation of conditions like these is the one which assumes that, in the course of the disease, there arrived a time when the micro-organisms died, either from lack of adequate nutritive material (certain anatomical obstacles having prevented their further advance into new territory) or from poisoning (by some kind of protective serum provided by the tissues or by the blood).

Last of all, there are those rare cases in which both the soft and the bony tissues in the vicinity of the tympanum are extensively invaded and destroyed, in a comparatively short period of time, with little or no accompanying pain. A personal idiosyncrasy in regard to impressions which ordinarily produce the sensation of pain might be assumed in explanation of these rare cases; but it seems to me more natural to assume that we are dealing here with some special variety of streptococcus—one that has the power of creating a substance (a ptomaïne) which possesses anæsthetizing properties.

We do not need to dwell here upon the injurious effects which a run-down state of health or insalubrious surroundings may exert upon the course of an acute suppurative inflammation of the middle

ear. Influences of this nature seem to diminish the patient's power of resistance, and thus indirectly to aggravate the severity of the attack.

CLASSIFICATION.

The subject of suppurative inflammation of the middle ear may be treated most conveniently under the three heads: 1, Acute Suppurative Inflammation; 2, Chronic Suppurative Inflammation; and 3, Mastoid and Other Complications.

ACUTE SUPPURATIVE INFLAMMATION OF THE MIDDLE EAR.

An acute inflammation develops in the middle ear under a variety of circumstances. For example, it is of frequent occurrence in connection with the exanthematous fevers (measles and scarlet fever). It is not a rare complication in nasal and pharyngeal diphtheria, in small-pox, in epidemic cerebro-spinal meningitis, in typhoid fever, and in the grippe or epidemic influenza. The so-called "cold in the head" is now and then followed by an acute suppurative inflammation of the middle ear, and bathing in salt water sometimes leads to the same result. The different methods of flooding the nasal passages with remedial solutions or even with simple water are all liable to produce such an acute otitis media. Among the rarer causes I may mention heat-prostration and the introduction of the vapor of chloroform and ether into the middle ear by means of the Eustachian catheter.[1] While it is held by some authorities that it is not an unusual thing for a diffuse inflammation of the external auditory canal to spread to the middle ear, I am confident that this event happens only in those rare cases in which a gouty inflammation first attacks the skin of the meatus and then gradually involves the neighboring bony and soft tissues of the mastoid process and tympanic cavity. On the other hand, it very often happens that a diffuse inflammation of the inner half of the auditory meatus involves at the same time the entire dermoid surface of the tympanic membrane. It is highly probable that it is the observation of this latter fact which has led to the supposition that the tympanic cavity was also involved at the same time. That such a supposition, however, is incorrect, is shown by the absence of tinnitus, of pain, and of any but the most trifling interference with the hearing.

In young children, and sometimes also in adults, the presence

[1] Such a case is reported by Dr. Cornwell, of Youngstown, Ohio, in the Transactions for November, 1879.

of hypertrophied lymphoid tissue in the vault of the pharynx predisposes them in a decided manner to attacks of acute suppurative inflammation of the middle ear. In such individuals the simplest "cold in the head" is likely to be followed by a severe inflammation of this nature; and if they happen to contract scarlet fever or measles, a middle-ear inflammation may be anticipated as something almost certain to take place.

SYMPTOMATOLOGY AND COURSE OF THE DISEASE.

The development of pain in the ear is the most striking, if not the first symptom noticed by the patient. In infants, and even sometimes in children two or three years of age, the physician is often puzzled to know what ails the child; and the first hint that he receives with regard to the real cause of the patient's fretfulness and feverish condition is that afforded by the appearance of a slight discharge at the outer orifice of the ear. Teething is very apt to be assumed as the cause of the fever, and thus many a case of severe inflammation of the middle ear is allowed to run its destructive course unrecognized, and consequently unchecked. Then again, in certain cases, the disease may gain considerable headway through another cause. There is a widespread belief in the public mind that an "earache" is something which is quite harmless and entirely different from a genuine inflammation of the ear. This belief is favored by the well-recognized fact that the great majority of earaches spontaneously subside without inflicting any harm either upon the ear or upon the general health of the individual so affected. It is therefore easy to understand how several days may elapse before the parents deem it necessary to seek professional aid.

Upon the development of a perforation, the patient often experiences marked and speedy relief. "I felt something give way in the ear, a watery discharge appeared, and the pain soon subsided," is a statement which one often hears patients make. In many cases, however, the rupture of the membrane affords little or no relief. This is probably due, in many instances, to the insufficient size of the outlet. As the pus can only escape under considerable pressure, when the perforation is small, the tension, which is the chief cause of the pain, continues, and the patient of course experiences little or no relief from his suffering. Among the symptoms of minor importance may be mentioned: a sensation of fulness and sometimes of throbbing or pulsation in the affected ear; subjective sounds of various kinds, such as roaring, singing, whistling, etc.;

more or less marked impairment of hearing in the affected ear; increased pain when the jaws are opened and shut; tenderness on pressure over the orifice of the external auditory canal, etc. The two last-named symptoms indicate that the inflammation has spread from the middle ear to the outer meatus. All these symptoms may then gradually subside, and in the course of ten days or two weeks from the onset of the disease the patient may be quite well again and free from all symptoms referable to the ear. Such an attack, in the course of which no alarming symptoms manifest themselves, may be designated as one of moderate or average severity.

The following case affords a good illustration of the course pursued by a simple, uncomplicated attack of acute otitis media purulenta:

CASE XLI.—*Acute inflammation of the middle ear, with slight involvement of the pneumatic cells of the mastoid process; prompt and permanent relief of the pain afforded by a free incision of the tympanic membrane.*

The patient, a boy four years of age, began to complain of pain in the right ear early in the afternoon of May 30th, 1877. He seemed unnaturally languid, and manifested no desire to take part in the other children's play. In the course of two or three hours the pain disappeared. During the night he awoke several times, and each time complained of his ear.

May 31st.—Frequent paroxysms of pain, of short duration. Membrana tympani red and swollen; near its posterior border, low down, the dermoid layer is raised into a well-marked bleb by an effusion of serum between it and the deeper layers of the membrane.

June 1st.—The child slept well last night, after taking two drops of Magendie's solution of morphine. A few paroxysms of pain during the day.

June 2d.—Patient slept well last night without morphine. Makes no complaint of pain in the ear, and there is no appreciable heat of skin nor any acceleration of the pulse; yet the child refuses food, and looks pale and languid. Early in the afternoon the ear became quite painful, but in the course of two or three hours the pain disappeared again.

June 3d.—Patient awoke this morning with a sharp earache. Pressure both in front of and behind the ear causes pain. The posterior half of the membrana tympani is now (10 A.M.) markedly bulging and of a diffusely red color. I incised it freely, and gave exit to a blood-stained serum. In less than ten minutes the child fell asleep and slept soundly until 4 P.M. While he was asleep the discharge from the ear—a pinkish serum—was constant and very abundant. At five o'clock he took food, for the first time in several days, with apparent appetite. The ear, he says, is entirely free from pain.

June 4th.—The discharge is growing thicker and more like ordinary pus. No return of pain. Appetite good. Expression of countenance has entirely changed.

June 8th.—Discharge has ceased. Drum-membrane has almost resumed its natural appearance. The boy seems to be perfectly well again.

Comments.—The prompt recovery in this case may be attributed to these facts: the boy's health, at the time of the attack, was excellent; his surroundings—from a sanitary point of view—were all that could be desired; and, finally, he possessed the vigorous recuperative powers that belong to youth. In contrast with this case stands the following one:

CASE XLII.—*Acute suppurative inflammation of the middle ear following the snuffing of salt water into the nasal passages; recovery delayed by the patient's gouty condition; final healing occurred after he had taken a pleasure trip to Florida.*

The patient, a gentleman, forty-two years of age, and presenting the appearance of only fair general health, consulted me on the 1st of February, 1880. He said that for years he had been affected with an annoying nasopharyngeal catarrh, for the relief of which he had tried various plans of treatment, but with only temporary benefit. Quite recently he had been in the habit of snuffing a warm solution of salt into the throat by way of the nasal passages, and he believed that this measure had afforded him some relief. On that very morning, however, he had begun to experience a sensation of fulness in the right ear, and, as he had passed through several attacks of acute inflammation of the ear, he felt anxious lest this might prove to be the beginning of a fresh attack. I examined the right ear and found the membrana tympani slightly congested at the periphery, especially superiorly and along the handle of the hammer. Watch heard at a distance of eight or ten inches. An examination of his throat showed that the mucous membrane in the vicinity of the vault was red, dry, and swollen, and covered with tough mucus, of a dirty-yellow color. I advised him to send for leeches and a Clarke's douche if actual pain should come on later.

On February 2d I visited the patient at his house. He reported that soon after he returned home from my office the pain in the ear became quite severe, and continued throughout nearly the entire night. Toward morning he heard moist sounds in the ear, and at 6 A. M. he experienced simultaneously a sensation of relief from pain and a profuse outpouring of bloody serum from the ear. At 11 A. M., when I visited him, I found the pillow, nightgown, handkerchief, and numerous pieces of cotton-wool fairly soaked with the discharge. The pain had disappeared completely. The inner end of the canal was so swollen that I could only make out the existence of a central perforation. The swollen parts were gorged with blood and looked purple. During the remainder of that day the discharge continued to be very profuse, and still presented the appearance of bloody serum.

The following day (February 3d) the discharge steadily diminished and began to grow more yellowish. On examination with the speculum I found the perforation to be a little larger than the head of a pin of average size. The swollen walls of the canal had lost their purplish hue, and were simply pink, and less swollen.

From this time forward, for a period of about two weeks, little or no change took place in the condition of the ear. The discharge, which was only moderate in quantity, never became thick like pus, nor did it assume

any of the characteristics of mucus; it remained thin and very yellow, or at times yellowish green. Powdered iodoform, powdered burned alum, and solutions of nitrate of silver of different strengths, all failed to exert any very marked effect upon the discharge. Nor did the applications of a silver-nitrate solution, which I made several times to the vault of the pharynx, seem to accomplish much. I therefore, as a last resort, advised the patient to visit Florida and remain there for one, two, or three weeks, according to the effects produced upon the ear. This advice was followed, and the change of climate, scene, and diet accomplished what local treatment had failed to do. When the patient returned, after an absence of a little over three weeks, I found the drum-membrane healed, and the adjacent canal only a very little swollen. The discharge had ceased already several days previously.

Comments.—It is such an unusual thing to find the membranous portion of the external meatus markedly involved at the very onset of an acute inflammation of the middle ear, that I am disposed to believe that this particular feature, in the present case, was already in existence before the tympanic inflammation developed. In other words, I believe that this patient was in a somewhat gouty condition at the time of the acute attack, and that the latter simply added to the hyperæmia and infiltration of the skin of the external meatus. Such a latent gout, furthermore, explains the non-responsiveness to local treatment. Finally, the snuffing of salt water may be justly suspected of having brought on the acute middle-ear attack.

The following instance affords a good illustration of a complicated case of purulent inflammation of the middle ear:

CASE XLIII.—*Acute suppurative inflammation of the middle ear, following a "cold in the head," in a patient who was both gouty and hysterical; the inflammatory exudation consisted in part of fibrinous material; recovery took place slowly.*

The patient, a lady about forty years of age, contracted a bad "cold in the head" during the first week of September, 1878. In the course of two or three days she began to experience pain in the left ear Various measures were employed to relieve it, and among other things leeches were applied in close proximity to the outer orifice of the ear. The pain, however, steadily increased, and at the time I first saw her (September 18th, 1878) it involved the entire left side of the head. She could hear the ticking of my watch at a distance of only half an inch. On inspection I found the membrana tympani slightly bulging posteriorly. The canal was perfectly dry, but the dermoid surface of the membrane presented a soaked appearance. The parts immediately bordering upon the membrane were intensely red and moderately swollen. Ether having been administered, I made a free incision through the posterior half of the membrane, and carried it upward through a portion of the red and swollen tissues of the posterior fold. A sero-purulent fluid oozed through the artificial opening.

September 19th.—The hot douche was used freely after the drum-membrane had been incised, and the patient remained free from pain for several hours. This morning she is again in suffering. As the douche is used very frequently, it is impossible to state how free the discharge is. On examining the right ear, of which she now complains very decidedly for the first time, I find the membrana tympani and surrounding parts in essentially the same condition as that observed on the left side yesterday. Free incision of the posterior half; to be followed by the use of the hot douche.

September 20th.—Pain in the right ear relieved; slight watery discharge this morning. Pain in the left ear was severe during the greater part of the night; toward morning it diminished, and she was able to sleep for three or four hours. On examination I find the left drum-membrane concealed by a soft, pale, fleshy mass which occupies the inner end of the meatus and appears to be attached to the central portion of the membrana tympani. By pulling upon it with the forceps I ascertained that its peduncle was engaged between the lips of the artificial opening in the drum-membrane. Further traction caused the mass to break off at the perforation. The discharge from the left ear, so far as I can learn, has been slight.

September 21st.—Last evening, while I was out of town, the pain in the left ear became quite severe. Dr. Sexton, who was sent for, found the posterior half of the left drum-membrane markedly bulging, and re-incised it. The incision afforded relief, but at the present time (8 P.M.) the pain is again quite severe. On inspection I found a fleshy mass occupying the inner end of the left meatus. It was of a pale, pinkish hue, but at one part it presented a decidedly red color. By pulling upon it I ascertained that its peduncle was held fast between the lips of the perforation. In all outward respects, therefore, it was like the mass previously removed. By means of the forceps and Blake's snare I removed all of it that was within reach. Under the microscope a teased specimen presented the appearance of a homogeneous mass of dark granules, interspersed here and there with red blood-corpuscles whose circular outlines were barely recognizable. In some places there were indistinct evidences of fibrillation.

September 22d.—Patient passed a poor night. To-day (9 A.M.) there is tenderness over the squamous portion of the left temporal bone, over the mastoid process, and down along the left side of the neck. She complains of a dull, heavy pain in the left temple and eyeball. The left eye is bloodshot. At 8 P.M. I found the patient in so much suffering that I decided to convert the linear incision in the left drum-membrane into a T-shaped one, in the hope of affording an unobstructed escape for the exudation in the tympanic cavity. The patient having first been rendered unconscious by means of ether, I carried out this step, and also made a long and deep incision over the mastoid process.

September 23d.—By aid of opium and poultices patient passed a fair night. This morning (9 A.M.) I find her almost entirely free from pain in the left ear. The pain in the right ear continues, but is not severe. The discharge from both ears is still quite watery in character, and not abundant. At 6 P.M. the pain in the right ear became severe. When I saw the patient at 7:30 P.M. I found decided tenderness over the mastoid process, but no œdema nor redness of the integument. Ether having been administered, I

made a free incision through the posterior half of the right drum-membrane and also through the mastoid integuments.

September 24th.—Patient slept the greater part of the night, and this morning she seems to be every way better. The discharge from both ears is now distinctly purulent in character, though not abundant.

October 1st.—Steady improvement since last note. Left drum-membrane has nearly healed, and the discharge has ceased. On the right side the discharge still continues, but it is steadily diminishing in quantity. Moderate pain at times in both ears.

October 8th.—Right drum-membrane has healed. Patient is now entirely free from pain.

About ten days later I found both drum-membranes apparently normal. So far as the patient could judge, the hearing had been entirely restored. On testing it with the watch, however, I found a slight degree of impairment.

Comments.—In order that the peculiarities of this case may be rightly understood, it is necessary that I should state certain facts which were unknown to me at the time when I attended the patient, and which did not come to my knowledge until long afterward. In the first place this lady was the subject of well-marked hysteria, or perhaps rather neurasthenia; in consequence of which there was an almost constant disparity between the severity of the symptoms as reported by her, and the nature and extent of the lesions as observed by me. Then, in the second place, she had been for years a sufferer from all sorts of gouty manifestations. In the light of these facts I am now able to understand certain things which in 1878 were not at all clear. For example, the gouty diathesis explains the predominance, in the early part of the disease, of the otitis externa diffusa over the inflammation which was going on in the tympanic cavity. It also explains the proliferative tendency which manifested itself in this latter inflammation, and the stubbornness with which it resisted all our efforts to arrest its advance.

Among the most troublesome cases to manage are those in which the products of inflammation seek an outlet through the membrana flaccida, and not through the drum-membrane proper. This membrana flaccida, or Shrapnell's membrane, in certain individuals is so thin and flaccid that the least change in atmospheric pressure in the cavity of the tympanum shows itself at this point sooner than in the drum-membrane. It is a common experience, in examining the ear of a person who has suffered for a long time from narrowing of the Eustachian tube, to find a distinct hollow situated above and behind the short process, and then, after inflation, to find this same region converted into a rounded prominence; while at the same

time the drum-membrane proper shows at most only a slight change in its position as a whole. In such cases it is easy to understand how, under the pressure incident to the accumulation of an inflammatory exudation in the tympanum, this particular region should, by reason of its being the place of least resistance, be the spot where a perforation takes place. Before an actual outlet is established—that is, probably, before the last layer of the tissues, the dermoid, gives way beneath the pressure—the soft parts immediately surrounding this spot display very marked evidences of a special irritation. They become red and swollen, and if our examination of the ear is made for the first time at this particular stage of the disease, we are not at all likely to diagnose accurately what is the true state of the case. I have incised such swellings in the full belief that I was dividing the posterior half of the drum-membrane, and have only discovered my error after the inflammatory swelling had subsided sufficiently to reveal to me the true relations of the parts. The following case affords a good illustration of the peculiar lesions described above:

CASE XLIV.—*Acute suppurative inflammation of the middle ear, with burrowing of the discharge under the skin covering the posterior fold; formation of a sac-like swelling just outside the membrana tympani, which remained intact; slow recovery.*

The patient, a physician, about thirty-five years of age, contracted a bad cold during the first week of March, 1874. Soon afterward he began to experience pain in the left ear, with a moderate degree of deafness. In the course of two or three days a discharge made its appearance, and the pain at the same time became less severe. On the 17th of March, when I first examined the patient's ear, I found it in the following condition: the external auditory canal, in its outer half, was perfectly normal; in the neighborhood of the drum-membrane it was red and somewhat swollen. After all the pus had been carefully removed, the picture presented at the bottom of the canal was that of a red and swollen drum-membrane (posterior half). Posteriorly and superiorly, the swelling merged imperceptibly into the wall of the canal; anteriorly and inferiorly quite a deep recess separated it from the wall of the canal. At the most prominent part of the swelling a slight depression, from which fluid escaped, marked the location of the perforation. As there was comparatively little pain in the ear, so long as the patient remained quiet, I decided to watch the further progress of the case before adopting any more active treatment than simple cleansing of the canal, etc.

On the 20th of March, finding that the swollen condition of the parts persisted, and assuming that the small perforation could scarcely afford an adequate outlet for the discharge, I made a free incision through the swollen tissues.

March 23d.—Persistent pain. Discharge at times bloody. No diminution

in the swelling of the membrana tympani. Mastoid integuments, including the periosteum, freely incised.

March 27th.—Decided improvement in all respects. The swelling has now so far diminished that I am able to distinguish quite accurately the relations of the parts. The drum-membrane proper is intact. Just above it, and overhanging its posterior half, is a teat-like swelling which represents the pouting orifice of the perforation or (more correctly) sinus. In the hope of diminishing the degree of resistance which the discharge must encounter in escaping through such a long sinus, I removed a large portion of this teat-like projection with Blake's snare.

On the following day patient took passage on one of the Savannah steamers, in the hope of hastening his recovery by a change of air and scene. About three weeks later (April 17th) he returned to New York. The discharge from the ear, he reported, had ceased entirely on the 13th, and his general condition had greatly improved. On examination, I found that all evidences of active inflammation had disappeared. There was still, however, a small conical projection of the tissues just above the posterior half of the membrana tympani, and at its tip (and forming part of it) was a collection of whitish material—probably cheesy pus. There was no recognizable impairment of the hearing for voice sounds and conversation, but the ticking of a watch was heard at a distance of only two inches.

In March, 1875, every trace of the attack had disappeared, and the ticking of the watch was readily distinguished at a distance of nearly three feet.

SEQUELÆ AND COMPLICATIONS.

An acute suppurative inflammation of the middle ear does not always have so favorable a termination as that which took place in the preceding cases, and an unfavorable result is particularly apt to happen when the otitis media grows out of a severe attack of measles, scarlet fever, nasal diphtheria, or the grippe. In these diseases an actual destruction of tissue often takes place in some part of the middle ear before the attending physician discovers that anything wrong is going on in that organ. Or, as happens in rare instances, the same unfavorable result may occur even when the disease of the ear is discovered at a very early stage and is vigorously and intelligently treated. But, whatever may be the circumstances under which the destruction actually takes place, a localized bone caries is almost sure to be the immediate result; and from this, in turn, various pathological processes may develop. Thus, for example, we may have, as the most frequent result, a chronic suppuration of the middle ear; while in the exceptional cases a mastoid inflammation, a meningitis, a thrombosis of the lateral sinus, or, at least, a periphlebitis of this vessel, may represent the ultimate issue of the original ear disease. As these sequelæ or complications of

an acute suppurative inflammation of the middle ear are matters of prime importance, I will consider them more fully in a separate chapter.

The participation of the cervical and post-auricular glands in the inflammatory process is a common event in quite a large proportion of the cases of acute purulent inflammation of the middle ear. In the uncomplicated ones, however, I have never known this sympathetic inflammation to go beyond the point of producing a moderate degree of swelling and tenderness of the affected glands. It is only in cases in which the mastoid cells are seriously involved that suppuration of these glands takes place; and, even under these circumstances, we cannot always be sure that the trouble is not a cellulitis rather than an adenitis.

DIAGNOSIS.

When a physician is called to see a patient whose middle ear is only just beginning to be inflamed, he will at first be obliged to limit his diagnosis to the simple fact that an inflammation is going on in that particular portion of the ear. It is only after the disease has advanced further in its course that he can classify it as a catarrhal or a suppurative attack. Occasionally there is some difficulty in determining whether it is the middle ear or the external auditory canal which is the region primarily affected. If the disease has not progressed so far as to involve the external auditory canal to a marked extent, it is scarcely possible to err in our diagnosis. Even without actual inspection, the patient's account of the attack—in the case of an adult—generally gives us some idea of what particular part of the ear is the seat of the inflammation. Actual inspection of the parts, however, can scarcely fail to remove the last element of doubt. I can think of but three possibilities of error: first, an inflammation of the soft parts lining the osseous portion of the external auditory canal and the outer aspect of the drum-membrane may easily be mistaken for an acute inflammation of the middle ear that has involved (secondarily) the inner half of the meatus; then, in the next place, the whitish appearance of the dermoid surface of the drum-membrane, concealing perfectly—as it often does—the underlying inflamed tissues, may mislead an inexperienced observer into the belief that he is looking at an opaque, thickened, and uninflamed membrana tympani; and, finally, it is possible to mistake a deep-seated abscess of the posterior fold for an acute inflammation of the middle ear. The first error can only

be avoided by a careful sifting of all the evidence. An acute inflammation of the middle ear causes more decided deafness and far more pain than does an inflammation of the osseous portion of the canal. Again, the order in which the different symptoms have followed one another furnishes us with valuable aid in deciding which of the two diseases is the one that is under observation in any given case. To avoid the second error, it is simply necessary to demonstrate, by actual manipulation of the parts—that is, by the use of the slender probe, the curette, or the cotton-carrier, armed with a small mop of cotton—that the surface under observation is a part of the living tissues, and not a pasty, dead exfoliation.

The third opportunity for error is afforded by that rare pathological process—a suppurative inflammation in the depths of the soft tissues which constitute the so-called "posterior fold" (see p. 120). The resemblance between the picture which this condition presents, and that which may be seen when a perforation is about to be established in the membrana flaccida, is fairly close; and yet when the two cases are carefully compared, it will be seen that there are certain differences which are more or less characteristic of the two pathological conditions. In abscess of the posterior fold the redness and swelling are most marked at a spot a short distance behind the processus brevis of the malleus, while in the other condition the local disturbance is seated farther forward. Then, besides, in the case of the abscess, the hearing may remain for some time almost if not quite normal, while in the condition which precedes the formation of a perforation in the membrana flaccida, it is almost sure to be noticeably affected. In the third place, the inflammation of the posterior fold remains confined for a comparatively long time to this region; the lower part of the membrana tympani participating scarcely at all in the inflammation. In the other condition, however, this part of the membrane shows plainly that the tympanic cavity is diffusely inflamed. Finally, there are cases of middle-ear inflammation in which the active centre of the disease seems at first to be located in the vicinity of the entrance to the mastoid antrum, as well as in the antrum itself. For a short time —usually only for a day or two—the picture presented, in a case of this kind, very closely resembles that of a suppurative inflammation of the posterior fold. But while the pain in the latter condition is referred mainly to the depths of the ear, in the antral inflammation it is located distinctly behind the auricle; and, furthermore, there are apt to be both tenderness on pressure and swelling at the

corresponding spot. As regards the severity of the pain in the two conditions, I cannot make any positive statement; but I am disposed to believe that it is more acute in abscess of the posterior fold.

In cases of fracture or diastasis along the line of the Glaserian fissure there is at first a localized area of redness and swelling in the region of Shrapnell's membrane. The previous history of a fall or a blow, however, would prevent the possibility of interpreting this picture in any other than the right way.

In infants and young children we must rely almost entirely upon what we can ascertain by actual inspection. The mother's account of the symptoms observed is usually, at best, very vague. On the other hand, primary acute affections of the meatus are not so very common at that early period of life.

If we limit our diagnosis, in the class of cases under consideration, to the mere determination of the locality in which the inflammation is going on, our task—judged from the standpoint of practical utility—is but half completed. In order to treat the case intelligently and successfully, we should push our researches much further. We should have before our minds, for example, a reasonably clear picture of the limits of the inflamed area and of the amount of damage already done by the disease. The color of the drum-membrane, the extent to which it is disfigured, the flatness or rotundity of its movable portions, especially its posterior half, and the degree of inflammatory disturbance in the adjacent cutaneous walls of the canal, all furnish valuable means of estimating the degree of vigor displayed by the inflammation, and the degree of tension or pressure to which the soft parts lining the middle ear are being subjected. Having ascertained these facts with more or less accuracy by direct inspection, our next step should be to learn, if we may, to what extent the inflammation has spread from the tympanic cavity to adjacent parts. Has it extended in the direction of the cranial cavity? The severity of the pain in the head, on the same side as that of the affected ear, affords a rough means of measuring the degree to which the congestion of the adjacent meningeal vessels has progressed. Vomiting may also be interpreted as signifying a suspicious degree of meningeal hyperæmia. Without insisting too much on the value to be attached to the following statement, I may say that I have been disposed to consider the change from a simple unilateral headache to one more distinctly localized in the occipital or frontal region as an evidence

that the meningeal congestion has materially increased in degree and extent. I have observed this phenomenon so often in the more serious cases of inflammation of the middle ear that I think some diagnostic value should be attached to it. Has the inflammation spread to the mastoid region? Pain referred to this region, redness and perhaps swelling of the skin covering the mastoid process, and tenderness on pressure with the finger- these are the symptoms which indicate that the mastoid process is participating in the inflammatory process. In this same group of symptoms may be placed another, viz., redness and swelling of the posterior and upper wall of the meatus, in the immediate vicinity of the drum-membrane. Finally, the determination of the patient's body temperature may serve to confirm the opinion that we have formed from the other methods of examination employed. In children we may confidently expect to find an appreciable elevation of the body temperature in all cases of acute inflammation of the middle ear; in adults we also usually find some elevation of the body temperature, but, as is now well known to be a fact, this elevation is often absent or else it is markedly disproportionate to the serious character of the damage that is being wrought in and around the ear, and particularly in the cranial cavity. It is therefore unsafe in adults to infer, from the insignificance of the rise in temperature or from its remaining normal, that the case is progressing well and that no harm need be feared.

The existence of a perforation may be learned by direct observation or by auscultation while air is being forced into the middle ear. If the perforation is small, or if the membrane has not been thoroughly dried with the mop of cotton-wool, it may be impossible to distinguish the situation of the perforation by simple inspection. As a rule, we can readily discover the point of rupture in such cases by asking the patient to perform Valsalva's experiment while we watch the behavior of the drum-membrane. Even then the perforation may be so small that we can simply distinguish the oozing of a little fluid from a certain portion of the drum-membrane. With the slender probe, however, we can always demonstrate the precise spot occupied by the opening. The presence of fluid exudation in the external auditory canal is not to be taken as satisfactory evidence of the existence of a perforation. It may be, and very often is, simply an exudation from the outer surface of the drum-membrane and adjacent inflamed walls of the canal.

PROGNOSIS

An acute purulent inflammation of the middle ear, if allowed to run its course unchecked, will undoubtedly, in the majority of cases, do so without serious detriment to the patient. In the minority of cases, however—and it is by no means a small minority—the disease produces more or less serious damage. An impairment of hearing of variable degree, a chronic and generally offensive discharge from the ear, and even disease of the adjacent organs which may prove fatal, are the prominent items in the catalogue of damages that may result from an unchecked acute inflammation of the middle ear. These facts are now so well known to the Profession that I certainly may be excused from the necessity of furnishing satisfactory evidence of the truth of what I say. There was a time, however, and that too within the memory of some of the younger men in the Profession, when an acute inflammation of the middle ear was looked upon in a very different light; that is, it was generally considered as one of the diseases of minor importance, and it was accordingly allowed to run its course practically unchecked. As a result of that régime of professional ignorance and indifference with regard to diseases of the ear, there were, and are still in this city alone, hundreds of individuals affected with chronic discharge from the ear. In those days, therefore, the prognosis of an acute purulent inflammation of the middle ear—if based upon the facts of actual observation—must necessarily have been unfavorable, or at least very guarded in its nature, especially where the disease originated in one of the exanthemata. During the last twenty years, however, a very noticeable change has taken place in two particulars. In the first place, the majority of the better class of practitioners now recognize the danger of allowing an acute inflammation of the middle ear to run its course unchecked. If they do not feel competent to manage these diseases themselves, they call to their assistance some professional brother who is familiar with their treatment. In the next place, the number of physicians who are competent to treat a case of acute otitis media has very greatly increased. These remarks apply not only to the city of New York, but also to other cities and towns in the United States and Canada. There is, therefore, no lack of men who know how to prevent the disastrous results which sometimes flow from an acute inflammation of the middle ear. These important changes, both in the state of

professional opinion and in that of professional skill, have already led to a marked change in the prevalence of the bad types of chronic purulent inflammation of the middle ear. I speak now entirely from my own personal observation; and in accordance with that I may say that, if we compare the clinical material observed between 1870 and 1880 with that observed in recent years, a very noticeable diminution will be found to have taken place during the latter period in the proportion of cases affected with really serious chronic disease of the middle ear. There is but one plausible interpretation that we can put upon this fact, viz., that the treatment of this disease in its acute stage has been better conducted during the latter than during the former period. In fact, it is not an exaggeration to say that under proper treatment, *if begun soon, i.e. within a few days after the onset of the attack, an acute inflammation of the middle ear rarely results in the patient's death, or seriously impairs the hearing of the affected ear, or passes into a really chronic purulent inflammation.* At the present time, therefore, the aurist, or the general practitioner who has acquired the special knowledge and skill which the treatment of these cases demands, may give a very good prognosis in cases of acute inflammation of the middle ear, provided he be not sent for after serious damage has actually been inflicted by the disease.

The physician is often asked to state the probable duration of an attack of acute inflammation of the middle ear. The answer must of course depend upon the severity of the attack, upon the age and condition of health of the patient, upon the degree of inflammation and hypertrophy of the naso-pharyngeal mucous membrane, upon the exciting cause of the disease, upon the surroundings and mode of life of the patient, and upon various other circumstances too numerous to mention. Assuming that all these circumstances are favorable, we may estimate the probable duration at from ten days to three weeks in the cases of average severity, and at from four to six weeks in those of a more virulent type. In young and healthy children recovery takes place more quickly than in adults. In persons who have passed the middle period of life, the return to a healthy condition of the parts is apt to be slow. In individuals of a consumptive type our prognosis, especially with regard to the duration of the subsequent discharge from the ear, must be very guarded. In these individuals the mucous membrane of the middle ear seems to possess little or no recuperative power, and the discharge may continue for weeks or months, in spite of our best

efforts to arrest it. In cases of acute inflammation of the middle ear following scarlet fever or measles we must expect a less prompt recovery, as a rule, than is generally observed in cases which owe their origin to a "cold."

TREATMENT.

Since we have acquired the knowledge that an acute suppurative inflammation of the middle ear owes its origin largely to an invasion of micro-organisms, we have not, as it appears to me, made a corresponding gain in power to manage the disease successfully. Our best weapons and our best methods of using them are still the same to-day as those which we employed twenty years ago. On the other hand, this new knowledge has made many pathological phenomena plain which before were very obscure. I think that it has also taught us to judge more leniently a fellow-worker whose treatment, in some particular case, has proved unsuccessful; for the rapidity with which remote regions are reached by the bacteria, in certain exceptional instances, and the amount of damage which they are capable of inflicting in a very short space of time, often stand in marked contrast with the paucity and insignificance of the symptoms and external manifestations upon which our judgment in regard to the particular measures required must largely be based. It is therefore not to be wondered at if now and then—at long intervals, be it said—a fatal issue occurs despite our best efforts to prevent such a result.

TREATMENT OF THE DISEASE IN ITS FIRST STAGE.

The therapeutic task which confronts us in the first stage of an acute suppurative inflammation of the middle ear is of a twofold character: there is an abnormal fulness of the blood-vessels to overcome, and presumably there are already in the tympanic cavity bacteria whose presence must be gotten rid of before the inflammation can be arrested in its onward course. So far as the hyperæmia is concerned, doubtless something can often be accomplished toward reducing it, but the task of dealing directly with the bacteria is far more difficult.

Measures Directly Antagonistic to the Bacteria.—In the hope of diminishing their numbers I once employed intratympanic injections of hydrogen dioxide in the beginning of an acute otitis media suppurativa; but they proved unsuccessful, although they were re-

peated on two or three successive days. The probability is, that the bacteria had already penetrated so deeply into the mucous membrane that the germicidal fluid could not reach them. It does not seem likely, therefore, that we can ever accomplish very much by attempting to destroy these organisms while they are simply passing through the tympanic cavity. So far as I can now see, there remains but one other way in which we can make a direct attack upon them, and that is by introducing into the circulating blood a material which shall render it more or less germicidal in character. Attempts to accomplish this have already been made—as, for example, with the anti-streptococcus serum—but it is yet too early to pass judgment upon the efficacy of this mode of treatment.

It has been known for a long time past that the administration of calomel, in frequently repeated small doses (say one-tenth of a grain every two or three hours, until the bowels begin to respond in a noticeable manner), is capable, in certain cases, of exerting a decided antiphlogistic effect. Recently the very plausible suggestion has been made that this beneficial effect is due to the germicidal properties which the circulating blood acquires when a certain amount of calomel has been introduced into it. The employment of calomel, therefore, is to be recommended in the treatment of these cases.

Measures for Reducing the Hyperæmia.—As matters stand to-day, therefore, we are obliged—in the beginning of an acute suppurative attack—to place our chief reliance upon those measures which tend to diminish the local hyperæmia; and, fortunately, in so far as we may be able to accomplish this result, to just that extent shall we succeed in hindering the advance of the bacteria. For, as I have already stated in the early part of this chapter, an active circulation of the blood offers a serious obstacle to the advance and the destructive power of these organisms; and, in order to obtain such an activity of the circulation, we must remove or diminish the hyperæmia, this condition being incompatible with an active circulation.

The measures which have been found more or less effective in diminishing hyperæmia of the middle ear are the following: the application of either heat or cold to the region of the ear, local bloodletting, paracentesis of the membrana tympani, and bodily rest, or avoidance of physical exercise.

Heat and Cold Compared as Therapeutic Agents.—Both heat

and cold, if of moderate degree, cause contraction of the muscular elements of blood-vessels; that is, they are vaso-motor stimulants. They have both been largely used in the treatment of an acute inflammation of the middle ear, and, on the whole, with a fair measure of success. A moderate degree of heat (say between 105° and 110° F.) often diminishes the pain in the ear very noticeably. Now, inasmuch as this agency possesses no anæsthetizing properties, it must effect this result through a diminution of the intra-tympanic pressure, and this latter it accomplishes by causing a large number of small blood-vessels to contract. When a moderate degree of cold (that of ice water, for example) is employed in the place of heat, an equally good or perhaps even a better result is obtained. Many claim that it rarely fails to relieve the pain; and I am disposed to believe that this statement is true. Unlike heat, cold possesses decided anæsthetizing properties, and consequently it is reasonable to suppose that if the degree of cold employed be sufficiently low, and if the duration of the application be adequately long, the desired benumbing effect must certainly be produced. How far the vaso-motor stimulating effects of this remedial measure contribute to the relief of the pain, is a matter of uncertainty. The practical working of these two agencies is, therefore, about as follows: heat relieves the pain solely through its action as a vaso-motor stimulant—that is, through the diminution in pressure (upon sentient nerve fibrillæ) which results from the contraction of dilated blood-vessels; cold, on the other hand, may relieve the pain in precisely the same manner, but it is more likely that it accomplishes this result through its power to anæsthetize the irritated nerve fibrils. There may be times when the mere relief of pain is the question of paramount importance, and then doubtless cold should be selected by preference; but when the arrest of the disease and the prevention of serious complications take precedence over all other considerations, heat should be preferred to cold. It may fail to relieve the symptom of pain or to alter the course of the disease, but in this very failure we obtain information of decided value, *i.e.*, we learn—as perhaps, in a given case, we may not learn in any other way—that the disease is advancing. Cold, on the other hand, will probably relieve the pain, and thus we may easily be led into believing that the advance of the disease has been checked. Experience has taught us, however, that the disease often continues to advance even when the cold applications are kept up faithfully for many hours, and are perfectly successful in subduing the pain.

An Effective Mode of Employing Heat.—A simple and yet very effective method of applying heat to the middle ear and neighboring regions is the following: While the patient is lying upon the opposite side, with the affected ear turned upward, fill the external auditory canal of the latter with hot water (about 105° F.). Then place immediately over the ear a hot flaxseed-meal poultice (five or six inches square and fully half an inch in thickness) and spread a folded shawl or blanket over the whole, in order to prevent the heat from being dissipated too rapidly. As water is a good conductor of heat, that which fills the meatus may rightly be considered as an arm of the poultice which extends down to the very membrana tympani itself.

It would be interesting to know just what is the most effective way of employing heat in the treatment of an acute inflammation of the middle ear. My own impression is, that the real therapeutic efficiency of a hot poultice is exhausted in the course of a very few minutes; but I have never had a convenient opportunity for testing the correctness of this impression. When a patient who has been in suffering experiences decided relief from the application of heat in some form to the affected ear, he is very apt to desire that this part of the treatment be continued for several hours. But when I am asked to give specific instructions in regard to the proper length of time, I now usually advise the substitution of dry heat, in the form of a double handful of cotton-wool, at the expiration of an hour's poulticing. The results seem to be just as good as they were formerly, when I was in the habit of recommending continuous poulticing (a fresh poultice being applied every half-hour) for a period of three or four hours.

So far as my own experience goes, douching the inflamed ear with a continuous current of hot water, for a few minutes at a time, is certainly no more effective than the method which I have just described. On the other hand, it is a far more troublesome procedure to carry out successfully, and it is very apt to end in a wetting of the patient's clothing or bed-linen.

The Best Method of Applying Cold to the Ear.—The most convenient, comfortable, and effective contrivance for applying cold to the region of the ear is undoubtedly that known by the name of "Leiter's coil." It is a slender lead pipe, coiled in such a manner that it can be applied flatwise to the region immediately surrounding the auricle; an open space, through which the latter may project, being left in the centre of the coil. Iced water is allowed to

flow slowly through this leaden pipe, and to escape from one end of it into a piece of soft-rubber tubing which extends to a suitable receptacle lying upon the floor or upon a chair. By means of a rubber band or a strap this apparatus can be fastened firmly to the patient's head, thus rendering it unnecessary for a nurse or an assistant to lend a hand except when the receptacle of iced water requires to be refilled.

Local Bloodletting.—The abstraction of blood from regions which border closely upon the inflamed area may be effected by means of simple incisions, by the application of leeches, and by means of either the Heurteloup artificial leech or the apparatus devised by Dr. Gorham Bacon, of this city.

Medicinal leeches should be applied to the skin just in front of and below the tragus and as close to it as possible. The region immediately behind the auricle is perhaps even preferable to this, at least so far as effectiveness of the bloodletting is concerned. But there is a good reason why leeches should not be applied to the latter region. The leech-bites remain as sore spots sometimes for a period of several days, and consequently if we desire to ascertain whether there be any tenderness on pressure over the mastoid region, we shall not be able to determine surely—in the event of our finding any such tenderness—how much of it is due to actual inflammation in the underlying bone and how much to these superficial sore spots.

So far as the number of leeches to be employed is concerned, I believe that in a fairly strong and healthy adult it is of very little use to apply less than four; while in children of a more advanced age and in not very strong individuals two will perhaps suffice. In infants and quite young children it is better to omit leeching altogether, as in them it is sometimes a difficult matter to arrest the bleeding, which continues after the leeches have let go their hold. In adults, on the other hand, this after-bleeding is rather to be promoted, say for half an hour or an hour.

In the place of leeches we may employ, with equally good effect and with greater safety and comfort, the *Heurteloup artificial leech*, or the recently contrived apparatus of Dr. Gorham Bacon, of this city (see Figs. 87 and 88). This very simple contrivance answers the desired purpose admirably. As a substitute for the scarificator, which is a somewhat expensive apparatus and not easily kept clean, one can employ a sharp-pointed scalpel.

Both leeching and poulticing are procedures which, if they hap-

pen to be used at the right moment, are competent to turn the scale in favor of recovery. But where the inflammation is of a really serious nature, neither the one nor the other is likely to effect more than a brief delay in the advance of the disease. In the very early stages of an acute otitis media I invariably give the poulticing a fair trial, but I rarely in these days resort to leeching.

The so-called *Wilde's incision* (named after Sir William Wilde, of Dublin, Ireland) is another form of local bloodletting which is

FIG. 87.—Wet Cup, for use in Ear cases.

perhaps fully as effective as that by means of leeches. The principal objection to it is the same as that which I have brought against the application of leeches to the mastoid region, viz., that the presence of an unhealed wound makes it impossible for us to determine

FIG. 88.—Scarificator, for use in applying Wet Cup to region of the Ear. (After Bacon.)

the real significance of any tenderness which we may discover in this region. Furthermore, in the estimation of many patients it is a veritable surgical operation, to which they will not readily give their assent unless we can assure them that it is decidedly necessary. In this operation the skin and subjacent tissues, including the periosteum, are divided by an incision extending from the base very nearly to the apex of the mastoid process, the external wound measuring from three-fourths of an inch to an inch in length. If the patient's head is in the erect position, the point of the knife should be introduced into the skin about on a level with the upper wall of the external orifice of the auditory canal. If we begin the incision higher up, we shall be apt to divide a branch of the posterior auricular artery, which usually crosses the bone at about

that level. On the other hand, if we make the incision a little too far forward, we may nick this artery or incise it longitudinally, and so prepare the way for the development of a false aneurism, as has already twice happened, once in my own practice and once in that of Dr. Charles J. Kipp, of Newark, N. J. After the bleeding from the wound has ceased—and, within reasonable limits, the more protracted and the more copious the bleeding the better—the parts should be thoroughly sponged with a bichloride of mercury solution (1:1000) and a simple dressing applied.

Paracentesis of the Membrana Tympani.—The main object of establishing an artificial opening in the tympanic membrane is to secure free drainage, and so to put an end to the pressure, which is harmful to the mucous membrane and other structures of the ear in a variety of ways. For example, this pressure interferes with the circulation, and so threatens the life of the tissues pressed upon. It also facilitates, as I have already before stated, the advance of the bacteria deeper and deeper into the surrounding parts. Hence, the sooner this little operation is performed, after evidences of intra-tympanic pressure are discovered, the better for the welfare of the patient, and the sooner is he likely to be relieved of his pain. At the time when the paracentesis is made, the mucous membrane lining the tympanic cavity is usually in a very much swollen and congested condition. A number of small blood-vessels, therefore, are quite sure to be divided as the point of the knife passes over the opposite promontory. Hence paracentesis of the tympanic membrane must be classed not simply as a measure for securing better drainage, but also as a very direct and powerful agency for diminishing hyperæmia of the middle ear.

The two principal *indications for incising the drum-membrane*, in the course of an acute otitis media, are: undue outward distention or marked hyperæmia and infiltration of the posterior half of this membrane (usually the only part which is fairly visible). Either of these two conditions—*when associated with the symptom of pain*—calls for the operation of paracentesis.

In infants and in adults it is generally practicable to perform this operation in a satisfactory manner without the aid of a general anæsthetic, but in young children and youthful subjects it is not advisable to attempt it without such aid. The local application of cocaine has proved unsatisfactory as a means of anæsthetizing an intact membrana tympani.

So far as *the operation itself* is concerned, there are only a few

points to which it is necessary to call attention. In the first place, in order that we may avoid the risk of implanting in the middle ear a new source of infection, it is desirable that the cutting portion of the myringotome should be allowed to remain for a few minutes in strongly carbolated water. I have also used hydrogen dioxide for the same purpose, and on the whole I prefer it to carbolic acid. Then, in the next place, it is important to render the walls of the meatus and the outer surface of the membrana tympani aseptic, as otherwise, no matter how clean the knife may be, it might readily transfer some septic material from the outer to the inner side of the membrane when the incision is made. Here, again, the hydrogen dioxide will be found extremely useful. Two or three successive moppings with this reagent—each time with a fresh mop—may be trusted to destroy any septic organisms that happen to be present in the canal. The particular pattern of instrument—whether

FIG. 89.—Myringotome.

provided with a spear-pointed or a scalpel-shaped end; whether straight or bent at an angle—is not a matter of prime importance. It is largely a matter of individual preference whether a straight or a slightly bent myringotome be employed. After using both kinds, I have gradually fallen into the habit of using only the straight instrument. It seems to me that I can control such a straight myringotome more perfectly than I can a bent one. Those which I use are made from a single piece of steel, 16 ctms. long; the slender shank together with the blade measuring 7 ctms., while the eight-sided, roughened handle measures 9 ctms. in length. On the other hand, it is essential to a good illumination of the field of operation that the instrument selected should be of slender proportions; it is also very desirable that the cutting-edge and point of the knife should be very sharp.

There are two important points which should be kept clearly in mind when one is about to perform a paracentesis of the membrana tympani. The first is, that the point of the knife must not strike the stapes or the long process of the incus; the second, that the artificial opening, to be of the maximum value, must have a large area. In order to avoid injuring the stapes the operator should insert the point of the knife into the membrane quite close to its posterior periphery and not higher than on the line of junction be-

tween the posterior superior and posterior inferior quadrants (see Fig. 90). If he wishes to secure an opening that will afford ample drainage for a period of at least twenty-four hours, let him continue the incision downward and forward, in a curving direction, until it shall reach a point, in the anterior inferior quadrant, about halfway between its upper and posterior boundary-lines. The reason for stopping at this point and not going any farther forward is this: Around the mouth of the Eustachian tube the tympanic mucous membrane is much thicker, firmer, and more highly vascular than it is elsewhere, and when incised it is likely to afford escape to coagulable blood. In other words, if the incision be carried too far forward there is a strong likelihood that when the active bleeding stops, a mass of coagulated blood will be left behind in the tympanum—a mass which is large enough to entirely cover the artificial opening and in this manner seriously interfere with the drainage. That this mistake has been made, in some particular case, may always be suspected when it is found that the paracentesis, which has been performed rightly in all other respects, affords relief from pain for only a brief interval of time; and this suspicion will be converted into an actual certainty when, at the end of from twenty-four to forty-eight hours, there is found engaged in the artificial opening a firm mass of fibrinous material, the removal of which, by means of moderate traction made with the forceps, gives prompt relief to the pain.

FIG. 90.—Diagram showing where the membrana tympani should ordinarily be incised. The dotted lines, in the upper and posterior quadrant of the membrane, indicate where the long process of the ambos and the posterior crus of the stapes are located. The heavy black line, which curves downward and forward from just below the stapes, corresponds to that which the knife should follow.

Immediately after the operation it is a good plan to fill the auditory canal with as hot water (that has been previously boiled) as the patient can readily bear, and then to apply externally a large sponge or several thicknesses of flannel cloth wrung out of hot water. The heat and moisture applied in this manner relieve the pain caused by the incision.

As a final step the membrane and the walls of the external auditory canal should be dried with pledgets or mops of sterilized cotton, and then sterilized gauze should be packed lightly in the canal, from the tympanic membrane outward. An outside cushion of aseptic gauze and cotton, to be held in place by a roller bandage,

will complete the dressings, which may remain undisturbed for several days if the pain does not return.

Although there are not a few authorities who seem to think it desirable to employ inflations as a regular part of the routine treatment, after an opening has been established in the tympanic membrane, it has never seemed to me that this practice was to be commended. After the perforation has healed and every trace of active irritation has passed away, I believe that inflations are likely to prove useful, and accordingly I employ them at this stage, but never earlier.

Bodily Rest and Avoidance of Physical Exercise Conducive to a Diminution of Hyperæmia of the Middle Ear.—An acute inflammation of the middle ear is almost invariably aggravated by physical exercise on the part of the patient. *Rest*, or the avoidance of physical exercise, is therefore a very important agent in diminishing the virulence of this disease. A man in active business does not like to remain quietly at home because his ear is somewhat painful, and the physician often finds difficulty in convincing him that by pursuing such a course he will in the end economize time. Again, at a later period, after the acute symptoms of the disease have apparently subsided, patients are apt to resume business too soon, and in this way they may bring on a relapse which may prove even more serious than the original attack. Young children, during the onset of the disease, show very little disposition to play or to take any form of exercise. At a later stage, however, the precautions referred to above are very necessary. The moment the child is relieved from pain and has had the requisite amount of sleep, the desire to resume play manifests itself in an unmistakable manner. Restraint should be exercised under these circumstances, and the child should be allowed to regain its full measure of freedom in this respect only gradually. I am disposed to attach a great deal of importance to this matter of rest in the treatment of acute affections of the middle ear. I do not mean by this that I consider it necessary for the patient to go to bed and remain there until every trace of the inflammation has subsided, although in certain cases this will be found to be the better course to pursue; but simply that he should not walk about to any extent, that he should not go up and down stairs, that he should not ride in a carriage or omnibus over rough city pavements, that he should not transact any business that is calculated to engross his attention very seriously, and so on. All these things excite the heart's action or cause a

jarring of the inflamed and sensitive mucous membrane of the middle ear; and if they are persisted in, renewed inflammation is likely to be the result. Some of the worst cases of inflammation of the ear that I have seen clearly owed their protracted and violent course to the patient's disregard of this well-established principle in the treatment of inflammatory affections.

The *diet*, during the acute stage of the disease, should, as a matter of course, be of a non-stimulating character, and alcoholic drinks should be avoided. This is a matter, however, which generally regulates itself, as the patient is not apt to have sufficient appetite for any but the simplest kind of food.

TREATMENT OF THE DISEASE AFTER THE ACUTE STAGE HAS SUBSIDED.

The arrest of an unpleasant discharge and the restoration of the middle ear to as nearly normal a condition as possible are the main features of the problem which confronts us in this second stage of an acute otitis media. To solve this problem successfully, it is necessary that we should understand what are the exact pathological conditions which are keeping up the discharge. In the first place, we may exclude altogether from consideration such lesions as bone caries, accumulations of cheesy material, and granulation-growths in any part of the middle ear. These are the chief factors in the disease known as chronic suppurative otitis media, and they will receive due consideration in the chapter devoted to that subject. But if it be assumed that none of these lesions has anything to do with the disease which we are now considering, what, it will be asked, are the pathological conditions which prevent the middle ear from returning to a normal condition? My answer is, that the most important among these conditions is a *vaso-motor paresis* of the blood-vessels of the middle ear, and that back of this we often find, as predisposing factors, hypertrophy of the lymphoid tissue in the pharyngeal vault, enlarged faucial tonsils, diminished physical vigor, etc. To these may be added a local predisposing factor, viz., obstruction to the free escape of the purulent fluid.

As soon as the patient's general condition will permit, a thorough examination of the vault of the pharynx should be made; and if it be found that there is hypertrophied lymphoid tissue in this region, its complete removal should be effected without unnecessary delay. Enlarged faucial tonsils usually play a less important part

in keeping up the disease of the middle ear; but if the case proves to be one of unusual stubbornness, these too should be removed.

Systematic Douching of the External Meatus with Hot Water.—By means of this procedure several desirable things may be accomplished. In the first place, exfoliation of the superficial layers of the skin, both on the membrana tympani and throughout the inner half of the meatus, is almost sure to take place toward the end of the first stage of an acute suppurative attack; and the douching, if done with a fair degree of force, will loosen and carry away these masses of cast-off epithelium, and so prevent them from obstructing the escape of the purulent fluid through the perforation in the drum-membrane. In the second place, when the discharge is not very active, it is apt, through stagnation, to undergo decomposition to a greater or less degree. Decomposed pus possesses acrid properties, and consequently when it is in this condition it tends rather to perpetuate the already existing inflammation. The hot douching, repeated at suitable intervals, does not allow sufficient time for decomposition, and so, by means of this procedure, the evil in question is done away with entirely. Finally, the hot douching does excellent work as a vaso-motor stimulant, causing contraction of the paretic blood-vessels of the middle ear.

In a very large percentage of the cases of acute suppurative inflammation, this douching with simple hot water or with water which has first been boiled and then allowed to cool to the proper temperature (about 105° F.)—repeated three or four times a day at first, and then employed with gradually decreasing frequency—constitutes all the local treatment that is required.

The choice of instrument and the mode of carrying out the douching are by no means matters of small importance. Indeed, if personal attention be not paid to these points by the physician, it is more than likely that in a majority of instances the injected stream of water will either not reach the tympanic membrane at all, or else it will play upon it too feebly. Such unsuccessful douching may be explained in the following ways: in some instances the diameter of the nozzle is too great, and for this reason it cannot be introduced far enough into the auditory canal; in other instances, the nozzle may be slender enough, but the mother or the attendant is afraid of injuring the drum-membrane, and consequently the nozzle is not pushed far enough into the canal; finally, in still other instances, the nozzle is both rightly constructed and rightly introduced into the meatus, but the amount of force imparted to the

injected column of water is not sufficiently great. The apparatus which is known as "Angelo's ear-douche," and which is described and pictured at the end of the first chapter, has been thoroughly tested during a period of over twenty years, and has been found to diminish very materially the difficulties which I have just enumerated. The nozzle is slender enough to enter even a much narrowed meatus, and prongs have been placed along its sides at such a distance from the actual tip that no matter how hard the instrument may be crowded into the meatus, it cannot be pushed in far enough to disturb the membrana tympani. On the other hand, if the nozzle be pushed into the meatus as far as its prongs will permit it to go, the escaping stream of water can scarcely fail to play upon the drum-membrane and neighboring walls of the canal. The force of the injected stream will depend upon the degree of compression exerted upon the soft-rubber bulb which contains the supply of water.

The attending physician should, in every case, personally superintend the carrying out of this procedure when it is done for the first time, and he should satisfy himself that the person to whom it is intrusted is competent to perform the task efficiently.

Intratympanic Injections of a Silver-Nitrate Solution for the Purpose of Exerting Direct Vaso-Motor Stimulation upon the Blood-Vessels of the Middle Ear and Eustachian Tube.—After the simple douching with hot water has been tried for one or two weeks without effecting a complete arrest of the discharge, it becomes plain that we can no longer trust to this measure alone, but must employ something more effective. If our diagnosis is correct—that is, if the disease has now reached a stage in which the only lesion to be overcome is a paretic condition of the tympanic and tubal blood-vessels—a solution of silver nitrate, this most effective of vaso-motor stimulants, should be brought in contact with the affected mucous membrane. There is practically only one way in which this can be accomplished; that is, by forcing the solution through the opening in the membrana tympani into the middle ear. If the perforation is not a mere pin-hole, the following method of accomplishing this may be adopted: The fluid contained in the tympanum having been driven out into the external meatus by Politzer's method of inflation, and the latter region having been thoroughly cleansed and dried, the patient should hold his head in such a position that the affected ear shall be turned upward. Several drops of the remedial solution, which does not require to be warmed, should then be introduced into the external auditory

canal; after which the physician should pull the auricle away from the patient's head with one hand, while with the forefinger of the other hand he should press the tragus backward in the same manner as he would shut the lid of a box. When this has been accomplished he should (while relaxing his hold upon the auricle) press the tragus slowly and firmly inward toward the drum-membrane. In this way quite a strong pressure can safely be brought to bear upon the silver solution that lies upon the outer side of this membrane—a pressure usually sufficient to force a large part of it into the tympanum and on through the Eustachian tube. It is well, however, not to trust to this pressure alone, but to take advantage of the aid which the patient (if an adult) is able to afford by performing the act of swallowing (with or without simultaneous closure of the nasal orifices). When I resort to this method of forcing fluid into the middle ear, I make it a rule to lessen the pressure the moment the patient experiences either pain or dizziness. I also cease to make pressure as soon as the patient notices that some of the solution has reached the naso-pharyngeal space. The final step in the procedure is to remove, by syringing, the surplus of silver solution remaining in the external auditory canal. It is neither necessary nor desirable to expel from the tympanum any of the solution which may happen still to be present in that cavity.

The strength of the silver solution should not exceed one per cent (5 grains to the ounce of distilled water); and when it is employed for the first time in any given case, it is better that it should be somewhat weaker (2 or 3 grains to the ounce). Oftentimes a single application of the remedy in the manner described suffices; but if the secretion in the tympanum is even slightly mucoid in character, it is likely to interfere materially with the action of the drug (by preventing it from coming in contact with the mucous membrane generally). In that event several applications, to be made at intervals of two or three days, will be found necessary.

When the perforation in the membrana tympani is a mere pinhole (say, less than one millimetre in diameter), the method described above is not likely to prove satisfactory. Under these circumstances—and personally I should be disposed to add, under all circumstances—it is better to inject the remedial solution by means of an instrument known as "the middle-ear pipette" (Fig. 91). These pipettes are made from glass tubing, five-sixteenths of an inch in diameter and with rather thick walls. As they are not so very difficult to make, I will describe briefly the steps of the proce-

dure. Take a piece of glass tubing, about eight inches in length; hold the ends lightly with the fingers of both hands, and rotate it slowly around its long axis over the blue flame of a Bunsen burner. As soon as the central portion of this bit of tubing has become sufficiently soft—not at one small spot merely, but over a section of the tube say from half to three-fourths of an inch in length—draw it out into a slender tube about ten inches long. As the pipette when completed should measure not less than three inches in length in its slender portion, the next step should be to file a shallow circular notch around the tube, at a point about three inches distant from the shoulder—if I may so designate the spot where the broad part of the tube begins to grow narrower—and then break the tube at this spot. As it is desirable to have the tip of the pipette slightly bent, we should next heat this part very cautiously until it bends over, from its own weight, in the direction that we desire it to follow. If the tip beyond the final bend is too long, or if the heat has caused the orifice of the narrow canal to become closed, a circular notch should be filed in the tip, at a distance of not more than two millimetres from the bend. To render this fractured end sufficiently smooth, it may either be brought near enough to the Bunsen flame to fuse the sharp edges, or these may be ground smooth by a suitable file or stone. The broad portion of the tube, if too long, should be filed and broken off at a distance of from an inch and a half to two inches from the point where it begins to grow narrower. Before doing this, however, the physician should heat the tube at this shoulder and bend it at an angle of 120 degrees. The rubber caps attached to the glass droppers usually sold by the apothecaries may be fitted in a similar manner to these pipettes, and will be found to answer well the purposes for which they are intended.



FIG. 91.—Middle-Ear Pipette. Actual size. *a*, Glass tube; *b*, cap of India-rubber.

In practice it will be found necessary to have right and left pipettes, as one adapted for the introduction of fluids into the right mastoid antrum cannot be readily used for this purpose in the left

ear. A third pipette, with the tip bent directly downward (when the instrument is held with its rubber cap pointing downward), will also be found useful in those cases in which the perforation occupies the anterior inferior quadrant of the drum-membrane.

It is scarcely necessary to discuss here at length the question whether the curved or the straight tips are the better adapted for general use. My own preference is for the former. With the straight tip one is apt either to push it in too far, or to unintentionally draw it out of the tympanic cavity altogether, in both of which cases no fluid from the pipette will reach the middle ear. On the other hand, with the curved tip, it is possible to push it firmly against the mucous membrane of the promontory without thereby closing the aperture; and if we draw the tip too far outward, the resistance offered by the membrana tympani gives us timely warning of what we are doing. Furthermore, the curved tip enables us to direct the current of the escaping fluid toward or into the mastoid antrum. For all these reasons I consider the curved tip decidedly preferable to the straight one.

As glass pipettes may easily be broken, it is urged by some that these instruments should be constructed of platinum. Those who are unable to make their own pipettes, or who are not within easy reach of an instrument-maker, cannot probably do better than to follow this recommendation. In the course of several years I have broken perhaps half a dozen pipettes, at a total cost of only a few cents. A good set of platinum pipettes, similar in all respects to the glass ones which I have described, can scarcely be purchased for less than ten or fifteen dollars. To very many men this expensiveness of the platinum instruments would prove a serious objection to their use. I am therefore disposed to plead strongly in favor of the glass instruments, especially as they can now be purchased at some of the instrument-makers' shops.[1]

It was formerly the practice—and possibly this practice may still prevail to a certain extent—to prescribe the dropping (by the patient) of certain remedial solutions into the external auditory canal, in the hope of thereby accelerating a cure of the middle-ear disease. As anybody can readily understand, this plan of home treatment must necessarily, at best, be very inefficient, and particularly in the class of cases which we are now considering. The employment of the hot douche constitutes the only local treatment

[1] For example, at Reynders & Co. and at Meyrowitz Bros., in East Twenty-third Street, in this city.

which the patient can advantageously carry on at home; and even in the chronic cases in which the perforation happens to be quite large, the employment of any additional local measures is likely to prove a mere waste of time, if not an actual hindrance to the desired cure.

If the perforation is sufficiently large, powdered burned alum may be used in the place of a silver-nitrate solution, and for the same purpose. The mode of procedure is the following: After the middle ear has been freed, so far as this is possible, from the secretion which it contains, and also after the external meatus has been carefully dried, the tip end of a slender silver probe should be slightly moistened, then dipped into the mass of finely powdered burned alum, and finally carried with its load of the remedial powder into the middle ear. Two or three such loads, if not spilled just as the probe is entering the tympanic cavity through the narrow gateway of the perforation, will usually suffice. As to the general efficacy of burned alum as compared with silver nitrate, I am confident that the latter, when properly managed, is far superior. Nevertheless, one encounters every now and then a case in which the alum accomplishes what the silver solution has failed to accomplish.

General Measures which Aid in Arresting the Discharge.— When the local treatment fails to effect the desired cure, we may look for further aid from the internal administration of iron, strychnine, cinchona bark, and cod-liver oil. In young children the syrup of the iodide of iron (10 drops to the dose) and cod-liver oil in teaspoonful doses three times a day will often accomplish the desired result in a week or ten days. In adults, on the other hand, we have, in change of climate, etc., by far the most efficient remedy that we can prescribe for the relief of the obstinately paretic blood-vessels of the middle ear. Children are also markedly benefited by such a change in their surroundings, particularly when their home is in one of our larger cities and they are taken from it to some salubrious place in the country. The greater purity of the air in such a place, as well, probably, as its different character, seems to stimulate the diseased mucous membrane to return to a normal condition.

Inflations, in this later stage of an acute suppurative inflammation of the middle ear, are not indicated. They simply serve to drive the purulent secretion out through the perforation into the

external auditory canal; but as this secretion is speedily reproduced, I cannot see what possible gain is to be derived from the mere act of expelling it from time to time. After the perforation has healed, the conditions, for a certain length of time, will be those of a catarrhal or non-suppurative inflammation of the middle ear; and, in the presence of these conditions, inflations may very well serve a useful purpose.

CHAPTER XV.

CHRONIC SUPPURATIVE INFLAMMATION OF THE MIDDLE EAR.

ETIOLOGY.

In the present chapter I propose to consider only those types of chronic suppurative disease of the middle ear in which the pathological alterations are of such a nature that we may reasonably hope to cure them without resorting to an operation upon the mastoid process. The other cases will receive due consideration in another chapter, entitled "Diseases of the Mastoid Process and Neighboring Structures." I have adopted this arrangement of the subject-matter partly for reasons of convenience and partly in order to avoid repetition as much as possible.

A chronic suppurative inflammation of the middle ear begins almost invariably as an acute inflammation. In tuberculous and syphilitic individuals we may observe an insidious and painless development of the disease in the middle ear, but these cases are comparatively rare. The etiology of the chronic form, so far at least as it can be said to have an etiology separate from that of the acute variety, may be summarized in a single sentence: the lack of proper treatment during the acute stage of the inflammation is the cause of the chronic form of the disease in ninety-nine out of a hundred cases. This may seem somewhat exaggerated. Nevertheless, I believe it to be true. There are many cases, I admit, which yield very slowly to even the most skilful treatment, and which perhaps would be described as having merited the title of "chronic"; but the total duration of the affection is even then not likely to exceed a few weeks, whereas a genuine case of chronic otitis media purulenta is one in which either a constant or an intermittent discharge from the middle ear goes on for months, if not for years. It is to cases of this kind that I refer when I say that they owe their origin, as a rule, to the lack of proper treatment during the earlier stages of the attack.

COURSE OF THE DISEASE.

The simplest and least serious form of chronic discharge from the middle ear is that in which the only demonstrable damage remaining after the subsidence of the original acute attack is the partial destruction of the membrana tympani. In these cases, so far as can be ascertained, no areas of proliferative activity remain in any part of the mucous membrane, nor are there any spots where the bone is denuded of its natural covering. The discharge, which is often of a distinctly mucoid character, is not constant. When investigated more closely, these cases often turn out to be in reality cases of Eustachian catarrh, in which the existence of a perforation in the drum-membrane renders the escape of the secretion by this route easier than by the natural outlet in the pharyngeal vault. The removal of some remnant of hypertrophied lymphoid tissue from the latter cavity is usually all that is required to effect a cure.

Then besides these cases there are doubtless a few—very few, I imagine—in which absolutely the only lesion, in addition to the perforation in the tympanic membrane, is a vaso-motor paresis of the tympanic and tubal blood-vessels. Intratympanic injections of a weak silver-nitrate solution cause the discharge to cease—sometimes permanently, sometimes only for a limited period of time. The favorable result obtained by these injections, however, furnishes good evidence that the cause of the discharge could scarcely be anything more serious than a mere vaso-motor paresis.

The most numerous cases, doubtless, are those in which the discharge has a bad odor, and in which, as a rule, it is possible to demonstrate the presence, in the middle ear, of one or more of the following conditions: bone-caries, granulation-growths, and cheesy or epithelial products. The bone-caries and the granulation-growths are both of them lesions of probably contemporary development—the immediate outcome of the original acute attack. But the cheesy and epithelial products develop at a later date, and their presence affords unmistakable evidence that the mucous membrane is being subjected to some unusual irritating influence. There can be scarcely any doubt that this irritation is supplied by the secretions of the region, which, under the influence of the bacteria of decomposition, have been rendered acrid. In extreme cases a bone-caries, which originally involved only a small area and exerted at most only a slightly harmful effect upon the patient, may eventu-

ally, under the favoring circumstances just described, destroy all the bone substance which separates it from a vital part, like the lateral sinus, the brain, or the carotid artery; and granulation-growths, under the same favoring influences, may attain an unusually large size.[1]

DIAGNOSIS.

The physician's chief duty, so far as the diagnosis is concerned, is to ascertain as accurately as possible to just what extent, and in what particular respects, the different parts of the tympanum and neighboring regions are diseased. A thorough cleansing of the external auditory canal must be his first step in the effort to gain this information. Just how this should be accomplished has been stated in detail in Chapter I., and it will be unnecessary here to enter into any further description of the conditions which call for the use of this or that particular instrument, or to attempt a description of the proper modes of using them. I will simply formulate two general rules, which will be found, I believe, useful. The *first rule* is this: When granulation-tissue presents itself to view, it is never safe to assume that the relations are what they seem to be. Thus, for example, I have more than once thought, after thoroughly cleansing an ear, that the picture presented to my eye was one of a granulating and very much hypertrophied mucous membrane of the inner wall of the tympanum, with total destruction of the membrana tympani. By the aid of simple inspection this was as far as I was able to go in my interpretation of the appearances observed. By gently manipulating the parts with the probe or the curette, however, the incorrectness of my interpretation became at once apparent. The "granulating and hypertrophied mucous membrane of the inner wall of the tympanum" was in reality a flattened polypoid growth, lying upon the outer surface of the drum-membrane. Its peduncle, which passed through a large perforation in the posterior superior quadrant of the drum-membrane, sprang from the upper and posterior portion of the tympanic cavity. Long experience and the most careful scrutiny will never enable the physician to dispense with these instrumental manipulations. And it must be remembered that an error in diagnosis, under circumstances such as I have just described, means also an erroneous plan of treatment.

[1] One which I removed during my active service at the New York Eye and Ear Infirmary measured an inch and three-quarters in length and fully half an inch in diameter at the point of greatest breadth.

The *second rule* to which I referred above, is the following: If no fistulous opening is discoverable at any point in the walls of the external auditory canal or in Shrapnell's membrane—that is, in parts which can actually be seen—then we should take for granted that somewhere in the upper and posterior portions of the middle ear—that is, in parts which cannot possibly be examined by the eye—one or more of the following pathological conditions exists, viz., a mass of granulation-tissue, an area of bone-caries, or an agglomeration of cheesy and epithelial débris. The actual demonstration of one or more of these conditions is by no means the uncommon reward of him who, acting upon the above assumption, proceeds to search for them with his slender middle-ear probe and with suitable injections.

There are certain facts which may enable us, in some cases, to direct our search more intelligently, and consequently to reach more easily a correct diagnosis. Thus, for example, if we find that the discharge is escaping through Shrapnell's membrane we may feel reasonably sure that we are dealing with a case in which there is caries of the neck or head of the malleus. If we find a mass of granulation-tissue springing apparently from the posterior and upper portion of the tympanic cavity, we have a right to assume that the chief seat of the disease is in or close to the mastoid antrum. If the amount of the discharge—in the case which I have just supposed—is rather scanty and not particularly bad-smelling, we are warranted in believing that the pathological condition is a bone-caries, of small extent, involving merely the lip of the entrance to the mastoid antrum and perhaps also the short process of the incus, which is fastened to the tympanic wall at this spot. On the other hand, if the accompanying discharge is fairly abundant, and especially if it has a foul odor, we may assume with confidence that some comparatively large area, probably larger than that of the mastoid antrum, must be involved, and that the actual lesion must be a bone-caries, in company with an agglomeration of cheesy and decomposing pus. In both of these carious conditions—that of limited area and that of greater extent—the mass of granulation-tissue at the posterior end of the tympanum points clearly to the fact that pus of an irritating character must be constantly flowing down over this part of the mucous membrane. Finally, if there are granulations which seem to spring from a point directly above the membrana tympani, the vault of the tympanum will be the locality where we may expect to find the lesions which are perpetuating the discharge.

If in such a case the incus and malleus have not already been destroyed during the original acute attack, these two ossicles may well be suspected of being affected by caries.

PROGNOSIS.

Inasmuch as I have excluded from the present group of cases of suppurative inflammation of the middle ear all those in which the disease has already made serious encroachments upon neighboring parts, the prognosis, *so far as life is concerned*, is very good. But under conditions of neglect or of unusual irritation, it is possible for some of these cases to take on a very grave character. In other words, there is a possibility of danger in every case which is characterized by the presence of bone caries in the middle ear at some point situated at a level higher than that of the upper boundary of the membrana tympani. An area of caries situated at some point lower down—as, for example, at the posterior end of the tympanum or in the floor of that cavity—is not likely to have its drainage seriously obstructed. The statement may therefore be made that the danger, in all these cases, is in direct proportion to the likelihood of the drainage becoming obstructed.

A favorable prognosis may also be made in regard to the *arrest of the discharge* by therapeutic interference.

So far as the *hearing* is concerned, it is only in exceptional cases that we can encourage the patient to believe that it will be rendered more acute. Thus, for example, the removal of granulation-tissue from the vicinity of the stapes will oftentimes effect a very decided improvement in the hearing, but the mere arrest of the discharge does not usually exert a permanently favorable effect upon this function. Indeed, in some instances it distinctly reduces the hearing power—undoubtedly through a diminished succulency of the soft parts surrounding the foot-plate of the stapes. With the diminution and final cessation of the discharge these soft parts become increasingly dry, thereby losing much of their flexibility; and, as a result of this change, the stirrup, or rather the stapedio-vestibular articulation, becomes to a corresponding degree anchylosed. Hence, the increased impairment of the hearing, which is apt to be a great disappointment to the patient.

ILLUSTRATIVE CASES.

GROUP I.—*Cases in which the persistence of the discharge is clearly due to a paretic condition of the blood-vessels of the middle ear. The different obstacles which have to be overcome in curing this paresis are also set forth in the accompanying histories.*

CASE XLV.—*Chronic discharge of an odorless fluid from the middle ear through a small perforation in the tympanic membrane; prompt and complete cure of the discharge through the local employment of vaso-motor stimulants.*

Male, thirty-six years of age. First seen on December 11, 1881. History: Intermittent discharge from one ear for years past; also a sufferer from naso-pharyngeal catarrh. Examination shows a moderate quantity of somewhat thin, purulent fluid in the canal, and a red and thickened membrana tympani, perforated anteriorly and below. Treatment: Systematic douching of the affected ear with hot water; tri-weekly applications of a solution of silver nitrate (20 gr. to the ounce) to the vault of the pharynx; and the occasional forcing of a weak solution of the same through the perforation into the middle ear and Eustachian tube. The discharge was arrested in about ten days, and by January 4, 1882, the perforation had entirely healed.

Comments.—The prompt and very satisfactory results of the treatment adopted show almost conclusively that the main and practically the only lesion which it was necessary to combat in this case was a chronic vaso-motor paresis of the blood-vessels of the tympanum and Eustachian tube; and that the condition of the vault of the pharynx contributed largely to the perpetuation of this lesion and of the resulting discharge. Indeed, in not a few instances the only treatment which I have adopted—aside from the douching—has been that which was directed to the vault of the pharynx, and, nevertheless, the results have been almost as favorable as they were in the case just recited.

CASE XLVI.—*Acute inflammation of the tympanic cavity, followed by a muco-purulent discharge through a small perforation in the membrana tympani; the employment of local vaso-motor stimulation proved unsuccessful until special means were adopted for bringing the remedial solution thoroughly into contact with the affected mucous membrane.*

The patient, a clerk, about thirty-five years of age, and in good general health, was brought to me by his physician on the twentieth day of October, 1879. The story which he gave of his ear trouble was this: About the first of October he was struck on the left side of the head, and for nearly a week afterward he experienced severe pain in the left ear. On or about the fourth day he discovered that pus was escaping from the left auditory canal, and from that time forward the discharge had been constant. On examination, I found the left external meatus filled with a thick, purulent fluid. A per-

fectly circular perforation occupied the posterior inferior quadrant. It presented no resemblance whatever to a perforation of traumatic origin, *i.e.*, due to the violent concussion of the air in the meatus. In all other parts the membrana tympani presented a very white and tough appearance.

So far as I could judge, the probable facts in this case were these: The patient, at some earlier period of his life, had been subject for a long time to a purulent inflammation of the left middle ear, and both the perforation and the marked hypertrophy of the tympanic membrane were the results of that earlier inflammation; while the blow which he had recently received had merely brought on a somewhat severe otitis media purulenta acuta. From the patient, however, I was unable to obtain any evidence corroborative of this view of the case. He was positive that the ear had always been perfectly healthy before he had received the blow.

I advised the attending physician to instil (three times a week) a five-grain solution of nitrate of silver into the external meatus, after he had thoroughly removed all the pus, and then to force it through the perforation into the middle ear in the manner described above. I then performed the operation once in his presence, in order that he might see exactly how the treatment was to be carried out.

On the 9th of November the physician brought his patient to see me a second time. He reported that the discharge had increased rather than diminished. On questioning the patient I ascertained that he had not once tasted the silver solution since the day on which I first saw him; in other words, it is fair to assume that the remedial solution had only on that occasion been successfully brought in contact with the tympanic mucous membrane. This plan of treatment having failed, I resorted to the use of the pipette, and introduced two or three drops of a ten-grain solution of nitrate of silver into the tympanic cavity. The patient felt it in his naso-pharyngeal space almost instantly. He also experienced quite a sharp earache, which was relieved, in about one minute, by pouring rather hot water into the upturned meatus.

On the 11th and 13th of November the remedy was again introduced into the middle ear in the same manner, and on the 15th the patient reported that there had been no discharge during the previous forty-eight hours. Inspection of the parts also showed that the discharge had entirely ceased, and that even the tympanic cavity was free from unnatural secretion.

On the 9th of January, 1880, the patient consulted me again. He stated that about five days after I last saw him the discharge had reappeared, and had been constant since that time. He had been too much occupied with his business affairs, however, to place himself again under medical care. The same plan of treatment (with the pipette) was resumed.

January 11th.—Discharge still active. Silver solution introduced a second time.

January 14th.—No improvement perceptible. The thought then occurred to me that my lack of success was probably due to the fact that the remedial solution did not come in contact with more than a comparatively small portion of the tympanic mucous membrane, owing partly to the imperfect manner in which I cleansed the cavity of the middle-ear, and partly to the small quantity of the remedial solution injected. I accordingly syringed out the tympanum with Blake's middle-ear syringe, using the entire contents of a

full syringe (a little over one drachm) for that purpose. So far as I could discover, this procedure brought away only a little ropy mucus. I then injected into the middle ear two or three drops of a ten-grain solution of nitrate of silver, and, after the lapse of a few minutes, no pain having developed in the mean time, I repeated the operation, each time causing the solution to pass through the Eustachian tube into the naso-pharynx.

The patient returned on the 17th of January and reported that the discharge had entirely ceased. Inspection also confirmed this statement. Before dismissing the patient, however, I introduced into the left tympanic cavity, by means of the slender middle-ear probe, two or three pellets of powdered iodoform and burned alum, in equal parts. About six weeks later he reported that up to that time no relapse had occurred.

Comments.—This case is particularly interesting in that it shows how the presence of a little mucus in the tympanic cavity may suffice to prevent the silver solution from accomplishing those vaso-motor stimulant effects which it indisputably possesses.

CASE XLVII.—*Subacute inflammation of the middle ear, with an exudation of a serous character into the tympanum; paracentesis, and intratympanic injection of a weak silver-nitrate solution; later, powdered burned alum introduced into tympanum through the artificial opening; prompt recovery.*

The patient, a man forty years of age, and in good general health, stated that in boyhood he had passed through an attack of scarlet fever, which left him with both ears damaged. At long intervals he had had a discharge from the right ear, and recently he had also noticed a sense of fulness in the left ear, and at times a slight watery discharge from it. On examination (December 27th, 1879), I found the left meatus moistened with a thin, watery discharge, and the membrana tympani somewhat bulging and decidedly soaked in appearance. No perforation was visible, but probably a small, valve-like opening existed in the posterior half of the membrane. When Valsalva's experiment was performed by the patient, the membrana tympani yielded as a whole to the pressure from within, but there was no escape of fluid to indicate the location of the perforation. In order to gain free access to the tympanic cavity I made a long incision through the bulging posterior half of the membrane, and afforded escape to some pinkish serum. Although the pressure had been withdrawn, the posterior half of the membrane retained its convex condition, showing clearly that the pressure from within must have been of comparatively long standing. Without any preliminary washing-out procedures, I introduced, with the pipette, two or three drops of a two-grain solution of nitrate of silver into the middle ear. No unpleasant symptoms followed.

On the 28th of December, the discharge still continuing, and the opening in the membrane still being of ample size, I introduced a five-grain solution into the tympanic cavity. None of it appeared to reach the naso-pharynx in the ordinary manner, but yet, almost instantly after the injection had been made, tears began to flow freely from the patient's left eye, and for perhaps two or three minutes he experienced quite a sharp pain in the ear.

On the 30th of December the patient reported that the discharge had diminished in quantity and that the ear felt lighter (*i.e.*, less full). On examination I found that the lower wall of the meatus was barely moist, and that the posterior half of the drum-membrane had almost entirely lost its unnatural convexity. The perforation had nearly healed. After clearing out the middle ear by means of Politzer's method of inflation, I injected into the tympanum, by means of the pipette, a much larger quantity of the silver solution (five grains to the ounce) than I had ever injected before. It amounted to at least ten drops, and, as the perforation was then quite small, no regurgitation took place, as on the previous occasion. Tears at once came into the left eye, and for some minutes the patient was unable to utter a word, so much of the solution had escaped into his throat. A watery fluid ran for a short time in an almost continuous stream from the left nasal orifice. The pain in the ear was quite sharp, but it yielded very quickly to instillations of hot water.

On the 2d of January I found that the discharge from the ear had almost ceased. As there seemed to be no free fluid in the middle ear, I forced through the perforation, into the tympanic cavity, a few small pellets of powdered iodoform and burned alum.

January 4th.—Same condition. Iodoform and alum introduced a second time.

On the 8th of January the patient reported that the discharge had not reappeared since the 4th inst. On inspection I found the membrana tympani pale, dry, and of perfectly natural curvature. A small scab covered the site of the perforation. The hearing distance for the watch had increased from two inches up to nine inches. So far as conversation was concerned, the patient experienced no difficulty whatever in hearing all that was said to him.

CASE XLVIII.—*Subacute chronic inflammation of the middle ears, with marked implication of the Eustachian tubes; successful results from the employment of intratympanic injections of a fairly strong silver-nitrate solution.*

The patient, a college student, seventeen years of age, and of good physique, consulted me on the 16th of September, 1878, on account of a discharge from both ears, associated at times with pain. So far as he could remember, the discharge began during his childhood, and had continued without intermission up to that time. On one or two occasions he had found the secretion slightly stained with blood. Furthermore, the discharge varied in activity, at times being barely perceptible. During the period immediately preceding his visit, however, it had been more profuse than usual. On examination I found both auditory canals filled with thick muco-pus. Both drum-membranes presented the same lesions, viz., a small round perforation in the posterior inferior quadrant, marked bulging of the posterior half, a generally tough and soaked appearance of the whole membrane, and, finally, entire absence of any evidence of active irritation. The most urgent indication on both sides, therefore, was to establish a free outlet, and thus to relieve the constant condition of pressure upon the mucous membrane of the middle ear and the constant partial stagnation of the purulent secretion. I therefore made a long, crescent-shaped incision in the posterior half of each drum-membrane, and after removing as much of the fluid contents of the middle

ear as I could. I injected several drops of a ten-grain solution of nitrate of silver.

On the following day, the 17th, the patient reported that the discharge had diminished noticeably in quantity, especially on the left side. He had also experienced no pain since the operation. On inspection I found that the edges of the cut, in both drum-membranes, were somewhat red and swollen.

On the 18th I repeated the injections, using on both sides a forty-five-grain solution of nitrate of silver. Very little pain followed.

On the 19th I found that the discharge was very trifling. I therefore pushed a few pellets of powdered iodoform ($\frac{1}{3}$) and burned alum ($\frac{2}{3}$) through the perforation into the tympanic cavity.

On the 20th I repeated this procedure.

On the 23d the patient reported that he had been entirely free from discharge since the 20th, and on examination I found the parts almost perfectly dry. As the patient was anxious to return on that day to his home in Michigan, I was unable to keep the case any longer under observation. I have very little doubt, however, that what was then an apparent cure proved to be a permanent one.

Comments.—I am unable at the present time—twenty years after writing the preceding record in my case-book—to state positively what was the motive which led me to employ so strong a silver solution as one of 45 grains to the ounce. It is not unlikely that I introduced only a small quantity of the remedy into the tympanic cavity, and that the comparatively large size of the opening in the membrane rendered it unlikely that any considerable quantity of the fluid would find its way along the Eustachian tube into the nasal cavities. In the preceding case (Case XLVII.), as may have been remarked, the patient experienced considerable discomfort when the much weaker solution (5 grains to the ounce) came in contact with the nasal mucous membrane.[1]

Case XLIX.—*Chronic subacute inflammation of the middle ear (chiefly of the Eustachian tube), relieved by a single application of silver nitrate, in the form of a bead, to the tympanic mouth of the tube.*

The patient, a child, six years of age, had been subject since infancy to a slight watery discharge from the left ear, the result of an attack of measles. On examination (October 11th, 1876) I found a moderate amount of thin, purulent secretion in the left meatus. The membrana tympani showed no evidences of active inflammation, but a small circular perforation occupied the anterior inferior quadrant. After drying the parts as thoroughly as I could, I introduced the end of the middle-ear probe, on which a bead of nitrate of silver

[1] In one case, in which I yielded to the temptation to use a solution containing 120 grains of silver nitrate to the ounce, the remedy passed through the Eustachian tube, and speedily gave rise both to a severe earache and to nose-bleed.

had been fused, into the middle ear through the perforation I pressed it for an instant against the mucous membrane near the orifice of the Eustachian tube, and then quickly withdrew it. The child made no complaint of pain afterward.

On the 14th of October the mother reported that no discharge had been seen since the 11th, and that the child's hearing had appreciably improved. Inspection showed the parts to be perfectly dry. (The further history of this case is not known to me.)

Comments.—Although the plan of treatment adopted gave very satisfactory results in this particular case, I have, in one or two instances, found it to be altogether too violent a procedure. If the bead be applied in a strictly touch-and-go manner, the effect is likely to be good; but if one happens to hold it for too long a time in contact with the mucous membrane, a very painful reaction may be the result. On the whole, therefore, I prefer not to commend this manner of using silver nitrate.

Still another thought occurs to me in connection with this case. Is it not likely that the real cause of this long-continued discharge was something quite different from what I then believed it to be? At the present time, if a case exactly similar to this one were to come under my observation, I should confidently expect to find the real cause of the long-standing discharge to be a well-marked hypertrophy of Luschka's tonsil; and I should also not be surprised if, upon the removal of the hypertrophied lymphoid tissue, the discharge were to cease spontaneously without the aid of silver nitrate in any form.

GROUP II.—*Cases in which there is no demonstrable bone caries in the middle ear; the odorless discharge being kept up, apparently, by the presence of a polypoid growth in the tympanum.*

CASE L.—*Otorrhœa of many years' standing; polypoid granulations near entrance to antrum; no demonstrable bone-caries; total destruction of the membrana tympani and its almost complete reproduction as a result of treatment.*

The patient, a strong, healthy boy, seven years of age, was brought to me by his mother on the 3d of October, 1872. She stated that he had had a constant discharge from the right ear since early infancy. On examination, I found the meatus partially filled with pus. The membrana tympani had been totally destroyed. All that remained of the handle of the hammer was a mere stump, which projected into the cavity of the tympanum. The mucous membrane covering the promontory was much hypertrophied, and at two or three points it presented small knobs of granulation-tissue. From the posterior and upper portion of the tympanic cavity a polypoid growth sprang. It was of moderate size, and its peduncle was comparatively small. By means of Blake's snare I removed this growth without any difficulty. To

the stump, and to the remaining smaller knobs on the promontory I applied powdered burned alum. My instructions to the mother were, that she was not to syringe the ear with lukewarm water until the discharge reappeared—my object being to keep the alum in contact with the granulating surfaces as long as possible.

Failing to arrest the discharge entirely by means of these applications of powdered burned alum, on the 15th of October I applied the liquor ferri subsulphatis, on a small pledget of cotton, to the base of the polypoid growth, and touched the granulating spots on the promontory in the same manner with a forty-five-grain solution of nitrate of silver.

On the 21st of October I applied powdered burned alum again, the discharge having in the mean time almost ceased.

On the 24th of October I found the parts perfectly dry and quite natural in appearance.

On the 19th of January, 1880, more than seven years later, I had an opportunity of examining the ear again. To my great surprise the drum-membrane had been almost entirely reproduced. Posteriorly and superiorly a small gap still remained, but everywhere else a very thin and very much depressed membrane separated the cavity of the tympanum from that of the external meatus.

Comments.—So far as the size of these cicatricial reproductions of the membrana tympani is concerned, I may say that in this respect there is practically no limit to the reproductive powers of the membrane. The substantia propria, it is true, seems to possess extremely little regenerative power. On the other hand, the dermoid and mucous surfaces possess this power to an amazing extent. In one of my cases exactly one-half of the drum membrane was cicatricial, viz., the posterior half. The dividing-line between the original membrane and that which had been reproduced was very sharply drawn. The elastic nature of this cicatricial half manifested itself in a striking manner when I made an incision in it—the lips of the wound instantly gaping widely apart as the tissues were divided.

On looking over my memoranda I find that I have records of four other cases in which a cicatricial reproduction of the entire membrana tympani took place. (The details are given on pp. 284 and 285 of the preceding edition of this treatise.)

Case LI.—*Polypoid growth of inner wall of tympanum; fusion of the stump with the inner surface of the membrana tympani and with a newly formed cicatrix; ultimately, firm binding down of this membrane to the promontory.*

The patient, a girl six years of age, was brought to me by her mother on the 17th of July, 1879. About five months previously, as I was told, she had passed through quite a severe attack of scarlet fever, which left her with a double otorrhœa. On examination I found the left drum-membrane destroyed, and the mucous membrane of the middle ear in a granulating condition. The

hearing-power of this ear was still quite good. On the right side I found the inner end of the meatus filled with a soft, polypoid growth, which concealed the deeper parts of the ear. By aid of the snare I removed the greater part of this polypus. I found that it sprang from some portion of the mucous membrane of the middle ear, and that its peduncle emerged through a circular perforation (about two millimetres in diameter), in the membrana tympani, just below the tip of the handle of the hammer, and then branched out into two distinct lobes, which together formed a mass about as large as a large pea. Assuming that the growth sprang from the upper portion of the tympanic cavity posteriorly, I gave the wire loop such an inclination to the silver cannula that I was able to remove all visible portions of the polypoid growth. In other words, so far as I could see through the perforation into the cavity of the tympanum, every trace of the polypoid growth had been excised.

On the 4th of August, the patient having returned from the country, I examined the ear again, and found that a dry, cicatricial membrane had grown over the former opening in the drum-membrane. On touching this cicatricial portion, however, with the probe, I was surprised to find that it offered the same degree of resistance that one would expect to find in a moderately tough polypoid growth. No appreciable improvement had taken place in the hearing.

On the 6th of August, that is, about forty-eight hours later, I was astonished to find in the place of the cicatricial membrane a moist, succulent, but not granulating surface. My interpretation of this apparently sudden change was this: The slow growth of the intratympanic polypoid mass, and the unusually slight quantity of pus formed during the growing process, had allowed the perforation an opportunity to heal by the formation of a cicatricial membrane. Then the increasing pressure from within, exerted by the growing tumor upon the thin cicatricial membrane, had caused the two to unite into one continuous mass of tissue, and as a result of this union the outer cicatricial portion had assumed some of the characteristics of granulation-tissue. Already on the 4th, when I examined the ear, the polypoid growth had reached the plane of the cicatricial membrane, and communicated to it that semi-solid condition which puzzled me not a little at the time; but it was not until the 6th that the union had become sufficiently intimate for the latter membrane to assume some of the characteristics of the deeper growth.

The child returned with her parents on the 6th to their home in Nebraska, and I did not see her again until the 5th of December, 1879. The discharge had reappeared in the right ear during this interval, and had become quite abundant. On examination I found that the appearances presented by the right membrana tympani had changed very materially. In the first place, the membrane as a whole had been drawn inward beyond the position which it had previously occupied. Quite low down anteriorly there was a very small perforation. Touching different parts of the membrane gently with the probe, I found that it offered solid resistance throughout the central portion; in other words, it had become amalgamated with the mucous membrane of the inner wall of the cavity. While at all other points the drum-membrane presented a pale and tough appearance, that portion which corresponded to the former cicatrix was of a pale purplish hue, and perhaps a trifle more con-

cave than the surrounding portions. So far as I could ascertain, the Eustachian tube was impervious to air. For the purpose of arresting the discharge, I injected into the middle ear daily, for four or five days, a five-grain solution of nitrate of silver, by means of the middle-ear pipette. Under this plan of treatment the discharge ceased on the fourth or fifth day.

On the 15th of January, 1880, I found the right drum-membrane perfectly dry and free from any evidence of active irritation. A very minute perforation still remained in the anterior inferior quadrant. In front of the perforation, and also posteriorly near the periphery, the membrane seemed, when I pressed upon it with the end of the probe, to be free. All the intervening central portion, however, appeared to be solidly amalgamated with the mucous membrane of the opposite wall. As no discharge had made its appearance for several weeks, I allowed the patient to return home.

CASE LII.—*Chronic subacute inflammation of the tympanic mucous membrane, with development of a polypoid growth on the floor of the tympanum; excision of a part of the membrana tympani and removal of the polypoid growth thus fully exposed to view; arrest of the discharge.*

Male, thirty-four years old, healthy. January 30th, 1892. Suppurative disease of left middle ear in childhood. Then followed a long period of freedom from discharge. Recently an attack of moderately severe pain, followed by a free escape of blood, and then by a return of the discharge. Present condition: anterior superior quadrant of left membrana tympani destroyed; just above the lower margin of the perforation, and within the tympanic cavity, the surface of what seems to be a granulation-growth is visible. I excised a portion of the tympanic membrane (the dotted line in Fig. 92 indicates the limits of the excised piece), and was thus enabled to remove the polypoid mass which sprang from the floor of the tympanum. No bare bone discovered. On November 8th, 1895, I found that a cicatrix had developed in the place of the excised part of the tympanic membrane. No granulation-tissue discoverable at any point. No actual discharge, but yet there is more than the natural amount of secretion in the tympanum.

FIG. 92.

GROUP III.—*Cases in which the continuance of the discharge seems to be due in part to a proliferative process in some portion of the tympanic mucous membrane, and in part to a limited caries of the bony walls of the tympanum.*

CASE LIII.—*Chronic intermittent otorrhœa, dependent upon caries of the bony floor of the tympanum, and associated with an abundant growth of granulation-tissue in the neighborhood of the carious bone; partial removal of the granulations and arrest—probably only for a short time—of the discharge.*

Male, forty-eight years old, healthy. December 12th, 1896. Discharge from left ear intermittingly for many years past. Present condition: tympanic membrane entirely destroyed, the manubrium mallei alone remaining; an irregularly shaped mass of tolerably firm granulation-tissue occupies the

larger part of the floor of the tympanum; scanty amount of an odorless secretion. No exposed bone detected at this time. In two sittings, with an interval of three days between the two, I succeeded in removing, with a Blake's snare, all that portion of the growth which was visible; but on exploring the floor of the tympanum with the bent probe, after the mass had apparently all been removed, I discovered that it sprung from the bottom of a deep excavation situated in the floor of the tympanum posteriorly, and that the adjoining bone was bare and rough. By aid of the curette I was able to remove a considerable portion of the concealed peduncle, but probably not all of it. The proximity of the carotid canal and my inability to obtain a view of the excavation made me hesitate about completing the task in a more thorough fashion; I simply filled the excavation with powdered nosophen. What I had already done, however, proved to be sufficient to arrest all discharge, at least for a period of nearly one month. Since that time I have not seen the patient.

GROUP IV.—*Cases in which cheesy and epithelial products accumulate in the vault of the tympanum, undergo decomposition, and so contribute largely to a continuance of the discharge.*

CASE LIV.—*Chronic intermittent discharge from a tympanic cavity in the upper part of which cholesteatomatous material was firmly lodged; removal of polypoid granulations and excision of the malleus; thorough cleansing of the foul-smelling cavity; entire relief for a period of at least several months.*

Female, thirty years old, and in good health. January 14th, 1896. Intermittent discharge from, and frequent pain in, the right ear since early childhood. Present condition: the inner end of the external meatus is filled with polypoid granulations which seem to spring in part from the upper and posterior portion of the tympanic cavity, and also to a certain extent from the soft parts immediately surrounding the malleus. After these growths had been entirely removed with the snare, no difficulty was experienced in ascertaining that the greater part of the posterior half of the membrana tympani had been destroyed; that the anterior half was a very much thickened mass of tissue, in which the outlines of the malleus could not be distinguished; that a great deal of foul-smelling, cheesy, and cast-off epithelial material was accumulated in the vault of the tympanum and possibly also in the mastoid antrum; and that apparently the ambos had already been cast out. Repeated attempts were made (at intervals of forty-eight hours) to remove the tightly packed material from the vault of the tympanum; the bent probe and injections of hydrogen dioxide being used for this purpose. But the opening was so narrow that I succeeded in removing only a small quantity at each sitting. In order to gain more room, therefore, I excised the malleus together with the greater part of the anterior half of the drum-membrane. (The pain caused by the operation was materially lessened by the employment of a 5-per-cent solution of cocaine.) From this time onward I secured much better results from my cleansing measures, and by the 9th of March I was able to dismiss the patient as apparently cured; that is, the discharge had entirely ceased, and the powdered nosophen which guarded the entrance to the tympanic vault was found to be perfectly dry after the lapse of several days.

In June, 1897, I had an opportunity of examining this ear again, and I found it still in a perfectly quiet and dry condition.

CASE LV.—*Suppurative inflammation of the middle ear of several years' duration; complete destruction of the membrana tympani; bone caries and foul smelling cheesy products in antrum and vault of tympanum; a cure effected by injections of hydrogen dioxide and the introduction of powdered nosophen.*

Female, thirteen years old, and in fair health. October 20, 1896. Scarlet fever at age of seven; afterward discharge from left ear, and considerable pain. Constant and somewhat abundant discharge up to the present time. Polypoid growth was removed in 1893. Of late the discharge has had a very foul odor, and the patient has complained of a good deal of pain in the region of the affected ear. Present condition: well-marked hypertrophy of the faucial tonsils; left meatus filled with thick and very foul pus; tympanic membrane destroyed; the entrance to the antrum blocked with a mass of very red granulation-tissue; bent probe encounters denuded and roughened bone in different directions; soft, cheesy material in vault of tympanum. Treatment advised: removal of the tympanic granulations and the faucial tonsils; bi-daily douching with an Angelo's ear-douche and boiled water; and tri-weekly injections of hydrogen dioxide into vault of tympanum and in the direction of the mastoid antrum. At the same time the parents were warned that if these measures failed to control the discharge and to relieve the pain, an operation upon the mastoid process would become necessary.

The treatment was carried out by my associate, Dr. Robert Lewis. The tonsils and the tympanic granulations were first removed on November 2d; and during the following six weeks the patient, who lived in the State of New Jersey, was seen only once a week. The discharge from the ear grew rapidly less in quantity and soon lost its foul odor; the pain also soon disappeared; and by the end of December Dr. Lewis was able to discharge the case as cured; the nosophen powder which had been applied as freely as possible to the tympanic vault and entrance to the antrum being then found in a perfectly dry state. No relapse has occurred since that date.

CASE LVI.—*A collection of cholesteatomatous material in the antrum and vault of the tympanum; limited area of bone caries at the lower margin of entrance to the antrum; systematic employment of hydrogen dioxide and nosophen; cure effected after persistent treatment throughout a period of several months.*

Female, forty-five years of age, and in fair health. January 8th, 1896. Slight discharge from the right ear for many years past. Recently a good deal of vertigo, and some pain throughout the right side of the head. Present condition of the ear: Lower half of the membrana tympani rests like a lean-to against the inner wall of the cavity; upper half destroyed, with the exception of a stump of the hammer; ambos apparently gone; vault of tympanum and entrance to antrum filled with desquamated epithelium and cheesy material; granulation-tissue springs from region of annulus tympanicus, posteriorly and superiorly, and also from a point just beneath the entrance to the antrum. The granulation-growths and the main portion of the mass in the vault of the tympanum were removed on the occasion of the first visit. The subsequent treatment consisted in tri-weekly injections of the hydrogen

dioxide, and applications of powdered dermatol to the affected mucous membrane. These were carried out faithfully by the attending physician, and with fairly satisfactory results.

At the end of a few weeks I discovered the existence of a pocket-like excavation in the bone just below the entrance to the antrum. It was filled with granulation-tissue, and its inner wall must have been in very close proximity to the facial nerve, which passes directly downward, through this part of the bone, on its way to the stylo-mastoid opening. An occasional cauterization of the granulation-tissue in this pocket was resorted to, if I remember rightly; but otherwise no active efforts were made to destroy it. The other procedures, however, were carried out with painstaking care by the regular medical attendant for a period of several months; the intervals between the visits being made longer as the improvement became more pronounced. Finally, in the summer of 1897 it was found that the discharge had absolutely ceased, and that, at all the points where previously there had been an active growth of granulation-tissue, there was then a smooth covering of a dry, parchment-like epidermal film. Even at the pocket-like depression the soft tissues showed no tendency to grow or to furnish any appreciable secretion, and I have no doubt that eventually healing will also occur at this spot.

If one can judge correctly from the published reports of many of the best authorities, the mastoid antrum is the most frequent starting-point of such desquamative processes.[1] This statement is, I believe, in the main correct. The cases, however, in which the accumulation takes place in some other portion of the tympanic vault are quite numerous. In rare cases we may find a very large mass of desquamated epithelium packed tightly behind the skin lining the external meatus. As an instance of such an exceptional course of the disease, I will narrate the following case:

Case LVII.—*Intermittent discharge from the ear due to the presence of a large cholesteatomatous mass behind the posterior cutaneous wall of the external auditory canal; limited area of bone caries; partial cure effected.*

The patient, a strong, healthy man, twenty-five years of age, had been subject to frequent earaches and to an occasional discharge from both ears since childhood. During the last three weeks of September, 1875, he had experienced constant pain in the left ear. When I examined his ear on the 1st of October, 1875, I found the external auditory canal blocked up with a red, fleshy mass, which sprang from the upper wall of the canal. The most prominent portion, which looked like ordinary granulation-tissue, was removed with the snare, and then it was ascertained that the fleshy mass which blocked the entrance of the external auditory canal was really the prolapsed

[1] Consult Von Troeltsch (Arch. f. Ohr., IV., p. 105); Toynbee (Medico-chirurg. Trans., vol. xlv.); Lucae (Arch. f. Ohr., VII., p. 255); Duncanson (Edinb. Med. Jour., Nov., 1877); Matthewson (Trans. Amer. Otol. Soc., 1878); Moos (Archives of Ophthal. and Otol., III., No. 2), and Kipp (Archives of Ophthal. and Otol.).

upper cutaneous wall, in which an opening had established itself. A probe introduced into this opening could readily be passed in to a distance of fully three-fifths of an inch, without encountering at any point denuded bone. Considerable cheesy and very foul pus was removed from the contracted meatus, but no view could be obtained of the deeper parts, owing to the fact that the prolapse of the upper cutaneous wall of the canal extended inward as far, apparently, as to the immediate vicinity of the membrana tympani. As this prolapsed portion could not be lifted back to its natural position, it was evident that some substance (cheesy pus, as I suppose) had accumulated between it and the bony wall. For its removal I adapted a slender nozzle (diam. 1½ mm.) to an ordinary hard-rubber ear-syringe, interposing between it and the nozzle of the syringe a short bit of rubber tubing. This slender nozzle was introduced without any difficulty into the mouth of the sinus, and upon forcing in the warm water it was found that the greater part of it returned by the side of the nozzle, while the rest made its way through the sinus into the deeper parts of the ear, whence it escaped through the meatus proper. This procedure caused the patient not a little pain, and consequently could be repeated only a few times at a sitting. The first time (October 2d) almost nothing was brought away by the syringing, but on subsequent days the stream of water regularly brought away fragments of epithelial laminæ of the most perfect whiteness. The bent forceps was also frequently used in dislodging the larger masses, which were too large to pass through the orifice of the sinus except with the aid of some tractile force. On October 10th (the syringe having been used daily in the mean time) the last fragment was dislodged. The total amount of epithelium removed was sufficient to fill a two-drachm bottle (no force being used to pack the substance into small compass). A microscopic examination revealed the presence of a few crystals of cholesterine in addition to the lamellæ of large, polygonal, perfectly transparent, sharply outlined epithelial cells. From day to day, as the accumulation of epithelium became reduced in quantity, the calibre of the external auditory canal grew steadily larger, until, on the 11th of October, I was able to ascertain quite accurately by inspection the condition of the middle ear and deeper portion of the meatus. There was at the same time a very perceptible improvement in the hearing. After the last mass of epithelium had been removed, the probe introduced into the sinus encountered roughened bone surface at the point where the posterior wall of the meatus becomes the outer surface of the mastoid process. Farther inward, however, the end of the probe passed over a series of small, smooth hummocks, which conveyed to my mind the impression of being the exposed septa of the mastoid cells (the solid bone composing the posterior and upper wall of the meatus having been destroyed by caries—or possibly by pressure). At the farther end of the sinus, and encroaching slightly upon the posterior fold, was a second opening (in the cutaneous wall), which communicated with the inner end of the meatus, and was fringed like the outer one with granulation-tissue. Upon the removal of the granulations with the snare, the membrana tympani could be seen. It was still entire, but amalgamated at almost every point with the tissues of the inner wall of the tympanum. In the posterior upper portion, and in one or two places below, the membrane was still free. There was no swelling or tenderness over the left mastoid process. (I can give no further

details in regard to the progress of this case, as the patient soon afterward passed from under my observation.)

Comments.—It is not easy to build up any theory that will satisfactorily explain all the aspects of this unusual case. Originally there was probably a severe inflammation of the middle ear, which, not finding a free escape for its products through the membrana tympani—that membrane probably being more resistant than usual—extended to the mastoid cells. From this resulted in course of time a caries of that portion of the mastoid process which forms the posterior and upper wall of the external auditory canal. A fistulous opening then established itself in the cutaneous wall of the canal, and, as it was of small size and probably from time to time became closed for a short time, the accumulating pus from the carious region must have dissected a way for itself in the direction of least resistance, that is, inward toward the posterior fold. At this point, too, the cutaneous wall is thinnest, and here it was that a second opening established itself. As the mastoid cells were found to be exposed over quite an extent, without at the same time being carious (a condition which I will not venture to explain), it is fair to assume that the immense mass of epithelium found in this situation must have been cast off from the mucous membrane lining these cells, cheesy and foul pus having originally supplied the necessary irritating stimulus.

In rare cases we may encounter such laminated masses of epithelium in a middle ear which presents no evidence of being the seat of a carious process. Thus, for example, in February, 1878, I was consulted by a gentleman, who stated that since boyhood he had been affected with occasional but very slight discharge from both ears. On examination I found in the left ear a fistulous opening in the anterior fold, and a small perforation in the posterior inferior quadrant. In the right ear I found a little watery secretion in the meatus, and an opaque and tough-looking membrana tympani, which at first sight appeared to be entire. On more careful inspection, however, I discovered a linear, slit-shaped perforation, perhaps two millimetres in length, running parallel with and close to the posterior periphery of the membrane. When the patient performed Valsalva's experiment, the entire drum-membrane yielded to the pressure from within, just as an unbroken membrane would. From this behavior of the membrane I inferred that either a mass of mucus or a polypoid growth, acting like a valve, prevented the air from escaping through the perforation. I accordingly enlarged

the opening in the membrana tympani by making two incisions, one at each end of the perforation and at right angles to it. By these incisions I converted one lip of the opening into a rectangular flap, and so secured a broad outlet. Inflation by Politzer's method was then resorted to, and as a result a whitish mass, three-eighths of an inch long, two-eighths of an inch broad, and about one millimetre in thickness, was driven out into the external auditory canal. Under the microscope small fragments of this mass were found to consist solely of flattened epithelium (non-nucleated). The removal of this large mass from the cavity of the tympanum gave the patient marked relief from an annoying sense of fulness in the ear, and also materially improved his hearing, but did not entirely arrest the discharge. The patient remained under observation for about four days, and was then obliged to return to his home in Ohio. I heard from him, a few years later, to the effect that he had experienced no further trouble from this right ear; and in 1888 I had an opportunity of satisfying myself, by actual examination, that there was nothing left but a small cicatricial spot to indicate where previously there had been a perforation in the tympanic membrane.

This is perhaps the proper place in which to mention the fact that, in the cases which belong to this group, *living maggots*, the larvæ of the ordinary house-fly, are occasionally found in the meatus or even in the tympanic cavity. I have only once or twice encountered them in the ear, but they have been seen more frequently by Gruber,[1] Blake,[2] and others. The explanation usually given is this: the fly, attracted by the offensive odor of the discharge, deposits her eggs in the meatus near the external orifice; and in this decomposing fluid the eggs find a soil suitable for their development into living larvæ.

GROUP V.—*Cases in which larger portions of the temporal bone have been destroyed.*

In former years these cases were more common than they are at the present time. It is only when a severe attack of suppurative inflammation of the middle ear is allowed to run its course unchecked, or when inadequate therapeutic measures are adopted, that actual necrosis of the bone takes place. Under these circumstances a variety of defects may be encountered in the bony walls

[1] Monatsschrift für Ohrenheilkunde, III., 3, March, 1869; III., 4, April, 1869.

[2] Archives of Ophthalmology and Otology, II., 2, p. 37.

of the tympanum or of the external auditory canal. Thus, for example, on two occasions I have found the mucous membrane of the inner wall of the tympanic cavity very much thickened—so much so as to suggest the presence of a polypoid growth in the middle ear—and, when I manipulated it with the probe, I discovered that it hung down like a curtain or an apron over the promontory, and that its lower edge was much thickened. Every portion of this wall of bone appeared to be completely denuded of its mucous membrane (*i.e.*, of its periosteum), but it still retained its smoothness. In another case—that of a boy, seventeen years of age—I found all that part of the squamous portion of the temporal bone which separates the upper part of the tympanic cavity from the external auditory canal destroyed. The anterior and posterior folds were still intact, and so was the drum-membrane proper. The head of the hammer, however, with the exception of only its extreme upper portion, stood out prominently in the centre of the irregularly shaped excavation. The incus had evidently been destroyed. In two instances which I have reported in a later chapter, there was good reason to believe that all that mass of bone which is known as the tegmen tympani had been destroyed, and that the dura mater constituted the actual roof of the tympanum. Several cases have been reported[1] in which the labyrinthine portions of the petrous bone have come away as sequestra; and there is even one case on record where almost the entire temporal bone was cast off as the result of necrosis.[2]

In one case of chronic suppurative middle-ear disease which I saw about ten months ago, I found the cartilaginous portion of the auditory canal obliterated by the growing together of the opposite surfaces of skin. Quite near the external orifice, on the lower wall, a pouting orifice of a fistula was found, and it was through this channel that all the discharge escaped. A slightly bent probe introduced into the fistula encountered roughened bone at a depth of something more than one inch. So far as I could judge, this area of exposed bone was situated not far from the mastoid antrum. The patient, a young girl about fifteen years of age, seemed to suffer

[1] For instance, by Toynbee; by Schwartze (Arch. f. Ohr., IX., p. 238); by Dennert (*op. cit.*, X., p. 231, and XIII., p. 19); by Lucae (*ibid.*, p. 236); by Agnew (American Med. Times, vol. vi., No. 16); by Pomeroy (Transactions of the American Otological Society, 1872), and by Spencer (Transactions Missouri Medical Association, 1875).

[2] Dr. J. Gottstein: Archiv für Ohrenheilkunde, Bd. XVI., Heft 1 and 2.

no inconvenience from this badly drained focus of bone disease, and the parents were not at all disposed to give their consent to operative interference. Three or four weeks later, the whole region surrounding this ear became painful and swollen, and quite a large fragment of bone was cast out. A few days after this occurrence, the discharge ceased and the fistula closed; and from that time to the present the patient has experienced no further trouble from this ear.

POLYPOID GROWTHS.

Pathological Anatomy.—As regards the form, size, and structure of simple aural polypi, a few words will suffice. Their size varies from that of a pin's head to that of a large bean. In exceptional cases polypi as large as those shown in Fig. 93 are encountered, but the great majority of them are not larger than an ordinary-sized pea. As regards their shape, they are usually either spherical or bean-shaped, but not infrequently papillary or lobulated growths are met with. Nearly all middle-ear polypi, even the largest of them, possess relatively small peduncles. In their anatomical structure, the smaller and softer polypi are precisely like simple granulation-tissue. The larger growths, on the other hand, are sometimes quite firm in consistency—veritable fibrous polypi. A section of one of the softer growths—one in which the cellular elements predominate over the fibrous—is shown in the accompanying cut (Fig. 94), which has been kindly placed at my disposal by Dr. Gorham Bacon, of this city.

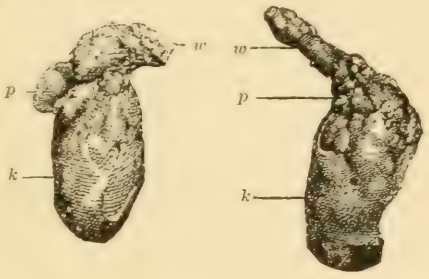

FIG. 93.—Aural Polypi. *w*, Root; *k*, body of polypus; *p*, round excrescences growing on polypus. Actual size. (After Politzer.)

Those middle-ear new-growths which may be classified as myxomata, angiomata, sarcomata, and carcinomata, shall receive due consideration further on (Chapter XVII.).

Etiology.—It may always be taken for granted that the presence of a polypoid growth in the middle ear signifies that, at the point from which it springs, some kind of irritant action is either still at work, or has been at work for a certain length of time at

some period of the past. So far as we can now judge, two conditions are competent to give rise to this irritant action, viz., a limited area of bone caries and a mass of decomposing cheesy material. It is a very common experience to find both of these conditions combined in one and the same case.

Diagnosis.—The determination of the precise nature of a polypus of the ear is rarely a matter of importance; the vast majority of these growths presenting gross physical characteristics which

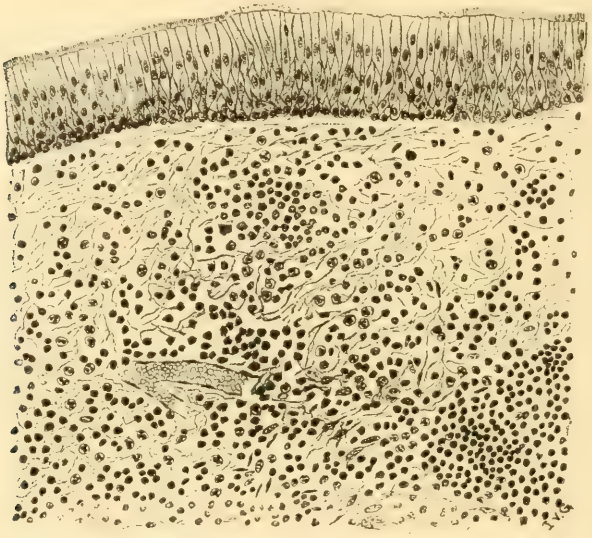

FIG. 94.—Cross Section of a Mucous Polypus, covered with ciliated cylindrical epithelium. (Drawn by Dr. Ira Van Gieson, from a specimen belonging to Dr. Gorham Bacon, of New York.)

stamp them at once as simple products of the proliferative activity imparted to the connective-tissue stratum of the mucous membrane. Our chief diagnostic task is to locate the starting-point of the new-growth, in order that we may, with the least loss of time and smallest discomfort to the patient, encircle its peduncle at this point with the wire loop of a Blake's snare. The two instruments which are best adapted to aid us in acquiring this knowledge are the slender middle-ear probe and the smallest size of smooth-edged, ring-shaped curette. Both of these instruments are described on pages 25 and 26.

Apropos of the subject of middle-ear polypi, I desire to warn the beginner that a growth of this kind—and sometimes a decidedly large one—may remain wholly concealed from view in the vault of

the tympanum or in an enlarged mastoid antrum, and that, too, notwithstanding the fact that its peduncle may be rooted in a portion of the tympanic mucous membrane which is barely out of sight (as at the lower margin of the entrance to the antrum). The possibility of something of this kind should be particularly borne in mind when our efforts to arrest a chronic discharge from the middle ear persistently fail of success.

Prognosis.—Although simple aural polypi, considered in their immediate relation to the patient's life and health, are perfectly harmless growths, they assume a more serious character when one reflects that even a small polypus may be large enough to block the entrance to the mastoid antrum, or the straits which separate the lower from the upper cavity of the tympanum, or the channel of some fistulous passage in the mastoid bone. How serious in its consequences such an obstruction may ultimately prove to be, has been already sufficiently set forth elsewhere in these pages.

The question in prognosis which interests us more directly, in the management of cases of chronic suppurative inflammation of the middle ear, is this: After a polypus has been removed, what are the chances that it will grow again? In reply to this question it may be said that if the growth be removed so thoroughly that the cut surface of the stump lies in the same plane as the surrounding fairly healthy mucous membrane, and if at the same time the source of the irritation which gave rise to the growth be also removed, a new polypus is not likely to grow up in the place of the original one. On the other hand, if the source of the irritation be permitted to remain, a new-growth will almost certainly develop from the stump of the old one; and occasionally—fortunately, not often—the seemingly thorough removal of the polypus and the arrest of the irritating discharge fail to stop the further sprouting of the stump. This occasional occurrence suggests the idea that after the tissues—as in the case of the stump of the polypus—have once acquired the habit of growing, of proliferating, they may, in exceptional instances, continue to manifest this habit spontaneously—that is, without the stimulus of an irritant operating from without.

The *treatment* of polypoid growths forms a part of the broader subject of treatment of chronic suppurative disease of the middle ear in general.

TREATMENT.

The measures which are required in the treatment of the uncomplicated vaso-motor paretic conditions which are sometimes found in cases of chronic suppurative disease of the middle ear have already been set forth in sufficient detail in a preceding chapter (Chapter X.). There remain, therefore, for our present consideration the following matters: the removal of a polypoid growth and the after-treatment of the stump; the removal of impacted masses of cast-off epithelium and cheesy débris; and the healing of areas of bone caries.

1. **Removal of a Polypoid Growth and the After-Treatment of the Stump.**—Very few surgeons at the present time advocate the removal of an aural polypus—*i.e.*, a growth of an appreciable size—by any other than mechanical means. If a large polypus fills the external auditory canal and presents itself within easy reach at the outer orifice, an ordinary dressing-forceps, or, better yet, Hinton's polypus-forceps, will serve the desired purpose as well as any other instrument with which I am acquainted. The mass is firmly grasped between the blades of the forceps, and is then separated from its deeper attachments by a combined rotary and pulling motion, or simply by direct traction. Further on, I will state under what circumstances traction is not to be employed. If the polypus, however, is situated more deeply in the canal, and reflected light is required to render the mass visible, such an instrument as Hinton's forceps—unless the canal happens to be unusually large—will be found awkward to manage, and productive of pain to the patient. Blake's snare[1] is the proper instrument to use under

[1] This instrument, which was introduced by Dr. Clarence Blake, of Boston, in 1869 or 1870, is sometimes spoken of as "Blake's modification of Wilde's snare." Those, however, who have compared the two instruments, and know from practical experience how different they are from each other, will agree with me that the more recent instrument is justly entitled to the name of "Blake's snare." In 1872 or 1873 the instrument was still further improved by the substitution of a simple cannula of soft (pure) silver for the double-mouthed steel or German-silver tube usually sold with the instrument. The pure silver cannula measures three inches (8 ctm.) in length and but one millimetre in diameter (externally) throughout its entire length (except where it fits into the handle), while the steel or German-silver one measures two millimetres in diameter, and at the flaring end over two and a half millimetres. In cases where the external auditory canal is narrow, or where it is found necessary to remove a polypus which is situated within the tympanic

these circumstances. By aid of the slender silver probe the physician can ascertain whether the mass grows from the cutaneous walls of the canal or from the middle ear or mastoid cells. Where the growth is of such a size as to fill the canal, it is not necessary that he should satisfy himself of the exact situation of the base of the polypus before applying the loop of wire. It is sufficient for him to ascertain by actual probing that he can pass his snare over the mass to a given depth (distance from the orifice of the meatus)

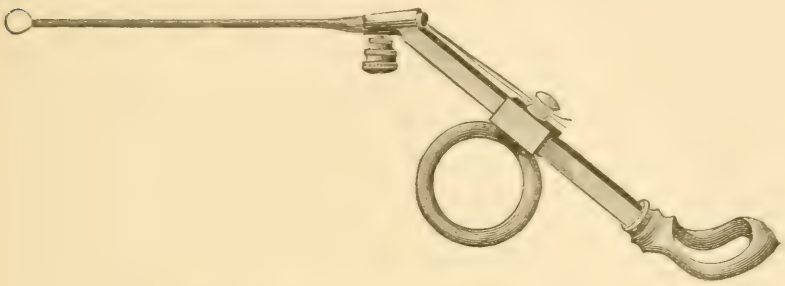

Fig. 95.—Blake's Polypus Snare. Actual size.

without encountering any obstacle. The loop is then to be pushed in over the mass to this depth and tightened sufficiently to hold the polypus firmly in its grasp. If the growth is succulent and not very firm, and especially if it can easily be rotated about its long

cavity and which can only be reached through a comparatively small perforation in the membrana tympani, the great advantage of the slender silver cannula is very apparent. But this is not the only advantage. In the double-mouthed cannula the wire does not cut entirely through the polypus; a slender connecting cord of tissue always remains uncut between the wire and the septum which separates the two mouths of the cannula. With this cannula, therefore, the last step of the operation always consists in the tearing asunder of this connecting bridge of tissue—a procedure necessarily more or less painful to the patient. In the simple silver cannula the wire, on being withdrawn into the tube, cuts the polypus off entirely at the point of seizure, all necessity for traction being thus done away with. As a result of this, the operation of removing a polypus from the ear is in very many cases an almost painless procedure. Finally, the employment of very fine malleable steel wire (size = No. 37) may be designated as the latest improvement which has been introduced in connection with Blake's snare. Wire of this size possesses all the strength required for the removal of the great majority of polypi, and at the same time causes far less pain to the patient, whenever it comes in contact with the healthy and very sensitive walls of the auditory canal or of the middle ear, than does the heavier wire hitherto commonly employed.

axis, steady traction should be made, in the hope of pulling out the polypus, peduncle and all. In not a few cases this object will be attained; but even if the effort fail to remove the entire growth, at least as much of the mass will be torn off as would have been if the wire had been made to cut through the polypus instead of simply grasping it firmly. If the growth is firm in texture and not easily rotated, it is better to use the loop simply as a means of cutting off portions of the growth. The same remark applies to the use of Hinton's polypus-forceps. Where the growth is firm in texture and firm in its deeper attachments, traction must not be employed. As soon as the bleeding has ceased, and the portion cut off by the wire loop has been removed with the bent forceps, the remainder of the growth is to be treated in precisely the same way as the first portion. The wire loop is to be applied again and again until the base of the growth has been cut away to the level of the surrounding mucous membrane or skin. If the polypoid mass springs from some portion of the external auditory canal, it will be found as a rule decidedly firmer in texture and more sensitive than one of middle-ear origin. It will also not possess the same degree of mobility as the latter. In polypi of middle-ear origin we shall find that they spring more frequently from the upper and posterior portion of the tympanum (entrance to the antrum) than from any other locality.

I do not know of any *accidents* which are likely to occur in the course of the operation of removing a polypoid growth from the ear. Serious bleeding is very rare. I can recall only one instance in which the hemorrhage that followed the removal of a growth from the middle ear was excessive and persistent. Firm plugging of the external auditory canal with cotton arrested the hemorrhage in this particular case, for the immediate moment; but I am unable to say anything about the exact source of the bleeding, or whether it returned at some later moment, for the patient did not afterward appear at the Infirmary. My impression at the time was, that the bony floor of the tympanum must have been in a carious condition, and that the traction exerted upon the peduncle of the polypus must have disturbed the carotid artery at some spot where its wall was eroded and ready to give way if sufficiently disturbed.

As regards the question of inflicting damage upon the apparatus of hearing in the middle ear, I have no doubt that clumsy and unskilful operative interference may result in serious impairment of the hearing. The malleus, however, and the firm ridge in which

Shrapnell's membrane is lodged, afford an excellent protection to the more deeply situated stirrup, which is by far the most important piece in the mechanism of the middle ear. Polypi are occasionally encountered whose peduncles include in their substance the handle of the malleus (the rest of the membrana tympani being destroyed). In such cases the wire should be applied with caution, and no traction whatever should be employed. The few polypi of this kind which have come under my observation were quite small, and were attached to the ossicle by rather slender peduncles. In two of these instances I managed to encircle the manubrium mallei—before I knew how it and the peduncle were related to each other—with my loop of wire, and was consequently unable to draw it back into the silver cannula. When this accident happens, the fastened ends of the wire should be loosened or cut, and traction should be made upon one of them. In this way it is an easy matter to extract the wire without doing any injury to the malleus. As a matter of fact, however, this ossicle is generally, under these circumstances, a perfectly useless and rigidly immovable object; and one need not, therefore, give one's self any special anxiety about its fate.

As to the *treatment of the stump* of the polypus, this must vary according to the spot from which it grows and also according to its length and texture. If the new-growth springs from the malleus or from the posterior end of the tympanum, no great difficulty will be experienced in excising it close to its very roots. The after-treatment of the stump will then amount to little or nothing. Thus, for example, it may be well to touch it firmly for an instant or two with a bead of silver nitrate fused upon the end of a probe; or, instead, a little burned alum may be applied to the cut surface. One thing, however, must always be borne in mind: silver nitrate may easily be applied too freely, and so may be made an agency for the promotion rather than the suppression of further growth. The proper handling of this drug is something which cannot be formulated in words. Every man must acquire this knowledge by experience. But if the growth originates from some spot which is fairly out of sight, we can scarcely avoid leaving a stump of unknown length; and under these circumstances we shall be obliged to omit all treatment of the stump *per se*.

Finally, in a few cases, the stump which remains after the operation presents a tissue which is unusually firm. If it be in a position where the glass porte-acid (see Fig. 96) can be used successfully, nitric acid (undiluted) is the safest and most effective de-

stroying agent that we can employ. Without the aid of the porte-acid it would be impossible to apply this powerful caustic only to the stump of the polypus; the dense fumes which instantly arise when the acid is introduced into the meatus would prevent us from seeing the object aimed at. This instrument (Fig. 96) consists of a slender glass tube (about ten centimetres in length, not quite two millimetres broad, and somewhat flaring at both ends), through which a platinum wire of moderately small size passes. One end of the wire is bent upon itself, so as to prevent the mop of cotton-wool, which is wound round it, from falling off. When the instrument is to be used, the wire should be first pushed into the tube far enough to carry the mop end of the wire well outside of the flaring end of the tube. The mop having been dipped into the acid, the other end of the wire is then to be pulled out far enough to draw the mop well back into the flaring mouth of the tube. The base of the growth having first been thoroughly dried, the flaring end of the tube should be placed firmly upon the raw surface, and, while it is in this position, the mop should be pushed down firmly for an instant against the part to be cauterized. The reaction which follows is very slight, and the pain is of but short duration. The best way to remove the mop from the platinum wire is to burn it off in the gas flame.

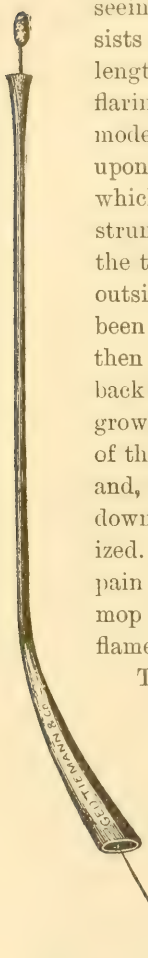

Fig. 96. — Glass "porte-acid" with platinum cotton-carrier passing through its interior. Full size.

There are various other caustics which have been employed at one time or another for the destruction of redundant tissues in the tympanum. The principal ones are acid nitrate of mercury, glacial acetic acid, sulphate of copper, and chromic acid. Acid nitrate of mercury is a very treacherous remedy; its penetrating power is so great that it destroys tissues at a considerable distance from those which are immediately touched by it. The same objection may be made against chromic acid when it is applied to the tissues in a crystalline state. In a fluid form, however, it can often be made to do excellent service; but even then great care must be exercised. My associate, Dr. Robert Lewis, Jr., has published in the New York *Medical Journal* for October 9, 1897 (and also in the Trans-

actions of the American Otological Society for the same year), an account of a case in which the employment of chromic acid upon the granulating edge of a perforation in the membrana tympani gave rise to a most extraordinary angeio-neurotic œdema of the tongue. There can be scarcely any doubt that this very rare phenomenon owed its origin to the damage done by the chromic acid to fibres of the chorda tympani nerve as it crosses the middle ear just behind (*i.e.*, upon the inner side of) the membrana tympani. The history of this remarkable case is here given in full:

"CASE LVIII.—*Dr. Lewis' case of angeio-neurotic œdema of the tongue, due to the application of chromic acid to the edges of a perforation in the tympanic membrane.*

Mrs. ———, of German birth, superintendent of one of our city hospitals, aged about forty-eight years, of average good health, not of a nervous temperament, certainly with no hysterical tendency, active, though weighing over one hundred and eighty pounds, consulted me about a year ago for a left chronic otitis media purulenta, which had existed for a number of years. She had been treated both here and in Germany a number of times, and this was an exacerbation of the disease, in character similar to a number of previous attacks; a muco-purulent discharge, slightly offensive, and a dull, evanescent pain being the only symptoms of which she complained. On examination, I found in the tympanic membrane, after cleansing the canal, a perforation about two by three millimetres in diameter, the superior margin of which was formed by the posterior fold, the anterior margin by the malleus handle, the posterior margin by the posterior edge of the annulus tympanicus. The opening was filled with granulation-tissue.

"Under cocaine anæsthesia, I removed, by curetting, as much of the granulation-tissue as possible, then cauterized the base with chromic acid, and ordered the patient to use a bichloride solution (1 to 6,000) as an aural douche three times daily, to be followed by the instillation of a few drops of a solution of fifty-per-cent alcohol (afterward increased to seventy-five per cent). Later, the solutions were stopped and insufflations of powdered aristol were used. Finally, after the third application of chromic acid, I did not see my patient professionally for some time; but when I did meet her casually she informed me that her ear was all right, but that during the night of the same day on which she made her last visit to my office her tongue became so swollen that she could hardly breathe for a few hours. I paid but little attention at the time to her account of this occurrence.

"About six months later, Mrs. ——— again visited my office, complaining of a renewal of the discharge. I found a little granulation-tissue present, and used the chromic acid as on the previous occasion. The next day I learned that, about twelve hours after I had made this application, her tongue began to swell very rapidly—indeed, so rapidly that in two hours she could not protrude it, nor could she shut her jaws; and the swollen parts interfered so markedly with her breathing that Dr. George F. Little, of the house staff, had seriously considered the advisability of performing a tracheotomy. Happily, by the administration of purgatives and by the local employment

of ice, tannic acid, and leeches (the latter applied near the angle of the jaw), about three hours after the œdema first showed itself the swelling began to subside, and within twenty-four hours after the application of the chromic acid the œdema had practically disappeared. Accompanying the glossal œdema and the œdema in the submaxillary region were small areas of œdema over the right frontal eminence, over the balls of both thumbs, over the internal malleolus of one ankle joint, and under the ball of the right foot. I also learned that the first attack which she had (to the recital of which I had paid so little attention) came on about the same length of time after my application of the acid, and followed about the same course as that which I have just described. Dr. Frederick J. Schoenberger attended her in the first attack, and also saw her during the second one, and found them in every way very similar. On the second occasion, thirty hours after she had visited my office, there was no evidence of abnormal irritation in or about the membrana tympani, the external auditory canal, the pharynx, or the buccal cavity.

"Both Dr. Beck and Dr. Collins of the visiting staff, who were informed of the symptoms on the next day, pronounced it to be, in their judgment, a case of angeio-neurotic œdema."

There are two other caustics which have sometimes been employed in the treatment of hypertrophic conditions in the ear, viz., sulphate of copper and acetic acid; but they do not appear to have given much satisfaction, as one rarely hears them mentioned at the present time.

2. **Removal of Impacted Masses of Cast-Off Epithelium and Cheesy Débris.**—The performance of this task constitutes by far the most important part of the treatment in the large majority of cases of chronic suppurative inflammation of the middle ear. The stagnation and the decomposition of the products of inflammation may be considered as the very fountain-head of the chronic discharge. When, therefore, we have once succeeded in removing all decomposing products from the recesses of the middle ear, and in destroying the bacteria which have given rise to this decomposition, we may confidently expect to see all discharge from the ear cease.

In a small number of cases the mere practice, on the part of the patient, of faithfully douching or syringing the ear once or twice a day, proves to be sufficient to accomplish the purpose desired. It is safe to assume that such a favorable result can only be attained when the processes of decomposition are confined to the lower part of the tympanic cavity—the only part that can be reached and effectively cleansed by the stream of water which escapes from the douche or syringe. In the majority of cases, however, the decomposing products are entirely out of the reach of any douche or syringe which the patient or ordinary unskilled attendant can use.

The vault of the tympanum and the mastoid antrum are the two regions in which this cleansing is generally needed, and, to reach these portions of the middle ear effectively, special procedures and instruments are necessary. In the first place, it is self-evident that the most effective way of removing the offending materials which are packed away in these two regions is to wash them out by means of a sufficiently strong stream of water or other fluid directed against them. But, before we can do this successfully, it is often necessary to overcome certain obstacles which stand in our way. The simplest problem of this character is that in which the posterior half, or at least the posterior superior quadrant, of the tympanic membrane and the entire ambos are destroyed, thus leaving us unimpeded access to the mouth of the antrum and the greater part of the vault of the tympanum. While our eyes cannot penetrate into this dark upper chamber, the suitably bent end of a slender probe can, and by its aid we may be able to ascertain whether the materials imprisoned there are of a soft nature, such as may be dislodged by a well-directed stream, or tough and firmly packed, requiring some degree of mechanical force to eject them. In the latter case the bent probe will be found a very efficient instrument for the accomplishment of this purpose; or, if the mass be so firmly attached to the surrounding walls that it cannot be loosened by the probe, we may use in its stead the smaller-sized steel curette, after we shall have given to its malleable shank the requisite degree of curvature. When a channel has once been effected through or on one side of the obstruction, it is a good plan to inject rather forcibly a few drops of hydrogen dioxide (3 per cent; U. S. Ph.) by means of the glass middle-ear pipette (see p. 324). Such an injection is made, at this stage of the work, not for any disinfecting purposes—although incidentally it will accomplish this also—but simply in order to obtain assistance from the dislodging power which its prompt conversion into bubbles of gas affords. In exceptional cases a single sitting may suffice to clear the vault of the tympanum of all offending materials, but as a rule the operations which I have just described must be repeated a number of times—sometimes for a period of several weeks—before the desired degree of cleansing and disinfection shall have been accomplished. And in carrying out this sort of work it is a good maxim not to attempt too much at one sitting. The cases which yield most quickly are those in which only cheesy and foul débris are accumulated in the vault. In these the injections of hydrogen dioxide very soon effect both a perfect

cleansing of the vault of all irritating products and a thorough destruction of the bacteria of decomposition which it may contain. From three to five injections at a sitting may be considered as a sufficient dose. The absence of effervescence in the escaping fluid may be taken as good evidence that a fairly complete disinfection has been effected. The parts are then to be dried, and small quantities of nosophen, aristol, or iodoform are then to be pushed up into the recently cleansed vault. In the earlier stages of this mode of treatment it is well to let the patient carry on systematic douching of the ear; but when the discharge has once been diminished in quantity to such an extent that it can no longer wash away the disinfectant powder which has been introduced into the vault, it is better to stop the douching altogether. The cleansings with hydrogen dioxide and the subsequent applications of the powder constitute, at this stage of the disease, all the treatment that is required.

In addition to the cases such as I have just described, there are some in which we cannot gain a sufficiently free access to the vault unless we excise a portion of the tympanic membrane. This is a very simple procedure, and calls for no special description or instructions. Then, again, there are still other cases in which, in order to gain the necessary amount of space, it is found desirable to excise both the malleus and the incus—or the malleus alone, if the incus, as is often the case, has already disappeared. This operation—termed an *ossiculectomy*—may, in certain cases, be performed simply by the aid of local cocaine anæsthesia; but, as a rule, it will be found better to administer a general anæsthetic. The steps of the operation are the following: The cutting away of any portions of the membrana tympani which may still adhere to the malleus and to the upper peripheral boundary; employment of the bent probe to ascertain whether the long process of the ambos is still attached to the head of the stapes; the separation of these two ossicles if they are found to be connected (in many cases they are not); the division of the fibres of the axis-band close to the neck of the malleus; and, finally, the wrenching away of this ossicle from its attachments, by means of a strong pair of forceps or by a strong wire loop (passed through the larger cannula of a Blake's snare). The incus usually comes away as soon as its chief support—the malleus—has been removed. The subsequent management of the case is precisely the same as that which I have already described above. It is scarcely necessary to add that in all our manipulations within the tympanic cavity the possibility of injuring the stapes—

and in this way diminishing the hearing power—must constantly be borne in mind. Under ordinarily careful manipulations the facial nerve is not at all likely to be injured.

It is not possible to lay down any very precise rules as to the degree of obstruction that must exist—or, rather, must appear to exist—in order to warrant surgical interference. In a number of instances I have said to myself, on the occasion of my first examination of the ear, that it would scarcely be possible, in this particular case, to effect a thorough cleansing of the vault without a preliminary removal of the posterior half of the tympanic membrane, or without an ossiculectomy. Nevertheless, the attempt was made in these cases to dispense with such operative interference, and in a fair proportion of them it was found that the obstacles were not sufficiently serious to prevent a successful result. A very striking instance of this character is under my care at the present moment:

Case LIX.—The patient, a man about fifty years of age, has had discharge (offensive in character) from the left ear since childhood. February 1st, 1898. The posterior half of the membrana tympani, very much thickened, is still *in situ*. My bent probe encounters denuded and roughened bone in the vicinity of the antrum. Simply foul pus is present, without any cheesy material. I have seen the patient only twice, and have injected the hydrogen dioxide four times at the first sitting and three times at the second. Nosophen powder employed. The offensive odor has now (February 8th) entirely disappeared, and, so far as I am able to judge at the present moment, the discharge has been completely arrested.

But when an attempt such as I have just described proves to be unsuccessful, the necessity for an ossiculectomy, or for the removal of the posterior half of the tympanic membrane, becomes perfectly clear.

Notwithstanding what I have said in the preceding paragraphs, I am quite willing to admit that in dispensary practice it may be wiser, in every case of the character which we are now considering, to proceed at once to the removal of the two obstructing ossicles and of the posterior half of the membrana tympani. In our large cities the dispensary surgeon is obliged to economize time, and to bear in mind that, as a rule, he will not be able to secure anything like regularity in attendance on the part of the patient.

3. Treatment of an Area of Bone Caries.—The measures which have been set forth in the preceding section are precisely those which are best adapted to effect a cure of a superficial bone caries. This lesion and the conditions discussed in that section are practi-

cally inseparable. A superficial bone caries in the middle ear is rarely, I believe, a factor of any very serious consequence, if we consider it by itself, apart from the conditions of stagnation and decomposition of pus. I base this belief upon the fact that whenever we succeed in thoroughly cleaning the surface of such a bone ulcer, and in shielding it for a short time (say for a few days) from the irritating influence of the bacteria of decomposition, it ceases to be anything but a passive, a harmless defect. Those cases which seem to be exceptions to the rule just stated are doubtless cases of more profound involvement of the bone—cases in which more radical measures (than mere cleansing and superficial disinfection) are required for the complete destruction of the bacteria of decomposition. Scraping of the surface of the diseased bone with a sharp-edged instrument or actual ablation of a considerable mass of the part affected will alone suffice to effect this purpose. The mere scraping of the bone is accomplished by means of ring-shaped curettes with sharp edges, or by the aid of sharp spoons of miniature patterns. So far as my own experience goes, I may say that such scraping is called for only in very exceptional cases. The need for employing still more radical measures arises only in a class of cases which do not belong in the present chapter, but in that which is devoted to the consideration of chronic mastoid disease (Chapter XX.).

CHAPTER XVI.

PERMANENT ALTERATIONS AND DEFORMITIES CAUSED BY SUPPURATIVE INFLAMMATION OF THE MIDDLE EAR.

It would neither be possible nor profitable to furnish anything like a complete catalogue of the alterations and deformities which remain behind after the spontaneous subsidence or the cure of a suppurative otitis media. It shall therefore be my aim to enumerate only some of the more important of these.

A tough and thickened membrana tympani is sometimes left as a permanent sequela of an otitis media purulenta of long standing. Taken by itself, such a thickening of the drum-membrane cannot very greatly impair the power of hearing. As an evidence, however, of a general thickening of the mucous membrane lining the middle ear, it must be considered as an important lesion. In one case which I saw in 1884, I found a drum-membrane that presented a very peculiar form of thickening—a *horny transformation*. Although the patient, a man fifty-six years of age, could not remember ever having had a discharge from the ear, it seems as if the alterations which I am about to describe must have originated in some sort of inflammatory action in the middle ear. I copy here the notes which I made in my case-book at the time: "At first glance the membrana tympani presented the appearance of polished wax. Outlines of manubrium mallei barely distinguishable. Everywhere, except along the anterior periphery—*i.e.*, from just above and in front of the processus brevis down to a point about opposite to the umbo—the outer surface of the membrane is clearly continuous with the skin of the external auditory canal. Anteriorly, however, the edge of the membrane is noticeably thickened and seems to be free; that is, a deep shadow, representing a ditch-like recess, separates the apparently free edge from the cutaneous wall of the meatus. With a bent probe I endeavored to separate this thickened edge from the underlying parts, but was not able to move it in the slightest degree. No elasticity of any part of the membrane. After I had made several such efforts, I observed that this thick-

ened edge became visibly hyperæmic, and in a short time the entire surface of this yellowish-white membrana tympani assumed a rosy hue. When the patient performed Valsalva's experiment, there was no escape of air into the auditory canal, but the hyperæmia of the membrane was slightly intensified by this act. From these facts I inferred that I was dealing, not with superposed layers of epidermis which might be dissected off from an underlying membrana tympani, but with the latter membrane itself."

In a second instance I found a large part of the membrana tympani converted into what seemed to be a horny growth, which had developed from the dermoid outer layer of the membrane. The details of this unusual case are the following:

Case LX.—The patient, a man thirty-six years of age, was admitted to the New York Eye and Ear Infirmary on the 21st of June, 1871. He stated that fourteen years previously, during exposure to severe weather, he first began to be troubled with noises and slight deafness in both ears. These symptoms had continued since, though at times they were less marked than at others. In both ears the watch could only be heard at a distance of two inches; in conversation with him, however, I was not obliged to raise my voice appreciably. On inspection I found the external auditory canals filled with hard, inspissated cerumen. To facilitate the removal of these hard plugs of wax, the patient was instructed to fill the ears night and morning with a warm solution of bicarbonate of soda (gr. x.—℥ j.). Three days later the cerumen was easily removed by syringing. On examination, the drum-membranes then presented the following appearances: On the left side there was nothing specially noteworthy; on the right, the upper three-fourths of the membrane was occupied by a flattened, sharply outlined mass of a pale yellow or yellowish-white color. It stood out from the level of the membrane to a distance of a little more than a millimetre, and terminated, throughout its entire lower border, with abrupt edges. Along its upper and anterior boundary, the mass became gradually merged in the skin of the auditory canal. Its surface was smooth and slippery, and, when touched with the probe, conveyed the impression of being quite hard, but yet not as hard as bone. The portion of the membrane that was not covered by the mass was of a uniform milky appearance, similar to that which is frequently observed in cases of chronic catarrh. With a view to obtaining more light on the nature of this mass, I instructed the patient to continue the use of the soda solution for another week. At the end of this period I found the mass practically unchanged. Its surface had been rendered slightly soft by the prolonged soaking, but I could discover no other change.

Cicatrices, or incomplete reproductions of the drum-membrane substance (as represented by its three essential layers), are very common. They are usually round, oval, or kidney-shaped, but they may also have other shapes. They are, as a rule, smooth, extremely thin, and transparent, and yield to pressure as if they

were made of rubber. In a few cases we find the cicatrix in a crumpled condition, as if it had been unduly stretched. Anatomically, such cicatrices consist of the dermoid layer on the side toward the meatus, and of a continuation of the epithelial layer which constitutes the free surface of the tympanic mucous membrane. Between these will be found some elastic fibres and a few capillary blood-vessels, but probably no nerves. The significance of the existence of such cicatricial spots in the drum-membrane is simply this: they afford strong, if not absolutely positive, proof that at some previous time the middle ear has been inflamed, and that, as a result of such inflammation, a perforation of the same size as the cicatricial spot was established in the membrana tympani. After

Fig. 97.—Depressed Cicatrix Resting upon the Inner Wall of Tympanic Cavity and Showing the Stapedio-incudal Joint. (After Politzer.)

Fig. 98.—Same Drum-membrane, Immediately after Inflation of the Middle Ear. (After Politzer.)

inflation, these cicatrices, unless the Eustachian tube happen to be unusually pervious to air, will be found to present a totally different appearance. In the place of a flat, or, more commonly, a concave, smooth, transparent surface, we shall see a tense, slightly opaque, hemispherical, or tomato-shaped bleb, which in the course of a few minutes usually returns to its former flat or concave state. More than once I have ruptured such cicatricial reproductions of the membrana tympani, and have in the majority of instances seen no harmful results from such a rupture. In one case, however, the inflation produced pain and some impairment of the hearing. I believe that it is better to avoid rupturing these cicatricial portions, and especially such as are found lying against the mucous membrane of the promontory. In these particular cases there is some likelihood that adhesions may have formed between the cicatrix and the mucous membrane, and forcible inflation under such circumstances is quite sure not merely to rupture the adhesions (which, I am willing to admit, may in certain cases be a desirable thing),

but also to tear the mucous membrane and cause hemorrhage—which, in the middle ear, is never a desirable thing.

I might mention briefly in this connection certain peculiar lesions which I have encountered thus far only twice. I refer to the development of a granulating condition in an old cicatrix of the drum-membrane, without the re-establishment of a perforation. In the first case the patient, a laborer, twenty-six years of age, had been subject for a short time, about a year previously, to a discharge from the right ear. The discharge gradually diminished, and finally ceased; but at the time when I saw him (November 22d, 1873) it had reappeared. On examination I found the right membrana tympani red, swollen, and smooth everywhere except over the greater portion of the posterior superior quadrant. Here the membrane presented a bright red and granulating surface, which bled upon the slightest touch. To this region I applied a forty-five-grain solution of nitrate of silver, by means of a cotton mop.

On the 29th of November I found that the granulating portion of the membrane had apparently become scabbed over. When I inflated the middle ear, the posterior superior quadrant of the membrane remained for a few moments in a markedly bulging condition, showing almost conclusively that no perforation existed at this point, and also that the membrane in this region had lost its substantia propria.

In the second case the ulcerated or granulating spot was circular in shape and occupied the central portion of the lower half of the membrane. In this case I resorted to inflation before the part had become scabbed over. The result was that the ulcerated portion alone responded visibly to the increased aërial pressure within the tympanum. It would seem, therefore, as if cicatrices of the drum-membrane were in a measure predisposed to ulcerative action.

Calcareous deposits have already been discussed sufficiently in a previous chapter (Chapter IV.), and I therefore do not need to say anything further on the subject in this place.

False membranes or *bands of adhesions* are often encountered in the middle ear. They must be considered as sequelæ of an acute or chronic inflammation (generally purulent in character) of the middle ear. I will select a few examples of this pathological condition from my case-books. In one case the description reads thus: "The drum-membrane is entirely destroyed, with the exception of a narrow rim at the periphery. The hammer is drawn out of position, so that the neck and a part of the head are visible. Its handle

is bound down to the long process of the anvil by adhesions." In a second case I found "a strong isolated fibrous band running from the lower part of the tympanic ring (the posterior half of the membrane having been destroyed) to (possibly) the head of the stirrup." In a third case a band ran from the centre of the handle of the hammer forward and a little downward to some point in the vicinity of the mouth of the Eustachian tube. In a fourth case the drum-membrane was found either to have undergone a high degree of atrophy or to have been replaced by a cicatricial membrane, through which was distinctly seen a whitish band running almost directly upward from the tip of the handle of the hammer to the region of the stapedio-incudal joint. In a fifth case the rigidity of the handle of the hammer, as ascertained by pressing upon it with the end of the probe, justified the assumption that the high degree of deafness which existed in this case was probably due to a similar anchylosis of the other joints, and particularly of the stapedio-vestibular joint. In a sixth case I found the hammer drawn completely out of its natural position and bound down by firm adhesions to the anterior wall of the auditory canal, or, at all events, to the anterior edge of the annulus tympanicus. Finally, in a seventh case I found one of the larger ossicles similarly bound down to the upper and posterior wall of the canal. It was so enveloped in firm cicatricial tissue that I was unable to distinguish accurately which of the two ossicles it was.

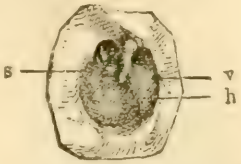

FIG. 99.—Large Loss of Substance of Right Membrana Tympani, with Formation of an Adherent Cicatrix. *v*, Thickened anterior remains of membrane fast to promontory; *s*, stapes-head with an opening above it leading into the vault of the tympanum. The Eustachian tube (*b*) is wholly shut off from communication with the major part of the tympanic cavity. (After Politzer.)

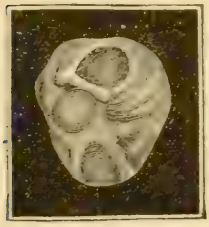

FIG. 100.—Cicatricial Retractions and Band-like Thickenings in the Membrana Tympani. (After Politzer.)

The adhesions which bind the handle of the malleus, or the membrane itself, or both, to the opposite promontory are more often encountered than those which I have enumerated above. On a previous page (p. 339) I have related an instance in which it was possible to follow this process through at least some of its stages.

Perforations are found in the membrana tympani of all sizes

and shapes, and in every conceivable part of the membrane. Double perforations in the drum-membrane proper are by no means common. In one of my cases the two perforations occupied the lower half of the membrane. In two other cases two small perforations were found, one in the anterior inferior quadrant, the other in the posterior inferior quadrant. In the fourth case my notes read as follows: "All that remains of the drum-membrane is a narrow bridge of tissues stretching from the tip of the handle of the hammer to the opposite portion of the sulcus tympanicus." Instances are on record of three, four, and even five perforations in the membrana tympani. Such multiple perforations are commonly believed to be the result of tubercular or syphilitic ulceration.

FIG. 101.—Right Ear of a Boy, Eight Years of Age, with a Long-standing Suppurative Otitis after Scarlatina. The membrane is extensively destroyed, leaving but a narrow margin all around, except where a triangular portion remains along the retracted manubrium. The tip of the incus process is just visible posteriorly, the niche of the round window appears behind, and the irregular depressions of the floor of the tympanum below. Anteriorly, we look into the Eustachian tube as far as to the isthmus. (After Randall.)

Finally, in the category of deformities, I might mention the *destruction or expulsion of the ossicles.* It is a very common experience to find the handle of the hammer reduced to a mere knob in the vicinity of the short process. In one case which I saw in 1883, not only was the lower half of the manubrium found to be lacking, but, in the process of healing, the stump of the malleus, as it appeared, had been left projecting outside of the newly produced tympanic membrane. I copy here from the memoranda which I made at the time: "On simple inspection the drum-membrane seems to occupy a nearly natural position and to be intact at all points except posteriorly, high up, where a marked depression exists. By aid of the probe in part, and also in part by aid of Valsalva's experiment, I find, 1, that the apparently natural drum-membrane is more elastic than a normal drum-membrane should be; 2, that the depressed portion is adherent to the inner wall of the tympanum, probably to the margin of the fenestra ovalis and to the head of the stapes; 3, that the lower half of the manubrium mallei has been destroyed, and that the remaining stump stands out beyond the plane of the drum-membrane, and has

no connection with it except in the neighborhood of the processus brevis."

If the hammer has disappeared *in toto*, we may be very confident that the anvil has gone with it; for when the anvil loses the support of the hammer, it becomes a mere dangling body, having only two remaining supports, and those comparatively feeble (the stapedio-incudal and the tympano-incudal articular ligaments). Unless extensive caries or necrosis of the petrous portion of the temporal bone exists, the stirrup seems to be able to maintain its position firmly in the fenestra ovalis. When it goes, or, rather, when its foot-plate goes, the hearing-power also vanishes. This, at least, must be the rule, but that exceptions may occur will appear from the facts developed in the following case:

FIG. 102.—Another Large Perforation. (After Politzer.)

CASE LXI.—*Suppurative inflammation of the middle ear, with destruction of all the ossicles; preservation of a very useful degree of hearing.*

The patient, a well-known physician in this city, about forty-five years of age, and very deaf, consulted me on the 17th of October, 1879, on account of a very distressing tinnitus. He said that during boyhood he had been subject to a discharge from both ears, and that on one occasion his mother had discovered in the discharge from the right ear the stirrup, in a perfect state of preservation. She put it into a box and kept it as a curiosity. The doctor had himself seen this ossicle as recently as during 1877, and was positive that it was the stirrup, and not one of the other ossicles. During recent years he had been entirely free from discharge, and at times heard fairly well. I tested his hearing, and found that words loudly spoken were heard about equally well in both ears. The sound of the tuning-fork, when placed upon the forehead, was referred by the patient to that region, and not to either ear; when held near the ear, it was heard by him at a distance of about four inches, in both ears. Every trace of the drum-membrane, hammer, and anvil had vanished from both ears, and a thick and pale (fibrous) cicatricial tissue covered the entire background, the only decided depression being a niche at the tympanic orifice of the Eustachian tube.

This is the only instance that I have met with in which the evidence was fairly conclusive that the expulsion of this most important ossicle, in the course of a suppurative inflammation of the middle ear, had not wholly deprived the patient of the hearing-power in the ear thus maimed. Nature, we may assume, had in this instance probably provided a fibrous substitute for the foot-plate of the stirrup before the actual separation and expulsion of

the ossicle took place. On the other hand, there are cases on record (Kessel, Dench, and others) in which the stapes has been removed in its entirety by surgical interference, and yet the hearing has not been destroyed. Indeed, it is claimed that in some of these cases the hearing was improved by the operation.

Treatment.—The only therapeutic question which arises in connection with this class of cases is that which relates to the possibility of improving the hearing or of alleviating a distressing tinnitus. The impairment of the hearing may, as a rule, be attributed to a lack of mobility on the part of the stapes; and the tinnitus is certainly in some cases due to the fixation of this ossicle in such a deep position, in the niche of the fenestra ovalis, that the labyrinthine contents must constantly be under abnormal pressure. So far as the question of anchylosis, or lack of mobility, is concerned, I do not believe that it lies in our power to materially alter this condition for the better. When the rigidity is due to the existence of connective-tissue adhesions which anchor the ossicles firmly to the surrounding walls of the tympanum, it is possible that in some cases a division of these bands may effect an improvement in the hearing-power or a diminution in the tinnitus. But when the rigidity is due to the solidification of the tissues about the foot-plate of the stapes, I am confident that all our attempts at mobilization, even when at first they may appear to be markedly successful, must ultimately end in failure.

Stapedectomy does not commend itself to me as an operation that is ever likely to accomplish much good. I once had the misfortune to destroy the hearing of one ear by accidentally passing a curette somewhat too violently across the fenestra ovalis (with its contained stapes), and in consequence of that experience I am perhaps unduly prejudiced in favor of the old-fashioned belief that only harm can come from operative interference with this ossicle. On the other hand, as stapedectomy is only recommended, by its advocates, for cases in which the hearing (of the ear to be operated upon) is already of very little value, I do not feel warranted in interposing any obstacles in the way of those who desire to subject the question to further practical tests.

In cases of simple perforation of the drum-membrane, where the discharge has ceased, I never make any attempt to induce healing of the opening through the formation of a cicatricial membrane, the gain which might result therefrom being altogether too insignificant. There is one point, however, which should be borne in mind with

regard to these cases of simple perforation. I refer to the harm which sometimes comes from the introduction of water into the external auditory canal. When so introduced it is almost sure to find its way into the tympanic cavity, and—the tympanic mucous membrane being in a comparatively healthy state—its presence there is apt to give rise to considerable irritation, and perhaps even to re-establish a subacute purulent inflammation of these parts. The removal of impacted cerumen from the external auditory canal by means of the syringe may, in cases such as we are considering, result in the production of an evil which in its turn may require considerable treatment. In cases, therefore, in which there are good grounds for suspecting the existence of a perforation in the drum-membrane (without otorrhœa), the syringe should not be used, if we can possibly dispense with it. The patient should also be cautioned about bathing in either salt or fresh water, without first protecting the affected ear against the entrance of water.

There are various contrivances which, in a few of the cases such as we have just been considering, are found to render the hearing somewhat more acute. Toynbee's artificial drum-membrane is one of the oldest of these contrivances, and at the present day there are several patterns of it in the market; only one of them, however, bearing the name of Toynbee. Then there is the little device of Hassenstein—a short stem of hard rubber, around one end of which cotton is to be wound and then smeared with vaseline or glycerine. Finally, it was discovered by Yearsley, an English surgeon, as long ago as in 1848, that a firmly wound pellet or roll of cotton, when placed in the right position in the external meatus, apparently is just as effective in increasing the hearing-power as are the other contrivances. In all of them one thing is essential to their proper working, viz., the external conductor of sound—be it the metallic rod of the Toynbee artificial drum-membrane, or the hard-rubber stem (armed with cotton) of Hassenstein's device, or the simple mass of tightly rolled cotton—must rest in contact with the stapes or the lower end of the long process of the incus. It is possible that in a few cases the contact of this artificial conductor with the manubrium mallei may suffice to improve the hearing. Ocular inspection under good illumination simply enables us to place these different objects more or less near to the point where they actually increase the volume of sound entering the labyrinth. But, as a rule, several readjustments must be made before the right spot is finally stumbled upon. An intelligent patient, on the other hand,

learns, in the course of time, to effect this adjustment much better and more quickly than it can ever be done by the physician. But, as I have already stated, the aggregate number of those who really derive an appreciable amount of benefit from these "aids to hearing" is very small.

CHAPTER XVII.

MISCELLANEOUS PATHOLOGICAL CONDITIONS AND DISTURBANCES IN THE MIDDLE EAR.

FOREIGN BODIES; INJURIES; MALFORMATIONS; NEW-GROWTHS; CYSTS; SYPHILIS; TUBERCULOSIS.

I. Foreign Bodies.

The finding of a foreign body in the tympanic cavity is an event of great rareness. There was a time when such an occurrence was more common. I refer to that short period, twenty-eight years ago, when the introduction of a Politzer eyelet into an artificial opening made in the tympanic membrane was widely practised by aural surgeons in the hope—which was soon proved to be vain—that it would permanently improve the hearing of many who were suffering from marked deafness. Not a few of these eyelets ultimately became foreign bodies in the tympanum, and their subsequent removal by surgical interference sometimes caused an infinite amount of trouble. Unskilled or ill-judged attempts to adjust a Toynbee's or other form of artificial drum-membrane have sometimes terminated in establishing it as a foreign body in the tympanum. This was the unfortunate termination in the following case:

Case LXII.—*Imprisonment of a thick disk of india-rubber in the tympanic cavity.*

The patient, a lady about sixty years of age, consulted me on the 24th of March, 1879, for a painful affection of the right ear. According to her statement, she had had a slight discharge from the right ear for a period of many years. About the 1st of March of that year she noticed that her hearing was more dull than usual, and, at the suggestion of a friend, she consulted a physician. He gave her very little encouragement, but said that she might experience some relief by wearing an artificial drum-membrane, and, with her permission, he introduced one into her ear. As this artificial membrane, however, did not improve her hearing, but, instead, caused her considerable discomfort, he undertook to remove it. Although he failed, as will be seen, to accomplish his object, he in a measure satisfied the patient that the membrane had been removed. From that time forward the ear had grown more and

more painful, and she had latterly experienced considerable pain throughout the entire right side of the head. At the time when I saw her she presented the appearance of a person who had passed through a prolonged period of suffering. On examination I found the inner half of the canal filled with a soft, polypoid mass, bathed with somewhat thick pus. I removed the growth with the snare and found that it sprang from the edge of a moderately large perforation in the drum-membrane. In the centre of the opening I noticed something of a peculiar grayish-white color, and on touching it with the probe I discovered that it consisted of some hard material which was firmly lodged in the cavity of the tympanum. By aid of the slender angular forceps I succeeded in extracting this foreign body, which proved to be a rather thick disk of whitish rubber, in the central portion of which was a small hole for the reception of a thread or the end of a slender probe. This circular piece of rubber was of almost precisely the same size and shape as the normal drum-membrane.

After this foreign body had been removed from the middle ear the pain soon disappeared entirely, the discharge became again insignificant, and when I examined the ear, after the lapse of about ten days, I found a perfectly smooth and unirritated drum-membrane, in the centre of which was a circular perforation not more than three millimetres in diameter. No further treatment was advised.

Comments.—It is difficult to understand how any physician possessed of his senses could have deliberately done such a foolish thing as to force a comparatively large disk of rather stiff rubber through an opening in the drum-membrane scarcely three millimetres in diameter. And yet the condition in which I found the ear showed very clearly that this disk had been placed deliberately in the situation where I found it.

In another case—that of a man forty-one years of age, whom I saw in February, 1880—I found the tympanum (the membrana tympani was entirely destroyed) very neatly and accurately packed with a firm wad of cotton, which, when it was removed, gave out a sickening odor of decomposing pus. The only history that I was able to elicit from this patient was to the effect that he had always had a discharge from this ear, and that for some time past it had smelled very badly and had annoyed him by escaping into the back part of his nose and causing a constant sensation of sore throat. He seemed surprised by the discovery of the wad of cotton, and expressed himself as being unable to explain how it came to be in his drum cavity. Its presence there, however, had given him no pain whatever. Nevertheless, immediately after the removal of the foreign body, the patient said that his head felt lighter and that the sensation of soreness on the corresponding side of the throat had disappeared. On inspection I found that the mucous membrane

at the anterior end of the tympanum was in a granulating condition.

The removal of foreign bodies from the tympanum is effected either by means of the slender angular forceps, where the object is of such a nature or in such a position that it can be grasped, or by aid of a specially constructed hook or of the slender middle-ear probe bent at a suitable angle.

II. Injuries.

These may be divided into three classes, viz., those in which the only lesion is a rupture of the membrana tympani, those in which various other parts of the middle ear are injured by direct violence, and, finally, those in which the damage is only indirectly inflicted, as through the effect of contrecoup.

1. Ruptures of the Membrana Tympani Without Accompanying Damage of Other Parts of the Middle Ear.—There are three ways in which this membrane may become ruptured: the concussion of the air in the external auditory canal may exert a strain upon it which it cannot bear; some foreign body may enter the auditory canal from without and tear it by direct violence; and finally, in the course of a fracture of the temporal bone by contrecoup, such a strain may be exerted upon the membrane that it ruptures. Ruptures from the first two of these causes—concussion of the air and an injury inflicted by a foreign body—are in my experience quite rare. I can find only seven instances of the lesion in my records. In three of these the rupture was produced by a blow of the hand upon the ear; in one instance a snowball struck the ear and caused the rupture; in another instance the patient, while pheasant shooting, ran against a dry twig which broke off in his ear; and, finally, in two instances I was unable to ascertain the cause (the patients were probably ashamed to confess that their ears had been boxed). In three instances (all of them cases of concussion of the air in the external meatus) the rupture extended from the tip end of the manubrium downward and a little backward—that is, in a line directly continuous with the handle of the malleus—to the periphery of the membrane. In the fourth case it ran from a

[1] Those who are interested in the subject will find other instances related in an article by Dr. Huntington Richards, entitled "Tympanum, Foreign Bodies in the," in vol. vii. of the "Reference Handbook of the Medical Sciences." New York: Wm. Wood & Co., Publishers, 1888.

point near the periphery of the posterior superior quadrant directly downward in a straight line to a point near the periphery of the posterior inferior quadrant, in very much the same manner as is shown in the accompanying cut (Fig. 103), drawn from one of Dr. Randall's cases. In a fifth case the rupture ran in a slightly curved line from the lower limit of the posterior superior quadrant (midway between the umbo and the periphery) to the central portion of the anterior inferior quadrant. In the sixth, the rupture occupied

FIG. 103.—Rupture of the Left Membrana Tympani. A vertical gap extends almost across the posterior half of the membrane, and the vessels are full, especially behind the manubrium. (After Randall.)

FIG. 104.—Double Rupture of Right Membrana Tympani in a Woman of Thirty, produced by a fall upon the ear—seen on the third day. The two openings have radiating directions, and show marked gaping. (Politzer.)

the posterior inferior quadrant, and consisted of an irregularly shaped opening with jagged edges. In the last case—that in which a sharp twig had penetrated the membrane—the perforation, which was irregular in shape, occupied the posterior superior quadrant. The foreign body must literally have grazed the incudo-stapedial articulation.

In one of these seven cases—the one in which the impact of a snowball had caused the rupture—I noted the peculiar fact that the torn edges of the opening showed no proliferative tendency whatever; at the end of six months the opening still remained unclosed. In two other cases hemorrhagic infarctions were observed in the immediate vicinity of the rupture.

Double ruptures are of rare occurrence. One such instance is shown in the accompanying cut (Fig. 104) which has been copied from Professor Politzer's work.

In the unique case reported by Dr. Robert F. Weir[1] the mem-

[1] Transactions of the American Otological Society, 1870. Consult also, in regard to injuries of the drum-membrane, Schalle, in Archiv für Ohrenheilkunde, XII., p. 10; Burnett, in Transactions American Otological Society, 1872; Politzer, in Wiener Medicin. Presse, 1872; Bürkner, Archiv für

brana tympani was ruptured horizontally, at a point about midway between the processus brevis and the tip of the handle of the malleus, and at the point corresponding with the line of this rupture the manubrium was found to be fractured (see Fig. 105).

2. Direct Injuries Involving Various Parts of the Middle Ear.—I can find in my case-books the records of only four cases in which the middle ear has been injured by a force acting directly



FIG. 105.—Ununited Fracture of the Manubrium, the handle being broken at about its middle, and the lower fragment displaced backward (*a*). Valsalval inflation corrected the displacement (*b*), but it soon recurred. (Weir's case.)

upon it or upon the parts situated in its immediate vicinity. Two of these were cases of gunshot or pistol wounds, while the other two were cases in which a fall or a blow (from a club) upon the mastoid process was the cause of the damage. In one of these cases there was reason to believe that the temporal bone had been cracked, and that the line of the fracture extended through that portion of the tympanum which constitutes the entrance to the mastoid antrum. The patient recovered ultimately without operative interference, but for a long time it seemed as if such interference would be unavoidable. Unfortunately, my notes do not permit me to furnish a more detailed history of this case. The second one, however, is more fully recorded, and I will therefore reproduce it here.

The full details of the two cases of bullet wounds are given below:

CASE LXIII.—*Fracture of temporal bone by a direct blow upon the mastoid portion; bleeding from the nose; mastoid portion was cracked, but facial paralysis did not develop until later; diastasis, with unusually wide separation of the opposite edges, along the line of the Glaserian fissure; cochlea not involved; good recovery.*

Male, thirty-eight years of age, healthy. October 24th, 1891. He was thrown from his horse during the month of May, 1890; was found in an un-

Ohrenheilkunde, XIV., p. 230; Shaw, Boston Medical and Surgical Journal, November, 1868; Turnbull, in Medical and Surgical Reporter, Philadelphia, February 22d, 1879.

conscious state, with blood escaping from his nose; the skin behind the left ear was discolored ("black and blue"). When he regained consciousness he noticed only a slight impairment of the hearing and some tinnitus in the left ear. Soon afterward, left facial paralysis developed.

Present condition: Hearing (left ear) nearly normal; paralysis has entirely disappeared; left tympanic membrane practically normal, but just above the processus brevis there is a well-marked sulcus which extends horizontally across the upper limits of the membrane. This sulcus suggests the idea that the separated surfaces of the bone, along the line of the fracture (or diastasis), never returned to their previous position, but remained a certain distance apart; the gap being filled in, probably, by connective tissue.

Case LXIV.—*Bullet-wound of one ear, with comminuted fracture of the temporal bone.*

The patient, a powerful but idiotic-looking negro, thirty-five years of age, while animated by a desire to end his life, fired one chamber of a loaded revolver into his right ear, and then, finding that he was still alive, he discharged the contents of a second chamber into his left ear. This was done on the 6th of March, 1874, and on the 18th he was brought to the New York Eye and Ear Infirmary. I was not able to learn what had been the man's condition during the interval between these dates. The patient himself was perfectly deaf, and the person who accompanied him simply knew the facts relative to the shooting. On examination I found the right external auditory canal filled with polypoid granulations. These sprang from the anterior and lower wall of the meatus, about midway between the outer orifice and the drum-membrane. At this point the bent probe entered an excavation in which loose pieces of bone were encountered. On the left side the auditory canal was also found to be filled with pus. Several small polypoid growths were removed from the narrow canal, but no region of exposed bone could be detected, nor could I obtain a satisfactory view of the deeper parts of the canal. There could be very little doubt, however, of the absence of the drum-membrane, and probably of the ossicles. The right ear being very painful, I prescribed leeches.

On the 22d of April I saw the patient a second time. The leeches had relieved him from pain. With the slender angular forceps I removed two fragments of bone from the right auditory canal.

On the 2d, and again on the 6th of May, I removed fragments of bone, one of which presented a blackened appearance.

On the 9th of May I encountered some hard substance in the region of the middle ear, and succeeded in extracting it. It proved to be a mass of lead, about the size of a half-pea, probably a portion only of the ball fired from the revolver. The opening in the canal from which the fragments of bone had been removed presented every appearance of being on the point of healing.

On the 16th of May I removed another piece of lead and some fragments of bone from the region of the right middle ear.

On the 3d of June I found that the wound in the meatus had healed, and that the mucous membrane of the middle ear was free from all evidences of active irritation. The discharge had apparently ceased entirely.

After the removal of the polypoid granulations from the left auditory canal all active discharge from that ear ceased.

If the damage observed in this left ear is to be ascribed to the effects of the shooting, the bullet must have been extracted by some physician during the period of twelve days that elapsed between the infliction of the injury and the time of entrance into the Infirmary.

Comments.—In the preceding case it is quite possible that the squamous and petrous portions of the temporal bone (on both sides) were also fractured. The ball, however, may simply have driven the stirrup violently into the vestibule, and not have produced an actual fracture of the petrous bone. In the following case the petrous bone could scarcely have been involved to a serious extent, although probably the squamous portion did not wholly escape.

CASE LXV.—*Gunshot wound of the ear; comminuted fracture of temporal bone; hearing seriously affected; ball removed ten years later.*

The patient, an apparently strong man, thirty-four years of age, and a soldier, was admitted to the New York Eye and Ear Infirmary, June 12, 1872. He gave the following history: In the course of an engagement with the enemy, in Valverde, New Mexico, on the 22d of February, 1862, the company of which he was a member (Co. G, First U. S. Cavalry) was ordered to retake a battery. While they were advancing he was shot in the right side of the head, the ball entering the skin just in front of the ear. The shot had come from a detachment of the enemy in the rear. Three days later the ball was extracted from beneath the skin, just above the right eyebrow. He then noticed a sensation of throbbing and fulness in the right ear, and not long afterward a discharge made its appearance in the outer canal. He remembers also that one of his comrades, at about that time, removed a bunch of hair, clotted with blood, from the right ear. During the first ten or twelve months following the injury he frequently found small fragments of bone in the discharge from the ear. Six months previous to his visit to the Infirmary he had experienced a severe attack of pain in the right ear, but before that time he had always been comparatively free from pain. From the very first he had been annoyed by a tinnitus, like the roaring of a shell. All sounds, moreover, seemed to reach him by way of the left ear. At night he had always been obliged to sleep on the right side, for whenever he attempted to lie on the left side the sense of weight in the right ear became unbearable. About a week previous to his visit to the Infirmary the parts about the right meatus became very painful and swollen. The swelling subsided in the course of a day or two, and then for the first time he discovered the presence of some hard substance filling the outer canal. He came to the Infirmary for relief, and in this way became my patient. On examination of the ear I found a black mass, partly covered by pus, blocking up the entrance to the right auditory canal. I experienced no difficulty in extracting it with the forceps, and on examination found it to be a very much corroded, oblong leaden bullet, a little over half an inch in length, and three-eighths of an inch in diameter. The deeper portion of the meatus was found to be filled with a

mass of granulations. No sinus could be found, nor any exposed surface of bone. The Eustachian tube was pervious. In front of the tragus there was a depressed scar, indicating the point where the other ball had entered. The patient was unable to hear the ticking of my watch in the right ear. The sound of a vibrating tuning-fork, placed on the central part of his forehead, was referred by him to that point, and not to either ear. With the left ear tightly closed, and the right turned toward the speaker, he could understand ordinary conversation at a distance of four or five feet.

On the 16th of June the patient reported that he had been quite free from pain since the removal of the ball, and that the discharge had also ceased.

On the 24th of July he again visited the Infirmary. The discharge had not returned. The tinnitus continued unchanged, but the sense of weight had disappeared, and he was able to lie indifferently on either side. Cicatrization had taken place in the ulcerated portion of the meatus, and there was then a clear but funnel-shaped passage down to the cavity of the tympanum. No trace was found of either the drum-membrane or the ossicles.

At the time when he was wounded, and even up to the time when he visited the Infirmary, the patient supposed that his ear trouble had been caused by the glancing backward of a fragment of the ball which struck him in front of the ear. Even the removal of a tuft of hair from the external auditory canal had not suggested to him the idea of a second ball, until after I had shown to him that the leaden mass removed from the meatus could scarcely be considered as a fragment of the ball that had been extracted from above the eyebrow of the same side. He then stated that many of the men in the enemy's ranks were armed with double-barrelled fowling-pieces, and suggested the possibility of his having been shot by the simultaneous discharge of both barrels of such a weapon. A more natural supposition is that he was shot by two balls contained in a single cartridge—one of them entering the meatus directly, without leaving any external wound, the other striking the bone in front of the ear and glancing forward. [1]

3. Fractures by Contrecoup.—The subject of fractures of the temporal bone belongs chiefly to the domain of general surgery, and yet the participation of the organ of hearing in the damage inflicted brings it also very properly among the topics which should be discussed in a treatise on the diseases of the ear. The so-called "fractures at the base of the skull" probably always involve the temporal bone. These cases do not often come under the observation of the aural surgeon, and the medical man first called to see the case probably never thinks of making an examination (with the speculum and reflected light) of the external auditory canal and drum-membrane. Hence our supply of facts with regard to the lesions demonstrable during life in the temporal bone of a person

[1] For other cases of gunshot wounds of the temporal bone, see Moos, Archives of Ophthalmology and Otology, vol. iii., 342; Terrillon, Annales des maladies de l'oreille, 1878, p. 249.

who is believed to have a fracture at the base of the skull is very scanty. Thus, for example, in not a single instance has it been my privilege to examine one of these cases earlier than upon the sixth or seventh day following that upon which the accident occurred. Hence the reports of cases which I shall give presently must necessarily be very imperfect, especially in regard to the earliest lesions.

Fractures of the temporal bone may be subdivided into two classes:

1. Fracture or diastasis of the tympanic or squamous portion, in the region of the middle ear, without implication of the pars petrosa.

2. Fracture of both the tympanic and the petrous portions.

Both of these kinds of fracture are produced, not by direct violence to the parts, but by *contrecoup*—that is, the patient, in falling, strikes upon the back or the top of his head, while the fracture occurs at the base of the skull. Indeed, in many cases the blow may be struck upon one side of the head, and yet the direction of the force thus expended may be such as to produce a fracture by contrecoup upon the same side of the head. In the first variety, the line or lines of fracture correspond with the lines of union of the three bony portions which together form the temporal bone, and which in fœtal life represent separate centres of growth, viz., the squamous portion (together with the zygoma), the tympanic portion (annulus tympanicus), and the petrous portion (together with the mastoid process). These fractures, therefore, partake somewhat of the nature of diastases. In the second variety, the fracture of the petrous portion of the temporal bone represents a genuine fracture. It takes place in the middle part of the bone, where it is greatly weakened by the presence of several large cavities (the meatus auditorius internus, the cochlea, the vestibule, and the semicircular canals), which are separated one from another by comparatively thin partitions of bone. While it is possible that a fracture may take place in the petrous portion of the temporal bone without a contemporaneous fracture or diastasis in the adjacent squamous or tympanic portion, we possess no facts as yet which will justify such a belief. In fact, the general surgeon is not in the habit of recognizing even two subdivisions, such as I have here made. Now, I am satisfied that these subdivisions are by no means fanciful, but rather the reverse: they are eminently practical. Let me illustrate. A person falls, or receives a blow upon the head. Bleeding from

the ear follows, and may even be copious in amount. He is unable to hear the ticking of a watch in the affected ear, and, when the good ear is closed, he finds difficulty in distinguishing spoken words. The general surgeon, if he make the attempt to locate the fracture without resorting to an examination of the ear, will be very likely to make this diagnosis: fracture of the temporal bone through its petrous portion; a diagnosis which almost necessarily implies the permanent loss of the hearing of the corresponding ear. On the other hand, an examination of the ear with the speculum and reflected light might show a fracture running along the Glaserian fissure, and a tympanic cavity filled with blood. By aid of the tuning-fork, the fact might also be learned that the sonorous vibrations of this instrument were heard best in the affected ear. The diagnosis would then have to be made of a fracture involving the squamous and tympanic portions, and not the petrous; and the patient could properly be encouraged to hope for a partial, if not a complete, restoration of the hearing. Furthermore, the knowledge gained by such an examination of the ear would be likely to materially modify the treatment that would otherwise be adopted.

There are still other phenomena with regard to which the general surgeon is more than likely to form an erroneous opinion, if he does not take advantage of the light which an examination of the ear is competent to afford him. I refer particularly to two symptoms, viz., hemorrhage from the ear, and a watery discharge from the same region. In cases of fracture of the temporal bone, a *hemorrhage from the ear* means, as a rule, a rupture of the blood-vessels in the vicinity of Shrapnell's membrane. Such a hemorrhage may be copious, and may continue for a comparatively long time; and the mere fact of its copiousness does not indicate that a communication has been opened between the cavity of the tympanum and any of the large vascular channels which surround the temporal bone. I am convinced, from actual observation in numerous cases, that the blood-vessels in the neighborhood of Shrapnell's membrane are amply able, under favorable circumstances, to provide both a copious and a prolonged bleeding. I am also satisfied, from examinations which I have made in cases of injury to the head of comparatively recent occurrence, that fractures of the temporal bone occasionally occur without the slightest bleeding from the external auditory canal. And, finally, the symptom of bleeding from the nose, which in these cases is commonly looked upon as adding to the seriousness of the outlook, is often in reality, as I

believe, merely a hemorrhage from the tympanum by way of the Eustachian tube. That these views, however, are at variance with those of the best surgical authorities, may be gathered from the following statement, which I have copied from Sir Prescott Hewett's remarks on Fractures of the Base of the Skull, in Holmes' "System of Surgery":

"Bleeding from the ears, in severe injuries of the head, has, for many years past, been held, and deservedly too, as one of the most valuable diagnostic signs of fractured base. But this bleeding, to be of any value as a means of diagnosis, must be of a serious nature, and, above all, it must continue for some time. With such a bleeding it may be safely diagnosed that there is a fracture of the base running through the petrous bone, and opening up a communication between the cavity of the tympanum and some of the numerous and large vascular channels which surround this bone, or with an extravasation of blood within the cranium itself."

The other symptom, which is considered to be of so great diagnostic value in cases of suspected fracture of the temporal bone, is that of a *watery discharge from the external auditory canal*. While our direct knowledge with regard to this symptom is almost a blank, apparently no examinations having been made of the ear in suitable cases, a general knowledge of ear diseases and of the anatomy of the temporal bone would prevent me from accepting in their entirety the views put forward by Sir Prescott Hewett in the following paragraphs, taken from the article quoted above:

"There are, then, as far as is known at present, three classes of cases of this watery discharge. In the first class, where the fluid from the ear is plentiful and of a decidedly watery character immediately after the accident there need be no doubt as to the nature of the injury—the watery discharge is due to the escape of the cerebro-spinal fluid, which, as already stated, can only take place through a fracture of the petrous bone implicating the internal auditory canal and its membranes.

"In the second class of cases, characterized by a copious and prolonged bleeding from the ear, followed by a watery discharge, a fracture of the petrous bone may also be safely diagnosed; but it cannot be said that the fracture follows any particular course. In these cases, it must, however, be clearly understood that it is not to the watery discharge that we can trust for our diagnosis, but to the copious and prolonged bleeding.

"Thus far there is no difficulty. Not so, however, in the third class of cases, in which there is at first a discharge of blood only, neither copious nor prolonged, which is followed by a watery discharge, varying as to the time of its appearance—varying as to its quantity. It may be present within a very few hours after the accident—it may be profuse within a few hours after its appearance. These are the cases in which experience has of late proved that the diagnosis ought to be doubtful. The discharge of blood is certainly

not of a character to warrant a diagnosis of fracture of the petrous bone; and as to the watery discharge, it is now well known that such a discharge may occur within a few hours after the accident, that its quantity may even be profuse, and yet there may be no fracture."

I may be in error with regard to this matter, and yet it appears to me to be a very simple problem, at least so far as the existence or non-existence of a fracture is concerned. To determine the full extent of the fracture, is quite another matter; although even here, as I have said before, it is easily possible to define rather coarsely the parts of the temporal bone affected. If we consider for a moment the solid, masonry-like construction of the temporal bone, we can scarcely resist the conclusion that, when a blow upon the top, back, or side of the head is followed by any decided symptom whatever in the ear (as, for instance, bleeding, a watery discharge, or even simply pain), a fracture or a diastasis must have taken place in the corresponding temporal bone. A mere jar of the head is not competent to produce a hemorrhage from the external auditory canal. On the other hand, an actual stretching of the soft parts to such a degree as to tear one or more blood-vessels is not, under such circumstances, physically possible in the vicinity of the drum-membrane, unless at the same time there shall have been an actual giving way of some part of the surrounding arch of bone. Such a laceration of the parts is sure to be followed by inflammation, and this inflammation will be proportionate to the degree of damage done to the parts. A profuse and sometimes long-continued watery discharge from the middle ear, by way of the external auditory canal, is a well-known characteristic of an ordinary, non-traumatic, acute inflammation of the middle ear, provided that an outlet for its escape has been established, either by natural or by artificial means, in the membrana tympani or neighboring wall of bone. In the severer cases of fracture of the temporal bone, the drum-membrane is very apt to be lacerated, and it is in precisely these severe cases of fracture that we encounter this symptom of a watery discharge from the ear. In estimating, therefore, the diagnostic value of this symptom, in cases of fracture of the temporal bone, I am disposed to go no further than this: a watery discharge affords a good measure of the degree of damage done to the temporal bone and contiguous parts. It is by no means necessarily a fatal symptom, for I have known several such cases to recover. I should perhaps not be justified in insisting that all of this watery discharge comes from the middle ear and parts bordering upon it;

for in the fatal cases, with considerable tearing of the membranes of the brain, it is reasonable to suppose that much of the watery discharge is due to an escape of the cerebro-spinal fluid. In a large proportion of the cases, however, I am confident that this watery discharge is merely the product of traumatic inflammation of the tympanic mucous membrane.

The treatment ordinarily employed to arrest an acute inflammation of the middle ear is the treatment which can best be adopted for the relief of the inflammation caused by the fracture. I fully believe that in certain cases it will be found competent to turn the scale in favor of recovery; and it is on this account that it seems to me to be a very important matter that in every case of supposed fracture at the base of the skull, an examination of the deeper parts of the ear should be made.

ILLUSTRATIVE CASES.

CASE LXVI.—*Fracture of the temporal bone, probably by contrecoup; merely a diastasis along the line of the Glaserian fissure, with a limited hemorrhage; cochlea not involved; good recovery.*

Male, forty years of age, healthy, but addicted to periodical drinking sprees. January 15th, 1894. Blow or fall upon the head one week previously. He is unable to state what happened during the next two or three days. Since then he has suffered somewhat from pain and tinnitus in the left ear, and his physician reports that his temperature remains at about 100° Fahr. Hearing not seriously affected.

Present condition: A large clot, covered with a thin pellicle of epidermis, fills the inner end of the left external auditory canal. The removal of this clot reveals to view a line, like a deep, freshly made scratch, extending horizontally across the region of Shrapnell's membrane, and then outward and downward, a distance of a few millimetres, over the anterior wall of the bony external meatus. The membrana tympani itself is œdematous and somewhat congested, and, when incised, it gave escape to a blood-stained pus. Treatment prescribed: Three leeches; poulticing with hot flaxseed meal; occasional douching with hot water; calomel, in doses of one-tenth of a grain every three hours.

On January 26th I found that the discharge had ceased, that his tinnitus had disappeared, and that his body-temperature was normal.

CASE LXVII.—*Fracture of the temporal bone, probably by contrecoup; mastoid portion cracked, but cochlea escaped; facial paralysis developed early; profuse hemorrhage from the ear and from the nose; almost perfect recovery.*

Male, about thirty-five years old, in good health, but occasionally drinks alcoholics to excess. February 18th, 1887. Three weeks previously, while driving, he was thrown out of his sulky and struck upon the left side of his

head, but exactly at what point he was unable to say. He was found by the roadside in an insensible condition, with blood flowing in a continuous stream from the left ear, from the nose, and to a slight extent also from the mouth. When he came to his senses, some time later, he discovered that the left side of his face was paralyzed, that the left auricle felt numb, that the hearing on that side was seriously impaired, and that there was a roaring sound in the affected ear. The act of blowing his nose produced a painful sensation in the left ear.

At the present time there is no paralysis, and the hearing in the left ear is remarkably good, all the circumstances being considered. The right ear being firmly closed, he can hear whispered words correctly at a distance of five feet; but he can hear the ticking of my watch only when it is placed in contact with the auricle. No alterations of any importance in the left tympanic membrane.

Case LXVIII.—*Fracture of temporal bone by contrecoup, with involvement of the petrous and mastoid portions, and the formation of a shelf-like false membrane in the external meatus. Permanent loss of the hearing in the affected ear.*

Male, twenty-five years of age, healthy. November 12th, 1892. Unsatisfactory history. Fall or blow upon the head six weeks previously, followed by left facial paralysis and total deafness in the left ear.

Present condition: At the inner end of the left external auditory canal there is a false membrane, of considerable strength, that stretches horizontally across the canal and seems to be amalgamated with the tissues of the membrana tympani, which are red and infiltrated. All these parts are bathed with a blood-stained pus. I am unable to find any exposed surface of bone, or to demonstrate the existence of a perforation. There is complete loss of hearing in this ear, and there is still a noticeable degree of facial paresis.

Treatment: the bi-daily use of Angelo's ear-douche with hot water.

III. Malformations.

It is reported, on apparently good authority, that in rare cases the mastoid antrum is entirely absent. While I have never encountered an instance of the absence of this chamber, I have found it, in one or two cases, to be of exceptionally small size. The only other malformation of which I have any personal knowledge is that of an abnormally bent manubrium mallei (see Fig. 106), evidently of congenital origin. The details of this case are as follows:

Fig. 106. — Hook-shaped Manubrium Mallei. (From a case seen by the author.)

Case LXIX.—The patient, a boy thirteen years of age, was admitted to the New York Eye and Ear Infirmary on the 15th of May, 1872. At the age of three he had passed through an attack of scarlet fever which left him with a double otor-

rhœa. On the right side the discharge had continued up to that time without interruption; on the left, it had entirely ceased about one year previously. On examination of the left membrana tympani I found that the end of the handle of the malleus was curved from behind forward, in the manner shown in the accompanying cut (Fig. 106). The membrane itself was opaque and somewhat mottled, but it presented no evidence of ever having been perforated. There was also nothing to indicate that a fracture of the manubrium had ever occurred. The membrana tympani and the manubrium mallei of the other ear had been entirely destroyed; and so it was no longer possible to institute a comparison between the two manubria. The boy's general health was excellent, and he presented no signs of ever having had rickets. [1]

IV. New-Growths.

Under this heading I propose to consider only those new-growths which depart so markedly from the ordinary type of aural polypoid tumors that it would be scarcely proper to treat them in the section devoted to the proliferative form of suppurative inflammation of the middle ear.

Hyperostosis of the bony wall of the tympanum is, I believe, quite a rare pathological condition. In the only three cases which I have seen, a suppurative affection of the middle ear was present in two of them, while in the other case it was possible that there may have been suppurative disease in early life. In the first, the bone in the neighborhood of the fenestræ and the promontory itself had increased so greatly in bulk that the posterior half of the tympanic membrane presented a polished, convex outer surface, apparently due to the pressure exerted upon it (from within) by the hypertrophied mass of bone. The handle of the hammer rested firmly against the tumor, and served to mark its anterior limit. That portion of the tympanic membrane which lay in front of the tumor seemed to be cicatricial in character, and depressed. The patient, who was sixty-two years of age, said that he had been quite deaf in that ear for at least thirty years.

In the second case—that of a boy, sixteen years of age, who had had a discharge from his right ear for a period of seven years—a hemispherical bony mass, apparently about five millimetres in diameter at its base, overhung the tympanic orifice of the right Eustachian tube. Posteriorly, it was in contact with the stump of the manubrium mallei (the membrana tympani having been com-

[1] The only other similar case of which I have been able to find any record is that reported by Buhl and Hubrich in the Monatsschrift für Ohrenheilkunde, vol. ii., No. 1, January, 1868.

pletely destroyed). The mucous membrane covering the tumor was still recognizable as a distinct, more or less succulent membrane.

In the third case—that of a child about two years old—an unusually firm polypus (fibroma) was found in the external auditory canal. When all of this growth (except the very stump) had been removed, partly by the snare and partly by the knife, it was found that it sprang from a hemispherical mass of bone which was seated posteriorly and superiorly, close to the entrance of the mastoid antrum. This hyperostosis, which included the corresponding portion of the sulcus tympanicus, encroached to a considerable extent upon the calibre of the auditory canal. A chronic discharge from the antrum undoubtedly supplied, in this case, the stimulus needed for such active proliferation of the adjacent bone.[1]

Vascular new-growths are probably encountered in the middle ear even more rarely than are those of a bony nature. So far as I can learn, there are but four instances on record in which a vascular tumor developed in a middle ear whose drum-membrane was still intact, viz., one reported by Schwartze,[2] two by Weir,[3] and one by myself.[4] In Schwartze's case very few details are given. The left drum-membrane, which was otherwise white and lustreless, presented a pulsating point near the umbo. The pulsations were synchronous with the radial artery, and ceased during the performance of Valsalva's experiment. From the meagreness of the details given, it is not even quite clear that the case belongs in the present category. In both of Dr. Weir's cases, however, one of which I had the privilege of examining at my office, and also in my own case, the evidence of the existence of an intratympanic vascular growth is reasonably clear. In view of the rarity of tumors of this nature, I will give in full the histories of these three cases:

Case LXX. (Dr. Weir's First Case).—"Mrs. J. A., aged thirty-five, was sent to me in November, 1870, by Dr. J. T. Metcalfe, for deafness of the right ear, which had begun about a year previously, had rapidly increased during the past few months, and was associated with a disagreeable though

[1] Consult also Zaufal, in the Archiv für Ohrenheilkunde, II., p. 48; and Moos, in the Archives of Ophthalmology and Otology, II., pp. 127 and 190.

At the post-mortem examination of a patient who died in the hospital at Heidelberg, in 1869, I found the head of one malleus enlarged to nearly double its natural size by an exostosis which sprang, by a broad base, from the very top of the ossicle.

[2] Arch. f. Ohren., I., p. 140.

[3] American Journal of Otology, vol. i., p. 120

[4] *Ibid.*, p. 126

regularly pulsating noise. There had been no pain or discharge. At times slight attacks of vertigo had been experienced.

"On examination, H. D. right side = $\frac{1}{20}$; left, normal. After I had removed a slight layer of cerumen, a remarkable appearance presented itself. The whole drum-membrane was evenly and intensely reddened and strongly pushed forward in a bulging manner, except along the line of the malleus, which was situated apparently in a depression, and was marked at its free end by a white spot, in strong contrast to the other parts of the membrane. The whole membrane pulsated visibly and strongly, especially so superiorly, where there was a broad, light spot. The pulsation was synchronous with that of the carotids, and was arrested by pressure on the artery of the corresponding side. No distinct vessels were to be seen on the membrane, only a general redness. By Siegle's tympanoscope the drum-membrane could be forced in but little, and the pressure only rendered the pulsation more broadly and decidedly marked, and particularly so near the inner side of the malleus. By the otoscopic tube the heart-sounds were distinctly heard, but not so on the sound side. No air could be felt to enter the tympanic cavity by Valsalva's or Politzer's method, nor by the catheter. No redness or abnormal change was noticed in the external auditory canal.

"Thinking at first that I had to do with an exaggerated case of bloody serum in the middle ear, paracentesis was resorted to at the middle of the posterior segment, giving exit to blood which rapidly filled up the canal and flowed to the amount of one ounce in a few seconds, but was easily arrested by plugging the canal for a few moments with cotton. Attempts were made to inflate the tympanic cavity by the catheter, after bougieing the Eustachian tube up to its isthmus, but no air emerged from the puncture. On inspection no change in the appearance of the drum-membrane had resulted from the puncture, but three days later, when paracentesis was again resorted to, and after the cessation of a moderate hemorrhage, the drum was found collapsed and somewhat wrinkled; the hearing also was found to have increased to $\frac{2}{20}$. This improvement in hearing and condition of the drum-membrane only continued until the next day, and the pulsation was then felt as decidedly as ever by the patient, though to the eye it was much more feeble. I had by this time come to the conclusion that I had to deal with a vascular tumor in the middle ear, or that I had, according to Schwartze, a hypertrophied condition of the mucous membrane associated with an accumulation of bloody serum in the cavity. Leaning, however, to the first view, a consultation with Dr. Simrock, an acknowledged aural authority, was suggested and carried out. Dr. Simrock thought that the difficulty was due either to fluid in the middle ear, or, as he thought that he succeeded in forcing air through the Eustachian tube, that it was a collection of fluid in the tissue of the drum-membrane itself. A third puncture was made posteriorly, carrying the needle in until it reached the promontory—no air could be forced out. Convinced of the correctness of my diagnosis, on December 5th, a fourth puncture was made with a large needle, and a probe dipped in pure nitric acid was inserted through the opening into the middle ear. But little pain was occasioned by this treatment. As a result of the several punctures, it was noticed not only that after each the hearing-distance increased, but that the pulsation became less distinct. This subsidence became more and more

permanent, but the cicatrices of the punctures, yielding under the pressure from within, protruded almost teat-like from the drum-membrane, and after this application of acid a mass projected through the opening there made, and, spreading out and pulsating faintly, obscured nearly the whole membrane, and assumed a polypoid appearance in the course of a week. This mass was punctured, and a probe dipped in liq. ferri persulph. introduced into its depths, blanching it at once.

"The subsequent history is in brief this: The mass sprouting from the opening in the drum-membrane was with difficulty destroyed by the use of nitric acid applied, first, every second or third day for a number of times; afterward, at intervals of one or two weeks (as the patient lived out of the city); and subsequently, as the tissue became tougher, by the use of the acid nitrate of mercury, which was carried, by means of a thin film of cotton around the end of a fine wire, through the tympanic opening into the cavity itself. At times considerable pain was caused by the applications, but as a rule they were less distressing than would have been anticipated. Several attempts were made to extract pieces of the mass for microscopical examination, and the one or two small portions so obtained were reported, by Dr. A. H. Buck, to show nothing but scales of epidermis and débris, so changed by caustics as to be unrecognizable.

"By this treatment, the tumor, in the course of four to five months, was apparently destroyed, and it was observed that in the later cauterizations little or no hemorrhage occurred, and that when the punctures and applications—for they were sometimes conjoined—were carried into the tympanic cavity, the sensation was given that that space was more or less filled with a solid tissue. No air at any time was felt in the middle ear.

"On July 1, 1871, three weeks after the cessation of treatment, it is noted that H. D. $= \frac{2}{20}$; bottom of canal closed by a smoothly depressed, fleshy-looking membrane, still considerably though irregularly injected. No pulsation whatever to be seen or heard by the physician, and only very slightly perceived by the patient.

"August 4th.—Mrs. A. presented herself, on her way from Newport, stating that she had had only occasional pulsation in the ear in the erect position, but always when in bed. On examination it was found that the membrane had changed from its former fleshy appearance to one more normal. Now the malleus could be defined; the membrane itself was still irregularly patchy, of a pink hue in spots, but with some translucency. By the use of Politzer's inflation, for the first time air is heard to enter the middle ear by the otoscope. Ordered Valsalva's experiment to be practised at home.

"November 14th.—Drum-membrane is quite normal in the posterior part. Malleus clearly seen. Anteriorly, two months ago, was seen a red bulging spot, as if the tumor was returning there, but this to-day is not seen; the drum-membrane at this point being now mottled with white bands running from the malleus to the periphery. Tube slightly open by Valsalva's method: air readily enters. H. D. $= \frac{3}{20}$ to $\frac{4}{20}$. To use Politzer's bag daily.

"February 7th, 1872.—H. D. $= \frac{8}{20}$. Only hears pulsation when in bed. Drum-membrane still mottled and sparsely injected. No evidence of return of tumor.

"December, 1878.—No recurrence of the tumor. Reports herself as hear-

ing well. Ear giving her no trouble whatever. As patient was met in the street, exact information could not be obtained."

CASE LXXI. (Dr. Weir's Second Case.)—"A negro woman, thirty-five years of age, was seen by me December 8th, 1870, with the history that for four years past she had had 'beating noises' in the left side of her head, which were much increased by stooping, which position would also cause severe dizziness. Vertigo came on at times in the erect position. The hearing on the same side had also failed, and on her visit to me was $\frac{1}{12}$, while on the left side it was normal. She believed that her heart was affected, as she so distinctly and so persistently heard the sounds in her ear. There was, however, no cardiac lesion. She was much depressed and anxious by reason of her ear trouble. On inspection it was perceived that the posterior surface of the drum-membrane, and more especially its inferior portion, was of a reddish hue, with some vessels running over it, and that it was not only bulged outward, but that it visibly pulsated synchronously with the heart. Considerable injection of the malleus was also present. The Eustachian tube was pervious. By Siegle's otoscope it was seen that a faint line half-way up the posterior segment was movable. Paracentesis was, therefore, resorted to, and blood rapidly filled the canal, but was readily checked by a mop of cotton left a few moments against the drum. Politzer's inflation being then used, air freely escaped through the opening in the drum-membrane, after which H. D. = $\frac{6}{20}$. She was not seen again until June 1st, 1871, when she returned with the statement that since the puncture she had been very much better, and her hearing had improved and kept in fair condition until a week previously, when the latter rapidly diminished. Now H. D. = $\frac{1}{4}$. Left drum-membrane translucent everywhere, except at postero-inferior portion, where a roundish-red spot, the size of a small pea, was seen projecting forward, but not pulsating. By Siegle's apparatus, fluid line was again detected: it was rendered more clear after Politzer's inflation had been successfully used. Projection outward apparently the same.

"June 15th.—Paracentesis used for a second time, causing not only H. D. to rise to $\frac{1}{2}$, but also disappearance of the pulsating noise and redness. This absence of pulsation was noticed only a few days.

"August 1st.—Returned with symptoms of dizziness, deafness, and pulsation. Fluid seen in tympanic cavity. Redness and pulsation in drum-membrane observed as at first. Paracentesis, with needle carried in until it was arrested by bony resistance.

"November 7th.—Repeated paracentesis. Says that after every puncture the sound is lessened in intensity.

"December 11th.—Paracentesis twice in past week, and a probe wet with liq. ferri persulph. also introduced.

"She was not seen subsequently until February 18th, 1873, when the tumor was seen projecting still on the posterior and inferior segment of the drum, pulsating, and of a red color. Dizziness complained of more than ever. H. D. = 0.

"Up to March 24th, paracentesis was performed three times, with the subsequent introduction of cotton wound around a cotton probe and dipped in acid nitrate of mercury. This kept the opening patent, and several appli-

cations through it of a solution of chromic acid (100 gr. to ʒ j.) were made. Pulsation scarcely seen, and heard much less distinctly by the patient. Dizziness has also ameliorated.

"April 25th.—For the past three weeks she has been free from vertigo and pulsating noises. After a rest of two weeks after last state, a new and long slit was made in the drum-membrane, and the chromic acid freely applied in the drum-cavity by the cotton probe. Considerable swelling and discharge followed. This has nearly all subsided, and she feels better in her head than she has felt in five or six years. She can now stoop down and do her work without an unpleasant pulsation.

"June 25th.—Has had the paracentesis and chromic acid used but twice since last note. She has steadily improved, having had no pulsation and no dizziness until about ten days ago, when both were noticed after violent exertion. By the speculum the lower part of the drum was found to be quite normal, save a few cicatricial traces. At the upper part posteriorly and advancing a little forward on the roof of the external auditory canal, is seen a reddish mass about two lines wide and about three long, not pulsating, but evidently an extension of the angioma. She was then going into the country, and promised to return to me in the autumn if any further symptoms arose. She, however, did not do so. I have recently heard of her death in 1875, from phthisis.

"From her friends I learn that the noises in her ear slowly increased, and for several months prior to her death they caused her much annoyance and distress."

Case LXXII. (Author's Case).—Female, aged thirty-three, anæmic in appearance, and with œdema of the lower extremities. March, 1871. Patient states that two months previously she began to be troubled with a peculiar noise in the right ear, resembling in character—as she described it—the croaking of a bull-frog. This noise came at regular intervals, and was synchronous, as she had noticed, with the heart-beat. She had never experienced pain in the ear, and could not remember ever to have had an otorrhœa. She had also never noticed any difficulty in hearing. On examination with the speculum and reflected light, the following condition of the parts was found: the meatus was normal. The membrana tympani was moderately sunken. The handle of the hammer was whitish and sharply outlined. In the anterior superior quadrant the membrana tympani appeared to be perfectly normal; in the posterior superior quadrant it was so transparent that the long process of the anvil and head of the stirrup could be plainly seen through it. The entire lower half of the membrane presented a uniform and rather vivid red color, as if an exudation of blood or bloody serum lay upon its inner side. Such, at all events, was the diagnosis made at the time. Paracentesis was suggested, but the patient felt too weak and miserable to have anything done.

On the 17th of September, 1873, patient presented herself at the New York Eye and Ear Infirmary for the second time. Her story then was that two years previously she experienced some pain in the right ear, and afterward observed that her hearing in that ear was very imperfect. From that time to this there had been a constant, pulsating, roaring noise in the affected ear. On examination it was found that she could no longer distinguish the

ticking of the watch in the right ear. The membrana tympani was found to have undergone the following changes: the lower half of the membrane was still as brightly red as in 1871, but at the umbo, passing from before backward, the upper boundary-line of the red region ran upward and backward, instead of straight across. The posterior half of the membrane—chiefly the lower two-thirds—was now markedly convex and pulsated synchronously with the pulse at the wrist. Suction with Siegle's apparatus gave marked relief for the moment, but the throbbing instantly returned when the instrument was withdrawn. I advised against active interference at that time. Patient never returned.

Drs. Henry D. Noyes and Charles Laight verified the condition as described above.

Comments.—The points of interest and importance in this case may be briefly enumerated as follows:

1. The development of a new-growth in the middle ear, without any apparent cause for such growth (such as inflammatory irritation), either in the past history or in the present condition of the ear.
2. The highly vascular character of the growth.
3. The slowness of its development.

All three of the growths described above were strictly intratympanic, and furthermore they developed as it were spontaneously, without the provocation which an irritating purulent secretion is capable of affording. In the case which I am about to describe there was ample provocation for the development of some form of new-growth, but it is not clear why a strictly vascular growth—to which I have given the name of angioma cavernosum—should have been developed. Virchow, in his admirable treatise on tumors, devotes nearly two hundred pages to the consideration of vascular new-growths. He subdivides the angioma into a number of varieties, and applies the term cavernosum to that variety which is characterized by the existence of a network of blood-spaces, occupying the place and fulfilling the functions of capillaries. According to his view, the arteries, in a growth of this kind, pour their blood into these spaces, from which it then passes into the veins, and so back into the general circulation. Such a growth as this, on a small scale, came to my notice in the practice of the New York Eye and Ear Infirmary.

Case LXXIII.—The patient, a mechanic, nineteen years old, was admitted as an out-patient on the 2d of April, 1870. He stated that from the time when he was seven years old to that time he had been affected with a discharge from both ears, and with frequent earaches. He had also been

very much troubled by all sorts of noises in his ears. Recently he said, the noise in the left ear had been what might be termed a pulsating, humming noise. It had been constant; but at regular intervals, corresponding apparently to the pulse-beat, it would become louder. Running upstairs, or any other violent exercise, would aggravate the noise very much. When he awoke, on the morning of the day on which he visited the Infirmary, he found his pillow covered with blood, which was still escaping from his left ear. The hemorrhage, which was not associated with even a trace of pain in the ear, continued throughout the entire forenoon. Up to the time of which we are now speaking, the patient had never seen any blood in the discharge from either ear. On examination I found the left meatus filled with blood, partly fluid and partly clotted. I removed it by syringing out the ear, and then, on examination, I found that an oblong, dark-colored body, about the size of a small pea, was lying, apparently free, on the lower wall of the meatus. On closer inspection, however, I discovered that it was attached by a long and slender peduncle to the stump of the hammer. Dr. Robert F. Weir, in whose department the patient belonged, then divided the peduncle with slender scissors. No hemorrhage of any account followed. Almost immediately after its removal, the small growth was placed in a weak solution of chromic acid, the only preservative fluid that happened to be at hand at the time. Later, it was transferred to a bottle containing alcohol.

On the 25th of June the patient reported that, about the middle of May, the noises and the discharge had both returned, and had continued ever since. On examination of the left ear, I found a pinkish, vascular teat dependent from the stump of the hammer, and standing out in marked contrast with the pale mucous membrane which formed the background.

When the growth which had been removed from the ear had been sufficiently hardened in alcohol, it was imbedded in a mixture of wax and oil in equal parts. No special precautions were taken to place the tumor in such a position that the sections through it should include either the point of rupture or the stump of the peduncle; but fortunately, the middle sections included both of these points.[1] I will not attempt in this place to give a minute description of the anatomy of this tumor, but will simply state that it was found to consist almost entirely of blood-vessels, which radiated from an irregularly shaped central cavity, and which were separated from one another by a network of fibrillated connective tissue holding blood-corpuscles in its meshes. In some of the sections a large blood-vessel could be followed from the central cavity into the peduncle. In one of these, and also in other sections, the point of rupture could be distinctly traced from the central cavity to the periphery of the tumor. As the patient was asleep at the time when the hemorrhage took place, it must be assumed that it occurred through natural causes, operating within the tumor itself. The constant pressure, which first produced the marked dilatation of the blood-vessels, and then an obliteration of their walls at different points, and eventually led to the formation of the large central cavity, must have been the chief agency in producing the final rupture of the peripheral portion of the tumor. Virchow's view, that an angioma is an independent new-growth of vessels, just as much as an exostosis is an independent new-growth of bone, finds strong confirmatory evidence in the fact that, six weeks after

[1] Fig. 107, on the opposite page, represents one of these sections.

the original vascular tumor had been removed, a second one, of precisely the same vascular character, was found growing at the same spot.

Malignant Tumors.—Cancer or sarcoma of the middle ear is fortunately an extremely rare affection Thus, for example, so far

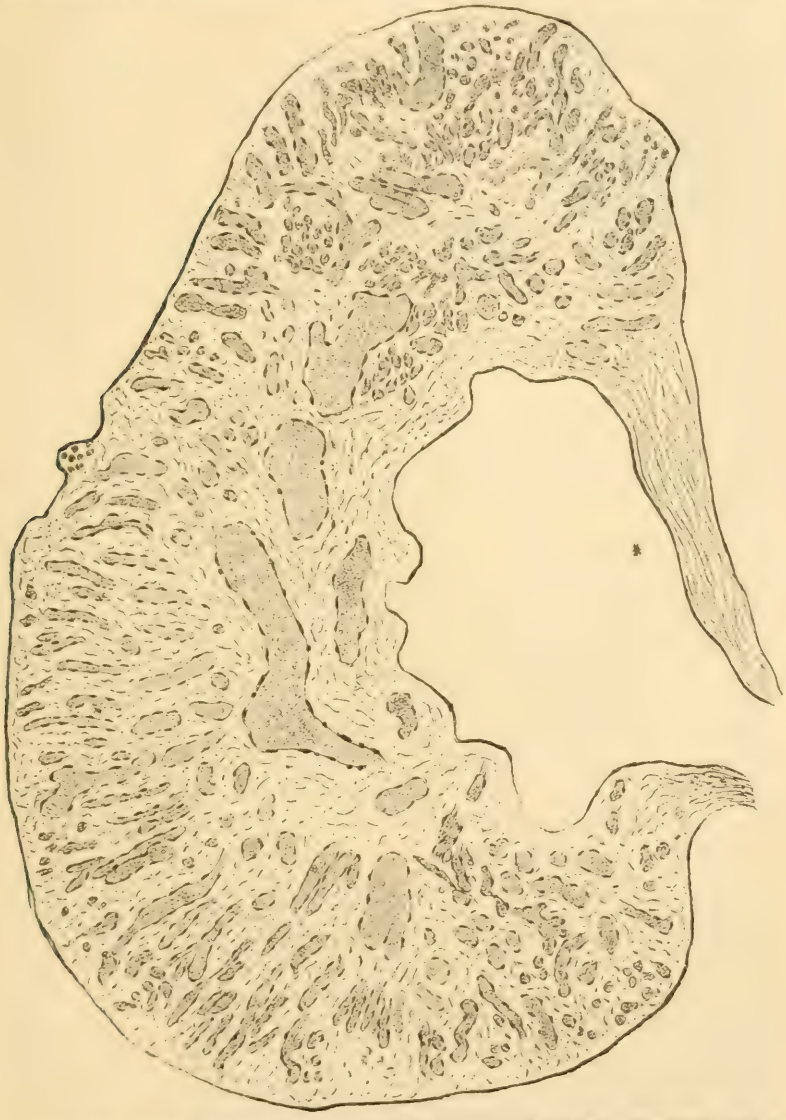

FIG. 107.—Cross Section of an Angioma Cavernosum of the Ear. Magnified only a few diameters. Drawn by Dr. Ira Van Gieson, from a specimen belonging to the author.

as I can learn, only one case of malignant disease of the middle ear had been reported[1] in this country, prior to the publication of a case by Dr. H. Knapp, in December, 1879.

This case was under my care for several weeks during Dr. Knapp's absence from the city, and it is the only instance of malignant disease of the tympanum that I have seen. A detailed report of this interesting case will be found in Vol. VIII, No. 4, of the *Archives of Otology*, and also in the last edition (1895) of the present treatise (p. 389). The growth, so far as could be ascertained, was a sarcoma of a mixed character (partly fibrous, partly cartilaginous, and partly composed of round cells in a homogeneous matrix). Ultimately it attained enormous proportions. A few other instances of malignant growths involving (and probably, but not certainly, originating in) the tympanic cavity have been reported.[2]

V. Cysts.

I can find in my records but six cases of well-defined cysts of the membrana tympani. In four of them there had previously existed a purulent inflammation of the middle ear. In one of these four cases, which I reported in detail, in 1872,[3] the cyst seemed to have formed between the layers of the drum-membrane. In the other three cases, however, the cyst-like tumor consisted of the posterior half of the drum-membrane, which, having lost its substantia propria through the prolonged pressure of the exudation in the tympanic cavity, had no longer been able to resist that pressure, and so gradually became converted into an elastic diverticulum. A case of this kind is pictured in Politzer's work (see Fig. 68). In acute cases I have frequently observed, during convalescence, a

[1] By Dr. Robertson, of Albany, in the Transactions of the American Otological Society for 1870.

[2] Five such are known to me. They are as follows: a case of round-cell sarcoma, reported by Dr. Arthur Hartmann, in vol. viii. of the Archives of Otology; another case of the same character, reported by Dr. J. Orne Green, in vol. xiv. of the same work; a case of destructive adenoma, reported by Dr. S. Sexton, in the New York Medical Journal for 1884; a case of carcinoma, reported by Dr. Gorham Bacon, in vol. xvii. of the Archives of Otology; and one reported by Sir William Dalby, in the Lancet for July 2, 1892. This authority also speaks of five other cases in which the cancerous growth originated in the tympanic cavity; but, unfortunately, he gives no details which prove clearly that they originated in this locality.

[3] In the Medical Record for November or December of that year.

very marked pouting of the membrane in the immediate vicinity of the perforation; and in one case of this character I found, on returning to the city after an absence of one week, that the simple pouting of the membrane had developed into a well-defined, almost pedunculate cyst, fully three millimetres in diameter. A minute perforation still existed, but it furnished such an inadequate outlet for the purulent secretion in the tympanum that the adjacent (probably atrophied) parts of the membrane were kept in a constant state of tension.



FIG. 108. – Cyst-like Protrusion of the Upper Posterior Quadrant of the Right Membrana Tympani. (After Politzer.)

In the remaining two cases the cysts were of quite a different nature. One of them occupied the very centre of the tympanic membrane, and measured nearly three millimetres in diameter. It was somewhat flattened, as if a portion of the fluid contents had been absorbed. In the other case the cyst occupied the lower two-thirds of the posterior half of the membrana tympani. It had evidently originated at the upper part of the membrane, and had, as it increased in size, dissected its way down to the lower part. Both of these cysts contained apparently pure serum, unmixed with blood; and both occupied spaces which they had made for themselves between the substantia propria and the outer dermoid layer So far as could be ascertained, there was no free exudation in the tympanum. Both of the cysts, after their contents had been evacuated, dried up and disappeared.

The largest of these cysts of the membrana tympani was about as large as a medium-sized pea. In every case but one the posterior half of the membrane was the part involved.

So far as the treatment is concerned, the plainest indication—in the case of cysts which communicate with the middle ear—is to establish a very free opening in the sac, and then to treat the case in the same way as we should a simple case of chronic suppurative inflammation of the middle ear.

VI. SYPHILIS.

In cases of syphilitic sore throat it is not an unusual thing to find the middle ear involved, on one or on both sides. As a rule, the picture presented to the eye of the observer is simply that of an

ordinary subacute catarrhal inflammation, the membrana tympani being red and swollen, without any appreciable bulging. The subjective symptoms also are in nowise different from those of an ordinary non-syphilitic catarrhal attack. In rare cases, however, pathological changes take place in the membrana tympani which are fairly comparable with those observed in the velum palati, and may therefore be described as specifically characteristic of syphilis. I refer to the development of a perforation—or of two perforations, as I have observed in two of my cases—in the membrana tympani, through a process of melting away, or necrosis, of the tissues.

From a mere inspection of the parts it is not unlikely that one may have difficulty in deciding whether the disease be of a syphilitic or of a tuberculous nature. The greater brightness of the red color, however, will aid in distinguishing the former from the latter, and the collateral evidence—physiognomy, history of the case, and perhaps the presence of other lesions of syphilis in other parts of the body—will enable the physician to render the diagnosis positive.

The prognosis is not very favorable. Antisyphilitic treatment may arrest the further progress of the disease and may effect a healing of the ulcerative process; but the hearing will rarely be restored to a perfect condition, as it often is after an equally severe non-syphilitic or non-tuberculous ulcerative disease of the middle ear. Nevertheless, a course of antisyphilitic treatment will often bring back a very useful degree of hearing-power.

VII. TUBERCULOSIS.

Tuberculous disease of the middle ear is by no means rare in private practice, and among the poorer classes in our large cities it is of almost frequent occurrence. When once the disease has reached a certain stage in its progress it is no longer possible to distinguish the visible lesions from those presented by chronic suppurative (non-tuberculous) inflammation of the middle ear. It is only by weighing these lesions in the light of the history of the case and of the general physical condition of the patient that we find ourselves forced to conclude that the damage which is revealed to us by aid of the speculum and reflected light has been wrought by tuberculous disease. On the other hand, in the beginning of this affection, a picture is sometimes presented which is decidedly characteristic; and besides, the symptoms accompanying these characteristic patho-

logical changes are quite as typical in their way as are the alterations in the tissues. A slowly increasing impairment of the hearing, with or without tinnitus, and perhaps a slight sensation of fulness in the affected ear, constitute the only symptoms throughout the first stage. In certain exceptional cases there may be a little pain, but, as a rule, it is entirely absent; and it is this absence of pain which constitutes a striking feature of the disease. After the lapse of a few days, or possibly of a few weeks, a discharge may make its appearance; and then, for the first time, the patient decides to consult a specialist about the condition of the ear. It is therefore not strange that we so rarely have the privilege of watching the advance of the disease at this early period of its course. The following illustrative cases will serve better to bring out into clear relief the characteristic features of tuberculous disease of the middle ear than any general account which I might frame:

CASE LXXIV.—*Primary tuberculous disease involving only a small part of the tympanic membrane; pulmonary complication; prompt arrest of the disease by a winter's residence in the Adirondack woods.*

Male, thirty-four years of age, of rather slender build, and somewhat pale. October 24th, 1896. Two months previously he had received a smart blow upon the left side of the head. As a result, the membrana tympani had been ruptured and the hearing of that ear had been somewhat impaired. Finding, at the end of two months, that the opening in the membrane was still unhealed, and that his hearing did not improve, he decided to consult a specialist. Present condition: In the lower posterior quadrant of the left tympanic membrane there is a nearly circular perforation with slightly reddened edges. The rest of the membrane is pale, but perhaps a little œdematous. No secretion in the tympanum or on the floor of the meatus. No apparent feverishness or acceleration of pulse.

Assuming that I had received a correct account about the drum-membrane having been ruptured, and finding that, after an interval of two months, the (presumably) slit-shaped opening had been converted into one of larger area and circular in shape, I expressed the suspicion that this peculiar ulcerative action was due to the agency of tubercle bacilli, and advised the immediate adoption of measures suited to the building up of the patient's general health. I prescribed no treatment whatever for the ear.

On the 2d of April, 1897, I saw the patient for the second time. He stated that about two weeks after I examined his ear, symptoms of pulmonary tuberculosis had manifested themselves; that immediately afterward he had placed himself under Dr. Trudeau's care, at his sanitarium in the Adirondack Mountains; that his pulmonary difficulty had healed rapidly; that his weight had increased to the extent of twenty-three pounds; and that he was then, so far as he could judge, in excellent health. I examined his left ear, and found everything in about the same condition as it was during the previous November. The edges of the perforation were pale and dry.

CASE LXXV.—*Apparently primary tuberculous ulceration of the upper and posterior part of the tympanic membrane; followed soon by a painful spinal disease; ultimately a cure, but with marked lateral curvature of the spine.*

Female, thirty years of age, ailing more or less during the past winter. Mother in excellent health; father looks poorly nourished and is markedly bow-legged. Of late, patient has noticed tinnitus and slight impairment of the hearing in both ears, but chiefly in the left. Present condition (March 13, 1881): slight congestion and infiltration of left tympanic membrane, dependent—as I then supposed—upon a subacute naso-pharyngeal catarrh. Usual treatment. At the end of about ten days I discovered that a small perforation had made its appearance in the posterior superior quadrant, close to the posterior periphery of the membrane. The adjacent cutaneous wall of the canal was slightly red and swollen. There had been no pain, and practically no secretion had accompanied the process. A few days before the actual loss of tissue was discovered, I noticed that the redness and infiltration had become more marked at this spot than elsewhere. My suspicions in regard to the tuberculous character of this peculiar ulceration were soon strengthened by the development of a region of tenderness somewhere over the spinal column. The patient's temperature was also found to be constantly higher than normal.

After several years of ill health, she was left with well-marked lateral curvature of the spine and with a perforation (in the left membrana tympani) a little larger than it was when she passed out of my care into that of the family practitioner.

CASE LXXVI.—*Repeated attacks of destructive tuberculous disease of the middle ear, associated with hypertrophic processes; apparently there were no other tuberculous foci in the body, although these attacks covered a period of at least seventeen years.*

Female, about thirty-five years of age, poorly nourished. Family history not ascertained. She consulted me on July 18, 1881, on account of an unpleasant sensation as if something were on the stretch between her left ear and the upper part of her throat. On examination I found that the left membrana tympani was intact, but much thickened and covered with a thin coating of pus. At its centre it was firmly adherent to the promontory, not directly, but through the medium of a thick mass of adhesions. I prescribed systematic douching with hot water.

During the past seventeen years I have seen this patient several times every year. For a long time I was in doubt as to the correct pathology of the case; but finally there was a succession of phenomena which made it fairly plain to me that I was dealing with a case of tuberculosis of the middle ear. In the first place, the condition observed at the first visit in July, 1881, soon changed in the following respects: slowly advancing (from above downward), painless ulceration of the posterior half of the membrane took place, and all my attempts to restrain the disease by the employment of silver nitrate, alum, etc., only served to make the condition worse. Then, under the influence of country air and a change in diet, the suppuration ceased and a new cicatricial membrane took the place of the former posterior half of the

membrana tympani, except at one very small spot where for months afterward I always found a minute perforation covered by a dry scab. On two different occasions, since 1890, there has been a repetition of the ulcerative process, and in both instances a cessation of the suppuration and a new healing of the membrane have ultimately taken place.

At the present time (January, 1898) the patient is passing through one of her periods of relapse. The posterior half of the membrane is entirely destroyed, and of the anterior half only the upper portion remains. Upon the promontory is seated a very thick cushion of firm tissue which extends well back toward the mouth of the antrum. While I am unable to see exactly what the condition of affairs is in the neighborhood of the stapes, the unusually good hearing-power of this ear shows plainly that as yet there has been no serious interference with the action of this ossicle.

Patient's general health has remained about the same through all these years. There has never been any reason to suspect the lungs or any other organ of being the seat of a similar process.

CASE LXXVII. — *Diffuse tuberculous disease (probably secondary) of the tympanic mucous membrane, with destruction of a small part of the membrana tympani, and with accumulation of cheesy material in the tympanic cavity.*

The patient, a clerk, about thirty years of age, in rather poor general health, and with all the external appearances of a person affected with phthisis, consulted me on the 30th of January, 1878, for marked deafness affecting both ears. He gave the following account of his trouble: During the previous autumn, as a result of sea-bathing, both ears had begun to discharge. He was very positive that the affection had developed without pain, and that previous to that time his hearing had been perfect. At the time when I saw him his deafness was so marked that I was obliged to speak in quite a loud tone of voice in order to make myself understood. On examination, I found the right auditory canal perfectly dry. The drum-membrane presented a peculiar whitish, polished appearance. A circular perforation, with sharply cut, somewhat thickened edges, occupied the anterior superior quadrant. The entire posterior half of the membrane was in a perceptibly bulging condition, and over its surface ran two or three dilated and sharply defined blood-vessels. When I tested this bulging portion with the probe I found that the drum-membrane was resting upon some solid substance. It felt more like a semi-solid substance (cheesy material, for example) than like bone. Anteriorly, the drum-membrane yielded readily to the pressure of the probe. On the left side, I found a little thin, purulent secretion in the auditory canal. The drum-membrane was in all essential respects like the right one. The only difference that I could discover was this: the perforation was slit-shaped, and occupied the anterior inferior quadrant, close to the periphery of the membrane; whereas in the other ear it was circular, and occupied the anterior superior quadrant, midway between the periphery and the handle of the hammer.

I expressed to the patient's physician the belief that cheesy material had accumulated in both middle ears, and said that I would like to make an incision through the bulging posterior half of one drum-membrane and endeavor to wash out the cheesy material; and if the operation proved successful, I

should want to repeat it on the other ear. My proposition was explained to the patient, but he declined to submit to any such operative interference.

In the first two of the cases narrated above, there is presented to us a group of pathological phenomena such as could scarcely owe their origin to any other agency than tubercle bacilli. A localized area of hyperæmia and infiltration in some part of the tympanic membrane—more often, apparently, in the posterior superior quadrant than anywhere else; the melting away and disappearance of the tissues so affected; and the absence of pain while these changes are going on—these are the early phenomena which characterize at least some of the cases of what I believe to be tuberculosis of the middle ear. The disease, after advancing to this point, may cease altogether; and yet it seems to leave behind unmistakable evidences of its recent presence—such, for example, as a decided lack of vitality on the part of the tissues. The tympanic membrane, which ordinarily possesses enormous reproductive powers, does not, in these cases, show the slightest tendency to regenerate the part destroyed. It is possible, however, that at some later period this regenerative power may, for a time at least, be recovered (see Case LXXVI.).

In another series of cases a wider area of the tympanic mucous membrane is involved, but yet the disease never seems to advance to the point of causing necrosis of any tissue except that of the tympanic membrane. An appreciable amount of pus is cast off by the mucous membrane, and, if the disease continues for a sufficient length of time, proliferative activity will also show itself in this membrane. It is a warrantable inference that the mucous membrane, in these cases, possesses sufficient powers of resistance to prevent widespread necrosis, but not sufficient to prevent an invasion by the bacilli. Case No. LXXVI. affords a good illustration of this exceptional type of middle-ear tuberculosis.

In a third series of cases (No. LXXVII., for example) the disease begins as a general invasion of the tympanic mucous membrane, associated with a fairly abundant formation of pus, and then the inflammation quickly subsides. But at this stage—and here we have the distinguishing feature of these cases—the residual pus in the tympanum does not disappear by absorption or by evaporation of its watery constituents, but undergoes a conversion into cheesy material, thus causing an obliteration of the cavity of the tympanum. What is the ultimate fate of these cases, I do not know.

Finally, in a fourth series of cases—and these, I suspect, are by

far the most numerous, at least among the poorer classes—the disease advances until the tympanic membrane, the ossicles, and even a large part of the mastoid bone, are entirely destroyed. Only one such case has come under my observation in private practice, but I am quite sure that I saw several of this nature during my service at the New York Eye and Ear Infirmary. (Two of these cases of extensive tuberculous disease of the ear are reported in a later chapter.)

In addition to the diagnostic features which I have already mentioned, there is one other which possesses a certain degree of value. I refer to the intolerance which a tympanum affected by tuberculosis shows, of anything like active local treatment. Douching with tepid water, in order to secure local cleanliness, and the application of a non-irritating antiseptic powder like nosophen, constitute practically all the local therapeutic measures which it is useful to employ.

Those who wish to have their diagnosis rendered more sure, may secure the aid of the bacteriologist. However, it seems to be admitted as a fact that the bacilli are not always discoverable in the pus taken from a tympanum which is obviously the seat of a tuberculous process. One must therefore be careful not to attach too much value to a negative result of the bacteriological examination.

CHAPTER XVIII.

DISEASES OF THE MASTOID PROCESS AND NEIGHBORING STRUCTURES.

ACUTE MASTOID DISEASE: ANATOMICAL AND PATHOLOGICAL CONSIDERATIONS; SYMPTOMATOLOGY AND DIAGNOSIS; ILLUSTRATIVE CASES; PROGNOSIS.

There are two quite different forms under which diseases of the mastoid process present themselves, viz.: those which represent an extension of an acute suppurative inflammation from the tympanum to the previously normal antrum and communicating pneumatic spaces; and those which result from the imprisonment of decomposing pus and other organic products in a mastoid antrum which has for months or years been the seat of a suppurative disease. To the first form we shall give the name of "acute mastoid disease," and to the other that of "chronic mastoid disease."

ACUTE MASTOID DISEASE.

Anatomical and Pathological Considerations.—In only a very small minority of all the cases of acute suppurative inflammation of the tympanum do the pneumatic spaces which open into it become involved to a decided degree. It will perhaps be worth our while to stop and consider why a serious involvement of the mastoid cells—as these spaces are commonly termed—should be such a comparatively rare event. In the first place, the anatomical relations of these cells, in the adult, are not favorable to the development of an inflammatory process. The antrum is virtually the posterior end of the tympanic cavity, for the passage which leads from the one to the other is, under normal conditions, of fairly large dimensions. Therefore it is reasonable to assume that in every attack of diffuse inflammation of the tympanum this recess must be involved to an equal degree with the remaining portions of the cavity. Consequently, when acute mastoid disease is spoken of, something more than this participation of the antrum is intended. A close examination of this outlying posterior end of the tympanum (Fig. 109) will

reveal to us good anatomical reasons why the great majority of inflammatory attacks do not extend beyond the immediate confines of this recess. The walls of the mastoid antrum are honeycombed with literally hundreds of minute openings which lead into the adjacent pneumatic spaces—some of them located in the mastoid process proper, others in the mass of bone lying behind the labyrinth, others still in that which constitutes the squamous portion of the temporal bone, and so on. These openings are all so minute that during the preliminary hyperæmia—the first stage of every

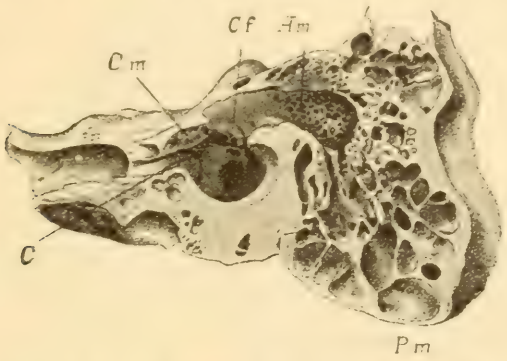

FIG. 169.—Section of the Left Temporal Bone, Showing the Mastoid Structures, the Antrum, and the Inner Wall of the Tympanum. (After Zuckerkandl.) *P.m.*, Processus mastoideus; *A.m.*, antrum mastoideum: *C.f.*, canalis facialis; between *A.m.* and *C. f.* is located the recessus tegmenti tympani; *C.m.*, canalis pro tensore tympani; *C.*, canalis caroticus in the background of the osseous Eustachian tube.

acute attack of inflammation—the swelling of the mucous membrane must close every one of them. In this narrowness of the entrances to the mastoid cells, therefore, we have a most serious obstacle to the development, in them, of a suppurative inflammation. But there is still another anatomical factor which tends to materially diminish the total percentage of cases of acute mastoid inflammation. I refer to the fact that quite a large number of individuals have mastoid processes which contain exceedingly few and only scantily developed pneumatic spaces. On this point, Zuckerkandl[1] says that, out of 250 mastoid processes which he examined, he found that pneumatic spaces were wholly lacking in 20 per cent of the specimens, and that perfectly pneumatic mastoid processes, without any diploëtic spaces, represented only 38.6 per cent of

[1] Makroskopische Anatomie des Ohres, in Schwartze's "Handbuch der Ohrenheilkunde"; Leipzig, 1892; Bd. I., S. 33.

the entire number. Unfortunately, Zuckerkandl's researches do not show—and I seriously doubt whether any amount of research would suffice to determine this point—whether we are warranted in considering the absence of pneumatic cells, in the specimens examined by him, as a perfectly natural peculiarity of construction, or whether these spaces may not have been present at some earlier period of the individual's life, and then have been obliterated by an unnatural hypertrophy of the bone, the result of a proliferative inflammation. However this may be, the fact remains that a consid-

FIG. 110.—Dissection (by chiselling) of the Mastoid Process, Showing the Free Communication which Exists between the Pneumatic Cells in the Body of the Process, and the Antrum. The upper ends of the bristles may be seen projecting into the cavity of the antrum. (From Nuhn's "Atlas of Surgical Anatomy"; slightly reduced in size.)

erable number of individuals have mastoid processes which are—by reason of their anatomical construction—not at all likely to harbor a serious suppurative inflammation.

When it is considered that an acute mastoid inflammation represents in reality a more or less successful invasion of these pneumatic spaces by pathogenic micro-organisms which have gained an entrance into the tympanum, it will be readily appreciated that still other factors besides the anatomical ones enumerated above must play a part in diminishing the frequency of acute mastoid disease. Thus, for example, the following factors undoubtedly have some share in promoting or hindering such an invasion of the mastoid cells: the particular kind of microbe which has invaded the tympanum; the duration of increased intratympanic pressure; and the

degree of defensive power possessed—at the time of the attack—by the mucous membrane of the middle ear. As I have already dwelt upon these different points at some length in a previous chapter, I do not need to say anything further on the subject in this place.

In the case of infants or young children, a recognizable degree of involvement of the mastoid process is encountered relatively more often than it is in adults; and, as a rule, it is a complication which, in these little patients, is far less serious in its nature. A study of the anatomical relations shows readily why these statements are likely to be true. At birth, and even during the first

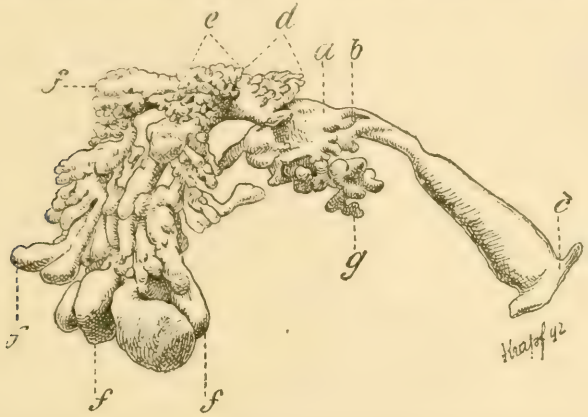

FIG. 111.—Metallic Corrosion-preparation of the Cavities which Communicate with the Tympanum. (After Siebenmann.) *a*, Tympanic cavity; *b*, tympanic orifice of the Eustachian tube; *c*, pharyngeal orifice of the same; *d*, aditus ad antrum; *e*, antrum; *f*, pneumatic cells of the mastoid portion of the temporal bone; *g*, pneumatic cells located under the floor of the tympanum.

year of life, the mastoid process consists of a small, flattened tuberosity which contains only one pneumatic cell of material size, viz., the antrum (see Fig. 112). This cavity lies very close to the outer surface of the bone, and, besides, the latter is often perforated at this point by one or more minute channels for the transmission of small veins. Sometimes also an emissary mastoid vein of appreciable size traverses the thin wall of bone at or near this point, and thus affords an easy outlet for the products of any inflammation which may take place in the adjacent antrum. In any case of a young child, therefore, in which all these favoring anatomical factors exist, an ordinary and comparatively mild suppurative inflammation of the middle ear is likely to produce at least hyperæmia and infiltration of the skin covering the corresponding mastoid

process; and if at the same time the tympanic membrane happen to be somewhat more resistant than usual, the inflammatory exudation may effect an outlet for itself at this point more easily than through the tissues of the tympanic membrane. In this way, also, a collection of pus may form beneath the skin and periosteum covering the mastoid process. In an infant or a young child, therefore, these manifestations on the outside of the mastoid process must not be looked upon as necessarily indicating a grave and threatening extension of the middle-ear inflammation. They are rather to be taken as evidence that, in the advance of the inflammatory process, the degree of intratympanic pressure has become so great as to call urgently for the establishment of adequate drainage.

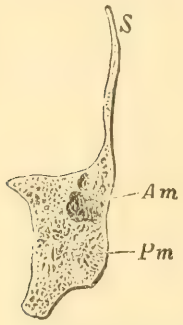

FIG. 112.—Transverse Vertical Section of the Mastoid Process Belonging to a Child Two Years Old. (After Gruber.) *S*, Squamous portion; *Am*, mastoid antrum; *Pm*, mastoid process. (Below and upon its inner side the antrum is surrounded by diploëtic bone substance.)

Already at the age of three or three and a half years the mastoid process will be found to be, in all essential respects, almost as fully developed as it is likely to be at maturity. It is only in the slightly diminished size of the process as a whole, and perhaps also in the inferior strength of the bony framework, that it differs from that of adult life. On the other hand, if we compare a number of adult pneumatic mastoid processes we shall scarcely find any two of them alike in the distribution and size of the cells. It is not an exceptional thing to find one or two large pneumatic spaces at the very tip of the process, while those which are situated higher up may be comparatively small. Then, again, in certain skulls the large cells may be distributed in a fairly symmetrical fashion throughout the mastoid bone (Fig. 111). This same lack of regularity in construction characterizes the location of the sigmoid groove (in which lies the lateral sinus), on the inner and posterior aspect of the mastoid process. At one time—and this is probably true of the majority of cases—it is situated so far backward that ample space is left between it and the posterior wall of the external auditory canal for all operative work that may be required. Then, at another time, it encroaches to such an extent upon either the anterior or the external boundary of the mastoid process that great care has to be exercised in our use of the chisel or the scoop. I remember one

instance, for example, in which the lamina of bone that separated the sigmoid sinus from the outer surface of the mastoid process measured not more than one-sixteenth of an inch in thickness. In this case the very first chip of bone removed with the chisel exposed to view the bluish wall of this large vein.

The *mastoid emissary vein* which conveys venous blood to the sigmoid sinus from the soft parts in the neighborhood of the occiput and along the lower portion of the corresponding side of the head varies decidedly in size in different individuals, or may even be absent altogether. When it is present, it enters the mastoid bone at different spots within a given area. Ordinarily, the presence or absence of this vein is a matter of no special consequence; but there are exceptional cases in which this vessel is so large that dividing it with the knife may lead to very troublesome hemorrhage (see further on, under Illustrative Cases.)

The area of distribution of the pneumatic spaces is a subject which demands some consideration. Superiorly, they may extend as high as to within half an inch of the temporo-parietal suture. In this comparatively thin part of the temporal bone they are separated, on the outer side from the periosteum, and on the inner side from the dura mater, by a dense layer of bone which varies from one to three millimetres in thickness. Anteriorly, the pneumatic cells extend forward over the external auditory canal. Posteriorly, they cease somewhat abruptly, that is, without any material diminution in size, in the immediate vicinity of the temporo-occipital suture. Hyrtl, according to the authority of Schwartze, found three skulls (among six hundred which he examined for this purpose) in which the pneumatic cells extended even into the occipital bone. I once, in trephining the skull, found pus between the outer and inner tables of the occipital bone, a short distance back of the temporo-occipital suture, and thought, at the time, that it had travelled along the diploëtic spaces from a large abscess which existed in the body of the mastoid process. In the light of Hyrtl's discovery, it now seems to me to be more probable that the pus found at this remote spot was really lying in pneumatic spaces which stood in direct communication with those immediately surrounding the abscess.

The *sigmoid sinus* ordinarily occupies a groove in the bone in the immediate vicinity of the posterior limits of the mastoid cells; but, as I have already stated above, the position of this groove varies greatly. The small venous channels in the mastoid pneu-

matic cells communicate at several points with the sigmoid sinus, and those of the antrum and tympanic cavity pass through the petro-squamous fissure (in the bony roof which covers both of these regions) into the cranial cavity, and pour their blood into the superior petrosal sinus. Thus, as it appears, there is no lack of channels along which bacteria may travel to vital parts of the head.



FIG. 113.—View of the Mastoid Antrum, as seen by a person looking from within outward. (Natural size.) The short process of the anvil may be seen resting against the lower edge of the entrance from the tympanic cavity into the antrum. Toward the right the outer wall of the antrum (the background of the cavity, in the picture) shows distinctly the numerous small openings which lead from this cavity into the adjacent mastoid cells. Furthermore, the picture enables one to judge very satisfactorily of the relations of the antrum to the membrana tympani,—the only part of the middle ear that it is usually possible for us to see by direct inspection. (Copied from a photograph taken by Prof. B. Alexander Randall, of Philadelphia.)

Furthermore, the posterior end of the antrum is in very close proximity to the sigmoid fossa, in which lies the extension of the lateral sinus—here called the sigmoid sinus; the distance between the two varying from three to six millimetres. The distance from the outer limit of the antrum to the external surface of the mastoid process varies from twelve to twenty millimetres (from one-half to three-quarters of an inch). In cases of hyperostosis the antrum may be found to lie at even a greater distance from the outer surface of the bone.

Finally, I have still to mention the *close proximity of the facial canal to the mastoid cells* (see Fig. 114). This channel, after pass-

ing horizontally backward, just above the niche for the oval window, curves rather sharply downward at the inner end of the lower margin of the entrance to the antrum. Both at this point and below, where it pursues a straight course downward, it is in very close proximity to pneumatic cells, and consequently is exposed to a the pathological processes which may take place in them.

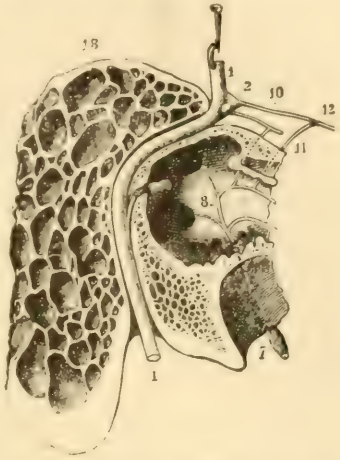

FIG. 114.—Diagram Showing the Relations of the Facial Nerve to the Different Structures of the Temporal Bone. (After Testut.) 1, 1, Facial nerve; 2, ganglion geniculatum; 7, petrous ganglion, or ganglion of Andersch; 8, Jacobson's nerve, crossing the inner wall of the tympanic cavity; 10, great superficial petrosal nerve; 11, great deep petrosal nerve; 12, cranial twig of the Vidian nerve, formed by the fusion of the two preceding petrosal nerves; 18, pneumatic cells of the mastoid portion of the temporal bone.

In a preceding paragraph I have spoken of the fact that in a large majority of the cases the acute inflammation does not extend beyond the immediate confines of the tympanum and antrum—or, in other words, that the invading bacteria, in these acute attacks, rarely penetrate into the pneumatic spaces of the mastoid process. But after they have once gained an entrance into these cavities, the conditions which exist there are pre-eminently favorable to their accomplishment of the maximum degree of damage to the tissues.

The pathological alterations which are found in these cells at different stages of the disease are the following: marked hyperæmia, enormous hypertrophy of the delicate mucous membrane which lines the spaces, necrosis of the septa of bone, and the breaking down of all these inflamed parts into pus. In addition to these changes, phlebitis and plugging of some of the small veins which are located in the mastoid process may occur, and may eventually lead to phlebitis and thrombosis of the sigmoid sinus, and to a general pyæmic infection. A certain amount of septicæmia is doubtless present in every one of these acute suppurative cases.

Symptomatology and Diagnosis.

There is no single symptom or external pathological manifestation which, taken by itself, points with unfailing accuracy to the existence of an acute inflammation of the mastoid pneumatic spaces. Our diagnosis must invariably rest upon several items of evidence, and especially upon the sequence of these symptoms and visible alterations. Nevertheless, some of these signs of an existing mastoid inflammation do at times possess an almost absolute diagnostic value. This is true, for example, of the development of tenderness on pressure over the mastoid process, in adults, a few days after the onset of the acute inflammation of the middle ear. It is also true of the development, under similar circumstances, of a swollen and prolapsed condition of the posterior and upper cutaneous wall of the external meatus in the vicinity of the tympanic membrane; and still other valuable indications might be mentioned. On the other hand, it is a thoroughly established fact that well-marked mastoid disease may develop in a normal (*i.e.*, non-sclerosed) mastoid process without either of the distinguishing marks which I have just enumerated; indeed, in exceptional cases, the accompanying subjective symptoms and the outward manifestations may both be of the most insignificant character, wholly out of proportion to the extent and gravity of the local disease.

In order to bring these points out more fully, I will consider here separately and somewhat in detail the relative value of these different symptoms and signs.

Pain.—In acute inflammation of the middle ear, pain in the mastoid region points to involvement of the pneumatic spaces only when it persists despite the establishment—either by natural processes or by artificial means—of an opening in the tympanic membrane. It is fair to assume that when once an adequately large opening has been provided in this membrane, all increased intratympanic pressure must come to an end; or, in other words, that whatever pain may be due exclusively to pressure in this cavity must then disappear. And it is equally fair to assume that if the pain persists after such an outlet has been provided, it must then be due to pressure upon an inflamed mucous membrane situated outside the tympanic cavity, or, in certain exceptional cases, to pressure upon certain intracranial organs. Thus, by exclusion of one of the two possible seats of the pain, we reach the conclusion

that the other—viz., the pneumatic spaces—is the region in which the inflammation is progressing. This persisting or frequently recurring pain may be referred by the patient to the deeper parts of the ear as well as to the region immediately behind it; and oftentimes the occipital region, the side or the top of the head, and even the frontal region, may be complained of more decidedly than either of these two localities. It is not unlikely that these differences in the localization of the pain are due to the varying degrees to which different plexuses of the trigeminal nerve are affected by the neighboring inflammation in the temporal bone.

Finally, when pain persists despite the presence of an ample-sized drainage-opening in the membrana tympani, and despite the fact that operative interference has already removed all possible causes of pain in the domain proper of the mastoid pneumatic cells, we are warranted in suspecting the presence of an accumulation of pus around the sigmoid sinus, between the dura mater and the wall of the skull, or even in the brain substance itself.

On the other hand, one must be careful not to assume, in a case in which there are indications pointing to the existence of mastoid disease, that this diagnosis is erroneous simply because the symptom of pain is lacking. There are cases on record in which the patient made scarcely any complaint of pain, and yet operative interference revealed the existence of advanced disease of the mastoid pneumatic spaces.

Tenderness on Pressure.—Tenderness on pressure over the mastoid region, when it develops in the course of an acute suppurative inflammation of the middle ear, affords a valuable indication of the spread of the disease to the mastoid pneumatic spaces. I can think of only one other condition in which such tenderness on pressure may develop; I refer to an inflammation of the external auditory canal which spreads backward over the outer aspect of the mastoid bone. If the patient is seen for the first time after the walls of the outer canal have become so swollen that it is no longer practicable to obtain a satisfactory view of the tympanic membrane, the physician will have to depend largely on the history of the case in determining the precise significance of any tenderness or swelling of the mastoid integuments which he may find.

Occasionally a small gland is found lying upon the outer surface of the mastoid process, and this may easily, even in the course of a comparatively mild inflammation of the middle ear, become somewhat enlarged and tender. The finding of a small movable body

under the skin will reveal to us the true explanation of this form of local tenderness on pressure.

It is an important matter, in testing the mastoid region for tender spots, to subject every part of the bone to fairly firm pressure; for it is not a rare thing to find such tenderness on pressure only at some one or two comparatively small spots—as, for example, at the extreme posterior limit, below, or quite deep down upon the anterior aspect of the bone. The conditions found at the time of the operation often harmonize perfectly with the results previously ascertained by such a digital examination; pus being present only in certain pneumatic spaces situated at points corresponding to the spots where tenderness was previously demonstrated to exist. The spot, however, where tenderness is most often and earliest found is situated rather high up and close to the line where the skin is reflected over the back of the auricle. It represents that part of the surface of the mastoid process which lies nearest to the posterior end of the antrum. The significance of tenderness at this spot is, as one would naturally anticipate, much less serious than it is at spots situated farther away from the antrum.

Finally, if a blister, or the tincture of iodine, or leeches have already been applied to the skin behind the ear, as is very apt to be the case, it will not be possible for us to draw any safe conclusion in regard to the presence of tenderness on pressure in the mastoid region; for all of these therapeutic procedures are likely to leave the skin of this region in a somewhat sensitive condition.

Hyperæmia and Œdema of the Skin Covering the Mastoid Process.—If tenderness on pressure develops behind the auricle, this symptom is very apt to be followed in a short time by redness and swelling of the skin in the same region. When these alterations do not appear, we may explain their absence in one of two ways: either the mastoid inflammation is of a mild type—a mere hyperæmia of the mucous membrane which lines the pneumatic spaces; or else the tenderness on pressure is not due to the slight inflammatory involvement (through an extension by way of some of the numerous minute vascular channels which exist in the central part of the outer wall of the bone) of the overlying soft parts, but merely represents the pain caused by pressure transmitted through a somewhat elastic wall of bone to the sensitive soft parts within. Redness of the skin is more often lacking than œdema, and the latter may spread throughout a wide area—even as far as to the occiput or the forehead.

Prolapse of the Upper and Posterior Cutaneous Wall of the Auditory Canal in the Neighborhood of the Membrana Tympani. —If the invading micro-organisms have already succeeded in penetrating beyond the immediate walls of the antrum, the mass of bone which separates the latter cavity from that of the external auditory canal will become,—if the bone be not of too dense a character,—at a comparatively early stage, the seat of active inflammatory changes; and the outward sign of this osteitis will be a corresponding inflammation of the skin located on the posterior and upper wall of the meatus near the tympanic membrane. On the other hand, if this portion of the temporal bone possess such a dense structure that the bacteria cannot readily penetrate it, the phenomenon which I have just described will not appear, and our estimate of the extent and activity of the neighboring mastoid inflammation will have to depend upon other evidence. In some instances of severe inflammation of the middle ear the periostitis involves the entire osseous portion of the meatus, the swelling of the lining membrane being greatest near the tympanic membrane, and shading off gradually from this point outward. My recollection is, that in the majority of these instances the disease has eventually subsided without giving rise to a serious inflammation of the mastoid cells; and from this circumstance I am disposed to believe that, as a rule, this symmetrical periostitis has an entirely different significance from that which is localized in the posterior and upper parts of the canal. It represents, I suspect, the effects of a direct invasion of bacteria from the tympanic cavity, while the latter should rather be considered as a mere localized periostitis which has developed in sympathy with the contiguous bone inflammation.

An abundant discharge of creamy pus through the opening in the membrana tympani is a very trustworthy indication of suppurative disease of the pneumatic spaces. Such a copious discharge of pus, as one can readily understand, must necessarily come from an area much larger than that of the tympanic cavity; and it must therefore be the mastoid region from which this large quantity of purulent fluid—amounting in some cases to several teaspoonfuls in the course of the twenty-four hours—escapes. Inasmuch as such a free flow of pus cannot possibly take place through the natural channels which lead from the pneumatic spaces to the antrum, we are warranted in assuming that the process of breaking down of the bony septa has already progressed so far as to remove many of those which are located in the vicinity of the antrum, and thus to establish a

free outlet for the pus. The period when this change is likely to take place is that of the second or third week of the disease.

Facial Paresis or Paralysis.—It is only in very exceptional instances that an acute suppurative inflammation of the mastoid cells is associated with any disturbance of the facial nerve, and then, as a rule, the trouble is only of slight degree and of brief duration. When such a paresis, however, does develop, it furnishes good evidence that the inflammation must have involved the pneumatic spaces to a considerable degree.

Extension of the Inflammation to the Soft Parts Below the Mastoid Process; Bezold's Symptom.[1]—Sometimes the tissues on the side of the neck, a short distance below the tip of the mastoid process, become inflamed and swell rather rapidly into a hard, flattened, and very sensitive tumor. The skin covering this matted cake of inflamed glands and other soft parts lying in front of the sterno-cleido-mastoid muscle is red, œdematous, and firmly adherent to the underlying tumor. This rapid infection of the tissues on the side of the neck is held by Bezold to indicate that some of the inflammatory exudation in the pneumatic spaces has escaped from the lower end of the mastoid process, either through a congenital defect in the bone, or through an opening which owes its origin to a pathological process of softening. Bezold's explanation, which is now generally held to be the correct one, receives strong support from two facts, viz., the simultaneous diminution or disappearance of the pain, and the diminution or even entire cessation of the discharge from the middle ear by way of the perforation in the tympanic membrane.

In the order of development of the different phenomena which may be considered as diagnostic of mastoid disease, Bezold's symptom comes, as a rule, rather late; that is, after the pain, the tenderness on pressure behind the ear, the hyperæmia and œdema of the skin in this locality, and the prolapse of the posterior and upper cutaneous wall at the inner end of the meatus, have made their appearance. The phenomena described here, it must not be forgotten, bear a very close resemblance to those observed in cases of sigmoid thrombosis.

Phlebitis of a Mastoid Emissary Vein.—An area of localized inflammation is sometimes observed, in the course of an acute attack

[1] Ein neuer Weg für Ausbreitung eitriger Entzündung aus den Räumen des Mittelohrs auf die Nachbarschaft u. s. w.; Deutsche medicinische Wochenschrift, 1881, No. 28.

of mastoid inflammation, at one of the following points: directly below and a little posterior to the mastoid process; a short distance behind this bone and a little above the level of the tip; and still farther back, not far from the occipital protuberance. The possibility that these areas of inflammation in the scalp may be due to phlebitis of a mastoid emissary vein was first suggested, I believe, by Dr. J. Orne Green, of Boston. When such a localized inflammation is encountered in a case which for other reasons is believed to be one of mastoid disease, the phenomenon should certainly be considered as furnishing very strong corroborative proof of the correctness of the diagnosis. Similar areas of inflammation have been observed at points above the mastoid region, even as high up as on the vertex and as far forward as in the temporal region, and their presence in these localities suggests the possibility that the lymphatics may also serve as channels along which the infection is conveyed from the pneumatic spaces to distant parts of the scalp. The possibility of an escape of pus from an extradural abscess, through one of the natural openings in the skull, must also be borne in mind in connection with these localized areas of inflammation beneath the scalp. Their possible relation to sigmoid thrombosis must also not be overlooked.

Septicæmic and Pyæmic Phenomena.—While it is scarcely possible for a suppurative inflammation of the mastoid pneumatic spaces to run its course without giving rise to a certain amount of septicæmia, experience shows clearly that this—as expressed by the degree of elevation of the body-temperature—does not bear any fixed relationship to the severity or extent of the suppurative disease. It is only in youthful individuals that we are likely to find this normal (if I may so term it) relationship as a prevailing characteristic; but in adults the rise in temperature is often insignificant, even when, through the presence of other signs, we are confident that a severe suppurative disease is in progress. However, cases are encountered in which the behavior of the body-temperature furnishes us with valuable diagnostic aid. Thus, for example, the persistence of a high temperature after a free opening has been established in the membrana tympani may justly be interpreted—in the absence of any other demonstrable cause—as pointing strongly to mastoid involvement. And yet even in these cases there must be additional evidence before we can safely make a diagnosis of mastoid disease. A persistent high temperature, in conjunction with pain in the region of the ear, with tenderness on pressure over the mastoid region, or with

prolapse of the posterior and superior cutaneous wall of the external auditory canal, may be considered as good evidence of the existence of this disease. On the other hand, if this additional evidence is lacking, and especially if the conditions in the tympanic cavity are steadily improving, we should institute a more rigid search for disease in some other part of the body. Among the puzzling cases of this character which have come under my observation, I can recall one in which a beginning pulmonary tuberculosis, another in which an endocarditis, and a third in which a limited pleurisy, explained the persistence of an elevated body-temperature; but in each of these cases the discovery of the true cause was not made by the attending physician until several days of anxious uncertainty had elapsed.

When *pyæmic symptoms* occur—as shown by irregular chills and by the development of metastatic or embolic foci of inflammation in other parts of the body—we may be sure that the disease has passed the stage of a mere suppurative inflammation of the mastoid cells, and has involved to a serious degree some contiguous venous channel. First, periphlebitis, and then phlebitis, with entrance of infected products or of the infecting agents themselves into the venous circulation, are the changes which take place in such cases. As the condition known as pyæmic thrombosis of the sigmoid sinus is one of great importance, I will consider its symptomatology in a separate section, a short distance further on.

Symptoms on the Part of the Brain.—If the products of an acute suppurative mastoid inflammation are not afforded, by surgical interference, a sufficiently early outlet, or if an adequate drainage channel is not established spontaneously through a process of softening of the inflamed bone substance somewhere at the periphery of the mastoid process (*e.g.*, anteriorly, in the external auditory canal; externally, in the central part of the body; or inferiorly, in the tip), there is great danger that an outlet may form in an upward direction into the cranial cavity. And when this happens, the occurrence will soon announce itself by one or more of the following symptoms: nausea and vomiting, general headache or pain of a more localized character, delirium, convulsions, drowsiness, thick speech, photophobia, strabismus, optic neuritis, dry and heavily coated tongue, and perhaps alterations in the rhythm and rate of the pulse-beat and respirations.

ILLUSTRATIVE CASES.

CASE LXXVIII.—*Simple hyperæmia of the mastoid pneumatic cells, such as is often encountered in the course of an acute inflammation of the middle ear; rapid subsidence of the pain and tenderness after paracentesis of the membrana tympani.*

Female, thirty-two years of age, and in robust health; she was attacked with an influenza on the 9th of November, 1872, and had more or less fever with a constant catarrh of the eyes and nose. On the 12th the right ear became involved, the symptoms being moderate deafness, roaring, and some pain. Watch heard at a distance of six inches. External auditory canal healthy. Membrana tympani dull, opaque, and rather flatter than normal. The air during inflation entered the middle ear with a dry sound. Four leeches were applied in front of the ear.

November 14th.—The leeches afforded only partial relief. Membrana tympani is œdematous in appearance and somewhat convex outwardly.

November 15th.—Patient passed a bad night. The pain is again severe, and is referred by her to the entire side of the head. Tenderness on pressure over the mastoid process, but no redness or swelling of the integuments. The posterior wall of the external auditory canal has also become tender upon pressure. A free vertical incision through the posterior half of the membrane was followed by an oozing of bloody serum from the wound. By inflation of the middle ear through the Eustachian catheter the serum was made to escape in such quantity that it ran down over her cheek.

November 16th.—Comparatively free from pain last night. The watery discharge continued through the night, as shown by the stains on the pillow. The tenderness has disappeared, and patient feels quite well again. No subsequent return of the pain.

CASE LXXIX.—*Another case of hyperæmia of the mastoid pneumatic cells, of a more pronounced grade; further advance of the disease checked by paracentesis of the membrana tympani, by incisions through the swollen cutaneous walls of the external auditory canal, by a Wilde's incision, and by the application (later) of four leeches to the skin in front of the tragus.*

Female, about thirty-five years of age, and of a rather delicate constitution. January 20th, 1877. Two days ago, while suffering from a bad "cold in the head," and not very long after snuffing salt water for the relief of her trouble, she was seized with a rather sharp pain in the right ear. Yesterday, the pain in the mean time having grown worse, five leeches were applied behind the ear. These afforded only temporary relief, and, as a consequence, she was able to get but little sleep during the night. To-day the pain has been severe. On examination with the speculum and reflected light, the membrana tympani, and especially the upper and posterior portion, is found to be red and swollen. Two small blebs, springing from the lower wall of the canal, conceal the lower part of the drum-membrane from view. Incision of posterior half of the membrane afforded escape to a drop of bloody serum. Warm douche to be used freely. Patient to remain in bed.

January 21st.—She has passed another night of suffering. There is now

a free sero-purulent discharge, but the pain has not abated. On examination the posterior wall of the meatus is found to be markedly swollen in the vicinity of the drum-membrane. Tenderness over the mastoid process, but no redness or swelling of the integuments. Patient being under the influence of ether, two free incisions were made through the inflamed tissues of the external auditory canal and posterior fold of the drum-membrane, and a third through the mastoid integuments. Poultices to be applied, and patient to be given 10 minims of Magendie's solution of the sulphate of morphia.

January 22d.—She passed a fairly comfortable night, and to-day feels comparatively free from pain.

January 23d.—Pain again moderately severe. The discharge from the ear is now decidedly purulent. Pulse, 104; temperature, 99.2° F.

January 24th.—Pain still persists throughout the entire right side of the head, and is especially noticeable whenever she coughs.

January 25th.—Last evening pain again became quite severe. Temperature rose to a little over 100° F. Four leeches were applied in front of the tragus. This morning patient feels better. The discharge is now profuse. Temperature normal. Patient is conscious of a constant escape of pus through the Eustachian tube into the back part of the nose. From the character of the matter expectorated (absence of mucus) and from the sensations experienced by the patient, I have very little doubt that the discharge referred to comes from the middle ear by way of the Eustachian tube. Swelling of inner end of meatus diminishing.

January 26th.—Continued improvement. Temperature, normal; pulse, 88. Tubal discharge diminishing; discharge by way of the meatus still active.

February 3d.—Patient is now entirely free from pain, and there is very little discharge from the ear.

February 14th.—The perforation in the drum-membrane has healed, and very little swelling of the parts remains. An insignificant scar indicates the location of the incision behind the ear. Watch heard at a distance of four inches.

Case LXXX.—*Acute suppurative inflammation of one middle ear, with spontaneous establishment of an outlet in the upper wall of the meatus a short distance from the tympanic membrane; extension of the disease to the mastoid pneumatic spaces; intercurrent attack of inflammation of the metacarpo-phalangeal joint of the left middle finger, preceded by marked diminution in the amount of pus discharged from the ear, by a chill, by vomiting, and by profuse sweating; disease arrested by the usual mastoid operation.*

Male, aged thirteen. February 23d, 1885. Sharp earache in right ear ten days previously, followed by a profuse discharge. Comparatively little pain since then, but the discharge continues to be profuse. Examination shows that the pus is escaping, not through the membrana tympani proper, but through a pouting orifice in the upper cutaneous wall, a short distance from the drum-membrane. Slight tenderness behind the ear. Temperature, 100.5° F. Douche to be used several times daily with a saturated solution of boric acid.

March 1st.—At noon to-day he had a slight chill; temperature, 104° F.;

pulse, 92. The chill was followed by a noticeable increase in the amount of discharge. No increase in the mastoid tenderness.

March 2d.—Persistent vomiting and retching last evening. Mastoid tenderness more marked to-day; temperature, 102.4° F.

March 3d.—Marked diminution yesterday in the amount of the discharge. He has taken fifteen grains of quinine daily during the past two days. Yesterday he had a profuse sweat. This morning he began to complain of pain in the metacarpo-phalangeal joint of the left middle finger. With the pain was associated a small, well-defined red spot, which gradually spread and soon presented all the appearances of an acute inflammation of the joint. The least movement caused great pain in the part. On inquiry, I ascertained that he had never before had anything like rheumatism. Nevertheless, I put him on ten-grain doses of salicylate of soda every four hours. [This attack may have been one of rheumatoid arthritis, or else one of pyæmic (metastatic) origin.]

March 4th.—The redness and swelling have not extended appreciably beyond the limits of the knuckle. The pain in the part is already beginning to subside.

March 6th.—Patient passed a bad night, the pain in the right side of the head being severe. It is referred chiefly to the right temple. No redness or œdema of mastoid integuments, but still some tenderness over the upper portion. Calibre of the external auditory canal markedly reduced in size. Discharge still profuse, and now at times a little bloody. Perforation of bone advised.

March 7th.—He is again feeling better; temperature normal. Ether was administered to the patient, and the drill was applied at the usual spot. At a depth of half an inch the bone appeared to be noticeably softened. On breaking into the antrum, creamy pus welled up to the surface of the bone. In chiselling out the drainage groove I opened into some of the more superficial cells, which were found full of thick pus. In washing out the antrum I used an unusually strong solution of bichloride of mercury (1 to 1,000), and, as a good deal of it passed through the Eustachian tube into the pharynx, it gave him not a little discomfort afterward for at least an hour.

Patient made a rapid and complete recovery, the discharge from the meatus ceasing entirely on March 9th, and the external wound healing permanently on or about April 1st.

Case LXXXI.—*Unusually slow development of suppurative disease of the mastoid diploëtic spaces; well-marked outside evidences of the underlying disease of the bone; operative interference; complete recovery.*

The patient, a resident of Orange, N. J., twenty-one years of age, of a healthy constitution, consulted me September 4th, 1872, for a painful affection of the mastoid process. He stated that in June he was seized with a severe pain in the ear after bathing. The pain continued for three or four days, and then stopped, leaving him quite deaf in the affected ear. At the expiration of two weeks a discharge appeared, and this had continued since until the fourth or fifth day previous to his visit to me. Shortly before the discharge stopped, he noticed some tenderness behind the affected ear. The pain, which for four days had been growing steadily worse, was referred to the mastoid

region, whence it extended upward and backward to the parietal and occipital regions. Tinnitus. Appetite poor. Countenance pale. Watch heard at a distance of four inches on the affected side. The skin covering the mastoid process red and swollen. External auditory canal diminished in calibre by the falling forward of the posterior cutaneous wall. Membrana tympani invisible. Incision of the integuments covering mastoid process. Free escape of pus and blood. The periosteum was dissected up a short distance on either side, and the underlying bone seemed healthy. The following day, September 5th, while pressing pretty firmly against the bone with a steel director, it seemed to me that the point of the instrument met with less than the usual resistance. I then attempted to perforate the outer shell with a small steel drill, and in doing so suddenly exposed a large abscess which occupied nearly the entire mastoid process. The opening was further enlarged with a conical drill until the little finger could be admitted, and the contents were then entirely evacuated. Tent inserted and patient allowed to return to his home, where he said that he could get further medical treatment. The incision of the integuments on the previous day had already greatly alleviated his sufferings.

On the 14th of November following he wrote: "The pain never returned since you performed the operation, and the wound healed inside of ten days. I went to a doctor to have it dressed, but he refused to have anything to do with it, and said that it was a very dangerous operation, and might have killed me; so I went to a friend of mine and had it dressed. In ten days the outside was all healed, and I could hear a great deal better. Now I can hear my watch tick about twenty-four inches from my ear."

Case LXXXII.—*Acute suppurative inflammation of the mastoid pneumatic spaces, with meningeal hyperæmia, but without any pain—in or around the affected ear or in the head generally—after the sixth day; no discharge from the ear at any time; prompt recovery after operative interference on the eleventh or twelfth day of the disease.*

Female, fifteen years of age, and apparently in robust health. About January 4th, 1895, she, along with several members of the family, was taken ill with what seemed to be the grippe. Very soon afterward she complained of pain in the ear and at various points on the right side of her head. These pains were supposed to be of a purely neuralgic character, as they finally centred themselves in the region of the right cheek. Her temperature at this time was found to be 104° F. In the course of a day or two she seemed to have recovered her usual health and was permitted to return to school.

On January 10th the pains in the ear and on the right side of the head returned, but were not specially severe, and soon passed away entirely. She felt considerable general malaise, however, and her temperature was found to be decidedly above the normal (104° to 105° F.). As the pain was referred sometimes to one side of the head and sometimes to the other, and as other members of the family were ill at the same time with what seemed to be the grippe, it was believed that the elevation of the temperature was attributable wholly to the action of the grippe poison, and that the pain was of a simple neuralgic character and not dependent upon any local inflammatory action. Nevertheless, the attending physician examined the ears and found a little

congestion of the right membrana tympani; but it did not seem to him that it was sufficient to explain either the elevation of temperature or the pains occasionally experienced by the patient. *At no time after January 10th did she experience any pain in the right ear.*

On the morning of the 13th she had a decided chill and the temperature rose to 105° F. It was then thought that the ear trouble might be more serious than was at first supposed, and I was accordingly asked to see the patient. On examination I found the posterior superior quadrant of the right membrana tympani and the immediately adjacent soft parts red, swollen, and tensely convex. On expressing my surprise that she was not in suffering on account of this localized inflammation, the patient reiterated the statement that she had no pain in the ear, but simply felt the beating of her pulse in that locality. A free incision was made (without the aid of an anæsthetic), and a drop of pinkish pus (quite thick) was evacuated. For several hours afterward the ear was frequently douched with hot water, and hot flaxseed meal poultices were kept applied the greater part of the time. Calomel was also administered every hour in one-tenth-grain doses.

On the 14th, I found that she had vomited twice during the night, and that her temperature had not gone below 104.5° F. No perceptible discharge from the ear had yet shown itself.

On the 15th, I found that she had again vomited during the night, that her temperature remained high, that she had experienced no pain in the ear, and that, despite the douching and frequent poulticing, no discharge whatever had made its appearance. An examination revealed the fact that my incision had completely healed, and that the posterior and upper part of the drum-membrane still formed with the adjacent soft parts a slightly convex red mass of skin of a somewhat parched aspect. Slight tenderness on pressure over the central part of the mastoid process was also found to have developed since the previous visit. I accordingly advised that the mastoid process be opened without further delay; and this operation was performed on the same day. The conditions found were the following: the antrum filled with pus and granulation-tissue; the bone in the immediate vicinity of this cavity perceptibly softened; everywhere else throughout the mastoid process a high degree of hyperæmia and abundant granulation-tissue in the pneumatic cells.

On the morning of January 16th, the day after the operation, her temperature was found to be normal, and it remained so from that time forward. Her pulse-rate also fell to 90; and in the course of another day or two it fell to 72, and remained at about that rate afterward. Before the operation the pulse-rate had varied from 104 to 108.

The external wound closed on January 28th.

CASE LXXXIII.—*Acute inflammation (possibly suppurative) of the mastoid pneumatic spaces, with apparently no pain after the first or second day of the attack; operation on the fourteenth day; final recovery somewhat delayed by bad sanitary conditions of the patient's home.*

Child, six years old, in good general health. I was called to see the case, for the first time, on May 17th, 1895. The parents stated that six days previously their daughter had complained of pain in the left ear, and that

soon afterward a discharge from this ear was noticed, but that it had lasted only about one day; and that from that time to the day on which I saw her there had been no further complaint of pain in the ear. The temperature, however, had varied from 102° to 105.2° F. On examination, I found the left membrana tympani red and markedly bulging. There was no redness or tenderness of the skin behind the auricle of the affected ear. An anæsthetic was administered, and I made a long, crescent-shaped incision in the left drum-membrane, giving vent to a little pinkish pus. Frequent douching with hot boric-acid solution was prescribed. A rather scanty discharge continued during the next twenty-four hours, and then ceased entirely.

May 23d.—There has been no further discharge from the left ear since the 18th; but on the afternoon of the 21st I found a drop or two of yellowish pus at the inner end of the external auditory canal. From day to day, however, I have noted a slowly increasing prolapse, downward and forward, of the skin lining the upper and posterior portion of the osseous external auditory canal; this condition being first noticeable in the vicinity of the membrana tympani. The child has made no complaint, at any time, of pain in the ear, and she has acted as if she were entirely free from any such distress. Furthermore, the membrana tympani has steadily grown paler and more natural in appearance, and every attempt to elicit any sign of distress, when I pressed firmly upon different parts of the left mastoid process, has failed. Day after day, however, and despite the fact that she has taken daily, for three or four days in succession, from twelve to fifteen grains of quinine, the body temperature has risen every afternoon to 104° and even 105° F.

May 24th.—Still no complaint of pain, and no evidence of any distress. But the temperature continues to rise to 104° or 105° F., and early this morning the child vomited. There is also now a little tenderness over the central part of the mastoid process, and the prolapsed condition of the cutaneous wall of the canal continues, although it is perhaps less marked than it has been. Operation advised and performed during the afternoon of the same day. When the outer surface of the mastoid bone was laid bare, the peculiar shaven-beard appearance commonly observed in the stage just preceding that of actual necrosis was recognized over a central area about as large as a three-cent silver bit. This corresponded to the only spot where tenderness on pressure had been elicited at the last moment. A high degree of venous hyperæmia (the blood was unusually dark) and the filling up of many of the pneumatic cells and the antrum with granulation-tissue were the only lesions noted. Pus was not found at any point: but if any of the cells had contained pus, the copiousness of the bleeding would not have permitted us to recognize its presence.

The subsequent progress of the wound was every way satisfactory. Healing took place without the formation of more than a few drops of pus. The skin behind the wound remained perfectly normal in appearance. The child made no complaint of pain in the ear, and ate and slept quite well. But every afternoon her temperature rose to a high level—rarely under 104°, and on one occasion as high as 107° F. The administration of quinine was again resorted to, and it was found to exert a limited influence upon the temperature. The doses were increased until the child finally took twenty-seven grains in the course of twenty-four hours. This brought on vomiting, and

it was then decided (June 10th) to remove the child from her residence, in the upper part of the city, to the country.

During the summer I learned that the child had begun to improve almost immediately after she was taken out of the city, and that she had entirely regained her health in the course of a few weeks. It was ascertained, furthermore, that the drainage of the city house was in a most defective condition.

CASE LXXXIV.—*A remarkable instance of extensive disease of the mastoid pneumatic spaces in a young child who for weeks had been looked upon by her guardians as essentially well; unusually quick healing of the wound, after the operation.*

Child, about six years old. General health always good. Mild attack of scarlet fever early in April, while absent from home. Child complained of pain in the right ear for two or three days; a discharge then made its appearance, and from that time onward she made no further complaint of pain. She ate and slept well, and played with her toys as if she felt perfectly free from pain. The discharge was at no time abundant, but it gradually diminished in quantity, until, at the time when the preceding statement of the case was made to me by the child's father (May 7th, 1895), it had very nearly ceased. As the family expected to sail for Europe on May 22d, and as the child could not conveniently be brought from the country before the 20th, the father wished to know whether he might safely postpone bringing her to see me until that date. I replied that I believed, from his account of the case, that he might safely allow the child to remain in the country until the time mentioned.

On May 20th, the child was brought to New York, and I examined the affected ear. The external auditory canal was of normal size and appearance, and contained a little stringy mucus which escaped through a very small perforation in the centre of the membrana tympani, which was entirely free from hyperæmia, but showed a little fulness in the vicinity of Shrapnell's membrane, chiefly posteriorly. Usually I attach great importance to this condition; but as the child had experienced no pain in the ear for several weeks past, as there was neither redness nor tenderness of the mastoid integuments, and as the discharge appeared to be of a purely mucoid character and very scanty, I made up my mind that no serious significance should, in this particular case, be attached to the slight prolapse of the skin at that part of the external auditory canal which corresponds to the floor of the mastoid antrum. I therefore dismissed the case as one which needed no further active treatment until the family should reach London and could obtain the services of some physician competent to thoroughly remove a fairly large mass of hypertrophied adenoid tissue which I had discovered in the vault of the pharynx.

The following morning (May 21st), the child complained of pain in the right ear, and soon afterward the nurse discovered that the skin behind the ear was red and swollen. Her temperature was taken and found to have reached 103° F.

On the following day—that on which she was to have sailed for Europe—I operated and found that pus was escaping outward through a very fine

opening in the cortical portion of the mastoid process. The bone substance in the immediate vicinity of this small opening appeared to be dead. Pus, abundant granulation-tissue, and softened bone structure were found throughout the greater part of the mastoid process. The activity of the bleeding and the abundance of granulation-tissue found at this depth made it impossible for us to determine whether the antrum contained any pus or not. A considerable area of softened bone was removed from the region situated directly above and behind this cavity.

On the eighth day following the operation the outside wound had entirely healed. A slight mucoid discharge, however, still continued from the external auditory canal; but this ceased entirely on the fourth or fifth day after the removal (by my associate, Dr. Robert Lewis, on June 3d) of quite a large adenoid growth from the vault of the pharynx. A decided improvement in the hearing also became noticeable at the same time.

Case LXXXV.—*Acute suppurative inflammation of the mastoid pneumatic cells in an individual affected with well-marked diabetes mellitus; operation; fetid pus and gas found in the cells; subsequent infection of the subcutaneous cellular tissue of the corresponding side of the head; wound healed at the end of about five weeks after the operation.*

Male, forty-nine years of age, and, up to the time of the present illness, strong and apparently healthy. Early in March, 1895, he had an attack of what seemed to be the grippe. His right ear soon became involved, and he experienced a great deal of pain in it. At the end of two days a discharge made its appearance, and he then obtained some relief from his earache. From that time to the day on which he called to see me (April 10th, 1895) the discharge from the ear had been constant and abundant. The pain had come in paroxysms, and at times had been severe. During the preceding two or three days there had been some redness, swelling, and tenderness of the skin behind the right ear, and he had been unable to obtain more than brief snatches of sleep on account of the severity of the pain, which by this time involved the entire right side of his head. His urine was examined, and found to be loaded with sugar. He was questioned in regard to the quantity which he habitually passed, but apparently he had not voided a greater amount than might fairly be termed normal. An examination of the ear revealed the fact that the upper and posterior cutaneous wall of the right external auditory canal was prolapsed to such a degree that it was not found possible to obtain a view of the drum-membrane. The body temperature was found to be 99 F., and the pulse 102, full and regular; but the patient looked and felt decidedly ill. There were very decided evidences of mastoid periostitis.

On the 11th of April, ether was administered as an anæsthetic, and the usual operation was performed upon the affected mastoid process. The surface of the exposed bone showed, near its centre, the shaven-beard appearance indicative of the plugging of a number of small blood-vessels in the cortical portion of the bone. Pus and gas bubbles were found at a very slight depth from the surface. The odor which quickly filled the air in the immediate vicinity was that of sulphuretted hydrogen with a certain sweetish flavor added to it. In all directions pus and dead bone were found, and

from the antrum and immediate surroundings the flow of dark blood was unusually active. In the immediate vicinity of the sigmoid fossa I found the bone perfectly black and softened. I carefully scraped away all this affected bone until I reached the hard cortical substance which constitutes the immediate bony support of the lateral sinus; and as this seemed to be natural in consistence, although somewhat darker than it should be, I decided not to break through into the sigmoid fossa. The usual dressings were applied after the mastoid excavation had been thoroughly irrigated with a 1–2,000 bichloride solution and then dusted with a powder composed of one part of iodoform and four of boric acid (as suggested by Macewen).

During the first four days following the operation the patient experienced a good deal of pain throughout the right side of the head; and all the soft parts behind and above the wound, and extending to a considerable distance from it, presented an angry and swollen appearance, almost suggesting erysipelas. But the body temperature did not rise above 100.3° F. Toward the end of this period I evacuated some thin pus from beneath the scalp above the wound, and on the next day (April 17th) I found the patient almost free from pain and with considerably less inflammation around the wound. The urine was examined a second time, and found still to be loaded with sugar.

From the 17th of April onward the patient made a rapid recovery, without drawbacks of any kind. On the 21st, he returned to his home in the country. A third examination of his urine was made about one week or ten days later, and sugar was still found in it in abundance. On the 10th of May, he called to see me, and I found that the wound had become reduced in size to a very small granulating orifice. It probably healed entirely in the course of the following four or five days.

PROGNOSIS.

Acute suppurative mastoid inflammation, if left to itself or if treated in the impotent fashion which prevailed even as recently as thirty years ago, is a disease remarkably full of disagreeable and dangerous possibilities; such, for example, as a lifelong discharge from the ear or from an external fistulous opening; a permanent paresis or paralysis of the facial nerve; periphlebitis and phlebitis of the sigmoid sinus or the superior petrosal sinus; metastatic abscesses; and inflammation of the membranes or of the substance itself of the brain. We have no means of giving precise figures in regard to this matter, but I believe that I shall not exaggerate the truth if I venture to say that, in the first half of the present century, at least one in four of these acute mastoid cases terminated fatally, whereas at the present time not less than nine out of ten of them make a perfect recovery. All through these years the tendency, on the part of aural surgeons, has been, first, to operate at an earlier stage of the disease, and so to arrest its advance beyond

the strict domain of the pneumatic cells; and then, in those cases in which the disease had already involved neighboring structures, to follow it, in their explorative work, to the remotest corners which it may have reached. Aseptic and antiseptic methods have contributed greatly to the success of these bolder and more thoroughgoing surgical measures. Indeed, it rarely happens at the present time that one can rightly say, in any given case, that the disease has advanced so far that it would be a hopeless task to operate. Brain symptoms, paralyses, and pyæmic manifestations are no longer accepted as evidences that the disease has advanced so far that we may not entertain a reasonable hope of fighting it successfully. As contraindications of a more serious character may be mentioned, too feeble heart power, or the presence of a pneumonia or a pleurisy. On the other hand, while it must be admitted that the existence of diabetes mellitus adds to the gravity of the prognosis, this fact by itself should not deter us from operating.

CHAPTER XIX.

DISEASES OF THE MASTOID PROCESS AND NEIGHBORING STRUCTURES (Continued).

ACUTE MASTOID DISEASE: OPERATIVE TREATMENT.

When an acute inflammation of the mastoid cells does not yield promptly to such simple measures as paracentesis of the membrana tympani, hot poulticing (or the use of the Leiter coil, if that be preferred), douching the meatus with hot water, and perhaps, in addition, local blood-letting (leeches, incision of the cutaneous wall of the meatus),—the proper course to adopt is to perform what is usually termed a mastoid operation.

The question is often asked: How early in the course of the disease does it ever become necessary to perform this operation? In reply to this I can simply say that I do not remember ever to have operated before the ninth day after that on which the patient first experienced pain in the ear. As a rule, however, the simpler therapeutic measures which are commonly adopted at the onset afford more or less relief, and thus encourage us to persevere with these same measures in the hope of arresting any further advance of the disease. In this way it very often happens that the fifteenth, or the twentieth, or possibly even a much later day, is reached before the conclusion is finally adopted that operative interference can no longer be postponed with safety to the patient. Usually some new symptom indicative of the true character and extent of the disease appears and removes from the physician's mind any doubts which he may still entertain in regard to the wisdom of operating without further delay. In an earlier section of the preceding chapter (that relating to Diagnosis) I have discussed very fully the relative values of the different symptoms which occur in this disease, and I may therefore omit any further reference to the subject in this place. I will simply make one additional remark. The cases in which the greatest difficulty is experienced in reaching a conclusion whether to operate or not, are those in which the conditions and symptoms, for days together, seem to point to a spontaneous recovery. In such cases of doubt it is well to remember that the error of operating in

a case which might have recovered without the aid of an operation is one which carries with it very little that is evil; whereas the error of postponing operative interference for too long a time may cost the patient his life. Every aural surgeon can, I am sure, recall more than one actual instance of the fatal consequences of such postponement of operative interference.

In the earlier operations upon the mastoid process, the chief object aimed at was to establish a free opening between the antrum and the outer world by means of a drill or other kind of boring instrument. Despite the manifest imperfections of this method, it proved to be adequately efficient in a large percentage of the acute cases. Prof. H. Schwartze, of Halle, Germany, was the first to recognize these imperfections, and to advocate the more thorough method which is now universally adopted, and which has very appropriately been termed the Schwartze operation.

THE SCHWARTZE OPERATION.

Preliminary Measures.[1]—The hair having been closely shaved from the side of the head over a considerable area immediately above and behind the ear, these parts and the auricle should be thoroughly scrubbed with soap and hot water, by means of a nail-brush. Then, according to Macewen[2] of Glasgow, they should be sponged first with spirits of turpentine, in order to dissolve all the oily matter, and afterward with methylated alcohol. Finally, cloths saturated with a moderately strong solution (1 to 40) of carbolic acid should be kept applied to the parts for at least one hour before the time for the operation—if possible, for forty-eight hours. In the place of carbolic acid I am in the habit of using a 1–1,000 bichloride solution.

While such precautions may seem superfluous, in view of the fact that the main object of the operation is to reach and expose thoroughly to view a focus of infection (thus, in an instant, apparently undoing all the good effects of these precautions), nevertheless it is possible for the surgeon, if he do not adopt such measures, to introduce into the wound bacteria which are of a more injurious nature than those which are already present in the mastoid cells.

[1] The following details are given in the hope that they may be of some assistance to physicians who are compelled to operate at the patient's residence, and not in a well-organized hospital.

[2] "Pyogenic Infective Diseases of the Brain and Spinal Cord," London, 1893

Then again, the attitude of being constantly on one's guard against such powerful agencies as the pathogenic micro-organisms is much safer for the surgeon to adopt than that of indifference for one stage of the operation and minute carefulness for the next.

The external auditory canal should also receive as thorough a cleansing as circumstances will permit. In cases of middle-ear disease of comparatively recent date, a thorough syringing of the canal with a 1–4,000 or 1–5,000 bichloride-of-mercury solution will doubtless accomplish the desired purpose; but in chronic cases, accompanied by a discharge of foul pus from the antrum or the epitympanic space, no amount of syringing will render the canal aseptic. In such cases, therefore, it is a good plan, after thoroughly syringing the passage, to dust a little dermatol or iodoform, or iodoform and boric acid (1 part of the former to 4 of the latter, as suggested by Dr. Macewen), over the fundus of the canal, and then to insert loosely into the orifice some iodoform gauze.

The hands of the operator and his assistants should be subjected to the same sort of cleansing and antiseptic measures, viz., thoroughly scrubbing them with a nail-brush, rinsing them in fresh water, then soaking them for four or five minutes in a 1–1,000 bichloride solution or a one-per-cent formalin solution,[1] and finally transferring them for two or three minutes to a vessel containing wood alcohol.

All the instruments and cloths that may be required during the operation should first be thoroughly sterilized. Boiling in simple water (or in water to which sodium bicarbonate has been added) for fifteen or twenty minutes will accomplish the desired purpose. A much more convenient method, however, is to subject all these things for fifteen or twenty minutes to the fumes of a heated pastille of formalin. A complete apparatus for this purpose is now obtainable at some of the instrument-makers.[2] After the instruments have been disinfected they should be laid in deep hard-rubber or glass dishes containing sterilized water. What these instruments are will appear further on, in the description of the operation itself. There are a few things, however, which may be spoken of more conveniently at the present time. In the first place, a large piece of rubber cloth (say thirty inches wide by four or five feet

[1] Made by adding one ounce of Schering's forty-per-cent standard solution of formalin to two and one-half pints of sterilized water.

[2] Meyrowitz, at 104 East Twenty-third Street, New York, manufactures a formalin sterilizer of copper which weighs only a few pounds.

long) will be found extremely useful. One end is to be placed under the patient's head and shoulder, and the other is allowed to hang down over the side of the operating table, directly over a pail, tub, or slop-jar. The following things will also be needed: Several roller bandages of gauze, preferably two inches wide; about two quarts of a standard 1–1,000 bichloride solution; two or three gallons of thoroughly hot sterilized water; from one to two dozen small sponges of aseptic gauze (small squares of sterilized lintine answer very well as sponges in the later stages of the operation); two or three sterilized porcelain or smooth stoneware pitchers and basins of fairly large capacity; a supply of freshly made iodoform gauze (ten per cent); some plain sterilized gauze; a powder-blower (with rubber air-bulb attached) filled with iodoform or with xeroform; and some sterilized absorbent cotton. Every operator will be likely to add to or modify this list in accordance with his individual preferences.

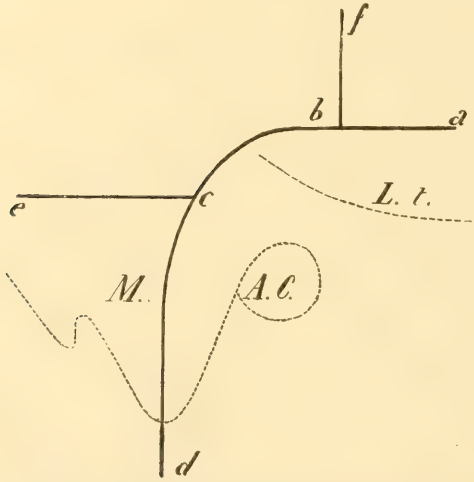

FIG. 115.—Diagram Showing the Relations of the Different External Incisions. *M.* Mastoid process, the outlines of which are indicated by the dotted line; *A. C.*, orifice of osseous external auditory canal; *L. t.*, linea temporalis: *d c b*, the usual mastoid incision, which, under certain circumstances, may have to be extended forward to *a*; *e c*, horizontal incision required in all cases in which exposure of the sigmoid sinus is contemplated; *f b*, vertical incision required in cases in which an abscess of the temporosphenoidal lobe is suspected.

As a final preparatory step, all the hairy part of the head should be completely enveloped with the folds of a gauze bandage freshly soaked in a 1–1,000 bichloride solution.

The External Incision.—This should begin (see Fig. 115) at a point on a level with the top of the auricle and directly above (the body being in the erect posture) the orifice of the external auditory canal. At first the knife should be carried a short distance backward, in a horizontal direction, and then it should gradually be turned so as to cut vertically, the incision being extended as far down as to the tip

[1] Provision must be made for keeping this water hot for at least an hour or an hour and a half.

of the mastoid process. In certain special cases the horizontal part of the incision must be extended about half an inch farther forward, in order that the operator may gain easier access to the external meatus. In this horizontal portion of the incision, also, it may be found sufficient, in a few cases, to divide the skin alone; but in the majority of instances the fascia and the underlying auricularis superior muscle will also have to be divided, as otherwise it would not be possible to gain sufficiently free access to the entrance of the osseous external auditory canal. In the vertical part of the incision the point of the knife must be carried through the periosteum down to the surface of the bone.

Separation of the Periosteum from the Bone, and Control of the Bleeding.—The incision which I have just described is sure to divide the posterior auricular artery and perhaps one or two other small arterial branches. The bleeding from these divided vessels may be disregarded for the moment, or, if it be too active, pressure may be made by an assistant upon the trunk of the posterior auricular lower down, until the separation of the periosteum shall have been effected. This latter step is accomplished by the aid of a flat, blunt-edged periosteum elevator, care being taken not to tear and bruise the parts any more than is absolutely necessary to effect the desired separation. As soon as the bony surface of the mastoid process has been exposed to view over a sufficiently large area, our attention should next be directed to the arrest of the bleeding. This can usually be accomplished quickly and effectively by the application of artery clamp forceps to the bleeding-points. These instruments are left *in situ* throughout the operation, and may easily be held to one side by an assistant, thus leaving the operating field entirely free. If the deeper inflammation has not, up to the time of the operation, involved the mastoid integuments to any appreciable degree, this application of three or four pairs of forceps to the chief bleeding-points will be found sufficient to stop all troublesome hemorrhage. But if the mastoid integuments have been in a state of congestion and infiltration for several days previous to the operation, the application of the artery forceps will not suffice to keep the bleeding within bounds. The prolonged congestion of these parts will have rendered countless dilated arterioles incapable of contraction, and the active oozing of blood from the cut surfaces may cause considerable delay. Sometimes stuffing the wound rather tightly with a small sponge wrung out of decidedly hot water suffices, in the course of a few minutes,

to arrest the bleeding. Another device is to plunge a small piece of sponge or lintine in water that is nearly scalding, and apply it for a moment or two to the surfaces of the wound. The bone itself also, in some cases, bleeds so actively as to annoy the operator greatly in his work. Very hot water will often control this bleeding from the interior of the mastoid bone, but in some cases the annoyance persists up to the end of the operation.

When the surface of the mastoid bone has thus been fully exposed to view, the condition which it presents to the eye of the observer may or may not afford some indication of the pathological alterations which are going on in the underlying cells. Oftentimes the aspect presented is that of an absolutely natural bone, and yet beneath this normal cortex the pneumatic spaces may be the seat of combined suppurative and hypertrophic processes of a most pronounced character. Then, again, minute bleeding-points, scattered over the surface of the bone, will reveal plainly the engorged state of the deeper-lying vessels; or, if the disease has advanced beyond the stage of simple dilatation of the veins, and has reached that of stasis, the surface of the bone, especially at that point where it approaches nearest to the mastoid antrum, will probably present the shaven-beard appearance; that is, there will be a group of well-defined blackish spots at this part of the surface of the bone. Each such dark-colored spots represents a section of a minute thrombus; and when all the small veins of the bone are in the same condition—and not merely the dozen or more which simply pierce the cortex on their way to join the larger outside veins—the general coloring of the bone will be of a bluish or dark purplish hue. Bone in this condition can no longer live; it is on the point of becoming a sequestrum. A fistulous opening is also occasionally encountered when the surface of the mastoid bone is exposed to view.

Operative Work upon the Bone Structures.—It is perhaps not a matter of any very great importance at what particular part of the exposed area of bone the operator shall begin his work of removing the cortex. On the whole, I think it is a good plan to aim first at reaching the antrum, for when once the location of this cavity has been established there will be comparatively little difficulty in working intelligently and safely in all other directions. I have known beginners to go so far astray in their search for the antrum that I have devised for their use an instrument which is called a *mastoid hook guide* (Fig. 116). The curved end of this

hook is to be introduced from above into the orifice of the external auditory canal, and held firmly by an assistant in this position, between the bone and the overlying soft parts, until the antrum has been reached. Its usefulness is then at an end, and it should be removed. When the instrument has been hooked into the canal, in the manner described, the knob will serve to indicate, with sufficient accuracy, the position of the posterior upper curve of the orifice of the auditory meatus; and the relations of this landmark to the mastoid antrum may be learned at a glance by consulting Fig. 110. Roughly speaking, I may say that the position of that cavity—or, rather, of a line leading from the operator's eye to that cavity—is a scant quarter of an inch behind and a little above that of the steel knob.



FIG. 116.—Mastoid Hook Guide. (Somewhat reduced in size.)

It seems desirable to add a few remarks in regard to the manner in which an operator *may satisfy himself that he has reached the mastoid antrum*, and not some adjacent pneumatic cell. There are various ways in which he can gain assurance in regard to this point. In the first place, his knowledge of the anatomy of this region should tell him whether the cavity which he has reached fulfils in a general way the anatomical requirements of the case or not. If its distance from the surface of the bone proves, upon actual measurement, to be less than half an inch, he should, for this reason alone (in adults and older children), suspect that he has reached simply an outlying pneumatic cell. By introducing into this cavity a slender Bowman's probe, the end of which has been bent so as to form nearly a right angle with the stem or shaft, he can readily determine which of the two cavities in question is before him. In the case of the antrum, the probe should slip easily forward into the posterior end of the tympanum; while in the case of an outlying pneumatic cell the end of the probe would encounter only rigid walls. If any further evidence be desired, either air or fluid may be forced—only a moderate degree of pressure is permissible—into the tympanic cavity (by way of the external auditory canal) and thence out through the cavity believed to be the antrum. Any pressure in the reverse direction—from the antrum toward the

middle ear—for diagnostic purposes, is not to be commended. Cases of complete absence of the antrum have been observed, but they are extremely rare. If the surgeon has reached a depth of three-quarters of an inch without encountering the antrum, he should abstain carefully from proceeding to any greater depth. The chances are that he has gone astray from the right path, either too low down, too high up, or too far back; and he should once more study the relations of the excavation which he has made in the mastoid to the posterior upper margin of the bony orifice of the external auditory canal. If he cannot, by aid of this landmark, correct whatever error he may have made, I do not know of any other way by which he may ultimately reach the antrum. Furthermore, if he has not already encroached upon one of the semicircular canals, or upon the facial nerve, or upon the sigmoid fossa, let him bear carefully in mind that the bottom of his excavation must be perilously near one or the other of the regions named. On the other hand, if he is perfectly satisfied that he has not gone astray, and that the bottom of his excavation is precisely where the antrum ought to be,—in other words, that he is dealing with a case of absence or obliteration of this cavity,—let him work his way cautiously forward until he reaches the general cavity of the tympanum.

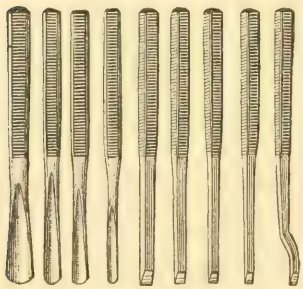

Fig. 117.—Schwartze's Chisels. (½.)

So far as the removal of the cortical portion of the bone is concerned, the chisel is now, I believe, almost universally admitted to be the most efficient instrument that can be used—at least until the underlying pneumatic cells shall have been exposed over an area large enough to permit the use of the rongeur forceps. Those known as *Schwartze's chisels* (Fig. 117) are narrow and strong, and leave nothing to be desired as instruments suited to this sort of bone work. Some operators prefer the gouge to the chisel. My objection to it is, that its cutting-edge breaks more readily, and it is not an easy matter to keep it thoroughly sharp. For driving power, some kind of *mallet* is required; and for this purpose I know of nothing better than one made of rolled and hardened rawhide (Fig. 118).

The chisel should be driven in directions as nearly as possible tangential to the surface of the skull, and the operator should

restrict himself to the cutting away of comparatively thin chips of bone. This latter precaution is specially necessary when the attempt is made to expose the dura mater or the wall of the sigmoid sinus. My own preference is to turn the bevelled edge of the chisel toward the outside; but I find that some of my confrères use the instrument in the reversed position. I will therefore not attempt to decide which is the better plan of procedure.

In order to gain the maximum amount of space for our operative work upon the bone, it will be found necessary to draw forward as far as possible the anterior flap of the wound. For this purpose some kind of a retractor will be required; and here I am disposed to advocate the employment of a pattern which has comparatively blunt-pointed teeth (Fig. 119), for one with sharp-pointed teeth is likely, it seems to me, to implant infection in the tissues which they pierce. In the evacuation of pus from the mastoid cells the retractor is almost sure to become infected; and if, while it is in this condition, it should be found necessary to readjust its position, the plunging of its sharp points into the tissues of the flap can scarcely fail to carry infection into their substance.

Fig. 118.—Rawhide Mallet. (Considerably reduced in size.)

Fig. 119.—Retractor.

The chiselling is to be continued until enough of the comparatively hard cortex has been removed to enable the operator to use effectively the *Volkmann sharp-edged spoons* (Fig. 120) in excavating the softer bone substance which constitutes the framework of the pneumatic spaces. As soon as this excavation work has pro-

gressed so far that the margins of the opening in the cortex are undermined, then the *rongeur forceps* (Figs. 121 and 122) may be used to great advantage in enlarging the external opening still further. At this stage of the operation it is certainly a more effective instrument than the chisel. The two models shown in the cuts are the ones which I find the most useful.

FIG. 120.—Volkmann's Spoons. (Somewhat reduced in size.)

As the work of excavation with the spoons progresses, it is a good plan to resort frequently to the use of the probe, for in this way one may obtain early information of the proximity of a cavity (for example, the antrum) or of an exposed membranous structure, like the dura mater or the wall of the sigmoid sinus. Bowman's probes will be found specially well adapted to this sort of exploratory work.

In the ordinary mastoid operation there are certain principles which should guide the operator in the performance of his task. In the first place, it is *desirable to establish a broad opening from outside into the mastoid antrum*, in order chiefly to put an end to any abnormal intratympanic pressure which may exist, and also to enable us to remove any granulation-tissue or softened bone which may be present. At this point I desire to caution those who are perhaps operating for the first time, against *the too free use of a Volkmann's spoon in the mastoid antrum*. In the first place, it is rarely necessary, in these acute mastoid cases, to do any scraping of the walls of the antrum for the purpose of removing carious or softened bone. In the very act of effecting an entrance into that cavity the operator is almost sure to remove the larger part of any carious bone that may be present. Then by excavating afterward the bone around this entrance, without disturbing the forward part of the antrum, he may feel assured that he has completed his task with sufficient thoroughness. In clearing the cavity of the granulation-tissue which is almost invariably present, it is not desirable to use the spoon with any force. Where I have failed to remove

this granulation-tissue from the antrum by comparatively gentle manipulations I have invariably allowed it to remain; and in not a single instance, so far as I can recollect, has its presence there interfered in any perceptible manner with the subsequent recovery. It is a matter of much greater importance that the artificially established outlet from the antrum should be of ample dimensions; and it is also a most desirable thing that in our manipulations with

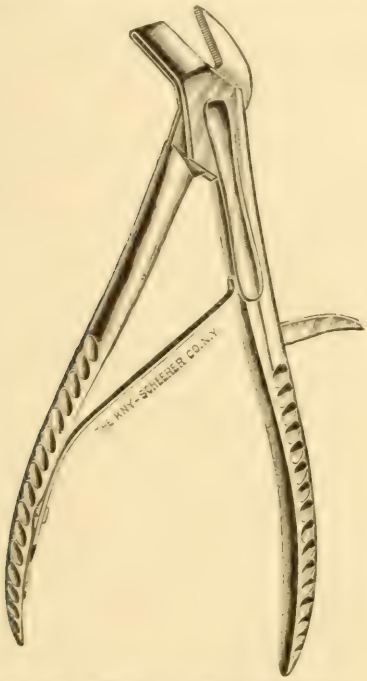

Fig. 121.—Hoffmann's Rongeur Forceps. (Reduced one-half.)

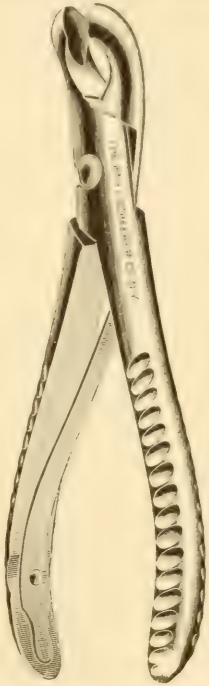

Fig. 122.—Esmarch's Rongeur Forceps. (Reduced one-half.)

the spoon, most of which are carried out under a pool of blood, we should not damage the facial nerve or the chain of ossicles.

Outside the mastoid antrum it is necessary to push our work of excavation in the following directions: downward to the tip of the mastoid process, where there is often an isolated large pneumatic cell or two filled with pus or granulation-tissue; backward toward the temporo-occipital suture, where again there are often isolated foci of pus; and finally upward and backward from the antrum, as far as to the hard inner plate of bone which separates this region from the dura mater and the sigmoid sinus.

Up to this stage of the operation the course to be pursued by the operator in regard to the removal of bone substance is plain enough. But if, on reaching this inner plate—either that situated above the mass of bone which lies behind the antrum, or that which constitutes the anterior and outer wall of the sulcus sigmoideus—he finds that it is still hard and no more hyperæmic than appears to him to be perfectly consistent with its eventual return to a normal state, the question at once confronts him: Does this comparatively normal condition of the inner plate (as seen from the outside) warrant the conclusion that pus has not already formed, or is not about to form, between it and the fibrous membrane which rests against its inner surface? In recent years I have followed the rule not to disturb this wall of bone whenever I found it in this comparatively healthy condition, believing that when it presented this appearance it could safely be accepted as an index that the soft parts lying beyond must be in an essentially normal state. But experience has taught me that this rule is not a safe one to follow. In the majority of instances it has indeed proved to be correct; but in a few cases I have been obliged to perform a secondary operation, for the release of pus lying outside the dura or the sigmoid sinus. These were cases, furthermore, in which I found the inner table neither softened, nor blackened, nor even excessively hyperæmic —in all of which conditions an experienced surgeon would not hesitate for a moment to remove those portions of the bone which were so affected. In the light of this experience, therefore, I have been forced to draw the conclusion that there is only one thoroughly safe course to pursue in these cases of acute suppurative inflammation of the mastoid pneumatic cells, viz., *to expose to view a small area not only of the sigmoid sinus, but also of that part of the dura mater which lies in the vicinity of the posterior end of the antrum.*[1] If pus has already formed in either of these localities—the regions where it is most likely to form—the removal of the intervening wall of bone will set it free. On the other hand, if the disease has not advanced as far as this, the operator will have the satisfaction of knowing, by actual demonstration, that he has fully complied with all the surgical requirements of the situation.

[1] Some weeks after I had written the above I discovered that the German otologist, Jansen, had recommended precisely this same course. My recollection is, that I found the statement in question either in Jacobson's treatise or in a recent number of the Archiv für Ohrenheilkunde; but, having failed to make a suitable memorandum at the time, I am now unable to say positively where I read the statement.

When the work of excavation is completed, the walls of the cavity thus created—except at the points mentioned in the preceding paragraph and at the opening made into the antrum—should everywhere offer hard resistance; in other words, the bone substance which remains should be healthy (except for the fact that it is perhaps a little hyperæmic).

As a final step in our work upon the bone, the rongeur should be used in smoothing the margin of the opening in the cortex; and if at any point this margin overhangs the cavity conspicuously, thus rendering the subsequent dressings of the wound more difficult, it is a good plan to cut away, with this same instrument, the overhanging portion.

The next step should be the removal of the artery clamp forceps and the placing of a ligature around any vessel which shows a persistent tendency to bleed. After this, the cavity of the wound, and especially any pocket-like recess under the skin, should be thoroughly irrigated with a moderately strong (one to two, three, or four thousand) bichloride solution—or, as some prefer, with a three-per-cent hydrogen-dioxide solution (United States Pharmacopœia). If any of the bichloride solution should pass through the Eustachian tube during the irrigation, its contact with the pharyngeal or nasal mucous membrane will give the patient a great deal of distress for hours afterward. For this and other reasons I think it is advisable—in these acute cases—to abstain from any attempt to wash out the tympanic cavity with a bichloride solution. The injection of steril zed water through a glass nozzle materially narrower than the diameter of the entrance to the antrum may safely be indulged in, if, for any reason—as, for example, the fear that chips of bone may have lodged in the cavity—it be thought best to carry out such intratympanic washing.

When the wound has once been thoroughly cleansed and disinfected, *the question of bringing together by sutures the opposite edges in the upper angle of the opening* must next be decided. If a broad opening has been established in the cortical portion of the bone, thus permitting very free access to every part of the excavation, and if at the same time the skin has been divided, toward the occiput, by a second incision, at right angles to the first, no hesitation need be felt about closing the upper horizontal portion of the wound by sutures. Indeed, in the case of women, it is very desirable that this part of the wound should be sutured, as otherwise, when the final healing takes place, it will be found that the auricle

on the affected side droops a little below the level of its fellow on the opposite side.

After trying various other plans of *dressing the wound*, I have come back to the iodoform dusting and subsequent packing (not too tightly) with iodoform gauze (ten-per-cent strength) as on the whole the most satisfactory method.[1] A large mass of sterilized absorbent cotton placed over the gauze and firmly held in place by a roller bandage completes the dressing.

Accidental Occurrences.—In the early part of the operation, while the effort is being made to separate the periosteum from the outer aspect of the mastoid process, far back, there sometimes occurs a sudden *copious hemorrhage of dark, venous blood*. This occurrence signifies that the patient possesses a large mastoid emissary vein—a comparatively infrequent anatomical peculiarity—and that the periosteum elevator has divided this vessel at the point where it enters the mastoid foramen. Some idea of the quantity of blood which can escape from this torn vessel, in the course of a few instants of time, may be gained from a mere statement of the fact that in one temporal bone which I examined, I found the mastoid opening, which was somewhat oval in shape, to have a long diameter of four millimetres and a transverse one of three millimetres. The effect of dividing such a vein at a moment when, under the influence of the anæsthetic (sulphuric ether), the intravenous pressure is at its maximum, will be almost the same as if we had established an opening of equal size in the wall of an artery. The hemorrhage may be arrested by crowding a small piece of iodoform gauze into the mastoid foramen.

There is scarcely any *danger of cutting into the sigmoid sinus* with either the chisel or a Volkmann spoon, provided the cutting edge of the instrument advance in a direction which forms a decidedly acute angle with the wall of the vessel. The safety of the latter lies in its high degree of elasticity; the sharp edge of the chisel or spoon merely pushing it aside as it advances. On the other hand, when through the effects of disease this elastic wall of the vein has become more rigid and at the same time softer (in process of breaking down), either of the above-named instruments may easily pierce its substance.

[1] It is still too early for me to express any opinion with regard to the efficiency of xeroform as a substitute for iodoform. It is claimed that it is practically non-poisonous. I am trying it at the present time in one of my cases, and it certainly appears to control the formation of pus.

Some of the sudden and copious hemorrhages of dark-colored blood, which seemingly come from an injury of the wall of the sigmoid sinus, are due simply to the cutting in two of some communicating mastoid veinlet close to the point where it pours its blood into the larger vessel. Packing with iodoform gauze quickly controls a hemorrhage of this kind or one which comes directly from the sinus itself.

Excessive oozing of venous blood from the divided vessels of the interior of the mastoid process is a comparatively frequent phenomenon. In the majority of patients this decided loss of blood produces no serious effects either at the time of the operation or subsequently; but in a few instances I have known it to induce such feebleness of the heart's action as to necessitate firm packing of the wound and a temporary suspension of all operative interference.

I have already spoken of the danger of injuring the facial nerve, and it is therefore not necessary to say anything more on the subject in this place. I will simply add that in a large percentage of the cases in which this accident has happened, the injured nerve has gradually regained the whole, or at least the larger part, of its power.

AFTER-TREATMENT.

It seems almost needless to say that a patient who has been subjected to an operation of this serious nature must be kept in bed for several days, preferably under the care of a trained nurse. Particularly important is it to keep a close watch on the behavior of the body-temperature during the first six or eight days after the operation.

At the end of the first twenty-four hours it is generally necessary to renew the outside dressings, on account of their being saturated with bloody serum. The iodoform-gauze packing, however, may safely be left undisturbed. If everything seems to be progressing favorably, it is not necessary to make a complete change of the dressings oftener than on every third or fourth day. Some surgeons make the interval considerably longer. On the other hand, if the body-temperature, after being normal, should rise, the dressings should at once be removed and the wound and its surroundings should be carefully scrutinized. The commonest local cause of such a rise in temperature is the development, at some point in the vicinity of the wound, of a subperiosteal or a subcutaneous abscess. But if nothing of this nature can be discovered,

and if the aspect of the wound itself seems to be healthy, the possibility of a pneumonia, a pleurisy, an endocarditis, or some other remotely situated centre of inflammation (perhaps metastatic), must be borne in mind.

When such a *secondary abscess* develops, the seat of the inflammation may be located at almost any point on the corresponding side of the head. Speaking simply from memory, I should say that the commonest location of such a purulent focus is at a point directly above the auricle—that is, directly above the upper angle of the wound; but in this I may easily be mistaken. In the most recent experience of this kind which I have had, the area of swelling and tenderness was located on the temple, directly back of the outer angle of the eye. Pressure at this point, on the eighth or ninth day after the operation, caused pus to escape from the anterior portion of the wound. The temperature, which had previously risen to a point somewhat above 104° F., immediately afterward began to fall; and at the end of twenty-four hours it had reached a nearly normal level. In another case which now occurs to my mind, I found the scalp tender and swollen at a point high up on the side of the head. I forced a fairly large probe from the upper angle of the wound, beneath the skin, up to the location of the swelling, and was in this way enabled to evacuate the abscess by simple pressure. In this case, also, the temperature, which had risen to 103° or 104° F., fell rapidly to the normal standard.

In certain exceptional cases, the pain in the head or the elevation of the body-temperature—one or both of these symptoms—persists after the operation has been performed. When this happens, we may rightly suspect that our operative interference has not set free all the imprisoned pus. The patient should then be anæsthetized a second time, and a further search should be made for this imprisoned pus. The sigmoid fossa and the extradural space higher up, in the vicinity of the antrum or near the temporoparietal suture, are the localities where we shall be most likely to discover such a collection of pus. The preceding remarks, be it understood, refer only to those cases in which the original operative interference stopped short of the removal of any part of the inner table or plate of bone; for it is still too early to speak from experience in regard to the complications which may occur in a case that has been operated upon in the manner which I have recently adopted and which I am disposed to advocate. My hope and belief is that, under this new rule, no such later intracranial

processes as are now comparatively frequent will arise. Speaking merely on theoretical grounds, I should strongly suspect the development of a cerebral or a cerebellar abscess in any patient who, after being operated upon in the manner described above, continued to complain of marked pain in the back or the side of the head, and whose body-temperature, besides, showed an upward tendency.

The Stage of Convalescence. As a rule, the patient should remain in bed during the first five to eight days. Then, if no untoward symptoms have shown themselves, he may be permitted to return gradually to his ordinary mode of life, except in the matter of physical exercise. In this particular he should be somewhat cautious until, through the complete healing of the wound, an adequate support shall have been provided for the exposed wall of the sigmoid sinus. This final healing rarely occurs before the fourth week, and sometimes it may be delayed until the sixth or seventh week after the operation. Under the old method of operating I have repeatedly known the wound to be completely healed by the twelfth to the fourteenth day.

CHAPTER XX.

DISEASES OF THE MASTOID PROCESS AND NEIGHBORING STRUCTURES (Continued).

CHRONIC MASTOID DISEASE: PATHOLOGY; SYMPTOMATOLOGY; DIAGNOSIS; TREATMENT.

Chronic suppurative disease of the mastoid process is encountered under a variety of forms; or perhaps it would be more correct to say that the pathological phenomena encountered in cases of chronic mastoid disease vary considerably in accordance with the extent and particular location of the mastoid territory involved, and with the length of time which has elapsed since the original acute attack took place.

With very few exceptions—I refer to those of a tuberculous nature—chronic mastoid disease begins originally as an acute suppurative inflammation of the pneumatic cells—an inflammation which is followed by the destruction and melting down of enough bone-tissue adjacent to the antrum to furnish a moderately good drainage channel for the remaining carious area. As a result of this fairly adequate drainage—by way of the antrum, the tympanic cavity, and the external meatus—the patient may, for a period of many years, suffer no distress or inconvenience beyond that occasioned by the persistence of a discharge from the affected ear.

In the ideal community there should doubtless be no such thing as a chronic caries of the mastoid process (except that, perhaps, of a tuberculous nature), for the acute mastoid cases would all be operated upon at the proper time, and the possibility of the chronic form of the disease would thereby be obviated. Such ideal conditions already prevail at the present time, to a large extent, among the more prosperous strata of society, in proof of which I have only to mention the fact that in private practice one rarely sees now a case of this kind, whereas between the years 1870 and 1880 such cases were not so very rare. Among the poorer classes, however, chronic caries of the mastoid process is still encountered quite frequently; and many of these individuals would doubtless perish from abscess of the brain, from meningitis, or from metastatic

pyæmic inflammations, were it not for the admirable surgical treatment which they receive from those in regular attendance at the infirmaries and hospitals devoted to diseases of the eye and ear.

The chronic form of mastoid disease is characterized by certain features which distinguish it very markedly from the acute form. Thus, for example, it seems to be a fixed law that, *pari passu* with the chronic suppurative process near the antrum, a subacute condensing osteitis shall involve all those pneumatic spaces which escaped injury during the original acute attack. This osteitis is characterized by the formation of new bone-tissue, and it progresses steadily, through a period of months or years, until solid, ivory-like bone takes the place of what before was an assemblage of air-containing cavities. *Sclerosis or hyperostosis of the outer portions of the mastoid process is therefore a regular characteristic of chronic suppurative mastoid disease.*

This well-established fact in the pathology of chronic mastoid disease has a very important bearing upon its symptomatology. The presence of such an ivory-like wall of bone on the outer side of the focus of suppurative disease offers an impassable barrier to the escape of pus in that direction. In fact, the process of hyperostosis goes so far in these cases that even those channels which, under normal conditions, give passage to numerous small veins, become obliterated. It will therefore be easily understood why those symptoms which have such a great diagnostic value in the acute form of the disease—viz., redness, tenderness, and swelling of the skin in the mastoid region, and redness or prolapse of the skin which lines the superior and posterior wall of the meatus near the membrana tympani—should, as a rule, be entirely lacking in the chronic form. The rare exceptions to this rule may, in some cases, be explained by assuming that the process of hyperostosis had not as yet obliterated all the channels of communication between the neighborhood of the antrum and the surface of the mastoid process. Then again there are still other cases in which an accompanying inflammation of the soft parts of the external auditory canal extends outward and backward to the skin covering the mastoid process, thus giving rise to the symptoms of swelling and tenderness on pressure which a novice might easily attribute to a direct extension of the inflammation from the body of the underlying bone. An error like this, however, can have no possible evil consequences.

Then, in the second place, the *bacteria of decomposition* play an

important part in chronic mastoid disease, whereas in the acute form they play no part whatever. By reason of their presence certain highly irritating juices (toxins) are created in the focus of suppurative disease, and under the provocation of this irritating influence the mucous membrane lining the focal cavity assumes a proliferative activity. At one point, this activity takes the form of a connective-tissue hypertrophy (granulation growths), while at another it goes no further than to cause the shedding of layer after layer of the outermost strata of epithelial cells. Thus, in the course of time, there will be developed, side by side in the same focal cavity of a case of chronic mastoid disease, the following pathological processes: the new-formation of connective tissue, usually limited in extent; the casting off of epithelium in laminated sheets, often to a prodigious extent; the formation of pus, which immediately undergoes decomposition and soon becomes converted into cheesy material; and, finally, the ulcerative destruction of bone-tissue in whatever directions there may still be some which has not undergone the sclerosing change (these directions being almost invariably upward toward the dura mater at the base of the brain, or backward toward the lateral sinus). The final ending of chronic mastoid disease is likely, therefore, to be an abscess of the brain, or an infective sinus-thrombosis, or a combination of both these conditions.

SYMPTOMATOLOGY.

Chronic mastoid disease has no characteristic symptoms during the greater part of its course. It is only when the ulcerative process begins to encroach upon the facial nerve, the dura mater, or the sigmoid sinus, or upon some part of the labyrinth, that any symptoms other than that of a foul-smelling discharge from the affected ear make their appearance. The earliest of these is *pain* —referred generally to the side or the back of the head. *Facial paresis* occasionally develops, thus indicating an extension of the area of ulcerative disease in the direction of the facial canal. In some cases *vertigo* is also complained of by the patient; and in two or three of these cases I have had the opportunity of demonstrating that that portion of the tegmen tympani which lies above the mastoid antrum had been entirely destroyed. Doubtless some little increase of pressure upward against the exposed surface of the dura had, in these particular instances, put the fibres of the ampullar branch of the auditory nerve upon the stretch, and thus had excited the symptom of vertigo. The same increase of pressure in the

focal cavity is likely to cause a certain degree of *septicæmia*, which will manifest itself by a rise in the body-temperature. Ultimately, the disease may extend beyond the limits of the temporal bone, and in this manner the sigmoid sinus, the dura mater, and even the brain itself may become involved. Under these circumstances *chills at irregular intervals, various abnormal conditions of the eye, localized paresis*, or even a *partial hemiplegia, convulsions, delirium, vomiting*, and finally *coma*, may be looked for as evidences of such an extension of the disease beyond the limits of the temporal bone.

Finally, among the rare issues of the disease may be mentioned hemorrhage from one of the large blood channels which pass in such close proximity to the middle ear, viz., from the sigmoid sinus or from the carotid artery.[1]

DIAGNOSIS.

In the great majority of instances the chronic nature of any given case of suppurative disease of the ear, and more particularly of the mastoid process, is revealed to us by the past history of the affection. Now and then, however, the circumstances of the case may be such that we shall have to depend for the determination of this fact entirely upon the physical examination. It is not necessary to rehearse here the various lesions which indicate unmistakably the chronic character of the disease; they have already been discussed in sufficient detail in another part of this chapter. The problem in diagnosis usually presents itself in the following form: Are we dealing with a *bona fide* acute attack—one that has developed in an ear not previously subject to chronic suppurative disease? or, Does the present attack represent an acute exacerbation of a long-standing disease? To the inexperienced beginner this problem may often prove to be a difficult one to solve. The most important point to remember in this connection is the fact—to which I have already called attention—that in an acute lighting up of an old suppurative mastoid inflammation there will probably be no external manifestations of such an internal acute exacerbation of the inflammation—no redness, no swelling, no tenderness of the skin covering the mastoid process. Indeed, in not a few instances our decision to perform a Schwartze operation is based almost

[1] See a monograph on the latter subject by Marcé: De l'ulcération de la carotide interne dans la carie du rocher. Paris, 1874. Hermann has also reported a case of hemorrhage from the carotid artery in vol. iv., p. 294, of the Archiv für Ohrenheilkunde.

exclusively upon the solitary symptom of pain in the region of the ear—a pain which has developed in or near an ear which has long been the seat of suppurative disease.

The symptoms which develop when suppurative inflammation extends to the sigmoid sinus will be considered in the next chapter; and those which are encountered when an abscess develops in the brain, will be discussed in a still later chapter.

ILLUSTRATIVE CASES.

CASE LXXXVI.—*Chronic suppurative and desquamative disease (cholesteatoma) of the mastoid antrum and neighboring pneumatic spaces; tegmen tympani et antri destroyed, and superjacent dura mater exposed; arrest of the suppurative and desquamative processes (for long periods) by injections of hydrogen dioxide and the introduction of powdered iodoform.*

The patient, a man about forty-five years of age, consulted me on December 21st, 1890, for the relief of a foul-smelling discharge, with which was associated a tendency to attacks of vertigo. On examination I found that this discharge came from an opening, of a circular shape, in the roof of the canal, and that the tympanic membrane itself was intact. The inner margin of this opening was formed by the upper limit of the membrane. The space beyond the opening appeared to be somewhat tightly filled with foul-smelling cheesy material and desquamated epithelium. Gradually, after a number of sittings, I succeeded—partly by the use of instruments, and partly by irrigation with hydrogen dioxide—in clearing this cavity of its contents, which consisted mainly of tough, white, laminated sheets of epithelium, intermingled with caseous material. These manipulations and injections caused considerable faintness and dizziness, but no distinct revolving of objects in the room. The size of the irregularly shaped cavity which had thus been cleared of its foul-smelling contents could only be approximately estimated. It included all of the vault of the tympanum, a good deal of the space previously occupied by the bone substance which lies between the roof of the external meatus and the under surface of the dura mater, in the immediate vicinity of the vault of the tympanum, all of the antrum, and some of the outlying pneumatic cells. In exploring this cavity with a bent probe, after I had finally succeeded in emptying it thoroughly, I found that the end of the instrument could be passed directly upward a distance of several millimetres without encountering any firm resistance. At a height of perhaps eight millimetres I felt distinctly that I was pressing against something elastic. This pressure, however, caused the patient so much distress that he begged me to desist. He said that when I made pressure with my probe, everything in the room began to revolve from left to right, and at the same time he felt great faintness. On questioning him in regard to the plane in which the rotary movement took place, I ascertained that it appeared to him to be nearly horizontal. His head, however, at the time of my manipulations, was in a semi-reclining position. It is probable, therefore, that he

saw the objects before him in the room revolve in a plane that was at right angles to his line of vision.

After the thorough cleansing of this large cholesteatomatous cavity had once been effected, it was loosely packed—so far as I was able to accomplish this difficult task—with powdered iodoform. It is more than likely that this drug was not transported to some of the remoter parts of the cavity. Nevertheless, the presence of what I did succeed in introducing sufficed to put an end to all discharge for a period of several months. And from that time to the present I have been obliged to resort to the injections of hydrogen dioxide not more than four or five times; the relapses seemingly being due to the effects of some passing head-cold, and yielding to a single, or at most to two injections,[1] on alternate days.

CASE LXXXVII.—*Enormous cholesteatoma filling the entire mastoid process; the dura mater at one point, the wall of the sigmoid sinus at another, and the facial nerve at a third, entered into the formation of the lining wall of the cavity; the greater part of the posterior osseous wall of the meatus was found to be destroyed; operation (by Dr. Robert Lewis, Jr.), and subsequent perfect recovery.*

Female, 24 years of age, apparently in good health, consulted me on March 1st, 1898. She stated that she had had a discharge from the right ear since childhood, but that she had experienced no pain in or around the ear until during the preceding month of December. Then, in consequence of a severe "cold," she had suffered a good deal from pain in the right ear and from "neuralgic pains" in the right side of the head; and she had also had chills and sweats. At the same time an abscess had appeared below the ear, and in the course of a few days it had broken. Since that time she had lost considerable strength, and had felt generally ill.

On examination I found, about half an inch below the lobe of the right ear, the pouting orifice of a fistula which led upward toward the tip of the mastoid process. The skin covering this process presented a perfectly normal appearance, and pressure made at different points revealed no tenderness except in the vicinity of the external meatus. On the lower and posterior cutaneous wall of the latter, close to the commencement of the osseous portion of the canal, there was a small mass of granulation-tissue surrounding the orifice of a fistula which led almost directly backward against the denuded anterior face of the mastoid bone. Beyond the mass of granulations the meatus grew rapidly narrower until, in the vicinity of the middle ear, the posterior cutaneous wall almost came in contact with the anterior. Pressure with the probe revealed the fact that this posterior wall of skin did not rest against a bony background. A slender cotton-carrier, armed with absorbent cotton, was pushed beyond the constricted portion of the canal, and when it was withdrawn it was found to be stained with blood and smeared with a foul-smelling, cheesy material. The body-temperature was found to be a few tenths of a degree above 99° F.; pulse between 90 and 100, and not strong.

[1] The mode of making these injections is described on p. 323. By "a single injection" is meant a single sitting, in the course of which three, four, or five injections may be made.

As the evidence pointed clearly to cholesteatomatous disease of the antrum and body of the mastoid process, I advised early operative interference.

My associate, Dr. Robert Lewis, Jr., took charge of the case and operated on March 4th.

Notwithstanding an entirely normal appearance of the outside of the mastoid process, its cortex was found to be a mere shell, not more than two millimetres in thickness. Beneath this shell of bone there lay a cholesteatomatous mass fully as large as a large Spanish olive. The main body of the mass had nicely rounded limits, but in an upward direction its shape must have been somewhat that of a wedge, for it extended as high up as to the temporo-parietal suture. The consistency of this unctuous, foul-smelling mass, which contained exceedingly little desquamated epithelium, was that of well-compacted butter. After the cavity had been thoroughly cleansed, it was found that it was lined throughout with a smooth epidermal membrane, that the inner two-thirds of the bony posterior wall of the auditory meatus had been completely destroyed, and that consequently the skin which ordinarily rests against this part of the mastoid bone was now suspended like a screen or curtain in the canal. It was also found that the inner table of the temporal bone had been destroyed both posteriorly and superiorly; thus permitting the lateral sinus and the dura mater to constitute portions of the wall of the cholesteatomatous cavity. Finally, it was discovered (not at this time, but a few days later) that the wall of bone surrounding the facial nerve throughout this antral part of its course had been destroyed, and that the fibrillæ of the nerve were covered simply by the membranous lining of the cholesteatomatous cavity. Two openings were found in the outer wall of the mastoid process: one situated anteriorly, in that part of the bone which had escaped destruction, and the other in the digastric groove, close to the tip. The former of these proved to be a continuation of the opening discovered in the external auditory canal, while the latter communicated with the fistulous track on the side of the neck.

The wound was dressed in the usual manner, and no attempt was made at that time to do anything with the unsupported posterior cutaneous wall of the auditory canal. Twelve days later, after the patient had regained in some measure her former strength, she was put under the influence of an anæsthetic, and Dr. Lewis closed the outside wound with sutures; leaving, however, a small opening for drainage at its lower angle. In suturing the opposite edges of the wound he made some of the sutures to pass through a broad flap which he had previously cut from the unattached posterior cutaneous wall of the auditory canal, and turned back in such a manner as to bring its granulating surface against the raw internal surfaces of the flaps of the wound (after the method recommended by Rudolf Panse).

About ten days after this last operation was performed, I had an opportunity of examining the patient. I found that the external wound had healed throughout its entire extent, and as yet no appreciable sinking in of the skin had taken place over the unusually large excavation in the bone. Upon removal of the tampon of iodoform gauze from the external auditory canal and former cholesteatomatous cavity, it was found to be only slightly moistened with pus, which evidently came from a granulating-point near the former entrance to the antrum. Everywhere else, the lining walls of the

cavity, so far as I was able to see them through the speculum, were smooth and free from granulations. (A more detailed account of this interesting case will be published at an early day by Dr. Lewis.)

TREATMENT.

The treatment of chronic mastoid disease is fundamentally the same as that for the acute form; its object being, in both conditions, to remove from the mastoid portion of the temporal bone a focus of suppurative disease which is threatening to extend to the sigmoid sinus, or to the brain, or to both. There is one respect, however, in which the operative problem presented by the chronic form of the disease occasionally differs materially from that presented by the acute form. I refer to the fact that in the former it sometimes seems very desirable, if not indeed a necessity, to provide a broad channel through which we may easily reach every part of the antrum and vault of the tympanum from the external auditory canal. The necessity for such a provision may sometimes arise in an acute case of rather long standing; but under ordinary circumstances we are at liberty, in the acute cases, to ignore, in a large measure, the antrum and epitympanic space. The ordinary Schwartze operation meets all the requirements of such cases. In many of the chronic cases, on the other hand, the area of the suppurative disease extends from the epitympanic space back into the antrum, or into a still larger cavity composed partly of the antrum and partly of the space once occupied by adjoining pneumatic spaces which have become obliterated by ulcerative disease. When we find that we are not able to effect a thorough cleansing of such a cavity—the one thing absolutely essential to a cure of the disease—we are then forced to perform one of three operations: either the usual Schwartze operation, or the operation known as the Stacke operation, or a combination of the two (termed, for convenience, the Schwartze-Stacke operation). Prior to 1890, our only resource, in cases of this kind, was the Schwartze operation. When the work of removing the products of disease and the affected bone structure was done in a thorough fashion, this operation generally gave very satisfactory results. But every now and then a case was encountered in which the relief obtained by the Schwartze operation proved to be only partial in character. It was this experience, doubtless, which led to the search for a method of operating which would leave the antrum and epitympanic vault so completely exposed to view (through a speculum introduced into the outer canal

of the ear) that at any time, and as often as might be thought desirable, these regions could be thoroughly cleansed and medicated. It was in this way that the Stacke operation came into existence.

STACKE'S RADICAL OPERATION.

In 1890 Ludwig Stacke, an aural surgeon practising in Erfurt, Germany, published a new method of effecting a radical cure of long-standing purulent discharge from the ear. This method is now generally known as Stacke's radical operation. The fundamental idea of this method of operating is to cut away the bony structures which constitute the outer wall of the antrum and of the tympanic vault, and thus to render it possible for the surgeon to see every part of the cavities through a fairly large speculum introduced into the external auditory canal in the usual manner.

Steps of the Operation.[1]—The skin above and behind the auricle is to be divided by the same incision as that which is employed in the Schwartze operation. In its horizontal portion it should extend well forward, to or to a point a little beyond a vertical line running through the tragus. In this part of the incision only the skin should be divided, and not the fascia of the temporalis muscle. After the linea temporalis has been reached, and from this point downward to the tip of the mastoid process, firm pressure should be made with the knife, in order that it may divide the periosteum as well as the skin. At its lower end the incision should extend to a point about half an inch below the tip of the process. When this has been accomplished, the auricle and attached border of skin should be carefully dissected, by the knife applied flatwise, from the underlying fascia of the temporalis. Then, while these same parts are being pulled strongly forward, the point of the knife should be applied to the surface of the bone at the point where the first incision crosses the linea temporalis, and this new incision should be carried along the ridge of the linea temporalis as far forward as the soft parts, put upon the stretch, will permit. Only the fascia and the periosteum are to be divided by this second incision; the skin itself is not to be cut. These two incisions, which join at the point where the first one crosses the linea temporalis, include, from behind and above, the osseous meatus. By means of a periosteum elevator the periosteum included between the two incisions should gradually be separated from the bone until the

[1] This account is taken from Stacke's "Die operative Freilegung der Mittelohrräume," etc. Tübingen, 1897.

margin of the osseous meatus (with its spina supra meatum) comes into view. Then, if the available space seems to be insufficient for further operative work in the auditory canal, the tendon of the sterno-mastoid muscle may be separated from the tip by a series of short transverse strokes of the knife. This separation will permit the auricle and attached parts to be drawn a little farther forward.

For the separation of the posterior cutaneous wall of the meatus from the underlying bone—the next step of the operation—Dr. Stacke employs a narrow, specially constructed pattern of periosteum elevator. When this separation has been effected, he introduces, into the space thus created, a narrow scalpel, bent flatwise, and divides, from behind, the thin skin of the posterior half of the canal (and also to a certain extent that of the upper part of the canal) as close as possible to its line of attachment to the annulus tympanicus. Then, by means of a slightly bent elevator, constructed specially for the purpose, he lifts the entire membranous canal out from its bony pit; apparently no importance whatever being attached to the fact that some tearing of the inner portion of this membranous structure usually takes place during this procedure. After the membranous canal has thus been separated from its surrounding walls, a blunt-ended tenaculum or retractor is employed for the purpose of drawing the entire mass forward. Dr. Stacke designates all the different steps which I have thus far described as the preliminary operation.

The bone structures to be removed are now easily to be seen, under good illumination, and there is a sufficiency of space for all the manipulations required. If the malleus, the incus, and the upper part of the tympanic membrane are still *in situ*, these should first be removed. Then a suitable bone gouge (with the convex side turned backward) should be placed first against the front part of the inverted, wedge-shaped ridge of bone which separates the epitympanic space from the external auditory canal, and, by aid of a suitable mallet, chip after chip of this mass of bone should be cut away until the ceiling of the epitympanic space is directly continuous with the upper wall of the canal. The blows given with the mallet should be of only moderate force; the gouge should be held lightly between the thumb and two first fingers of the left hand; and the work of removal should progress from below upward, and from in front backward. When the part of the ridge which is directly opposite the stapes and the superposed facial canal is reached, a hook-like instrument—called by Stacke a pro-

tector—is to be introduced into the entrance to the mastoid antrum. As its name implies, this instrument is intended to protect the above-named important structures from any sudden inward movement of the gouge. This protector, as Dr. Stacke states, will also be found very useful in lifting out the chips of bone. After the danger-point (opposite the stapes) has been passed, the protector may be withdrawn, and the chiselling work may proceed a little more boldly. The mass of bone, however, which lies below the lower margin of the entrance to the antrum is a region which must still be carefully respected, for it is here that the facial nerve is most liable to receive an injury. All the bone which lies above and to the outside of this mound—for such will become its shape as the chiselling progresses—may be cut away freely and without fear of inflicting any injury. When the bone work is completed, the new posterior wall of the canal should pass in a direct line, inward and somewhat backward, to the posterior limit of the antrum or of the larger cavity produced by the action of disease. The upper wall of the meatus should also run in a direct line to the highest point of every part of this cavity and of the epitympanic space. Such carious conditions as may be encountered must be dealt with as they would be in the regular Schwartze operation. The bone surface at all points should be left in a thoroughly smooth condition. The exposure of the dura mater at one or two points is not an uncommon occurrence, and need cause no anxiety.

The final step in the Stacke operation is that which relates to the readjustment of the soft parts and the closing of the external wound. In the first place, the upper part of the membranous canal is to be slit open, from its free inner extremity outward to the concha, by an incision which runs parallel with the long axis of the external auditory canal. Then from the point (at the concha) where this incision terminates, a second incision should be carried downward and backward (at right angles to the first incision) and along the very edge of the concha to the floor of the entrance to the auditory meatus. As a result of these two incisions a quadrangular flap will be obtained, and this—by dint of a little twisting—may be utilized in covering over the raw surface of bone which is to constitute the new posterior wall of the canal. It may also be found possible to extend the flap far enough inward to cover at least a little of the floor of the antrum. If it be found that the outer part of the flap is so thick that it is likely, when twisted, to narrow the calibre of the passage, it is best to trim it down some-

what with the scissors. For the purpose of keeping the flap in contact with the underlying raw surfaces, Dr. Stacke advocates the employment of very small pledgets of sterilized gauze, which are to be packed in, one after the other, until the excavation and the inner part of the canal are filled. He is opposed to the employment of irrigation in any form in the course of the operation, but permits the dusting of the parts with sterilized iodoform powder.

The upper portion of the external wound is to be closed by sutures, while the lower part is to be kept open until it becomes clear that there will be no necessity of interfering in any way with the more deeply situated parts through this posterior opening. Usually it may be allowed to heal at any time after the fourth or fifth week. The outside dressings are simply those which are used in the regular Schwartze operation.

The *after-treatment*, according to Dr. Stacke, is indisputably the most difficult portion of his radical method of dealing with this class of cases. The main thing to be aimed at is the securing of a smooth epidermal covering for the large excavation which has been made in the bone. The different steps in the process by which nature effects this result are, first, the development of a cushion of healthy granulation-tissue upon the cut surface of the bone, and then the growth, over the surface of this, of epidermis. The chief difficulty which the surgeon will encounter, as this process advances, is that of controlling the growth of the granulation-tissue, in order that it may interfere as little as possible with the advance of the epidermis from the sides, and in order that the formation of adhesions, of cord-like bridges, and of diverticula may be prevented. And the means which he has at his command for overcoming this difficulty are pressure (by means of very small tampons) and cauterization (by means of silver nitrate and the galvano-cautery).

The patients are to remain in bed for the first seven or eight days after the operation. While it may be found necessary to change the outside dressings earlier, the deeper ones should be allowed to remain undisturbed until the eighth day. The parts are not to be irrigated, and every step required in the repacking of the wound is to be taken under the strictest aseptic precautions. The second dressing of the outside wound should take place earlier, say at the end of three days. The secretions by this time have become more abundant, and so the interval between any two dressings must be made shorter. As the reparative process advances there will come

a time when it will be found advantageous to omit the gauze tampons altogether. Useful as they are at first, the irritation which they cause finally compels the surgeon to dispense with them. Dr. Stacke confesses that it would be a very difficult matter for him to specify at what particular stage of the treatment the tampons should be abandoned. He says, however, that the experiment may safely be tried when it is evident that the epidermis has grown out over one margin of the narrowest part of the excavation. On the other hand, if the tampons are omitted too early, there is great danger that adhesions will take place. Particular care must be taken not to allow the bead of silver nitrate to touch parts over which the new epidermis has already grown. The larger masses of redundant granulation-tissue can as a rule be removed more effectively by Wilde's (*i.e.*, Blake's) snare than by any other means. The employment of chromic acid in substance is to be avoided.

The duration of the after-treatment varies from four to twelve weeks.

THE SCHWARTZE-STACKE OPERATION.

Schwartze,[1] while giving his approval in the main to Stacke's method, makes certain criticisms and suggestions. He believes, for example, that it is better not to draw out from the bony canal all of the membranous lining, but to leave the anterior half undisturbed *in situ*. In this way the subsequent occasional development of a necrosis in the bony canal will be avoided. Stacke's object in drawing out the soft parts from the canal is to gain the maximum amount of space for the chiselling work upon the deeper-lying bone. But Schwartze maintains that in ordinary cases—those in which no stenosis exists—an adequate amount of space may be obtained by simply pulling these soft parts forward by means of a slender retractor introduced into the canal between the bone and the posterior half of the membranous lining. He also objects to the "protector," which is likely, as he believes, to occasionally inflict an injury upon the very parts which it is supposed to protect. Then, in regard to Stacke's instructions not to employ antiseptic irrigation, he says that when he notices any odor in the secretion, he does not hesitate to wash out the excavation with a 1–1,000 bichloride solution. Schwartze also expresses the opinion that the plan of working with the chisel, gouge, or sharp-edged spoon from

[1] "Operationslehre," Handbuch der Ohrenheilkunde, Zweiter Band. Leipzig, 1893.

within outward (*i.e.*, from the antrum outward, after exposing this cavity freely, in the ordinary manner) is preferable to that of working from without inward (*i.e.*, from the external auditory canal into the antrum). My associate, Dr. Robert Lewis, has recently (early in 1896) tried this method in a case of long-standing foul discharge from the antrum and epitympanic space, and he expresses himself as very well satisfied with it. He experienced no special difficulty in cutting away all the portions of bone which are usually removed in the course of the typical Stacke operation, and he escaped entirely that fear of injuring the facial nerve or the stapes which constitutes—certainly in the case of those who operate for the first time—such an unpleasant accompaniment of the operation when performed in the regular manner (*i.e.*, as advised by Stacke). It is this modification of the operation which is known as the Schwartze-Stacke operation.

Opinions seem to be divided in regard to the advisability of destroying the membrane which lines the cholesteatomatous cavities encountered so often in the course of a Stacke operation. There is no doubt whatever that in many instances, if this membrane be thoroughly freed from contact with cholesteatomatous material, it will cease to give any further trouble; in other words, that it will act like a simple, horn-like skin surface. But, unfortunately, there are other cases in which the apparently smooth membrane is in reality pierced at numerous points by openings which lead into small pockets or channels that are also filled with cholesteatomatous material. It is evident, therefore, that no matter how perfectly we may cleanse and disinfect the larger cavity, the smaller pockets and channels will not be reached by any of these simpler measures. It is for this reason that some authorities—among whom Stacke is to be reckoned—advocate the thorough destruction of the lining membrane of the larger pathological cavity and also of some of the underlying bone-tissue. However, these efforts to thoroughly eradicate the disease have so often proved unsuccessful that not a few surgeons are disposed to rest satisfied with the accomplishment of the following two results, viz., the thorough removal of all cholesteatomatous material from the main cavity, and the acquisition of the power to inspect and thoroughly cleanse every part of this cavity, at any subsequent time, without resorting to operative interference. The attainment of these results means at least a partial cure of the offensive discharge from the ear, and the almost sure removal of a source of danger to life.

CHAPTER XXI.

PERIPHLEBITIS AND INFECTIVE THROMBOSIS OF THE SIGMOID SINUS.

SYMPTOMATOLOGY AND DIAGNOSIS.

There are no symptoms which indicate surely that an inflammation of the mastoid process has extended beyond the inner cortical layer of bone and has excited suppuration around the sigmoid sinus —or, in other words, has set up a periphlebitis in this region. It is only when the interior of this vein becomes involved that we may sometimes infer, from the symptoms then manifested by the patient, that an actual phlebitis has developed.

A high body-temperature with marked fluctuations; pain referred to the region behind the affected ear and to the corresponding side of the head generally; and chills or rigors at irregular intervals, often followed by profuse perspiration, are symptoms which, if they develop in the course of chronic suppurative disease of the middle ear, are universally accepted as indicating the existence of an infective thrombosis of the sigmoid sinus. At an early stage of the disease the symptoms enumerated above may be found to be the only indications of the inflammatory process going on in the sinus; but, after a certain length of time has elapsed, other manifestations will be likely to develop, viz., those due to obstruction of the flow of venous blood through the sinus, and those arising from inflammation of the veins which communicate with it.

Macewen mentions, as one of the manifestations due to obstruction of the flow of blood through the sigmoid sinus, an occasional over-distension of the mastoid vein, which enters the upper part of the sigmoid sinus. In most individuals, as I have had frequent opportunities of observing upon the living subject, this vein is of such insignificant size that, even if it were in an over-distended condition, it would scarcely be possible, through the thick skin of this part of the head, to discover its presence. On the other hand, in the few exceptional cases in which the mastoid vein is a vessel of considerable size, any interference with the flow of blood through

it might readily cause it to stand out with cord-like prominence. The five illustrative cases of sigmoid sinus thrombosis reported by Macewen are all instances of the development of this complication in the course of a chronic suppurative disease of the middle ear. The over-distention of the mastoid vein is not mentioned as having been observed in any of these cases, and I strongly suspect that this manifestation is uniformly absent in the sigmoid thrombosis of chronic suppurative disease of the ear. It is a well-known fact, as I have stated elsewhere, that osteosclerosis affects all mastoid processes which are the seat of a chronic suppurative antrum disease, and that as a result of this proliferation of bone-tissue the numerous channels for small veins are obliterated. I have never investigated the question of how the bone hypertrophy affects the channel for the mastoid vein, but it seems reasonable to suppose that this also undergoes obliteration. On the other hand, in the three cases reported by Whiting the thrombosis occurred as a late development in the course of an acute suppurative disease of the middle ear. No mention is made by him of any recognizable over-distention of the mastoid vein, but he calls attention to the fact that in two of the cases there was an œdematous condition of the skin between the affected mastoid and the occipital protuberance. This condition may be explained most naturally, as it seems to me, by assuming it to be due to the back pressure in the mastoid vein, the blood in this vessel being prevented from flowing into the sigmoid sinus.

For a more exhaustive description of the remaining symptoms of sigmoid sinus thrombosis, I must refer the student to the classical treatise of Macewen, as I can give here only a brief résumé of his account.

Phlebitis or thrombosis of venous channels more or less closely associated with the sigmoid sinus,—especially the internal jugular, the anterior and posterior condylar, and the deep veins of the neck into which the condylar veins empty themselves,—and occasionally of the mastoid vein, points to thrombosis of the sigmoid sinus.

Pressure over the internal jugular, especially its upper third, causes acute pain. Occasionally also deep pressure applied to the upper third of the posterior cervical triangle causes pain. This is apt to be found at a somewhat later date than the tenderness over the internal jugular. It is due to pressure upon the inflamed posterior and anterior condylar veins, also some of the basilar veins, and eventually the deep posterior cervical plexus and the occipital

veins. Exceptionally, the tenderness may be found in this region before it is found over the internal jugular.[1] In one of Whiting's cases (thrombosis developing in the course of acute mastoid disease) there was no tenderness on pressure over the internal jugular.

When the internal jugular is thrombosed the finger readily discovers the cord-like formation to the inner side of the sterno-mastoid muscle and on the outer side of the carotid artery. This cord-like formation may be felt as far down as the clavicle, but it is often confined to the upper third of the vessel in its course along the side of the neck. At a later stage of the disease, after disintegration of the thrombus has occurred, digital examination may fail to discover any cord-like formation.

The veins in the upper third of the posterior cervical triangle, when thrombosed, are more difficult to detect, as they are so small and so deeply situated.

At a still later stage, "as a consequence of infectious thrombosis in the cervical region, the tissues in the vicinity of the blood-vessels become œdematous and infiltrated with plastic exudation, so that vessels, muscles, enlarged glands, and soft tissues generally, become fused into one mass. This infiltration may terminate in resolution, provided the source of contamination be removed, but if not, it will undergo purulent disintegration" (Macewen).

Abscesses may also form in the deeper parts of the upper third of the posterior cervical triangle or under the sterno-mastoid muscle in the course of the internal jugular vein, and under the deep cervical fascia. "When these intravenous abscesses do form in the neck, the portions of the vein below are occluded with a firm thrombus, which, though exposed and liable to the same disintegration as that which overtook the upper part of the thrombus, is yet frequently sufficiently firm to form a barrier between the lungs and the abscess" (Macewen).

The entire length of the thrombus may disintegrate and be carried by the blood stream to the lungs. The infected masses are conveyed to these organs through the internal jugular, or they may

[1] Whiting says that this symptom, which he terms *Griesinger's Symptom*, is as often absent as present, but when it exist it is a "valuable aid in estimating the probable position and extent of the obstructing thrombus. The deeper down toward the bulb that the clot extends and the more marked the disintegration, the greater the constancy of Griesinger's symptom, which depends upon phlebitis of the deep veins of the neck, the anterior and posterior condylar participating with considerable frequency in the inflammatory extension from the sinus."

be carried by the veins which, passing into the posterior cervical triangle, convey blood through the vertebral and other channels to the subclavian. Rigors, increase of the already high temperature, and profuse perspiration characterize the occurrence of this event. The pulmonary infarctions which result from the entrance of such infective particles into the lungs may or may not give rise to recognizable physical signs.

Infective enteritis, with profuse diarrhœa, is an occasional accompaniment of thrombosis of the sigmoid sinus.

When the flow of blood through the cavernous sinus is interfered with, as sometimes happens in thrombosis of the sigmoid sinus, the ophthalmic vein becomes engorged; and, as a result, there will be moderate œdema or puffiness of the eyelids of the corresponding side (Whiting). The same authority also speaks of intra-ocular inflammatory changes (*e.g.*, neuro-retinitis) and of pareses of one or more nerves located in the region of the cavernous sinus.

In one of my cases of thrombosis of the sigmoid sinus (Case No. XCII.) a profuse nosebleed occurred during the sixth week of the disease—that is, two or three days before the operation, and therefore at a time when probably the sinus had been thrombosed for several days. It occurs to me that perhaps this phenomenon should also be reckoned among the possible symptoms of sigmoid sinus thrombosis; for the nasal veins pour their blood into the superior ophthalmic vein, and this in turn communicates with the cavernous sinus.

"The differential diagnosis between infective sigmoid sinus thrombosis, cerebral abscess, and meningitis, is fairly easy in uncomplicated cases, but one must remember that all three may be present in the same case" (Macewen).

Finally, it must be borne in mind that, in the course of a suppurative inflammation of the mastoid process, an infective thrombosis may develop in the internal jugular independently of any demonstrable phlebitis of the sigmoid sinus. We can only speculate as to how such an unlikely event may occur; but that it does sometimes occur is shown very clearly by an observation made, within the last few days, by Dr. Frederic Whiting at the New York Eye and Ear Infirmary. In the course of an operation which he performed upon the mastoid process of a young lad, he found a collection of pus lying between the sigmoid sinus and the inner cortical plate of bone; but the sinus itself, although covered with a layer of plastic lymph, was elastic and contained fluid blood. He

removed the bone surrounding the sinus as far down as the bulb, but still failed to find any evidences of thrombosis. Believing that he had discovered ample cause for the patient's high temperature (102 or 103 F., if I remember rightly) he abstained from making any further search. I should also have stated that there was no swelling or redness of the skin below the mastoid process, or any other evidence to show that the inflammation had extended downward along the side of the neck. In the course of three or four days it became evident, from the fact that the boy's temperature continued to rise—reaching at one time, 106° F.—that the operation had failed to reach some other focus of inflammation besides that located in the mastoid process. The patient was accordingly anæsthetized a second time, and a careful search was made for this other focus. In this way it was discovered that the internal jugular was thrombosed from a point a short distance below the bulb to one situated between the hyoid bone and the clavicle; and the thrombus was found to have already in part broken down into pus. One or two inflamed lymphatic glands were found in close proximity to the thrombosed vein; thus suggesting the possibility that the infective organisms had travelled from the original mastoid focus to these glands by way of the lymphatics, and that they had then in turn penetrated the wall of the jugular from the infected glands. If this supposition be rejected, we must perforce accept the more usual one of a metastatic transfer from the original focus, by way of the blood-current of some small mastoid vein, to the wall of the internal jugular at some point below the bulb.

Very soon afterward the patient manifested the symptoms of a metastatic pneumonia, and death followed in the course of a few days. The patient's mind, however, remained perfectly clear almost to the last. At the autopsy no evidences whatever of inflammatory action were found within the cranial cavity or in the region of the wound on the side of the neck.

Inasmuch as the thorough removal of the primary source of the infection constitutes the very first step which must be taken for the relief of the conditions described above, the necessity of previously reaching a conclusion in regard to the existence or non-existence of a thrombosis of the sigmoid sinus becomes a matter of greatly diminished importance; for the operator knows that in taking this first step he will learn what is the exact condition of the sigmoid sinus—whether unobstructed, or simply thrombosed, or both ulcerated and thrombosed; and then, if he proceeds, as he should, to

take the surgical steps which are required for the relief of these particular pathological conditions, he will in large measure discover to what extent the vessels which communicate with the sigmoid sinus are also involved in the disease. While, therefore, every possible advantage should be taken of the knowledge which is to be derived from a study of the symptomatology of the case and of the objective signs which it may present, our chief reliance must be placed upon direct inspection of the suspected organ—an inspection which, as I have advised elsewhere, should be made (with very few exceptions) in every case in which a mastoid operation is performed.

When the surrounding wall of bone has been removed, the pathological conditions of the exposed sinus may already be so pronounced that we can, by mere ocular inspection, or by palpation coupled with such inspection, determine just what this vein's condition is. Thus, for example, if the blood is still flowing through it, the exposed membranous wall of the vessel will present evidences of that elasticity which is a characteristic of all large veins. If the patient coughs, a hernia-like protrusion of the unsupported part of the vessel-wall will be observed. A similar but less sudden distension will take place when pressure is made upon the internal jugular. But if any doubts arise, the proper procedure is to thoroughly sterilize both the exposed wall of the sinus and a medium-sized aspirator needle; and then, by the aid of the latter instrument, we shall be able to determine whether or not normal venous blood is flowing through the vein.

ILLUSTRATIVE CASES.

CASE LXXXVIII.—*Case of acute suppurative inflammation of the mastoid pneumatic spaces, which was temporarily relieved by drilling through the outer cortex of the bone; subsequent extension of the inflammation backward to the sigmoid sinus; purulent periphlebitis of this vein; escape of the extradural pus through the mastoid foramen, and formation of a subperiosteal abscess midway between the mastoid process and the occipital protuberance; recovery after a simple evacuation of the pus from this abscess.*

Male, twenty-eight years of age, and of robust constitution. (New York Eye and Ear Infirmary.) August 25th, 1875. About ten days ago he began to suffer from pain in the right ear, after bathing in the ocean. A discharge soon made its appearance, but the pain has continued unabated up to the present time. On examination I find the drum-membrane red, swollen, and perforated. The skin covering the mastoid process is red, swollen, and tender when pressed with the finger. Free incision of the mastoid integuments; warm douche at home.

September 15th.—The incision afforded almost entire relief from pain.

The wound, however, has not yet fully healed, and more or less tenderness still remains in the vicinity. The discharge from the meatus is abundant.

October 7th.—During the past few days the discharge has been slight, but the pain has returned and is now quite severe. It involves the entire right side of the head. There is still tenderness on pressure behind the ear, and the skin in this region is red and swollen. Patient having been brought under the influence of ether, the mastoid integuments were divided in the line of the former incision, and the drill was applied at the usual point on the surface of the process, where the periosteum was found to have become separated from the underlying bone throughout a limited area. After two or three turns the instrument suddenly entered an oblong cavity, estimated to be about three-fifths of an inch long (vertically) and about a quarter of an inch wide. The bone through which the drill passed felt appreciably softer than natural. As the bleeding from the external wound was quite active, it was impossible to ascertain whether the cavity referred to contained pus, or not. No fragments of bone were discovered. Tent introduced into the wound.

October 8th.—Patient passed a comfortable night. Temperature, 99.5° F. Carbolized-oil dressings.

October 9th.—Quite sharp pain last night for a few hours. To-day he feels again quite free from pain. Introduction of tent to be discontinued.

October 12th.—Decided increase of pain since yesterday. It is referred to the mastoid region. Pulse is to-day quite weak (104), and patient has a decidedly drowsy appearance. Temperature, 99° F. Three leeches to be applied behind the ear; afterward hot poultices.

October 18th.—A few days ago a swelling began to develop on the right side of the head, midway between the mastoid process and the occipital protuberance, but on a little higher level than the line drawn from the latter point to the external meatus. This swelling has steadily increased in size until now it forms a well-defined lump on the side of the head. On palpation distinct fluctuation is felt. The drowsiness noticed on the 12th still continues. At the same time the patient's countenance wears an expression of suffering. An incision through the centre of the circumscribed swelling afforded escape to about half a drachm of thick pus. By means of the probe it was ascertained that the pus lay between the periosteum and the bone. Pulse ranges from 76 to 84, and is fairly strong.

October 20th.—Decided improvement in patient's condition. He has lost his appearance of drowsiness, and says that the pain is very much less than on the 18th. Both external wounds still remain open. The discharge from the auditory canal has nearly ceased.

October 27th.—Patient again complains of pain in the right side of the head, more particularly toward the occipital region and in the temple. The wound made by the last incision has apparently healed, and no visible swelling remains, but tenderness on pressure still persists in this region. A probe directed backward and upward from the bottom of the mastoid wound passes easily onward a distance of an inch and a half without encountering any resistance. Firm pressure over the point reached by the end of the probe causes a few drops of pus to escape from the mastoid wound. During the past four days the patient has been able to leave his bed and walk about the ward.

November 20th.—Since last note patient's condition has changed very little. His general condition is good. The pain has moderated to such an extent that he no longer complains of it. The second wound is again open in the form of a very small sinus. Denuded bone can still be felt through both openings.

November 24th.—The two fistulous openings not showing any tendency to heal, I to-day connected them by a deep incision, thus converting the pus-secreting region into an open wound. The bone was found to be denuded over quite a large area, but at no point could anything like a carious process be made out. At one spot an opening in the bone was found. It led in an upward direction, and its upper edge was sharp and shelving. Whether this opening, which in a normal state probably afforded a passage for one of the emissary veins, furnished, in the present pathological condition of the parts, an outlet for the pus that had accumulated between the periosteum and the bone, I was unable to determine. Wound to be stuffed daily with charpie, for the purpose of favoring its healing from the bottom.

December 15th.—For several days past the patient has been entirely free from pain in the head. The wound is apparently healing permanently.

January 15th.—External wound has healed perfectly, and patient feels as well as he ever did.

CASE LXXXIX.—*Acute inflammation of the mastoid pneumatic cells, resulting in unusually widespread destruction of bone-tissue; the dura mater and the outer wall of the sigmoid sinus laid bare by the destruction of the inner table of bone; the accompanying symptoms wholly insignificant in proportion to the extent and gravity of the pathological lesions.*

Male, forty-three years of age, and markedly subject to gouty rheumatism, consulted me on March 16th, 1898. He stated that during the previous December he experienced a severe attack of inflammation in the left ear. The pain lasted for eight days, and then, upon the appearance of a discharge, he experienced relief from his suffering. The discharge lasted for three weeks, and then seemed to cease. But soon afterward a small abscess developed just within the outer orifice of the canal. It caused little or no pain, and broke in the course of a day or two. As the discharge, which had then reappeared, showed no signs of stopping spontaneously, he consulted a physician and was put under regular treatment. The result of this was that at the end of three or four weeks (*i.e.*, about seven weeks after the commencement of the original attack) all discharge had ceased, the abscess in the canal had healed, and the perforation in the membrana tympani had closed. After this, for a period of twelve days, the patient felt perfectly well in every respect. Then he contracted a fresh "cold," as a result of prolonged exposure on a very chilly day, and a second severe earache in the same ear was the result. His physician made a free incision in the drum-membrane, afforded escape to a few drops of pus, and thus relieved him almost immediately of his pain. Three days later, a small abscess again formed at the old site, on the posterior wall of the canal, low down, near the orifice. It was incised, and a drop or two of pus was evacuated. Bare bone, as was ascertained by the introduction of a probe, formed the floor of this small abscess. No fistulous channel in the bone was discovered. In the course of two or three weeks this external

abscess and the opening in the membrana tympani had both healed for the second time. Then there followed a period of a few days during which he once more felt as if he were perfectly well. But after this the pain in the ear returned for a few hours, and a discharge reappeared at both the old openings. During all this period of twelve or thirteen weeks there had been no redness, tenderness, or swelling of the skin in the mastoid region, nor had he referred his pain at any time to this same region or to the back of the head. There had been no chills, nor any appreciable elevation of the body-temperature. It was only during the two or three days which preceded that on which I first saw him, that the patient experienced a certain amount of pain in the left frontal and occipital regions.

On examination (March 16th) I found a small perforation, with granulating edges, in the posterior half of the left membrana tympani. There was a barely recognizable degree of drooping of the posterior and superior cutaneous wall of the canal close to the membrane. Near the floor of the meatus, posteriorly and just outside the termination of the osseous portion of the canal, there was a small fistulous opening (not granulating), at the bottom of which my probe encountered roughened bone surface. There was no redness or swelling of the skin behind the affected ear, and it was doubtful whether there was or was not a slight degree of tenderness on firm pressure just over the antrum. Pulse, 92; temperature, 98.6° F.; conjunctiva of left eye bloodshot.

The usual operation was performed on the following day (March 17th). The conditions found in the bone were these: Beginning shaven-beard appearance at the usual spot, below the linea temporalis. Cortical portion everywhere hard and at least one-eighth of an inch in thickness. From the cortex down to the pneumatic cells which lie next to the antrum the bone substance was purely diploëtic in character and rather difficult to remove with the spoon. Immediately beyond this diploëtic portion, pus, granulation-tissue, and softened bone were encountered. At least a teaspoonful of pus was evacuated from the region lying behind and above the antrum, and a slightly smaller amount was found in the region bounded by the outer wall of the sigmoid sinus, the tentorium cerebelli, and the cortical layer of the bone. An imperfectly broken-down barrier of pneumatic cells separated the two collections of pus; and whatever space was not occupied by this fluid was filled with masses of granulation-tissue. In order to expose thoroughly the parts affected by disease it was found necessary to remove, at first with the chisel and afterward with the rongeur forceps, practically all of the cortex of the mastoid process; the opening in the bone thus created measuring an inch and three quarters in a vertical direction, and an inch and a quarter antero-posteriorly. All the bone substance lying between the outer cortex and the sigmoid sinus was found to be destroyed. This part of the excavation, therefore, had the membranous wall of the sigmoid sinus, and, farther back, the outer surface of the dura mater, for its inner limits. After all the granulation-tissue had been carefully removed from this part of the cavity, it was found that it extended in a backward direction some distance beyond the temporo-occipital suture, its upper limit being the tentorium cerebelli. The outer wall of the sigmoid sinus was firm and elastic, but of a black color, due probably to capillary stasis and thrombosis in its outermost layer The

exposed dura mater beyond the sigmoid sinus seemed to be simply congested. After the excavation had been thoroughly irrigated with a 1 to 3,000 bichloride solution, it was packed with iodoform gauze and the usual dressings were applied.

From this time to April 20th, when it was found that epidermis had grown over the entire surface of the former wound, not a setback of any kind occurred. At first, the dressings were found (on the fourth or fifth day following the operation) to be soaked with what seemed to be a blood-stained serum; but, after that, the fluid which moistened the dressings (in a rapidly diminishing degree) seemed to be colorless. Only on one occasion was any pus (two or three drops) found on the surface of the wound, and at no time did the temperature rise above 98.8° F.

CASE XC.—*Another instance of serious mastoid disease in a lad who continued to go about, and even to indulge in athletic sports, very much as if nothing were the matter with him; at the operation the sigmoid sinus was found protruding into the abscess cavity, its outer wall being separated from the outer surface of the mastoid process by a plate of bone one millimetre in thickness; complete recovery.*

Male, sixteen years old, in good general health. About April 15th, 1895, he experienced a sharp pain in the right ear. Dry heat was applied, and he obtained relief in the course of a few hours. During the following four weeks he occasionally, for brief periods of an hour or two, experienced a little pain behind the same ear. There was no discharge at any time from the external auditory canal, and his general health seemed to be comparatively little affected by the condition of the ear. He made the impression on his parents of being more nervous and irritable than usual, and his general appearance and manner led them to believe that he was perhaps overworked. Nevertheless, all through this period he indulged freely in athletic sports.

On May 14th, he had a second brief attack of severe pain which he referred to the region behind the right ear. Movements of the head aggravated the pain.

On May 15th, I saw the patient for the first time. The hearing-power of the right ear was then noticeably diminished. There was some drooping of the upper and posterior cutaneous wall of the external auditory canal throughout its entire length. The soft parts behind Shrapnell's membrane were also somewhat more prominent than natural, and the membrana tympani itself presented a dull and soaked appearance, but without any bulging of the membrane outward. There was no redness or swelling of the mastoid integuments, but there was some tenderness when I pressed firmly upon these parts.

Systematic poulticing and rest in bed were advised. On May 22d, I saw the patient again. The parents reported that under the treatment suggested the pain and tenderness on pressure had rapidly disappeared, the temperature had returned to the normal height, and the boy had seemingly obtained complete relief from his ear trouble. On examination I found that the drooping of the upper wall of the inner half of the canal had greatly diminished, but had not entirely disappeared, nor had the slightly prolapsed portion of the skin near Shrapnell's membrane, posteriorly, returned to its normal situation.

Aside from these two points there was absolutely nothing to indicate that the mastoid process was not in a condition of perfect health. Here again I felt disposed to look upon these slight departures from the normal condition as simply indications that the mastoid process had not entirely recovered from its recent inflammation, but that the remaining osteitis was insignificant in degree and extent. I accordingly advised the patient to go about again as usual, but to avoid athletic sports until he felt sure, by actual experiment, that his ear was once more able to bear the unusual strain.

On May 23d, still feeling quite well, he indulged during the forenoon in a single game of tennis, and walked a short distance. Early in the afternoon the pain in the mastoid region had returned, his temperature rose to over 102° F., and the skin behind the ear once more became red, swollen, and tender. Prompt and continued poulticing, with rest in bed, soon relieved the pain, swelling, and tenderness behind the ear, and restored the body-temperature to a little over 98° F.

On the 25th, I found him free from all pain, with a normal temperature, with no redness or swelling of the mastoid integuments, and only a little tenderness on firm pressure over the central and lower parts of the mastoid process. The history of the case, however, showed so plainly that a focus of disease must still be lingering on within this portion of the temporal bone, that I urged the advisability of an immediate operation. My advice was accepted, and the operation was performed during the afternoon of the same day.

After the surface of the bone had been laid bare, and the mastoid hook guide had been put in position, I applied the chisel at the usual spot, just behind and a little above the knob of the hook,—that is, just behind and a little above the curving posterior and upper margin of the entrance to the osseous external auditory canal,—and removed a single chip of bone substance about one millimetre in thickness. Immediately underneath this thin piece of bone lay what seemed to me to be slightly bluish granulation-tissue. Exploration with the probe, however, revealed the fact that it was the outer wall of the sigmoid sinus, which in this case occupied a position not only unusually far forward, but also much nearer the surface of the skull than I remember ever to have seen it before.

On further removal of the bone in a downward direction it was found that the central and lower part of the mastoid process was converted into quite a large abscess cavity, into which the curving portion of the sigmoid sinus projected to the extent of two-thirds or more of its circumference.

All this exposed surface of the vein was covered with small elevations of granulation-tissue, but the vessel was thoroughly elastic, and it was evident that the blood was still flowing through it in a natural manner. By cautious chiselling and spooning with a Volkmann's spoon directly behind the vertical portion of the sigmoid sinus, I succeeded in reaching the antrum. No recognizable pus was found here, but abundant granulation-tissue was removed both from this cavity and from the adjacent pneumatic spaces.

The further history of the case presents no features of special interest. The wound healed naturally and promptly, and no drawbacks of any kind occurred during the patient's convalescence.

CASE XCI.—*Acute suppurative inflammation of the mastoid pneumatic spaces in an individual who was affected with well-marked diabetes mellitus; operation; inner table of the bone found to be destroyed over a part of the outer wall of the sigmoid sinus; death, eight days after the operation, apparently from diabetic coma.*

Male, forty-seven years old, a physician, and somewhat emaciated in appearance. On the 16th of April, 1895, he used the nasal douche with warm salt water. Shortly afterward pain developed in the left ear. Paracentesis of the membrana tympani was performed by his son on the following day. Only temporary relief from the pain. Free discharge from the middle ear. Pain soon increased in severity, and involved the entire side of the head, although the patient felt it chiefly in the mastoid region. On the 10th of May I saw him for the first time. There was then a little tenderness on pressure behind the left ear, but no redness or œdema of the skin. The discharge from the ear seemed to be abundant, and was distinctly purulent in character. Membrana tympani red and infiltrated. The posterior and upper cutaneous wall of the inner half of the canal drooped perceptibly.

On inquiry I ascertained that the patient had been affected with well-marked diabetes mellitus for a period of at least two years, and that during the past year he had lost fully forty pounds in body weight.

Local antiphlogistic measures and rest at home were tried for eight days in the vain hope that the mastoid inflammation might thereby be relieved. Complete relief from pain was obtained, but the discharge still continued to be purulent in character and copious, the prolapse of the upper cutaneous wall still persisted, and there was no perceptible change in the degree of tenderness observed behind the ear.

The operation was performed on the 18th of May, under ether anæsthesia. The cortical portion of the mastoid process was found to be reduced in thickness to a mere shell of bone. Pus (inodorous) and granulation-tissue filled, apparently, the entire process. After removing the contents of this large cavity, I proceeded to scrape its walls with a small and rather dull-edged Volkmann's spoon in order to make sure that no diseased bone or mucous membrane should be left behind. While I was doing this, with the slender Volkmann's spoon held between my thumb and fingers as one usually holds a pen, I felt something give way on the inner and posterior portion of the cavity, and instantly there was an abundant but quiet welling up of very dark blood. From this circumstance I knew at once that I had broken through what was doubtless the ulcerated (but not yet perforated) wall of the sigmoid flexure of the lateral sinus. A temporary stuffing of simple gauze was inserted, and at the end of a few minutes it was removed in order that one of iodoform gauze might be introduced in its place. The temporary tampon, it was found, had entirely checked the hemorrhage.

May 19th.—Patient has constant nausea and is unable to keep anything on his stomach. Temperature normal. No chilly sensations.

May 20th.—Iodoform plug removed from the cavity in the mastoid process. No further bleeding. Wound looks healthy. Some headache. Iced milk retained, but nausea persists. Temperature still normal. Wet bichloride dressings, and wound douched once a day with a 1-2,000 bichloride solution.

May 22d.—Wound surface has a dirty appearance. The few granulating spots look unusually pale, as if the parts lacked vitality. Bichloride solution used in douching the wound to be increased in strength to 1–1,000, and the douching itself to be employed twice instead of once a day. The temperature still continues to be normal, the pain in the head has gone, and the nausea is slowly becoming less marked, but the patient's general strength is evidently diminishing.

On the 26th of May, under manifestations of increasing weakness, the patient passed into a comatose condition, with rapid breathing, and died before night. There were no chills, elevation of temperature, or anything else to indicate that the opening in the sigmoid sinus had in any way aggravated the situation. His death seemed to be due to his diabetic condition, aggravated unquestionably by the disturbing effects of the administration of the anæsthetic and by the shock of the operation.

Case XCII.—*A case of extensive destruction of the bony portions of the mastoid process in consequence of acute suppurative inflammation of the middle ear; purulent periphlebitis of the sigmoid sinus; infective but benign thrombosis of this vein; prompt recovery after an extensive removal of carious bone-tissue.*

On February 10th, 1895, I was summoned to a neighboring town to see a boy, about five years of age, who was suffering from disease of the left ear. The only history which I was able to obtain—on account of the absence of the person who had taken care of the child during his recent illness—was the following: About six weeks previously he had been taken ill with pain in the left ear, and soon afterward a discharge had made its appearance. From that time onward he had experienced frequent attacks of pain in the affected ear, and the parts around the ear had become tender and very much swollen. The discharge had ceased two days previously and the pain had grown worse. A copious nosebleed from the left nasal passage had also occurred at this time. On examination I found the left auricle pushed out of place by a diffuse and very hard swelling of the soft parts behind and above the ear. After the boy had been put under the influence of an anæsthetic I made a curving incision, several inches in length, in the usual situation, and then at right angles to this I made a shorter one in the direction of the occiput. I found the tissues, along the lines of these incisions, fully an inch in thickness and as hard as those of a fibrous tumor. A small quantity of pus was set free when the surface of the bone was reached; and, when the latter had been fully exposed to view, it became evident that throughout a large area, and especially in an upward direction, it was in a state of necrosis. The excavation which I found it necessary to make, in order to remove all the bone-tissue which was either dead or suspiciously soft, was irregular in shape and of large dimensions. There was an abundance of granulation-tissue, the escape of dark blood was copious, and it continued for a comparatively long time. Pus was found in the sigmoid fossa, and the sigmoid sinus, which was evidently thrombosed, presented a granulating surface. As there had been no history of chills or sweats, or of any complication suggesting the existence of pyæmia, I did not disturb the contents of this vein. The wound was dressed in the usual manner, and the patient was left in charge of the local physician.

On the 14th of February I received word that since the operation the boy

had made no further complaint of pain; that his temperature had fallen, within a few hours, to 99.4° F.; and that it had remained at about 98° F. during the succeeding days.

The subsequent healing took place rapidly and without drawbacks of any kind; and the skin, which, in the region of the wound, had been so enormously thickened, returned to a perfectly natural condition.

CASE XCIII.—*Acute suppurative inflammation of the middle ear, extending rapidly to the mastoid pneumatic spaces, and eventually causing purulent periphlebitis of the sigmoid sinus and infective thrombosis of that vessel; three separate operations performed; ultimate recovery.*

The patient, a man of strong physique, about fifty-four years of age, consulted me on January 29th, 1894, for the relief of pain in the left ear. For several days previously he had been suffering from a "cold in the head," and on the preceding day he had taken a sleigh-ride; but he had not been conscious of having experienced at the time any chilling of the body. The pain had first been felt early in the morning of the day following that on which he took the sleigh-ride,—that is, only a few hours before he came to my office. I examined the ear, and found the membrana tympani, especially the upper half, markedly hyperæmic. There was also a decidedly congested and swollen condition of the naso-pharyngeal mucous membrane. No secretion had as yet accumulated in the drum-cavity. An application of a fifteen-grain silver-nitrate solution was made to the vault of the pharynx, and hot poulticing of the painful ear and rest in bed were prescribed.

On the following day I visited the patient at his home, and found that he had experienced very little, if any, relief from the pain in the ear. The appearance of the drum-membrane showed that the drum-cavity was already full of secretion, and that the inflammation was increasing in violence, despite the hot and moist applications. I accordingly made a long, crescent-shaped incision in the posterior half of the membrane, affording a free outlet to the pent-up, blood-stained serum, and I ordered a continuance of the poulticing and the free use of the hot-water douche.

The paracentesis afforded a measurable degree of relief, but only for a short time. On the 3d, 5th, 7th, and 10th of February it was found necessary, on account of the rapidity with which the opening healed, and on account of the return of pain whenever the opening ceased to be of fairly large size, to repeat the paracentesis. Soon after the first operation, the discharge became purulent in character and quite abundant. On the 11th or 12th of February there was a slight tenderness on pressure behind the ear, and accordingly three leeches were applied to this region.

On the 14th, as the leeches had afforded only temporary relief, a Wilde's incision was made; and on the following day a seton was established at this point. A very broad, curved needle (made specially for the purpose), with cutting edges and armed with six or eight threads of coarse silk, was introduced at the bottom of the Wilde's incision, and pushed out backward through the skin at a spot about one inch distant from the point where it had entered.

The discharge from this artificial sinus, kept in an irritated condition by the presence of the mass of silk, failed to exert any marked impression upon the amount of discharge from the middle ear or upon the subjective pain ex-

perienced by the patient. After the seton had been in place for four or five days, the patient had a sharp chill, which lasted for a few minutes, but was not followed by any appreciable rise in temperature. (The patient's body-temperature was tested nearly every day and sometimes twice a day, but it was always found to be either normal, or, at most, two-tenths or three-tenths of a degree above the normal.) At the time, I felt confident that this chill was due to the imprisonment of pus in the seton channel; for when I examined the parts, one or two hours afterward, I found both orifices practically closed by the drying up and caking of the discharge at these points.

On February 21st, Dr. Herman Knapp saw the patient with me in consultation. The pain had not been materially diminished by any of the measures which I had instituted—repeated paracenteses, hot poulticing, and frequent douching of the external auditory canal, the application of leeches to the mastoid region, a Wilde's incision followed by the introduction of a seton, an occasional dose of calomel, the daily employment of the Carlsbad Sprudel salts, etc.—and it was becoming more distinctly hemicranial in character. I therefore felt that the time had arrived when it would be wise to establish a free outlet from the mastoid antrum through the mass of bone lying outside of it. On this particular day, however, the patient felt decidedly better than he had felt for several days previously, and we accordingly agreed to postpone, at least for the moment, the consideration of the question of operative interference. It was decided, however, to remove the seton, for it was apparently accomplishing no good purpose, and yet, at the same time, it was preventing us from estimating correctly, by aid of such signs as tenderness on pressure, swelling, etc., of the skin, how the underlying mastoid inflammation was behaving. Dr. Knapp's examination of the patient's left eye with the ophthalmoscope gave a negative result.

On the following day (February 22d), the patient once more complained of decided pain in and around the ear; and, as the opening in the drum-membrane had by this time again become insufficiently large for free drainage of the inflamed middle ear, I excised a small portion of it by first making a flap (with its base below) and then snaring off its upper free extremity. The incision which marked the posterior limit of this flap approached very closely to the curved line corresponding to the insertion of the membrana tympani in the sulcus tympanicus, and as the knife passed through the thickened tissues of the membrane there was a sudden escape of thick creamy pus quite different from the muco-purulent secretion escaping from the old opening in the membrane. By further manipulations I succeeded in dislodging, through the opening, a core-like mass as large as a No. 3 shot. The introduction of a bent middle-ear probe revealed the fact that the posterior wall of the cavity from which this creamy pus and this core-like mass of broken-down tissue had been evacuated, was bone denuded of its covering of mucous membrane. In other words, I had accidentally evacuated a separate collection of pus, located at the posterior end of the tympanic cavity, between the surface of the bone and the mucous membrane (periosteum), just beneath the entrance to the mastoid antrum. In the natural state, the bone at this point is somewhat rough and irregular. From the sense of touch alone, therefore, I could draw no safe conclusion as to its condition. There could be no doubt, however, about its being in a state of inflammation.

The relief afforded by this operation was but very little, if at all, greater than that afforded by my previous simple paracenteses.

On March 1st, Dr. Knapp again saw the patient with me, and it was decided to cut down to the antrum. The operation was performed in the usual manner. No well marked pneumatic cells were encountered until I had chiselled away the bone to a depth of nearly half an inch. These cells were all found to be filled with granulation-tissue, and at all points the bone substance was found to be in a condition of marked hyperæmia. Close to the antrum, however, it was found to be of a bluish-black color and softened. No pus was encountered until the antrum was reached, and then only a barely recognizable amount. Every portion of the wound, the antrum, and the tympanic cavity proper, was thoroughly irrigated with a 1 to 4,000 bichloride solution,—the fluid escaping freely from the middle ear into the external auditory canal. No sutures were employed, and the wound was dressed with iodoform gauze.

From the 1st of March to the 16th nothing worthy of special note occurred. The operation caused the pain to almost disappear at first, but gradually it returned, and steadily increased up to the date last mentioned. Then, in the belief that there might perhaps be some obstruction to the free escape of pus, I reopened the wound freely, and, with a Volkmann's spoon, cleared away all the granulation-tissue which had formed in the antrum and in the excavation made in the bone, outside of the antrum. This procedure, however, afforded only temporary relief. From time to time during the following three weeks I tried different kinds of drainage-tubes and contrivances, in the hope of securing complete freedom from pressure upon the mass of escaping pus; for whenever I succeeded in accomplishing this, even for a short time, I observed that the patient experienced comparative freedom from pain. But the discharge was abundant and granulation-tissue repeatedly blocked the openings in the drainage-tube, thus re-establishing the condition of pressure which was so undesirable. It was during this period that the patient had the second and last chill that he experienced during the entire illness. The drainage-tube, at the time, was completely blocked, and there was an appreciable increase in tension of the skin surrounding the outlet. I am unable to state whether this second chill was or was not associated with a rise in the body-temperature.

Toward the end of the period now under consideration, there was a noticeable increase in the redness and swelling of the integuments covering the lower and posterior part of the mastoid process, and the lateral movements of the head caused some distress. But there was no tenderness along the side of the neck, and the tenderness over the tip and posterior aspect of the mastoid bone was but little, if at all, greater than one usually finds in the vicinity of a still open mastoid wound. The discharge, however, was more copious than it should be from such a wound, and I made up my mind that there must be a centre of active osteitis in the lower part of the mastoid bone. Accordingly, on April 9th, the patient was put under the influence of chloroform, and a considerable portion of the lower part of the mastoid process was removed by chiselling. No centre of pus was found, but everywhere the bone appeared to be in a markedly hyperæmic state.

During the week following this operation the patient's condition steadily

grew worse in the following respects: The movements of the head became more painful, there began to be an appreciable degree of tenderness below the mastoid process, and the swelling, tenderness, and pain in the region lying between the mastoid bone and the occiput increased to an appreciable degree. Then, besides, he found that he could read for only a short time, on account of the pain which it produced in the left eye. On the other hand, the body-temperature did not rise above 99.4° F., the pulse-rate did not exceed 82 beats to the minute, and the patient continued to take his food with relish. The symptoms just enumerated, however, satisfied me that the inflammation was extending in a backward and perhaps inward direction, and that a bolder search for some centre of pus should be made in these directions. This conclusion was still further strengthened by my finding, on April 13th, that pus from some new source, situated below the artificial opening in the bone, was burrowing down the side of the neck in front of the sterno-cleido-mastoid muscle.

On April 14th, the patient was brought under the influence of chloroform, and I proceeded to chisel away the outer and posterior surface of the mastoid process. At all points the bone was found to be markedly hyperæmic, but no pus or appreciable softening of the bone substance was found until the immediate wall of the channel for the sinus (sigmoid groove) was reached. At this point, situated at a depth of fully half an inch from the outer surface of the mastoid process, the bone seemed to have undergone a certain degree of softening, and odorless, creamy pus welled up from this cavity as soon as the chisel cut through the surrounding softened wall of bone. By means partly of the chisel and partly of a medium-sized Volkmann's spoon I enlarged the opening until it measured about three-eighths of an inch in diameter. The outer wall of the exposed vein was found to be granulating, but not softened, so far as I could judge from pressure with the probe. The absence of all tension warranted the belief that the vein was thrombosed at this point. So far as I could judge, the pus surrounding the vein came partly from some point higher up and partly from below. I fully expected to discover roughened bone, or the opening of a fistula, at some point along the anterior aspect of the sigmoid groove, but my probe revealed no such point.

The situation of affairs, as brought to light more fully by this operation, made me feel that I could no longer do full justice to the case; that, in the further search for centres of pus, regions would have to be laid bare with which I did not feel myself to be sufficiently familiar; and that, therefore, a general surgeon should be summoned. Accordingly, Dr. Frederic Lange was invited to take charge. The patient was once more anæsthetized (April 16th), and Dr. Lange proceeded first to expose thoroughly the downward track of the pus along the jugular vein. Then he removed, by chiselling and by the use of the rongeur forceps, all that remained of the mastoid process; thus laying bare the jugular vein from its situation in the sigmoid groove down to a point perhaps one inch below the level of the tip of the mastoid process. All of the jugular vein thus exposed to view was evidently in a thrombosed condition, as its walls showed no changes in tension when firm pressure was made upon the side of the neck, lower down, or when the patient coughed. Dr. Lange also removed, in an upward direction, that part

of the temporal bone which covered the upper portion of the sigmoid sinus, thus gaining free access to any collection of pus that might exist in this part of the cranial cavity. No such collection, however, was found. Then, finally, he worked his way cautiously downward and inward until he had exposed the styloid process, the trunk of the facial nerve as it emerges from the stylo-mastoid foramen, and the region beneath the foramen lacerum. The probe was passed through this opening into the cranial cavity, but no collection of pus was found. All this work, I scarcely need to state, was performed under constant aseptic and antiseptic precautions. After the operation was completed, a drainage-tube was laid in the wound, with its inner end resting against the deepest part of the excavation, and iodoform gauze was packed around it. A few turns of a bichloride gauze bandage served to keep the dressings well in place.

On the day following the operation, the temperature rose to 100.4° F., and then gradually fell, during the course of the following week, to normal. The pain in the left eye brought on by reading gradually disappeared, and with it the slight alterations observed by Dr. Knapp, shortly after the operation, in the fundus of the eye. At the end of three weeks the patient was allowed to leave his bed, and at the end of about six the wound had entirely healed.

The discharge from the middle ear, by way of the external auditory canal, ceased on the third or fourth day after the first operation upon the mastoid process, but on two or three subsequent occasions it returned for brief periods of time. It was not clear to what these slight relapses were due; but it is probable that some interference with the drainage from the antrum, by way of the outside wound, caused sufficient back pressure to reopen the perforation in the membrana tympani.

Throughout almost the entire attack the hearing in the affected ear remained fairly good, and soon after the last operation it returned to a practically normal condition.

Comments.—The most striking feature in this case, as it seems to me, is to to be found in the fact that the disease began, almost at the very start, as an osteitis. There was, it is true, the usual antecedent naso-pharyngeal inflammation, and this inflammation spread in the usual manner to the mucous membrane of the middle ear. But the course which it pursued, after it had reached the latter cavity, was certainly very different from that which we are accustomed to see in the vast majority of cases. I have often said to myself, and have perhaps expressed the view to others, that if an acute inflammation of the middle ear (not associated with diphtheria, measles, scarlet fever, small-pox, or typhoid fever) could be subjected to suitable treatment within the first twenty-four hours, it would never progress so far as to seriously involve the neighboring mastoid process. In the present instance the patient presented himself within a few hours of the time when he felt the first twinges of pain in the ear. Simple antiphlogistic measures were

employed immediately, and then, as soon as any secretion had accumulated in the drum-cavity—that is, at the end of twenty-four hours—a very free opening was made in the drum-membrane, in order that intra-tympanic pressure—the factor which is believed to play perhaps the most important part in the aggravation and further spread of an acute middle-ear inflammation—might be quickly done away with. And yet, despite all these measures, which were carried out at an exceptionally early stage of the disease, the mastoid process became involved to a very serious degree. The most plausible explanation of this lack of success in arresting the inflammation is to be found, I believe, in the assumption—which is strengthened by the facts revealed in the later course of the disease—that already at this early stage the bacteria had invaded the adjacent bone, particularly that portion which lies near the posterior end of the tympanum and around the antrum. It is not unlikely, furthermore, that there may have been certain anatomical peculiarities which rendered this mastoid bone more than ordinarily liable to such an invasion. As favoring this view, I may mention the facts that seventeen years before the present attack I operated upon this same patient's right mastoid process, and that one of the most troublesome features in the case was an obstinate tendency to the formation of firm granulation-tissue around a small spot of bone caries situated at the posterior end of the tympanum, just beneath the entrance to the antrum.

The following case illustrates well not only the serious results which may flow from an infective thrombosis of the lateral sinus, but also how the surgeon, if he fully comprehends the situation and is prompt in combating the different pathological events as they develop one after the other, may have the satisfaction of rescuing a patient from death.

Dr. Frederic Whiting's Case.[1]

Case XCIV.—*Pyæmic sinus-thrombosis following an imperfect removal of diseased bone from the vicinity of the sigmoid sinus; internal jugular laid open from its horizontal portion, within the cranial cavity, to a point about half an inch below the clavicle; development of several metastatic abscesses at brief intervals following the second operation; final and complete recovery about nine weeks later.*

Female, aged thirty years, and in good health, had a severe attack of the grippe during the last week of February, 1897. In order to relieve the con-

[1] Published in the Archives of Otology, vol. xxvii., No. 1, 1898, and reproduced here partly *verbatim* and partly in a condensed form.

gestion of her head she employed, on two occasions, the nasal douche, with a solution of salt. On the second occasion the douching was followed by a sharp pain in the right ear, which lasted for three days. Profuse suppuration then set in and the pain became less marked. In the course of another three or four days the discharge from the ear had diminished in quantity, but the skin over the mastoid process had become swollen, and there was tenderness on pressure. Simple douching with hot water was prescribed.

On the 20th of March, when she was admitted for the first time to the wards of the Infirmary (but not under Dr. Whiting's care), her condition was as follows: Body-temperature, 100° F.; the skin over the right mastoid process was œdematous and very tender when pressed upon; the supero-posterior cutaneous wall of the canal was pushed out from the bone; and there was a profuse discharge.

A mastoid operation was performed on March 22d, and pus was evacuated. The bony wall of the sigmoid groove was found to be in a carious condition, and the diseased parts were removed by curetting. The sinus itself showed no signs of being diseased, and accordingly was not further disturbed. After April 3d the patient came regularly to the Infirmary to have her wound dressed. Her temperature, when she left the ward, was 98° F., and she seemed to be on the high road to recovery. During the following three months the wound was dressed regularly, but it was noted that it was slow in healing. Exposed bone was found when the probe was employed, but no symptoms of a systemic disturbance occurred until July 24th. Then the patient had a severe chill, which was accompanied by a rapid rise of temperature. During the following four days she had sometimes one and sometimes two chills daily, with fever, loss of appetite, and frequent vomiting.

On July 29th, when she was transferred to the service of Dr. Whiting, she was carried into the ward in a state of collapse. Her complexion was of an ashy hue and her face was covered with cold perspiration. Her pulse was feeble (rate, 108) and her temperature stood at 101° F. After she had been put to bed her temperature rose rapidly, until it reached 106° F. Then, a few hours later, it was found to have fallen to 101° F. The urine contained a large amount of albumin, together with some hyaline and blood casts; specific gravity, 1.015.

Inspection of the mastoid showed an open wound, the result of incomplete healing; the lips of the wound were sloughing. There was an œdematous condition of the scalp both upward toward the vertex and backward toward the occiput. There was also marked tenderness along the course of the jugular on the right side of the neck.

"A fact of much interest, in view of what subsequently occurred during the course of healing, may be appropriately mentioned here. While inspecting the cervical region of the patient upon the affected side, I laid my finger with sufficient force to make obstructive pressure across the course of the external jugular; and notwithstanding that the pressure was continued for a considerable period, no turgescence of the vein ensued, and, indeed, there was no appreciable difference to be noted in the size of the vessel when pressed upon or when unimpeded; while upon the healthy side the external

jugular, although not unduly prominent, upon very light pressure became immediately engorged to a pronounced degree."

On the following morning Dr. Whiting operated. "The wound made in the original mastoid operation was extended directly upward to the squamous suture, and a second incision was made extending backward from the first to the level of the centre of the meatus auditorius externus, three inches, or nearly to the occipital protuberance; these flaps were easily raised except near the site of the original wound, where the periosteum was adherent and thickened. When the flaps were elevated over the foramen of exit for the mastoid vein, there was no bleeding, an important diagnostic point. With sharp curettes and rongeur an extensive area of necrosed bone was removed, extending from the remains of the mastoid tip upward well into the squama, exposing the temporo-sphenoidal lobe, and backward over the sigmoid groove, the entire bony wall of which, as far downward as the foramen lacerum posterius, was soft almost like cork, and was easily broken away in large pieces; there was necrosis of the entire mastoid apophysis.

"The sigmoid sinus was uncovered at the knee and backward one and one-half inches along the horizontal portion; also all the descending portion as far as the jugular bulb. Every bit of the inner table comprised in the sigmoid groove was discolored a dark or brownish hue, more marked downward toward the jugular, and was roughened and fenestrated with numberless minute perforations, in none of which were any granulations found. Upon inspecting the parietal wall of the sinus it was found quite free from any plastic lymph or granulation, was greatly distended, tense, and prominent; there was *no pulsation seen or felt*, and upon palpation the sinus was very firm and resisting; the walls were intact throughout, both on parietal and visceral surfaces, there being no discoverable point where ulceration had supervened.

"The exposed dura in the immediate neighborhood of the sinus appeared normal in color, and did not bulge or pulsate unduly; a thoroughly sterilized aspirating needle was now introduced into the sinus as far back toward the torcular as the opening in the bone would permit; the attempt at aspirating was negative. The needle was again rendered aseptic by boiling, and reintroduced at the jugular bulb, which second attempt at aspiration was equally unproductive. Feeling, thereupon, entirely certain that a thrombus filling the sinus completely had been encountered, I incised the parietal wall parallel to the course of the vein from behind downward to the bulb; there was no flow of blood following the incision, and the exposed clot varied in consistency from a firmly organized resisting mass near the torcular to a collection of thin, foul-smelling pus with some stringy inspissated lymph, which adhered closely to the vessel walls at the bulb.

"The proximal end of the opening, in which was the greatest quantity of pus, and where the disintegration of the thrombus was complete, was packed with iodoform gauze, that its contents might not mingle with, and further infect, the contents of the distal extremity of the sinus.

"With a curette the sinus toward the torcular was quickly cleared of its obstructing contents, and a copious flow of blood allowed to escape momentarily unchecked, with the anticipation that any loose infective particles might become in this manner detached and expelled; the bleeding was then

controlled by packing iodoform gauze into the lumen of the vein, and the curetting applied with diligence downward to the jugular bulb, from which much thick, ropy pus and granulation of putrid odor was removed, also a considerable quantity of what appeared like cholesteatomatous material; but no flow of blood was established, notwithstanding the fact that the curette was passed through the posterior lacerated foramen into the jugular vein; pressure below on the neck from the clavicle upward in the course of the vein was also inefficient, and all attempts to restore the circulation from this direction were abandoned.

"The opening in the sinus and the wound in the skull were now thoroughly flushed out with a solution of bichloride of mercury (1 to 5,000) and as rapidly as possible packed with iodoform gauze.

"After cleansing the skin of the neck and chest, and making the region aseptic, the internal jugular was exposed throughout its entire length, and after being raised from its sheath was ligated in the inferior carotid triangle one-half inch or more below the level of the clavicle, and also at its emergence from the skull; the facial vein, which was patent and which bled upon being intentionally wounded near its junction with the oblique, was likewise ligated. When first exposed upon opening the neck the jugular did not pulsate, and it felt as if filled with a soft cruoric clot; this proved to be precisely the case, for upon splitting the vein between the ligatures a soft fibrinous clot was encountered which was easily stripped with the fingers from its endothelial lining; this clot was evidently a very recent extension into the jugular, for it did not seem to be organized or even firmly adherent in any part, and was free from odor. Low in the neck as was the ligation, it is my belief that the coagulation extended still deeper, probably quite to the innominate vein, but was enacting a conservative process, forming a barrier which prevented the dissemination of the disorganized infective thrombus above. The wound was drawn together at the centre with a stitch, and was packed with iodoform gauze above and below. The vein was not resected. The side of head and neck were then dressed with iodoform gauze over which a layer of bichloride gauze was placed, the whole being covered with cotton and bandaged.

"The duration of the entire operation was one hour and thirty minutes, during which time the patient required free and constant stimulation. Upon returning her to bed, hot-water bags were applied to feet and epigastrium, and transfusion of normal salt solution at temperature of 105° F. was made into the cellular tissues of the abdomen, 16 ounces in amount. Patient rallied promptly and appeared stronger. Two hours later, her heart action again became weak, but reacted to hypodermic stimulation. At 12 M. temperature was 100°; at 2 P.M., 103.2°, the highest point during the day. She complained of pain in the occipital region, and experienced relief upon the application of an ice-cap.

"July 30th.—Patient passed a nearly sleepless night, although complaining of but little pain. She had retained all medicine and nourishment during the twenty-four hours ensuing after the operation, while for three days before the operation she had vomited everything taken into the stomach. During the following three days the condition of the patient was most critical; her temperature was high—on one occasion 104.2°, and seldom be-

low 100°; her pulse averaged nearly 120, and her respirations about 40 to the minute. She slept infrequently and for but brief periods. There were no attacks of heart failure, for the stimulation with strychnia, digitalis, whiskey, and ammonia was persisted in, and her stomach refused nothing that was offered. To this most fortunate circumstance and to her own fortitude the woman largely owed her recovery from the ensuing long illness.

"On August 3d, ninety-six hours after the operation, the packing was for the first time removed entirely from the wounds of the skull and neck. Up to this time the outer dressings only had been changed. Upon removing the packing from the distal end of the opening in the sinus there was free hemorrhage, and fresh packing of iodoform gauze was quickly introduced, easily controlling the flow. When the bulb was washed out there was scarcely any detectable odor to the scanty discharge expelled; in this wise differing materially from the case reported by Forselle, where the odor persisted in the discharges for ten days or more. The wounds looked healthy and were beginning to granulate, and were repacked as before. On this day the urine was examined, and was found free of albumin for the first time. A few casts, however, were found.

"She complained of some pain in the left arm just over the outer condyle of the humerus; and as the tissues felt somewhat indurated and looked slightly reddened, they were poulticed. The following day—sixth day after operation—deep fluctuation could be felt. Accordingly an incision was made, and pus to the amount of six ounces was evacuated.

"On the following day patient's temperature again mounted rapidly to 104°, and she complained of pain in the left thigh. On palpation deep fluctuation was felt and the contour of the thigh looked slightly bulging on the outer aspect. After incision, twenty ounces of pus were evacuated. This abscess was opened six days after the operation. Upon the eighth day all the dressings of head and neck wounds were again changed. There was still some little bleeding from the distal end of sinus opening, easily controlled by gauze placed against the opening and not packed into the lumen of the sinus.

"During the next five days the patient's condition improved gradually. She took more nourishment and appeared stronger; but upon August 12th, the fifteenth day after the operation, she became suddenly delirious, and, when free from restraint, attempted to leave the bed. Her delirium was active for about one week, and then slowly began to mend; in two weeks it had entirely disappeared.[1] On August 22d there was detected a small abscess in the sterno-cleido-mastoid muscle, about in the middle third, in opening which the incision was carried directly across the course of the external jugular vein, which vessel was divided. The cut ends of the vein thus exposed were greatly thickened, appearing to have the firm tense walls of a large artery, and gaping widely instead of collapsing, as is usual with a vein. There was no clot to be seen in the lumen, but notwithstanding this fact no blood escaped from either end of the divided vessel.

"On August 25th, the examination of urine showed no albumin, no casts,

[1] Dr. Whiting attributes these cerebral disturbances to a small embolism, the embolus being probably non-infective in character.

and but few epithelial cells. On this same day a swelling was noticed on the right arm, just below the external condyle; it was tender and fluctuated, and, upon being opened, pus to the amount of two ounces was evacuated. This was the last metastatic manifestation in the case, and occurred twenty-eight days after the operation.

"The wound in the neck closed six weeks after the operation, the healing being, I believe, much retarded by the presence of the jugular, which should have been resected, and which, having been in part infected, suppurated instead of becoming organized.

"On September 20th, the patient's temperature became normal, and she was permitted to sit in a chair beside the bed; and on October 4th she was discharged from the hospital for further attendance in the outdoor clinic, having been sixty-eight days under treatment—a very protracted convalescence; but when the intensity of the sepsis is considered, even this tardy recovery is cause for hearty congratulation."

FURTHER OPERATIVE MEASURES REQUIRED WHEN IT IS DISCOVERED THAT THROMBOSIS OF THE SIGMOID SINUS EXISTS.

A number of cases have been observed in which the presence of a thrombus in the sigmoid sinus has not been followed by pyæmic symptoms, by the development of metastatic foci (abscesses or embolism), or by any other perceptible results of a harmful nature (Cases XCII. and XCIII. belong in this category). In these instances the infective organisms, which presumably are always present in otitic thrombi, seem—in exciting a phlebitis of limited extent and in giving rise to the formation of a thrombus—to have exhausted their powers for harm. Unfortunately we possess no thoroughly trustworthy means of determining beforehand what is likely to be the further behavior of the thrombus in any given case of mastoid disease. Whether such a thrombus be still in the semi-solid, gelatinous condition, or whether it have already broken down, at its point of origin, into a purulent fluid, are matters which seem to bear no fixed and constant relationship to the subsequent course of the disease. Both conditions may lead to pyæmic phenomena, and consequently one is compelled to look upon every thrombus and every venous channel which has been the seat of such an otitic phlebitis as dangerous centres of infection.

Provided we are satisfied that the blood is still flowing through the sinus, we may disregard the existence of a periphlebitis, as shown by the granulating condition of the outer wall of the sinus, by its blackened appearance, or by the presence of a collection of pus between it and the surrounding wall of bone. I have encountered one or the other of these conditions in several cases, and have

in these instances limited my interference to the thorough removal of all surrounding sources of infection; and yet in every one of them complete recovery has taken place, after the operation, without the development of any pyæmic or metastatic phenomena. Further experience may teach me that I must make certain exceptions to this rule, or that I must abandon it altogether; but up to the present time, I have seen no reason for changing it, as it has worked with entire satisfaction. On the other hand, if we find that the blood has ceased to flow in the sinus—or, in other words, that it is thrombosed,—then the question arises: What further steps should be taken in order to protect our patient from the dangers of pyæmic infection? For an answer to this question I must fall back upon the experience of others, as in recent years (since February, 1895) no case of this character has fallen under my observation. So far as I am able to judge from the published views of those who have had experience in the management of this group of cases, the time has not yet arrived when an entirely satisfactory set of rules can be formulated. Nevertheless, that period is very near at hand, and in the mean time there are several points in regard to which the greater number of authorities agree. Thus, for example, if upon removal of the adjacent bone it be found that the wall of the sinus is ulcerated (generally at a point abreast of the antrum), and that purulent fluid and broken-down thrombus débris are contained within this vessel, it is generally believed that, before disturbing this focus of infection, the mass of bone which lies below the exposed part of the sinus, and which forms the outer wall of the bulb of the internal jugular vein, should all be removed until the commencing portion of the internal jugular is reached. A ligature is then to be placed around this vein at this point; the object of this procedure being to prevent any of the septic material contained in the sinus proper from passing downward, and so ultimately getting into the pulmonary circulation. The possible entrance of air into the vein will also be prevented by this procedure. After this safeguard has been provided, the sinus should be laid open freely from the point of ulceration upward to the horizontal portion of the sinus, and also some distance downward toward the bulb. Then by aid of the sharp-edged spoon or curette, introduced far in toward the torcular, the thrombus should be removed from this part of the vessel, in the hope of re-establishing a current of blood from this direction;[1] and, inasmuch as this

[1] To Zaufal is due the credit of first suggesting (Prager medizinische Wochenschrift, 1880) the feasibility of opening and cleansing the lateral

current may serve the useful purpose of expelling any infective material that may have been left behind, it is well—as suggested by Dr. Whiting—to allow the blood to flow for a moment or two before any effort is made to arrest it. Then, instead of forcing an iodoform gauze tampon into the calibre of the bleeding sinus, the same authority recommends that the gauze be simply packed against the walls of the vessel at this point. The reason why outside packing is to be preferred to a tampon is, that when the time comes for renewing the dressings the removal of the pad of gauze will be much less likely to cause a troublesome hemorrhage. The cleansing of the lower or proximal part of the sinus follows next in order; and, when this has been satisfactorily accomplished, a tampon of iodoform gauze should be introduced into the calibre of the open vessel. The presence of the ligature just below this point removes all danger of the occurrence of a hemorrhage when later it shall become necessary to remove the tampon and to introduce a fresh one in its place.

The course to be pursued with regard to the lower part of the jugular (the part below the ligature) will depend upon the condition which it presents. If, upon exploration for a certain distance below the ligature, it be found not to contain a thrombus, no further interference with it will be necessary. But if, on the other hand, the thrombosed condition be found to extend some distance downward, or if evidences of phlebitis (without thrombosis) exist, the incision through the skin should be continued down the neck (which must be previously rendered aseptic in the usual manner), over the sterno-mastoid muscle, the vein should be freed from its surroundings, and a second ligature should be applied below the thrombus, or—if this be found to extend below the clavicle—to the lowest part of the vessel which can be readily reached (*i.e.*, at a point just inside the upper edge of the clavicle). Dr. Whiting recommends that the portion of the jugular which lies between the two ligatures should be resected, as otherwise the presence of this infected vessel in the wound of the neck will be likely to delay healing.

It is not likely that there would be any serious disagreement among surgeons in regard to the wisdom of the different measures

sinus from disintegrated purulent thrombi, and of ligating the internal jugular as a prophylactic measure against the dissemination of infective particles. He was also the first operator to carry out this idea in actual practice (1884) (Whiting).

recommended above as being necessary for the cure of an ulcerated and thrombosed sigmoid sinus, with its attendant pathological conditions in the internal jugular. But it is possible that they might not all agree in regard to the proper course to be pursued in cases like those which I have narrated on pages 472 and 473 (Cases XCII. and XCIII.). In these cases there was no ulceration, redness, or perceptible softening of the wall of the sinus; the contained thrombus was certainly not hard; and if the vessel had been incised, or punctured with an aspirator needle, in order that we might learn exactly what was the condition of its contents, it is not likely that we should have found anything more than a recently formed coagulum of blood —differing, however, from an ordinary clot of blood in one respect, viz., that it contained infective micro-organisms. In Case XCIII., the patient had, it is true, shown no symptoms of pyæmic infection, and this undoubtedly influenced the operator in reaching the decision not to disturb in any manner the thrombosed sinus. The correctness of his decision, in this particular instance, is shown by the patient's subsequent rapid and complete recovery. But the question naturally suggests itself: Are we justified, in the light of this and other similar experiences, in formulating a rule that when, in the course of a suppurative disease of the middle ear and mastoid cells, we find a thrombosed sinus free from evidences of softening or of active inflammation, easily compressible, and unaccompanied by pyæmic manifestations, we may leave it alone, and trust simply to the thorough removal of all the diseased tissues in the vicinity? The patients in regard to whom such a question would be likely to arise are usually in a fairly good general condition, and therefore well able to bear a secondary operation, if subsequently the development of pyæmic symptoms should render such interference necessary. Consequently the decision not to disturb the sinus at that particular time would not preclude our resorting to such interference at some later date. There would seem, therefore, to be some justification for not interfering with the thrombosed sinus in a case like the one under consideration. And yet in adopting this course we should certainly be running some risk.

Prognosis.—The results of operative interference in pyæmic sinus thrombosis are constantly growing more favorable. The latest report of which I have any knowledge is that of Dr. Whiting, from which it appears that out of 139 operations—including both those in which the internal jugular was previously ligated and those in which this precaution was not taken—95 (a little over 68

per cent) terminated in recovery, and 44 in death. "Hessler's[1] table of operations after the appearance of metastases shows that of 29 such cases, 12 recovered and 17 died. Of the 12 recoveries, 10 were made after jugular ligation; of the 17 deaths, 10 were without ligation, and 7 with. In his table of cases without metastases the results are much more favorable. Of 30 cases operated, 24 recovered and 6 died. Of the 24 recoveries, 11 were with jugular ligation, and 13 without. Of the 6 deaths, 3 died with, and 3 without ligation" (Whiting).

[1] Ueber die otitische Pyämie, Archiv für Ohrenheilkunde, Bd. xxxviii., 1895.

CHAPTER XXII.

MENINGITIS; EXTRADURAL ABSCESS; AND ABSCESS OF THE BRAIN.

SYMPTOMATOLOGY AND DIAGNOSIS.

Extradural abscess, like the condition which is commonly termed suppurative periphlebitis of the sigmoid sinus, possesses, in its earlier stages, no special symptoms distinguishable from those of the main disease in the mastoid process. With the further advance of the disease, however, it may induce a sufficient increase of the intracranial pressure to give rise to some or all of the symptoms of abscess of the brain; or the infection may spread from it to the immediate coverings of that organ, and thus produce the symptoms of a diffuse meningitis.

The two localities in which an otitic brain abscess commonly develops are the cerebellum and the temporo-sphenoidal lobe of the cerebrum. When a suppurative inflammation of the middle ear is not provided, by natural processes or through surgical interference, with an adequate drainage outlet, it is likely in the course of time to involve neighboring organs; and the particular direction in which this advance shall take place depends in large measure upon the anatomical relations peculiar to each individual case. Thus, for example, if the subject of such an inflammation happens to have an unusually resistant membrana tympani, a feebly developed system of pneumatic cells, and a defective tegmen tympani (or one through which exceptionally large blood-vessels pass into the cranial cavity), he is very likely, if the needed drainage is withheld for a long time, to suffer from the development of an abscess in his temporo-sphenoidal lobe. The disease advances in this direction simply because it meets with less resistance along this path than it does along any other. Then, in another case, if the mass of bone lying between the antrum and the sigmoid sinus undergoes destruction, and the suppurative process eventually converts the sinus itself into an abscess cavity, there is a strong probability—if death do not occur in the mean time through the more direct effects of the

sinus disease—that the adjacent cerebellum will become the seat of an abscess. These are probably the commonest ways in which the cerebrum and cerebellum become involved in the course of suppurative disease of the middle ear. That other and more remotely situated parts of the brain may also become infected in the course of an inflammation of the middle ear is now a well-established fact.[1]

The symptoms which accompany the formation of an abscess in either the cerebrum or the cerebellum may or may not possess a certain degree of individuality. They are the following: Pain in the head, cerebral excitement, drowsiness, disordered speech, pareses of various kinds, convulsions, optic neuritis, vomiting, constipation, and a slow pulse. When some or all of these symptoms develop in the course of an inflammation of the middle ear or mastoid process there is good ground for suspecting that a suppurative inflammation of the cerebrum or cerebellum has been added to the original disease of the ear. (The aural surgeon is not likely to see those cases in which a traumatism is the cause of the disease in the brain.) A positive diagnosis is possible in very few cases. This is due to the fact that not one of the symptoms named can be referred to a single cause. Then, on the other hand, an abscess—sometimes even a large one—may form in the brain, and not give rise to any of the symptoms which commonly characterize, to a greater or less degree, this disease. The diagnosis, therefore, must be made from a study of the picture as a whole, and from the order in which the symptoms follow one upon the other, and not so much from an analysis of its individual details. And yet it is indispensable that the significance of these individual symptoms should receive some consideration in this place, although what I shall say will be derived largely from outside sources, and only to a slight degree from personal observation.

ANALYSIS OF SYMPTOMS.—EARLIER STAGE.

Pain, on the same side of the head, is rarely if ever absent in the earlier stage of the disease. It is usually more severe than that which accompanies an inflammation which has not yet ex-

[1] See, for example, the very interesting case (Case III.) recently reported by Dr. Henry L. Swain, of New Haven, Conn., in vol. xxvi. of the Archives of Otology. In this instance the infection travelled from the middle ear, through the tegmen tympani, to the lateral ventricle; but the precise pathway along which it travelled could not be inferred from any demonstrable textural changes in the intervening parts.

tended materially beyond the bounds of the mastoid process. It is apt to occur in paroxysms of such severity as to cause the patient to cry out on account of the suffering. Macewen says that, even when the abscess is located in the cerebellum, the pain may be referred to the forehead.

Vomiting is apt to be present during the continuance of the painful period. It may occur without any accompanying nausea. It also certainly occurs in many cases in which there can be no question of an abscess of the brain, but in which, on the other hand, there is every reason to believe that the meninges are involved. So far, therefore, as it possesses any significance, this symptom simply indicates that a meningitis—probably a leptomeningitis—exists. It is believed that vomiting is due to irritation of the fibres of the vagus nerve.

If *rigors* are present, they point rather to the simultaneous involvement of some venous channel like the sigmoid sinus; and yet cases have been observed in which no such involvement was discovered at the time of the operation.

An *accelerated pulse*, some *elevation of the body-temperature*, and a *coated tongue* are also usually to be observed in this early stage of the disease, but they possess no special diagnostic value.

According to Macewen, this earlier stage may last only a day or a part of a day, or it may be continued for as long a period as six or seven days.

LATER PERIOD OF THE DISEASE.

The most striking features of this more advanced stage of the disease are the diminution in severity or entire absence of the pain in the head, and a noticeably dull mental condition. Both of these features were observed in two of my cases, while in the third a state of active delirium followed immediately after the period of severe pain. Macewen, who applies the very appropriate term "slow cerebration" to this dull mental state, thus describes the patient's condition: "Accompanying the slow cerebration there is a marked want of sustained attention. The patient may be roused from his somnolent condition into a sufficiently wakeful state to understand and answer simple questions. During a long interrogation, however, he will drop asleep, or even when he attempts—which he seldom does—a long answer, the first part of it will be delivered correctly, but as he proceeds, the utterance becomes more

and more slow and less articulate, the look in the eyes more distant, the eyelids close, and he sinks again into the dozing condition from which he had just been aroused. The patient may ask for a drink, and before the vessel is lifted from the table and placed to his lips he falls asleep, and has to be rewakened before he will drink."

In uncomplicated cases the *body-temperature* is, at this period of the disease, generally either normal or a little below normal; the variations are usually trifling.

The *pulse* is apt to be unusually slow—from fifty to sixty per minute; and in some cases it may be as low as thirty per minute. Wreden observed a case in which the pulse fell to fifteen. According to Macewen, a large uncomplicated abscess in the brain is generally accompanied by an appreciably slower pulse-rate than a small one. The pressure, he says, is the chief cause of the slow pulse-rate. Koerner says that an abnormally slow pulse has also been observed in cases of extradural abscess.

Constipation is commonly present.

"The *respirations* also are slow, though usually regular. They are sometimes as slow as eleven per minute. In cerebellar cases the respirations are generally much slower than in abscess of the cerebrum, and often they are irregular, and occasionally of a Cheyne-Stokes character[1]" (Macewen).

Convulsions (general) occurred in one of my cases (abscess of temporo-sphenoidal lobe). So far as I am able to learn, they are not of rare occurrence. Koerner[2] says that in cerebellar abscess general convulsions occur more frequently than those which are localized in character.

Chills are occasionally observed in cases of brain abscess in which no involvement of the sigmoid sinus can be discovered. (See the report read by Dr. Gorham Bacon before the American Otological Society at its twenty ninth annual meeting.)

Optic neuritis and *congestion of the retinal vessels* are pathological phenomena which often accompany otitic brain abscesses. According to Koerner these symptoms are observed both in cerebral and in cerebellar abscess, and are not confined to the eye belonging to the affected side, although the condition is sometimes more

[1] Movements of chest diminish in frequency and extent, then stop altogether for several seconds, and finally return gradually to the normal type.

[2] "Die Otitische Erkrankungen des Hirns, der Hirnhäute und der Blutleiter." Frankfurt am Main, 1894.

marked on this side. They have also been observed, he says, in cases of extradural abscess. According to the same authority, the oculo-motorius, among the cerebral nerves which run along the base of the brain, is the one most often affected in abscess of the temporo-sphenoidal lobe. When the collection of pus becomes at all large, it rarely fails to produce such pressure as to paralyze the oculo-motorius of the same side. This paralysis, however, is not often complete; it is usually limited to the pupillary fibres of the nerve (as shown by the abnormal dilatation of the pupil) and to those which elevate the upper eyelid (as shown by the condition of ptosis). A simultaneous *paralysis of the abducens* (producing strabismus) has been observed a few times in abscess of the temporo-sphenoidal lobe, and once in a case of cerebellar abscess.

Macewen, in explaining the paralysis which is sometimes observed in abscess of the brain, says that it "may occur from destruction of the parts involved in the molecular disintegration at the seat of the abscess, or from pressure produced by the abscess upon the surrounding brain-tissue, or from the enervating effects of the encephalitis in the zone surrounding the abscess." It must not be forgotten, however, that paralysis may also occur in other intracranial pathological processes of otitic origin, as for example in meningitis (Case C.).

Pain caused by percussion over the seat of the abscess has been noted in some of the cases. The same remark applies to the symptoms of *vertigo* and *an unsteady* or *staggering gait*. All of these symptoms and manifestations may be due to other causes as well as to the presence of an abscess in the brain. For example, all those intracranial pathological processes which are accompanied by increased pressure upon the brain as a whole, or upon certain parts of it, may give rise to one or more of the symptoms which have been enumerated above. Starr, in his "Treatise on Brain Surgery" [1] thus refers to the value to be attached to the various symptoms which occur in the course of an otitic brain abscess: "There are no local symptoms produced by abscesses in the temporo-sphenoidal lobe that we can recognize unless the abscess grows to such a point as to invade the second or first temporal convolution on the left side, when sensory aphasia develops. There are no local symptoms produced by abscess in one hemisphere of the cerebellum unless the abscess grows to the point of invading the middle lobe

[1] Published by William Wood and Company, New York.

or the peduncle upon the base, when staggering[1] begins. Thus, it is evident that in a very large majority of the cases of brain abscess developing after ear disease, the diagnosis must be based entirely upon general cerebral symptoms, and not upon any local signs."

The interest connected with the terminal stage of abscess of the brain, when not relieved by an operation, is of a scientific rather than a practical nature, and therefore the symptomatology of this stage may very properly be omitted from the present very brief sketch. It must not be forgotten, however, that an *apparent natural cure* is among the possibilities. Macewen refers to this point in the following terms: "No doubt abscesses, once they have become encapsulated, may remain at rest for long periods, during which the patient is enabled to go about and perform work without presenting any obtrusive symptoms. . . . It is also quite possible, when the abscess has become encysted and the patient is in good health, that such an abscess may not only diminish in bulk, but become finally absorbed. It need scarcely be said that no positive proof of such an occurrence exists. The capsule of the abscess is much more likely to become thickened and remain as a foreign body. The capsule and contents may even become calcified. Gowers mentions that death has occurred from an abscess after a latent period of twenty years."

Death occurs through increasing œdema of the brain (causing a constantly increasing pressure); from a penetration of the pus into the arachnoid space; and from rupture of the abscess into one of the ventricles of the brain.

Differential Diagnosis.—The intracranial conditions which, in a case of suppurative ear disease, may be accompanied by symptoms not unlike those of abscess of the brain, are the following: Extradural abscess (including suppurative periphlebitis of the sigmoid sinus), meningeal inflammation (both the tuberculous and the non-tuberculous forms), and infective sinus thrombosis. The aural surgeon, fortunately, is not called upon to determine definitively beforehand which of these four intracranial conditions is present in any given case. His first duty is rather that of demonstrating, by an actual laying bare of the dura mater and sigmoid sinus, what are the nature and the extent of the disease in these easily accessible parts. Thus, for example, he will have no difficulty in determin-

[1] The primary suppurative disease in the antrum may involve the semicircular canals, and so give rise to this very symptom, without the intervention of any disease of the brain.

ing accurately whether an extradural abscess or an infective thrombosis of the sigmoid sinus is or is not present. On the other hand, if some other sinus (the superior petrosal, for example) be the seat of the thrombosis, he will not be able actually to demonstrate the fact; but his inability to do this will be seriously felt in only rare instances. If he finds, however, that one or both of the above-named conditions are present, but that there are no other visible alterations suggesting the existence of a cerebral or a cerebellar abscess, he is warranted, as a rule, in abstaining from any further explorative work at that particular time. But if, after a day or two have gone by, it should prove to be the fact that he had erred in his judgment, and that some other centre of disease must be present in the brain—as would be shown by the fact that the measures which he had doubtless taken for the relief of the conditions actually discovered had failed to relieve the symptoms due to increased intracranial pressure—then he would be justified in assuming the existence of an abscess in the brain, and in making such exploratory punctures as will enable him to locate its exact situation.

In a certain number of cases the preliminary laying bare of the dura mater in the vicinity of the tegmen antri reveals a condition of this membrane which announces at once the probable existence of an abscess in the temporo-sphenoidal lobe of the cerebrum. The necessity of exploring the contiguous brain is then perfectly plain. The same indications may also be discovered in the neighborhood of an ulcerated sigmoid sinus.

In exceptional instances the preliminary exploration of the sigmoid sinus and dura mater (near the antrum) may reveal pathological alterations of so comparatively slight a character as to satisfy the operator that the symptoms of increased cerebral pressure exhibited by the patient must depend on something more serious than what he has thus far discovered. In such exceptional cases it is better not to postpone an exploratory puncture of the brain, but to resort to it at once.

In a mastoid case upon which I recently operated, there were aphasic symptoms, drooping of the upper eyelid, and vomiting. When the dura mater near the antrum was exposed to view it was found to be hyperæmic and quite tense. These conditions, taken in connection with the symptoms, made me fear that an abscess might already have formed in the cerebrum. But the subsequent rapid and complete recovery—favored, undoubtedly, by the exces-

sive loss of blood caused by the rupture of a very large mastoid vein—proved conclusively that a leptomeningitis must have been the only serious cerebral disease.

Dr. Herman Knapp, of this city, has published the history of a case in which the symptoms seemed to point so strongly to cerebral abscess of otitic origin that an operation for the relief of this condition was begun; but, when it was discovered that the local pathological conditions in the ear were of such a character that they could scarcely have given rise to a cerebral abscess, further operative interference was abandoned. The disease which had so closely simulated abscess of the brain was ascertained, shortly afterward, to be a tuberculous meningitis. The following is an abstract of this most instructive case:

Case XCV. (Case of Dr. Herman Knapp).—"A strong man of apparently healthy constitution, who had had discharge from his right ear for three years. It had stopped a week before I was consulted. Headache, increase of temperature (101 to 102.25 F.), with normal pulse, drowsiness, movements of hands, stupor, incoherent and difficult speech, and delirium had set in. His family physician diagnosticated partial meningitis; two eminent neurologists diagnosticated cerebral abscess *ex otitide* and advised craniotomy; so did I when I was called. I was asked to perform the operation. A small quantity of offensive pus was still in the ear. There was no painful place in the head, nor any tenderness or swelling of the mastoid. Percussion not painful. My plan in operating was to remove the outer table of the mastoid, penetrate into the antrum and the tympanic and cranial cavities. The mastoid was sclerosed. Under the outer cortex the bone-tissue was blackened in patches and contained a few small cavities, filled with thin pus. Chiselling more deeply, the bone substance appeared healthy, hard, ivory-like, uninterruptedly compact, free from caries and necrosis; it gave no clue in which way the morbid process might have entered the cranial cavity. When the wound was two centimetres deep, I proceeded no farther. The patient died three days later. The autopsy showed extensive tubercular disease of the lungs, pleura, and pericardium, and tubercular meningitis which had no connection with the ear."

ILLUSTRATIVE CASES.

Case XCVI.—*Case of intense hyperæmia of both middle ears following diphtheria, with extension of the inflammation chiefly in an upward direction; beginning meningitis; arrest of the disease partly by paracentesis of the tympanic membrane and partly by the administration of mercury and potassic iodide.*

The patient, a girl, six years of age, and of apparently delicate constitution, was seen by me for the first time on January 4th, 1876. About four

[1] Transactions of the American Otological Society for 1892. The abstract, which I have copied here, appeared in the Archives of Otology, vol xxii., No. 2, 1893.

weeks previously she had passed through a pretty severe attack of pharyngeal diphtheria, from which she had scarcely recovered, when she began, about one week previously, to complain of pain in both ears. The pain, which soon became severe, had continued with unabated severity up to the time when I saw her, robbing her of sleep and of all desire to take nourishment. On the day when I was asked to see her she had been a little delirious at times. Temperature, 105° F.; pulse, 140. The deafness seemed to be almost total. Examination with the speculum and reflected light showed the right drum-membrane to be red and swollen in its upper portions, and somewhat bulging superiorly and posteriorly; the parts were perfectly dry. On the left side the external meatus was partly filled with masses of whitish moist epithelium. The drum-membrane was red and swollen. There was no redness, swelling, or tenderness of the mastoid integuments on either side. I made a free incision through the posterior half of each membrana tympani. Only blood was evacuated by the incision. Warm douche to be used freely, also poultices.

January 5th.—No improvement. Temperature, 105° F.; pulse, 140, and feeble; sordes on teeth; tongue dry; no discharge from either ear. Child lies as if in a state of partial coma. At the suggestion of Drs. Markoe and James R. Wood, who were called in to see the child, mercury was administered: internally, in the form of calomel, in small doses; externally, in the form of inunctions of the oleate of mercury (10 per cent), frequently repeated. Bromide of potassium was also given, in conjunction with the calomel.

January 6th.—Yesterday the child was decidedly delirious, especially toward night, and cried out, at intervals, with pain (referred to the left ear chiefly). This morning, however, the child is very much better, an active discharge having established itself during the night in both ears.

From this time onward,—as I learned from her physician, Dr. A. A. Davis,—she made a rapid recovery, and regained her hearing almost perfectly.

Case XCVII.—*Acute suppurative inflammation beginning in the mastoid antrum and spending its chief force in the immediately adjacent pneumatic and diploëtic spaces; development of an extradural abscess or extension of the inflammation along the course of the posterior temporal vein of the diploë of the temporal bone; spontaneous cure by the escape of the pus through an opening in the temporo-parietal suture and the formation of an external (subperiosteal) abscess.*

Male, twenty-one years of age, in good general health (New York Eye and Ear Infirmary). November 3d, 1875. About three months ago he contracted a severe earache in the left ear from bathing in salt water. The pain continued to be severe for a period of two weeks, and then became bearable. About six weeks ago the pain again returned, and has continued with, on the whole, increasing severity up to the present time. Besides the pain and deafness he has noticed a roaring sound in the affected ear, but never any discharge. The pain now involves the entire side of the head. On examination, I find the inner half of the meatus filled with a dark-colored material looking like a mixture of cerumen and pus. There is no appreciable redness or swelling of any part of the canal. The drum-membrane is covered with a tough,

whitish material—undoubtedly a soaked and thickened layer of epithelium—which completely conceals the outlines of the hammer. A V-shaped incision was then made in the membrane, but it was not followed by any escape of fluid. By lifting up the flap, it was observed that the middle ear was filled with a semi-gelatinous substance, which very soon, however, became infiltrated with blood. Nothing abnormal observed in the region of the mastoid process.

November 6th.—Since last note there has been a constant discharge from the left ear. To-day, for the first time, the pain has been appreciably less severe than usual.

November 17th.—During the past few days there has been no discharge from the ear. The parts behind the auricle, however, have become tender and swollen. On examination I found the external auditory canal dry, and the perforation in the drum-membrane healed. The membrane had a tough, leathery appearance, and there were no evidences of inflammatory action in the immediate vicinity. The swelling behind the ear proved, on examination, to be due to the presence of a collection of fluid beneath the skin. Fluctuation was felt, not only behind the ear, but also above it. A free incision afforded escape to quite a large quantity of pus, and the probe revealed the fact that it lay, at least in part, between the periosteum and the bone. While exploring the denuded bone surface, I discovered an opening, just large enough to admit the probe, at a point about an inch and three-quarters immediately above the tip of the mastoid process. The direction of the opening was upward, inward, and a little backward, and the probe passed into this bony canal a distance of half an inch without encountering any resistance. A fresh tent to be introduced into the wound daily.

November 20th.—Entire relief from pain since abscess was opened. Wound healing rapidly. Almost no tenderness in the vicinity. (No further data.)

Case XCVIII.—*Acute suppurative inflammation of the middle ear with involvement of the mastoid pneumatic spaces, but without rupture of the tympanic membrane; operative interference, which did not extend beyond the domain of the system of mastoid pneumatic spaces, gave only partial relief; a later operation revealed the existence of an extradural abscess near the temporo-parietal suture, and gave entire and permanent relief.*

Male, fifty-two years of age, of robust health. October 14th, 1895. Patient gave the following history. He had always been somewhat deaf in the right ear. About two weeks previously he had begun to suffer from a dull pain in this ear, and from that time to the day on which I first saw him, the pain had slowly increased. There had been no tinnitus, and as yet no discharge had made its appearance. On examination I found the right membrana tympani somewhat flatter than normal, and notably white, as if cheesy material were accumulated behind it. In strong contrast with this was the red color of the adjacent skin of the canal. Posteriorly and superiorly near the membrana tympani, there was an appreciable degree of drooping of the cutaneous wall of the meatus. There was no tenderness on pressure in the mastoid region. The body-temperature stood at 99.2 F. Bowels constipated.

As there seemed to be no urgent call for operative interference, I suggested to the attending physician that the douching of the ear with hot water, two or three times a day, should be continued; that the patient should rest quietly at his home, and not attempt to go on with his work, as he had been doing; and that for a few days he should take one grain of calomel at night and half a tumblerful of Rubinat-Condal water early in the morning.

On October 28th I saw the patient for the second time, and learned that his pain had slowly but steadily grown worse. He had had no chills. On examination, I found that the prolapse of the upper cutaneous wall of the canal was more pronounced than it was at the time of his first visit; and that tenderness on pressure had developed both over the central part of the mastoid process and over a point situated half-way between the latter and the occipital protuberance. There had been no discharge from the ear at any time, and the tympanic membrane and adjacent walls of the canal were perfectly dry.

At the operation, which was performed on the very same day, at least a teaspoonful of creamy, odorless pus was found in the mastoid pneumatic spaces—the greater part of it in the cells immediately surrounding the antrum, and a smaller quantity at the very tip of the bone. Appreciable softening of the bone was found both above and behind the antrum. A dark venous blood escaped very freely from the wound in the bone all through the operation. A fair amount of granulation-tissue was also found in the larger spaces.

By the 12th of November the wound was found to have nearly healed; only a small opening remaining at a point higher than the level of the external auditory canal. While the operation had afforded him very marked relief, it had nevertheless not taken away all painful sensations; for he still experienced, every night, more or less pain in the region of the right ear.

On the 4th of January, 1896, the patient visited us for the first time after an absence of nearly eight weeks. During this interval he had got along fairly well, but at times he had experienced considerable pain in the right side of the head. There had also been a constant but not profuse discharge from the fistulous opening, and considerable redundant granulation-tissue had formed. On careful exploration with the probe it was found that high up, at about the level of the temporo-parietal suture, there was an area of roughened bone.

My associate, Dr. Robert Lewis, Jr., operated on January 6th, and removed a necrosed portion of the skull close to the temporo-parietal suture. An extradural collection of pus was found lying upon the inner side of the necrosed bone.

After this operation the patient experienced no further pain, and by the 1st of February the wound had completely healed.

Case XCIX.—*Acute suppurative inflammation of the middle ear and mastoid pneumatic spaces, without rupture of the tympanic membrane; probable extension of the disease to the cerebellum; death under comatose conditions.*

On April 3d, 1877, I was asked to see a patient, forty years of age and strongly built, who, during the previous six weeks, had complained of pain in the head. At the very first beginning of the trouble, the pain had been confined to the right ear, but soon afterward it involved the entire right side

of the head. At no time had there been any discharge from the ear. Four days previously the cutaneous wall of the right external auditory canal had been incised at two points, on account of its swollen condition; but, before that time, no treatment directed to the ear (beyond occasional syringing) had been carried out. At the time when I was asked to examine the patient, he had already become slightly delirious, and was unable to retain any food in his stomach. I found him in a very sluggish mental condition, and I was scarcely able to obtain any answers to my questions. He sat in an easy-chair, holding his head in his hands, and referred his pain mainly to the occipital region. His pupils were of normal size and responsive to light; his pulse was 58 (three days previously its rate had been 100); his body-temperature was moderately elevated (the exact record was not stated in my notes); there was no swelling, redness, or tenderness of the mastoid integuments. Examination with the speculum and reflected light showed the presence of a little fluid secretion on the floor of the canal, and only a trifling degree of swelling of the cutaneous walls. The tympanic membrane presented a soaked appearance, without any bulging or any indication of the existence of a perforation. Diagnosis: abscess of the brain—probably of the cerebellum—from an acute suppurative inflammation of the middle ear. Operative interference was believed to be unwarranted at that advanced stage of the disease.

On April 5th the patient could no longer be roused from his comatose condition; but his death did not occur until the morning of the 7th.

Case C.—*Cholesteatoma of the mastoid antrum and neighborhood; pain in the head, on the affected side; partial paralysis of the leg, on the opposite side; chilly sensations, fever, and vertigo, at irregular intervals; operation upon the mastoid bone and thorough cleansing of the cholesteatomatous cavity; apparently complete restoration of health; discharge from the ear greatly diminished, but not entirely arrested.*

Male, twenty-two years of age, strongly built, consulted me on January 7th, 1893. He gave the following history: He had had a discharge from the left ear since early childhood, but had experienced scarcely any pain until about nine weeks before. Since then he had had, on various occasions, chilly and feverish sensations, a great deal of dizziness, and more or less left-sided headache, but no pain in or around the affected ear. He had also lost twenty pounds in body weight. The discharge, which was very foul in character, and was occasionally tinged with blood, had not changed in quantity. When the patient walked across my office I noticed that he dragged the right leg just a little. I questioned him about it, and he admitted that he felt as if he were walking upon cushions. He had noticed the symptom only during the previous day or two. On examination I found no redness, swelling, or tenderness of the skin behind the left ear. Quite a large polypus filled the external meatus. I removed this with the snare, and then discovered that a marked hyperostosis of the posterior wall of the canal (inner half) screened almost the entire area of the membrana tympani from view.

I advised a mastoid operation, and urged that it should be performed with as little delay as possible. The patient, who lived in a neighboring

State, wished to have the operation performed at his home, and promised to notify me as soon as he had made certain arrangements.

On January 10th I received word that he was ready for me. On my arrival I found that he had grown noticeably worse during this interval of three days. His face presented an ashy hue, his pulse was decidedly weak (104 to 110), and he had scarcely any power over the right leg. On questioning him I found that his headache was now general, and not confined to the left side.

Ether was used as an anæsthetic. Considerable time was consumed in chiselling out a broad opening, through bone as hard as ivory and at least half an inch in thickness, into quite a large cavity which extended from the tympanum in a backward direction nearly to the sigmoid sinus. Roughly estimated, I should say that this cavity, which was filled full of foul-smelling cholesteatomatous material, was about as large as a medium-sized cherry. I cleaned it out thoroughly, partly by the use of a probe and partly by irrigation with a 1 to 4,000 bichloride solution, and then dressed the wound in the usual manner.

While the most careful examination failed to reveal the existence of an opening leading through the tegmen tympani to the dura mater, I have very little doubt that such a communication existed. The patient's symptoms certainly justified the assumption that he was suffering from at least a pachymeningitis, and that this meningeal inflammation was rapidly extending over a larger and larger area.

On the 18th of January I received word that the patient was convalescing rapidly, that the wound presented a healthy appearance, and that the paresis of his right leg was much less marked than at the time of the operation.

About one month later I learned that the patient's wound had healed, that he had fully regained the use of his leg, and that his general health was excellent. The discharge from the ear had become very scanty, but had not entirely ceased. From that time to the present I have had no further news in regard to the patient's condition.

Comments.—More than five years have elapsed since I operated upon this cholesteatomatous cavity, and if anything had happened during this long interval, I feel confident that the patient's father—himself a physician—would have notified me. The symptomatology, toward the last, certainly justified the suspicion that an abscess of the brain might already have formed; but the prompt recovery of health and of the power to control the movements of the right leg points rather to disease involving the superficial portions of the brain. The patient's collapsed condition at the time of the operation did not permit me to undertake at that time any measures for the relief of the narrowed condition of the external auditory canal; but I warned him that on some future occasion operative interference would be required in order to secure the proper breadth for the drainage channel of the antrum.

CASE CI.—*Purulent basilar meningitis (leptomeningitis) and ulceration of the sigmoid sinus, which probably originated in a cholesteatoma of the mastoid antrum and adjacent pneumatic cells; membrana tympani intact; operative interference refused by the patient; death under convulsive conditions.*

On the 21st of September, 1872, I was asked by Dr. Herman Knapp to see with him, in consultation, a Mr. F., aged fifty-seven, and of a strong constitution. The history of the case was briefly this. During the previous ten or twelve years Mr. F. had had five distinct attacks of acute purulent inflammation of the left middle ear, from all of which he made a good recovery. The present attack began about seven weeks previously, and was characterized by headache and dulness of hearing, unaccompanied by discharge. On examination of the ear Dr. Knapp found the external auditory canal swollen, especially on the posterior side; the membrana tympani injected; and the mastoid process tender on pressure. In the progress of the disease, the membrana tympani becoming more congested and convex outwardly, the doctor incised it. No pus escaped, but the patient experienced relief from his suffering for about a week. The pain then returned, and the integuments covering the mastoid process became swollen. The patient also noticed a gurgling sensation in the ear, whenever he shook his head. An incision down to and through the mastoid periosteum afforded only temporary relief. The pain again became severe. At the consultation (September 21st) it was decided that perforation of the mastoid process was the only course that offered any hope of recovery. The patient, however, refused to have the operation performed.

September 22d.—Up to this time there had been no brain symptoms, but to-day, being called in haste to see the patient during the absence of Dr. Knapp from the city, I found him unconscious, pupils non-responsive, face flushed, and head very hot; pulse about 120, and full; breathing stertorous. The friends were then willing enough to have the operation performed, but it was clearly too late. The patient died the same night.

At the post-mortem examination, purulent basilar meningitis was found, together with a free communication between the mastoid antrum and the cavity of the sigmoid sinus. The two formed together an irregularly shaped cavity filled with pus. The pus did not extend down into the jugular vein, nor back toward the torcular Herophili. Both these portions of the vein contained venous blood. Sclerosis of the mastoid cells. Membrana tympani entire.

CASE CII.—*Abscess in the tempero-sphenoidal lobe of the brain, due to ulcerative destruction of the tegmen antri and perforation of the dura mater lying above it; meningitis, epileptiform convulsions, death.*

Female, twenty-nine years of age, in fair general health (New York Eye and Ear Infirmary), February 10th, 1875. She states that she has been subject to a discharge from the left ear since childhood. About six months ago a "tumor" was discovered in the affected ear. Several attempts were made at different times to remove this "tumor," but it constantly reappeared. Of late she has experienced a great deal of pain throughout the entire left side of the head. The pain has been especially severe at night, and at times has been accompanied by what she describes as "brain fever." Occasionally she

has experienced a sensation as if the left eyeball were being pushed out from its socket.

On examination the meatus was found to be blocked by the presence of a mass of granulation-tissue. After removing the greater part of this growth with the snare, I discovered, by aid of the probe, that it sprung from the posterior wall of the meatus, near the junction of the cartilaginous with the osseous portion, and that its point of origin was close to the orifice of a sinus that led quite a distance inward and a little upward and backward. In its course the probe, which did not seem actually to enter the substance of the mastoid process, encountered denuded and crumbling bone. No redness or swelling of the skin behind the ear. Moderate tenderness on pressure over the lower part of the process and also over that portion of the skull which is situated immediately in front of the occipital protuberance.

She was advised to become an in-patient of the Infirmary, in order that she might receive better care than it would be possible for her to receive at her tenement-house home. She readily consented, and was assigned to a bed in a separate room.

February 13th.—Pain still continues. Patient having been etherized, the mastoid integuments were divided, and the bone perforated with the larger drill to a depth of three-fifths of an inch. No pus or softened bone encountered. Anteriorly, however, the periosteum was found to have become separated from the underlying bone, thus allowing the probe to pass easily along the surface of the bone into the meatus.

February 14th.—Marked relief from pain.

February 16th.—Decided swelling and tenderness in front of and above the auricle. Motions of the jaw cause pain in the region of the ear. Temperature nearly normal.

February 20th.—Since last note patient has had an attack of syncope, lasting about one hour, and requiring the use of stimulants. To-day she is in about her usual condition. Her temperature varies from 98.5 to 99.5° F. The pain in her head is nearly constant. The parts around the ear still remain swollen. The polypoid mass in the meatus having grown to such a size as to obstruct the free escape of pus from the deeper regions, I removed the larger part of it to-day with the snare.

February 24th.—This morning patient had two epileptiform seizures of short duration. The swelling in the vicinity of the ear has diminished quite noticeably. The pain, however, continues. When asked in what part of the head she felt the most pain, she replied at once, in the left eye. Her answers to other questions were at times almost unintelligible. She would begin her answer, and then stop as if trying to think what else she should say. Temperature remains at about 99° F. Profuse sweats. Occasional vomiting.

February 26th.—She is now very restless, and force has to be used to keep her in bed. Her mind wanders constantly, and she no longer pays any attention to questions addressed to her. The right eye is drawn outward and the right upper lid droops. Temperature, 101° F.

She died the same night. The discharge from the ear continued to be abundant up to the very last. No post-mortem examination was allowed. By means of the probe, however, I ascertained that the inner and posterior

bony walls of the tympanum were denuded and roughened. The bent probe passed upward and backward, through what felt like a small opening in the tegmen tympani, into the cranial cavity.

Comments.—I have very little doubt that, in the case just narrated, an abscess of the brain existed already at the time when the patient first entered the Infirmary; but at that early period of my experience with this class of cases I did not fully appreciate the two important points to which I have already called attention, viz., that in a case of long-continued purulent inflammation of the middle ear, with obstructed drainage, one may confidently assume the existence of sclerosis (condensing osteitis) of the mastoid cells, and that it is almost useless to merely establish a channel of communi cation between the antrum and the outside world. The present improved method of operating upon the mastoid process—of freely exposing and removing all the areas of disease—would doubtless have led to the discovery of the abscess of the brain, and in all probability the patient's life would have been saved.

The following case, which I have copied from Macewen's classical treatise,[1] illustrates well how direct surgical interference with the brain itself may rescue a patient from what would otherwise be a fatal ending of his malady.

(Case of Dr. Barr, of Glasgow, Scotland.)[2]

Case CIII.—*Abscess in temporo-sphenoidal lobe due to infective otitis media (evidently an acute lighting up of inflammation in an antrum and epitympanic space already filled with cholesteatomatous material). Doubtful condition of lateral sinus; lungs involved. Coming under observation on fifth week of illness. Operation; complete recovery; duration of disease, six weeks.*

"W. H., a boy aged nine years, was admitted into the Hospital for Diseases of the Ear, under the care of Dr. Barr, on January 13th, 1887. The history, previous to his admission into the hospital, as given by his mother in answer to questions, was as follows: A month prior to the operation about to be described, he complained one day of pain in the region of the right ear, which made him fret, and prevented him from sleeping at night. On the following morning his skin was hot and dry, and he vomited, after which he became drowsy, being frequently awakened, however, by sudden startings and crying fits, due to acute pain. The pain over the region of the ear, the drowsiness, the feverishness, and the occasional vomiting continued to characterize the first seven days of his illness. On the eighth day, he had a rigor which lasted a quarter of an hour, in which he shook all over and his teeth chattered. Between this time and his admission into the institution he

[1] "Pyogenic Infective Diseases of the Brain and Spinal Cord," Macmillan & Co., New York, 1893.

[2] Reported on page 171 of Dr. Macewen's work.

had in all six rigors, at intervals of about two days. On the nineteenth day of his disease he was admitted into the Hospital for Diseases of the Ear.

"His condition was then as follows: He was a greatly emaciated child, having a pale, shrunken face with livid lips, his upper one being covered by a herpetic eruption. He had a short, catching cough. His axillary temperature was 100.8° F. Pulse, 108. He was very drowsy, complained of pain over the right ear, from which there was an offensive discharge.

"Dr. Barr found a perforation to exist in the upper part of the tympanic membrane, from which some purulent secretion was escaping, although the quantity was not great. There was defective hearing on that side, but the boy's mental condition prevented an exact estimation of the degree of deafness.

"For two days after admission (twentieth and twenty-first days of his illness) his complaints of pain were not obtrusive, but the drowsiness continued. On the third day after the pain had become aggravated, he had a slight rigor. There was no evidence of an acute inflammatory process, or of retention of pus in the ear, to account for the pain, and there was neither redness nor swelling over the mastoid process. Temperature at this time was 99.6° F.; pulse 92.

"Dr. Barr perforated the mastoid process, opened into the mastoid cells, and succeeded in passing a stream of antiseptic fluid through the antrum and tympanic cavity out by the external meatus. A small quantity of purulent and caseous débris was washed out. A drainage-tube was introduced into the orifice in the bone, through which an antiseptic solution was injected twice daily, from the opening behind to the external meatus and *vice versa*. For two days subsequently no change was observed in his condition, but a slight rigor occurred on the second day after the operation (twenty-fifth day of the disease), while the pain in the head and the drowsiness became worse. On the twenty-sixth day of his illness, a copious discharge of most offensive odor escaped from the ear. His tongue was red and smooth, and he refused to take food or drink. Pulse was intermittent and irregular. A red flush frequently suffused the face.

"On the thirtieth day of his illness Dr. Barr consulted Dr. Macewen as to the presence of cerebral abscess. The condition of patient when seen was as follows: On approaching his bed a heavy fœtid odor, traceable to the discharge emanating from his right ear, was perceived. He was an extremely emaciated child, with pale, grayish face, wrinkled skin, prominent cheek-bones, and somewhat sunken eyeballs, who lay upon his right side in bed, his hand beneath his head, looking as if he were asleep with his eyelids half open. His lips were livid, and on the upper one remains of a herpetic eruption appeared. His tongue was red and dry. Sordes covered the teeth. When an attempt was made to rouse him the right upper eyelid drooped, and there was a shade of passivity over the left side of the face, with a slight dragging of the angle of the mouth toward the right. The conjunctiva of the right eye was congested, and the eyelids were smeared with pus. The pupils were equal, about medium size, and responded sluggishly to the action of light. The veins over the right side of the head were congested, and stood prominently out on his shaven head. Pain on percussion was elicited over the right temporal, while percussion over the head generally was calmly

borne. There was no œdema about the mastoid process. The right sterno-mastoid muscle was rigid. There was no hard, cord-like feeling along the line of the internal jugular, though the external jugular was prominent. Acute pain was elicited on deep digital pressure just behind the origin of the sterno-mastoid, in the tissues near the exit of the vein which passes through the posterior condylar foramen.

"He was in a state of stupor from which he could only be partially aroused, and not to such an extent as to give an intelligent answer to any question. His pulse was markedly slow, 50 to 60 per minute, and was feeble and intermittent. His limbs were extremely attenuated, and there was an irregular muscular tremor over the body generally, such as one frequently finds in approaching dissolution. He had a frequent cough with purulent expectoration, which had an offensive odor, and there were moist râles over both sides of the chest. His bowels were and had been obstinately constipated. His urine was free from albumin. It was somewhat difficult to believe that a few weeks previously this boy had been apparently stout and robust, and had been vigorously engaged at football. There was a flow of excessively fœtid fluid from the external ear, and as this was greater in amount than what would be likely to come from the antrum or middle ear, it was suspected that there might be a connection between the tympanum and the intracranial cavity.

"There was no difficulty in concluding that this patient suffered from cerebral abscess, originating in infective otitis media. It was almost certain that it was situated in the temporo-sphenoidal lobe, and it probably had a tortuous and minute communication with the middle ear. It was feared that the lung affection was secondary to the infective absorption.

"The prognosis was almost hopeless, his youth being the one favorable point. Immediate operation was advised, and with Dr. Barr's concurrence it was at once carried out.

"**Operation.**—The middle ear was washed out with an antiseptic solution, and rendered as nearly aseptic as possible. A half-inch disc of bone was removed from the squamous portion of the temporal, at a point an inch above, and half an inch behind, the centre of the external auditory meatus. The bone was normal. The dura mater was here slightly congested, and did not impart any brain impulse to the finger; neither was any discernible when the aperture in the skull was filled with fluid.

"When this membrane was opened and turned aside the brain tissue immediately bulged into the osseous aperture, and rose above its external level. The pia mater covering it was congested, and the brain-substance had a yellowish-red appearance.

"A hollow needle was inserted into the brain, in a direction which, if introduced far enough, would strike the eminence in the petrous bone, above the middle ear. After it had penetrated the brain-tissue for about three-quarters of an inch, there was a sudden discharge of foul gas, accompanied by a bubbling sound and the escape of a few bells of air and fluid. Evidently the upper part of an abscess cavity had been tapped, and this contained fœtid gas. The needle was inserted a little farther, when the pus flowed out. It was of ordinary yellowish color, and had a most offensive odor.

"After two drachms had slowly welled away, the aperture in the brain-tissue was enlarged by forceps, and portions of the brain tissue which had become necrosed were removed. These last consisted of shreds, two about the size of large horse-beans, the others that of barley grains. On their removal more pus welled away. The cavity was then washed out with a saturated solution of boracic acid. After that, however, there was still a slow oozing of pus, along with extrusion of minute shreds of brain-tissue.

"It was evident that there was a considerable zone of purulent inflammation surrounding the abscess cavity, from which the pus continued to ooze. An aperture was then drilled into the base of the skull, through the tegmen antri and tympani, involving the petro-squamosal suture. The dura mater was examined here and found to be thick and pulpy. It was penetrated, and the abscess cavity was reached. A stream of boracic lotion was passed from this aperture, so as to wash out the cavity of the abscess, and it was continued until it passed freely out by the upper opening. The current was then reversed. Even after that, when the drainage-tube was inserted, an oozing of purulent fluid took place into the tube.

"The ear was again cleansed. Chromicized chicken-bone drainage-tubes were introduced into both apertures. The parts were thickly dusted over with boracic acid, and dressed with sublimated wood-wool pads. The disc of bone was not reimplanted.

"When placed in bed patient was extremely weak, but rallied after the first few hours. A marked improvement was observable during the first week. The pulse became quicker, the temperature a little higher—both good signs; the face became brighter, the eyes clearer, the conjunctiva free from pus, the ptosis vanished, and the mental condition improved. After the first week, though kept on restricted diet, he improved in weight, and continued subsequently to do so at a rapid rate.

"Dr. Reid examined the eyes about the end of the fourth week after the operation, and could find no trace of optic neuritis, and was further of opinion that optic neuritis could not have been present at the time of the operation without having left some traces of its presence four weeks after.

"It is probable that the aperture in the tegmen tympani and membranes led into the abscess cavity, from which the larger amount of pus noted escaped before operation.

"January, 1892.—The boy was still strong and well, suffering no inconvenience from the pulsating hiatus in the skull. This soft part ultimately became hard from contraction of the connective-tissue and bone thrown out from the sides of the osseous aperture."

Case CIV.—*Mastoid disease following scarlet fever; no really curative measures were adopted until after the lapse of about five months; probable invasion of the inflamed bone structures by tubercle bacilli during this period; numerous operations; after the last of these a cure seemed to have been effected; but finally death occurred, at the end of two and a half years, from (?) tuberculous meningitis.*

Girl, seven years of age, somewhat emaciated, and with a pinched countenance, expressive of long suffering. Both parents perfectly healthy. January 3d, 1891. The history given to me was as follows: In February, 1889,

the child, while in good health, contracted scarlet fever. At the end of about six weeks an abscess appeared behind the right ear. No attempt was made to treat this condition properly until August 2d, when the child was taken to Halle, in Germany, and placed under Professor Schwartze's care. The following brief memoranda, taken from the operation-book of the hospital, give some idea of the progress of the case during the next few months: "August 2d, 1889, polypus removed from the right ear. It sprang from the posterior wall of the canal. Point of origin scraped with a sharp spoon. Incision over mastoid and removal of a loose sequestrum. The removal of this piece of bone revealed the existence of a large cavity filled with granulations. These were removed, and the carious bony walls were scraped with a sharp spoon. Antrum freely exposed. Water easily syringed in both directions. Wound dressed with a pledget of iodoform gauze.

"November 7th, 1889.—Incision of an abscess which extended as far back as the occipital bone and was located beneath the periosteum. It contained relatively little thick pus, and its lining membrane was darkly discolored. The soft parts over the abscess were greatly thickened and presented a lardaceous appearance. Wilde's incision in old scar; removal of a medium-sized sequestrum which was lying loose in the former cavity. The walls of the latter were again scraped and the cavity somewhat enlarged. A part of the posterior wall of the osseous external auditory canal was also removed. At a spot exactly one inch behind the original incision, and on a line continuous with that of the upper border of the zygomatic process, there are three carious openings in the bone, lying side by side. A slender probe introduced into these openings can be pushed on into the operation cavity. The intervening bone was chiselled away so as to leave a trough-like opening, at the bottom of which the bluish dura was visible. Powdered iodoform dusted over the exposed surfaces and a pledget of gauze laid in the trough; iodoform gauze dressings over this. Drainage-tube laid in the antrum and lips of wound sewed together.

"January 5th, 1890.—The two fistulous openings converted into one by incision of intervening skin. Bone-trough full of healthy granulations, and edges of bone appear healthy. Entire cortical portion of tip of mastoid process cut away; no pus found. Entrance to antrum widened in a backward direction. Wound thoroughly irrigated with a strong (one-per-cent) bichloride solution, and afterward powdered iodoform applied. Drainage-tube reinserted and edges of wound carefully stitched together. Iodoform gauze dressings.

"June 20th, 1890.—Subperiosteal abscess behind the ear, close to the lobule. Incision carried through old fistula, and white, creamy pus evacuated. The old cavity in the bone was found to be filled with masses of granulation-tissue bathed in pus. These were thoroughly removed with a sharp spoon. While the scraping was in progress a bleeding occurred from the upper part of the wound. It was not copious, but the blood was noticeably dark-colored. A probe introduced at this point was easily carried a distance of two centimetres (three-fourths of an inch) downward, in the direction of the tip of the mastoid process; while in a backward direction it was carried a distance of three or four centimetres (into the pneumatic spaces of the occipital bone?). The first of these two channels was con-

verted by chiselling into a trough; the second one was not disturbed. No sequestrum found. Bleeding checked by a tampon of iodoform gauze; it did not recur after the removal of the latter. Powdered iodoform and usual gauze dressings.

"September 25th, 1890.—Granulations in excavation scraped out with a sharp spoon; neighboring soft parts cauterized with a Paquelin cautery. Wound dressed with boric-acid ointment.

"October 27th, 1890.—Fever having returned and another abscess having formed in the region of the original wound, injections with Koch's lymph were begun. The dilution used was made by adding ninety-nine grams of distilled water to one gram of the lymph; and from this one-per-cent dilution, 0.7 gram (containing therefore 0.007 gram of the lymph) was used in a single injection. Previous to each injection the dilution was sterilized by boiling. The injections were repeated at intervals of eight days. A feverish reaction took place after very small doses (five milligrams), and yet no change was observed thereafter in the aspect of the fistulous opening."

Early in the following December, the parents being obliged to return to New York, the patient was dismissed with a letter from Professor Schwartze to one of his former pupils in this city. The following extracts have been made from this letter: "The patient, whom I have referred to you for further treatment, has been under our care for a long time and has had everything done for her that we could possibly do, and yet she leaves here uncured. It is my conviction that she has tuberculosis, and also that the disease of the cranial bones is of a tuberculous nature. The ear disease, it is true, was originally the direct result of scarlet fever. . . . Furthermore, no bacilli have as yet been demonstrated to be present in any of the bone lesions, but only giant cells, which no longer are considered peculiar to tuberculosis. There is dulness, however, at the top of one lung. The discharge from the ear ceased several months ago."

When I saw the child on January 3d, 1891, there was a deep, open granulating pit behind the right ear; and still farther back, there was a smaller excavation. Between and around these the skin was puffed up, œdematous, and slightly red, but not specially tender. Patient carried her head with a decided inclination toward the right side, and she cried out whenever any attempt was made to turn it toward the left shoulder. The introduction of a probe into both openings simply revealed the fact that there were pathways leading some distance from each of them, in different directions. No exposed or roughened bone encountered at any point. Body-temperature (under the tongue), 101° F.

In view of the past history of the case I advised against active surgical interference, unless circumstances should arise which might render such interference necessary. Occasional applications of heat to the painful side of the head, small doses of morphine to be administered internally whenever the pain was specially severe, and calomel (gr. $\frac{1}{2}$) to be given every evening for a few days in succession—these were the only measures which seemed to be called for in the condition in which the child then was.

January 6th.—Continued high temperature (101° to 102° F.) and an increased frequency of the paroxysms of severe pain in the head.

January 17th.—Temperature a little higher (103° F.). The outside

wounds have closed, and her chief complaint is of sore throat. On examination I found a tense swelling on the right side of the fauces, back of the tonsil. An incision gave exit to a few drops of pus.

April 23d.—Only two attacks of severe pain in the head since last note. Wounds have not broken open again, and the throat has given her no further trouble; but at two different times abscesses have developed below the level of the ear, on the side of the neck. The accompanying tabular statement shows how the body temperature has been slowly diminishing:

	Weekly Average.
January 8th to January 14th	100.2° F.
January 15th to January 21st	100.0
January 22d to January 28th	101.2
January 28th to February 3d	99.7
Average for four weeks =	100° F.
Highest = 104° F.; lowest = 98.4° F.	

February 4th to February 10th	99° F.
February 11th to February 17th	100
February 18th to February 24th	100
February 25th to March 3d	99.3
Average for four weeks =	99.6° F.
Highest = 101.8° F.; lowest = 97.6° F.	

	Weekly Average.
March 4th to March 10th	99.6° F.
March 11th to March 17th	99.6
March 18th to March 24th	99.6
March 25th to March 31st	99.2
Average for four weeks =	99.7° F.
Highest = 102° F.; lowest = 97.8° F.	

April 1st to April 7th	99° F.
April 8th to April 14th	99.3
April 15th to April 22d	99.7
Average for three weeks =	99.3° F.
Highest = 101° F.; lowest = 98° F.	

On the 13th of May, I expressed the opinion that the child's general condition had so far improved that another attempt might be made—and with a fair hope of success—to eradicate all remaining traces of disease in the temporal and adjacent cranial bones. The parents readily acceded to the proposition to have their child operated upon again, but they wished the operation to be performed by Professor Schwartze. Accordingly they took passage at once for Germany, and the operation was performed on May 30th, 1891. The after-treatment lasted until about October 1st, and then the patient was dismissed as apparently cured of all active disease in the vicinity of the ear. How long this apparent cure lasted, I am unable to state; nor do I know any of the details of the illness which caused her death a few months later. It seemed to be due, however, so far as I could learn, to tuberculous meningitis.

(Case of Dr. Robert Lewis, Jr.)

Case CV.—*Cholesteatomatous disease of the mastoid process and epitympanic space; tubercle bacilli in the pus of an extradural abscess; unsuccessful search for an abscess of the tempora-sphenoidal lobe; death.*

"Female, twenty-four years of age, anæmic and in very poor health. When I saw her for the first time, on December 22d, 1896, she gave me the following history: From the time she was four years of age she had had (following an attack of measles) an almost constant discharge from the left ear, at times profuse, again scanty. During the past few months the discharge has been very offensive and profuse. Three weeks ago the patient first complained of a dull aching pain in the temporal region, which has steadily grown worse, and has extended so as to involve almost the entire left side of the head. At times it has been so unbearable that her physician could only give her relief

by administering morphine. Two weeks ago a paralysis of the facial nerve occurred.

"On examining the ear I found the canal filled with a very offensive and cheesy discharge. Having cleansed the ear as thoroughly as possible, I found the inner third filled with a polypus; this I removed under cocaine anæsthesia. I found no trace of the membrana tympani or of the ossicles. Dead bone was found on probing toward the antrum and in the epitympanic space.

"I strongly advised operative interference, but the patient would not submit; she was accordingly made as comfortable as possible with anodynes.

"On the evening of January 3d, 1897, I was called to see her, and found her very weak and suffering intensely. I again advised an operation as the only possible relief. The next day the patient gave her consent. I opened the mastoid in the usual way, and after removing the cortex I encountered very offensive cheesy masses extending into the antrum and epitympanic space. I removed all suspicious bone down to the tip of the mastoid process and as far as to the wall of the sigmoid sinus. I also removed the upper posterior wall of the external auditory canal and scraped the granulations from the middle ear. Subsequent exploration with a probe revealed the existence of an opening in the tympanic roof, and through this the instrument was passed a distance of over an inch into the middle cerebral fossa. I extended my original incision vertically upward from the external auditory canal, and with a half-inch trephine (its centre pin being placed about one inch above the middle of the external auditory canal) I removed a button of bone. Then with a rongeur forceps I extended this opening in the bone downward and backward, connecting it with the opening already made in the cortex of the mastoid process, and removing a portion of the tympanic roof in the course of this procedure. By this means I obtained free access to the superior surface of the petrous portion of the temporal bone. On lifting up the dura I found an extradural abscess, of a very cheesy consistency, lying upon the superior surface of the petrous portion of the temporal bone and close to its posterior border. [An examination, on the next day, of a portion of the contents of this abscess by Dr. J. Ewing showed numerous tubercle bacilli.] I scraped the abscess-wall thoroughly, and finding no further sinuses, and the dura being non-inflamed and firm, although thickened, I dressed the wound, using no sutures, but left it open.

"The next day the patient was free from pain and felt comfortable. Forty-eight hours later, a tendency to drowsiness was manifest; it was necessary to frequently awaken her to have her partake of any nourishment or to obtain an answer to a question. The drowsiness rapidly increased, so that on the third day following the operation I decided to search for a possible brain abscess. The body-temperature at the time was 100.8° F. At five in the afternoon of January 7th, I again had the patient placed on the operating table. We decided to use ether as preferable to chloroform. The dressings had been removed, and I was about to further explore the wound, which was clean and healthy, when the patient stopped breathing. The head was lowered at once, and artificial respiration was employed. In a few minutes the patient gave a sigh and respired, but only this one voluntary effort was made. Strychnine in combination with atropine was administered hypodermatically, and oxygen

inhalations were also employed. The faradic current was applied over the pneumogastric nerve, but the moment artificial respiration was discontinued, the patient became more and more cyanotic, and the heart-beat more and more feeble. The cyanosis would immediately disappear and the heart-beats grow strong as soon as artificial respiration was resumed. This was continued for about two hours without a change.

"The fact that the pupils were widely dilated made it evident that a source of increased intracranial pressure existed, and accordingly I concluded that no harm would result from an exploration of the brain, and possibly I might succeed by this means in reaching the source in question. I therefore introduced an aspirating needle in various directions, but without striking any pus. I did remove some fluid from the lateral ventricles, and this was followed by a contraction of the patient's pupils to normal proportions, and also by spontaneous breathing, which lasted, however, only for about four minutes. The rate of these voluntary respirations was about five per minute; then the breathing again ceased, and we were obliged to resume artificial respiration.

"I was inclined to explore the cerebellum, but, as this would make necessary further incisions and trephining, I desisted. About 10:15 P.M. her heart commenced to grow weak, and in another fifteen minutes it had ceased to beat. Unfortunately, an autopsy was not allowed."

TREATMENT.

In a previous chapter I have described the various steps which it is necessary to take in performing an operation upon the mastoid process. In a case of suspected brain abscess (of otitic origin) these steps must always precede those which are directed specifically to the task of locating and evacuating the abscess, and consequently it is not necessary to go over this same ground a second time.

Let us suppose, therefore, that the case before us is one in which the symptomatology points, as we believe, to the existence of an abscess in the temporo-sphenoidal lobe. In such a case we should commence our search in that part of the skull where the pathway of infection is most likely to be located—*i.e.*, in the tegmen antri et tympani. If the rule which I have recommended (p. 440) has been followed, a small area of the dura mater will already have been exposed to view in close proximity to the tegmen antri. But if this has not been done, the chisel should be applied to the skull just above the antrum (*i.e.*, to the rough margin left by the previous work of excavation), and comparatively thin shavings of bone should be removed, one after another, until the dura shall have been reached and shall have been exposed to view over an area about the size of a silver five-cent piece. Then, after the dura mater—for a short

distance from the margin of the opening—has been separated from the inner plate of the skull by a special periosteum elevator (with small, rather thin, and nicely rounded edges), one lip of the rongeur forceps should be introduced between the dura and the bone, and the latter should be cut away, bit by bit, until the larger part of the tegmen and—higher up—a good deal of the squamous portion of the temporal bone shall have been removed; care being taken, as the work proceeds, to separate the dura from the bone in advance of the work with the rongeur. If, upon the removal of the tegmen, we find unmistakable evidences of the involvement of the adjacent brain-tissue (such, for example, as a fistulous opening in the dura), we may proceed at once to enlarge the opening in the skull (upward and toward the sides) to its full required size, viz., that of a silver half-dollar. But if these external evidences are lacking, our best course will be to make the exploratory punctures while the area of exposed dura is still comparatively small—say about as large as a silver quarter of a dollar.

As soon as we have decided to still further enlarge the opening in the skull, it will be found necessary, in order to gain the required amount of space, to make a new incision (*b f*, in Fig. 115) through the skin and underlying parts, at right angles to the horizontal part of the usual mastoid incision, and along a vertical line which, if extended downward, would run through the tragus.

For exploration purposes a small-sized cannula and trocar or an aspirator needle (Fig. 123) may be employed. Some surgeons,

Fig. 123.—Aspirator Needle, so constructed that a piece of rubber tubing may be attached at its base. A short cylindrical piece of glass is let into this rubber tube, close to the point where it is slipped over the shoulder of the aspirator needle, thus permitting the operator to discover promptly the presence of any pus which may find its way through this channel. (Full size.)

I find, use by preference a simple scalpel of long and slender shape. If no pus be found, after the cannula and trocar have been pushed into the brain, a distance of from half an inch to an inch in various directions,[1] there will be no necessity for enlarging the opening in the bone in an upward direction.

Jansen advises that in every case in which the exposed dura

[1] In one case reported, six separate punctures, and in another nine, were made in different directions, into the substance of the temporo-sphenoidal lobe before the abscess was discovered. In still another case the cannula was pushed far enough inward to tap the contents of the lateral ventricle.

mater shows evidences of participating in the inflammation, this membrane be first incised, in order that the aspirator needle may be plunged directly into the cortical substance of the brain without first penetrating the dura mater. In this way the danger of transporting infection from the latter membrane to a (possibly) normal brain-tissue may, he believes, be avoided. On the other hand, he thinks that when the dura mater presents a fairly normal appearance, it is safe to pass the needle directly through it into the brain-substance, and not first make an opening in the membrane with a different instrument.

When the existence of an abscess in the temporo-sphenoidal lobe has been demonstrated and its location has been ascertained, then the opening in the bone should be enlarged and a V- or U-shaped incision should be made in the dura. If any of the divided dural vessels bleed sufficiently to cause annoyance, they should be tied. Then with the scalpel a free incision should be made through the intervening cerebral cortex into the abscess cavity. Koerner mentions one inch and a half as the maximum depth to which the knife should be introduced. This remark has reference as well to the cerebellum as to the temporo-sphenoidal lobe of the cerebrum. In the former locality, Koerner says, abscesses are never found at a greater depth than an inch and a half from the outer surface; and in the latter region a deeper incision would be likely to enter the lateral ventricle. For enlarging the cerebral incision a pair of dressing forceps may be employed. This instrument is to be introduced with the blades closed, and then the wound is to be enlarged by afterward opening the blades. Macewen speaks of this part of the operation in the following terms: "Along with the pus, molecular débris and minute sloughs of brain-tissue may be extruded through the cannula, but the larger sloughs, which are so frequently present in brain abscess, cannot escape in this way; they require a large opening for their removal. For this purpose, a quantity of brain-tissue, existing between the abscess and the surface of the brain, may require removal, or the peripheral brain-tissue may be turned aside. While the cannula is retained in the abscess cavity as a guide, the cerebral tissue may be removed by means of a Volkmann's spoon, or it may preferably be turned aside by introducing a pair of dressing forceps closed and opening them *in situ*. Frequently, when the forceps have thus been expanded, one or more of the sloughs flow between their blades and can at once be removed. Once the opening in the cerebral tissue has

been sufficient, the sloughs are often extruded by the intracranial pressure, and are carried slowly to the surface of the brain. If the sloughs be too large to be thus extruded, they may be gently detached from the abscess wall, and assisted out by the forceps and the sharp spoon, it being necessary to discriminate carefully between the slough and the healthy brain-tissue. It is of importance to remove these sloughs thoroughly, as if they remain they are apt to set up fresh irritation and abscess in their periphery by the infective matter which impregnates them, and which is contained in their interstices. The retention of such sloughs is one of the most fruitful sources of reproduction of abscess after evacuating the primary one, and is also a cause of delayed healing."

Cautious exploration of the abscess cavity with the finger is spoken of by several authorities as a permissible thing. According to Koerner no operator has thus far attempted to remove the lining membrane of one of these brain abscesses.

The final step in the operation is the washing out of the abscess cavity with a warm antiseptic fluid (Schwartze uses a bichloride solution, 1 to 10,000; Macewen, a weak solution of carbolic acid, 1 to 100). In carrying out this operation great care must be exercised in two respects: in the first place, a comparatively gentle current must be employed, especially in those cases in which the abscess has no lining membrane; and then, in the next place, a large outlet must be provided, in order that the injected fluid shall at no moment be under any appreciable pressure. When the fluid which escapes from the abscess cavity, during this process of irrigation, becomes quite clear, we may assume that any further washing is unnecessary. The patient's head should then be turned over far enough to permit most of the injected fluid to run out. After which the walls of the cavity should be dusted with a mixture of iodoform and boric acid (1 to 4, as suggested by Macewen); the external exposed parts of the brain, dura mater and bone, and the surface of the wound generally, should be carefully mopped with a 1 to 1,000 bichloride solution; a loosely fitting tent of iodoform gauze should be introduced into the external opening of the abscess cavity; and, finally, over all should be placed the usual dressings.

The subsequent dressing of the wound should be managed upon the same principles as those which guide us in the management of the wound left by a Schwartze operation. If we find, at the end of twenty-four hours, that there has only been the usual serous dis-

charge, and that no bad odor can be detected in the vicinity of the tent, we may leave it undisturbed and simply apply fresh outside dressings. The subsequent course of the case will aid us in determining how often, if at all, the wound in the brain should be washed out with a bichloride solution. If a discharge shows itself, it will be necessary to irrigate the cavity and to renew the dressings as often as once in twenty-four hours.

When the abscess is located in the cerebellum, both the exploratory punctures and the drainage opening should be made by preference at a point behind the sigmoid sinus and below the tentorium cerebelli—that is, in the angle made by the sigmoid sinus in front and the lateral sinus above. To reach this region, the opening which has already been made in the mastoid portion of the temporal bone is simply to be extended backward and perhaps a little upward until the triangular space just mentioned shall have been freely exposed to view. The rongeur forceps, provided it be sufficiently large and strong, will accomplish this work in a safe and fairly rapid manner.

The time required for the complete healing of the wound, after the operation for emptying a brain abscess, varies, in the great majority of cases, from three to seven weeks (Koerner).

Hernia cerebri sometimes develops soon after the operation. Thus, for example, in Knapp's case[1] the brain-substance began to protrude through the opening in the skull on the third day, and the hernial mass rapidly increased in size until it was as large as a goose's egg. It retained these dimensions for over six weeks, and then began gradually to diminish in size. At the end of twelve weeks the patient was well enough to be discharged from the hospital. In the case reported by Schwartze[2] the protrusion of brain-tissue began to show itself already on the day following the operation. On the sixth day a little of the protruding brain-substance was removed. Then again, on the seventeenth day it was found necessary to cut away a small and sharply defined gangrenous portion of the cerebral hernia. On the twenty-sixth day the patient was well enough to leave the hospital.

Koerner remarks that the existence of a hernia cerebri does not prove, as is claimed by some authors, that a second abscess or some other pathological process of such a nature as may cause increased intracranial pressure, is present.

[1] Archives of Otology, vol. xxiii., No. 3, 1894.
[2] Archiv für Ohrenheilkunde, Bd. 38, 1895.

CHAPTER XXIII.

FUNCTIONAL AND ORGANIC DISEASES OF THE AUDITORY NERVE.

PATHOLOGY.

Notwithstanding all the efforts which have been made by otologists during the last three decades to furnish methods of diagnosis whereby we may distinguish, with some degree of accuracy, between the different functional and organic diseases of the auditory nerve, we are to-day still unprovided with these means, and are therefore obliged, while waiting for more precise knowledge, to speak in a reserved and uncertain manner about the different pathological alterations which, as we believe, may affect this nerve or the parts adjacent to it.

Thanks to the painstaking investigations of Moos and other German physicians, it is now a demonstrated fact that in measles, scarlet fever, and diphtheria—and possibly in other diseases—the invasion of the middle ear by the streptococcus and other varieties of destructive micro-organisms may be followed by a similar invasion of the cavities of the labyrinth. When, therefore, in the course of any of the diseases named, the suppurative inflammation of the middle ear terminates in the complete annihilation of the hearing of the affected ear, we are perfectly warranted in ascribing this loss of function to the destructive action of bacteria which have wandered from the tympanum into the whorls of the cochlea. I am not aware that the same demonstration has, up to the present time, been furnished for the disease known as epidemic cerebro-spinal meningitis; and yet there can be no reasonable doubt that the total loss of hearing, which is so common an event in this disease, is also to be ascribed to an invasion of the labyrinth by bacteria.[1] But this latter invasion differs considerably, both in character and in results, from that which occurs in the course of scarlet fever. Whereas in

[1] Some time after this had been written, I discovered a statement, in vol. ii. of Bollinger's recently published "Essentials of Pathological Anatomy," to the effect that the bacteria peculiar to epidemic cerebro-spinal meningitis had been discovered.

the latter disease the microbes enter the labyrinth from the tympanum by way (probably) of the secondary tympanic membrane and the cochlea, and in the main confine their action to a destruction of the nervous apparatus of hearing, in epidemic cerebro-spinal meningitis they enter this cavity from the direction of the brain; their actual pathways being, in all probability, the aquæductus vestibuli and the aquæductus cochleæ. Along these routes the bacteria would find easy access both to the ampullæ of the semicircular canals and to the scalæ of the cochlea; and consequently we should expect from such an invasion not only a destruction of the hearing, but also a marked disturbance of the sense of equilibrium—for it is in the ampullæ that the centres which govern this special sense are believed to be located. As a matter of fact, these are precisely the conditions which are established in a goodly percentage of the cases of this epidemic disease; a staggering or an uncertain gait being a prominent symptom for weeks after the patient has in other respects recovered health.[1]

There are other infectious diseases in which the hearing—of one ear only, as a rule—is suddenly or rapidly destroyed, and yet the closest scrutiny fails to furnish any evidence which would warrant

[1] The reading of such reports as the following—made by two perfectly competent and trustworthy observers—must necessarily convey a sense of timidity and doubt to the mind of any author who ventures to expound the pathology of labyrinthine diseases:

Moos (Archives of Ophthalmology and Otology, vol. iii., No. 2, p. 177) reports a case of cerebro-spinal meningitis in which decided, if not total deafness was observed two days before death. At the autopsy, it was found that the tympanic mucous membrane, on both sides, was decidedly hyperæmic and swollen. There were also very decided evidences of a general meningitis. But the auditory nerve, in the porus acusticus internus, was quite free from evidences of inflammation, on both sides. Both labyrinths were also examined and found normal in every respect.

Klebs also (Virchow's Archiv, vol. xxxiv., p. 356 *et seq.*) narrates the history of a somewhat similar case of meningitis. The patient, a subordinate officer in the army, was taken ill on the 10th of April, and died on the 7th of May. No deafness was noticed when he was first taken ill. Soon afterward, however, he gradually became totally deaf. At the post-mortem examination the auditory nerves (examined microscopically) were found to be perfectly normal. The terminal apparatus of the cochlea was also found to be normal. The middle ear, however, was found (on both sides) to be the seat of extensive inflammatory changes. Strong bands of connective tissue, well supplied with blood-vessels, traversed the cavity in all directions, and must of necessity have greatly impeded the movements of the ossicles, to which they were adherent at numerous points.

us in assuming that the destroying agents have reached the auditory nerve by way of the tympanic cavity. Mumps or epidemic parotitis is one of these diseases, and syphilis is another. As regards both of them, we are forced to draw the conclusion that the specific micro-organisms of the disease are conveyed to the nerve by the help of the blood-stream, but we are not yet able to state in what particular part of this nerve—from its origin in the medulla oblongata to its distribution among the organs of Corti—they inflict the damage. In the case of mumps, the harm seems to be effected rapidly —in the course of one or two days—and to be irremediable; whereas in syphilis the trouble advances much more slowly, and in not a few of the cases treatment has been found to be effective in restoring the hearing, even after it has seemingly been completely destroyed.

Post-mortem examinations have revealed the fact that a hemorrhage may occur in any part of the labyrinth, and clinical observation occasionally brings us in contact with cases in which we can scarcely entertain a doubt that the sudden and permanent loss of the hearing in one ear is due to such a labyrinthine effusion of blood. While a certain number of these hemorrhages may owe their origin to an embolism of some arteriole, others may fairly be attributed to the giving way of one of the venous labyrinthine channels under too great a strain.

The term "*Ménière's disease*" is properly applicable to all those cases of apoplectiform deafness (not growing out of such diseases as the mumps, epidemic cerebro-spinal meningitis, etc.), in which the symptoms warrant us in entertaining the belief that a hemorrhage has taken place into the labyrinth; and in which, furthermore, an examination with the speculum and reflected light reveals the fact that no inflammation is going on in the middle ear. Ménière was fortunate enough, in his famous case, to obtain a post-mortem examination a few days after the occurrence of the characteristic symptoms, and he found the semicircular canals filled with clotted blood, which encroached to some extent upon the cavity of the vestibule. It seems proper, therefore, not to apply the term "Ménière's disease" to those cases in which, although the symptoms may be nearly or quite the same, there is no warrant for believing that a blood-vessel in the labyrinth has actually ruptured. In this category belong the cases in which, under reflex influences, the labyrinthine vessels are for a certain length of time subjected to marked dilatation (vasomotor paresis).

Still other pathological changes, of a more subtle character, must be assumed to take place in the cochlea if we are to explain plausibly—although perhaps not to our entire satisfaction—those cases in which the range of hearing becomes more and more contracted with the progress of time. The same remark also applies to those rare cases of *diplacusis* or *double hearing*—cases which very probably seem more rare than they really are because only those sufferers who happen to be musicians are able to give an intelligible account of their symptoms.

Furthermore, there is a class of cases in which both of the labyrinthine functions—that of hearing and that of maintaining the equilibrium—seem to suffer for a short time through reflex vasomotor influences which take their start in the stomach or in some other part of the gastro-intestinal domain. So far as one can judge, in the present imperfect condition of our knowledge, the underlying pathological lesions in the labyrinth consist simply of an undue dilatation (vasomotor paresis) of the blood-vessels, together with an escape of a larger or smaller number of lymphoid cells. These pathological conditions would cause an increase in the intralabyrinthine pressure, and this in turn would produce the tinnitus and vertigo which are the characteristic features of these attacks of gastro-intestinal origin. The same effects, it is possible, may be produced by the very opposite conditions, viz., those of an acute anæmia due to spasmodic contraction of the muscular elements of the arterioles; and yet, on the whole, I am disposed to believe that the other hypothesis is the more likely one of the two to be correct.

That form of deafness which is observed so frequently among boiler-makers, and perhaps to an even greater extent among those who work in stamp-mills in the mining regions, is commonly included, in the text-books, among the labyrinthine affections. The frequent and violent jarring of the membranous lamina spiralis with its superposed organs of Corti, it is maintained, gradually robs this delicate structure of the power of performing its functions. As I have already expressed my views in regard to this question in the chapter on chronic catarrhal inflammation of the middle ear (see pages 242 and 243), I will say nothing further on the subject in this place.

Voltolini[1] maintains that there is such a thing as a primary acute inflammation of the labyrinth, and he narrates the histories of a

[1] Monatsschrift für Ohrenheilkunde, October, 1867, and June, 1868.

few such cases. Schwartze[1] has also published the details of a case in which the symptoms seemed to point to an acute primary inflammation of the labyrinth. An examination revealed the existence of a subacute inflammation of the tympanum without exudation. Subsequently meningitis developed and the patient died. At the autopsy no other cause for the general meningitis was found beyond a purulent inflammation of the labyrinth. Schwartze's article was published in 1878, when our knowledge of bacteriology was very scanty. It is more than likely that he himself would to-day look upon this case as one in which an infection had spread to the labyrinth from a moderately inflamed tympanum, just as we occasionally see it spread to the mastoid region and there set up an inflammation far more serious than the primary one in the tympanum.

Mention is made, in some of the books, of *leukæmic disease of the labyrinth*. Nothing of the kind has ever come under my personal observation; and on reading over the brief account of it given in Schwartze's "Handbuch der Ohrenheilkunde," by Professor Gradenigo, I must confess that I prefer to wait for further light on the subject before accepting these labyrinthine disturbances as something distinctively associated with leukæmia. The impression which I gain from this article in the Handbuch is, that Gradenigo himself is disposed to entertain doubts about the leukæmic nature of the labyrinthine alterations observed.

In 1880 the late Dr. Alfred North, of Waterbury, Conn., published a report[2] of two cases of *poisoning by the oil of chenopodium*. In the case of the older of the two patients—a boy twelve years of age—it was estimated that he must have taken, in a single dose, fully one dram of the remedy. On the following day he complained of severe frontal headache and of a loud ringing in the ears. His gait was extremely unsteady, he was unable to retain any food in his stomach, and he was very deaf. On the fourth day it became evident that the boy's mind was affected. By that time also he showed signs of marked drowsiness, which steadily increased until, on the following day, he became entirely unconscious. Temperature, 100° F.; pulse, 58, weak and compressible; respirations normal. Bromide of potassium, in fifteen-grain doses, was administered every three hours; and slowly, in the course of the next ten days, the boy returned to a fair state of health. The frontal headache, however, persisted for a long time afterward, and he never

[1] Archiv für Ohrenheilkunde, Bd. 13, p. 107.

[2] American Journal of Otology, vol. ii., p. 197.

entirely recovered his hearing. In the latter part of 1883 I examined the patient, at the request of Dr. North, but found nothing worthy of note in the condition of the middle ears. He was then able to distinguish correctly words spoken in an ordinary tone of voice at a distance of about three feet from each ear.

All the symptoms in this very rare case point to a marked vasomotor paresis not only of the labyrinthine blood-vessels, but also of all those contained within the cranial cavity.

Finally, in a certain proportion of the cases of excessive hypertrophy of the lymphoid tissue in the vault of the pharynx, in quite young children, the impairment of the hearing is so profound that we are forced—in the absence of adequately serious lesions outside of that complex system of cavities—to assume that the cause of the deafness is located within the labyrinth; and when we come to consider what is likely to be the nature of this labyrinthine lesion, we find many reasons for believing that a dilated condition of the blood-vessels, and especially of the veins, is the real underlying cause of the deafness. In the first place, the picture presented by the tympanic membrane—which is not only markedly depressed, but also of a deep red or purplish color—warrants the statement that in these cases there exists a very decided degree of interference with the flow of blood through the veins which follow the course of the Eustachian tube. I do not know how large a part of the return current of blood from the labyrinth passes through these channels, but it is reasonably certain that an important fraction of the whole labyrinthine supply of venous blood finds an escape in this direction. In the next place, the almost complete restoration of the hearing, which occurs in some of these cases, almost precludes the possibility of any other cause for the profound deafness than that of labyrinthine hyperæmia. It is not unlikely that the abnormally depressed position of the foot-plate of the stapes also contributes its share toward the impairment of the hearing, but I question whether any considerable portion of this impairment can be rightly attributed to this pathological factor alone, except possibly in cases of long standing.[1] In the latter it is not unlikely that serious damage may result from the prolonged pressure upon the structures of the lamina spiralis membranacea.

[1] Parents are often remarkably slow in discovering the fact that their child is decidedly or completely deaf, and consequently months or even years may elapse before the primary cause is discovered and removed.

ILLUSTRATIVE CASES.

Labyrinthine Disease during Pregnancy.

Case CVI.—*Apoplectiform attack, without vertigo, but with complete loss of hearing in one ear, occurring a few days before the patient gave birth to a child; gradual recovery of a large part of the hearing-power, without treatment; a slight hemorrhage into the cochlea the probable cause of the symptoms.*

Female, twenty-four years of age and in good health. October 31st, 1882. History: Suddenly, during the night—about five weeks previously, and a few days before the birth of her child—she was awakened by a loud ringing and roaring sound in her right ear. It was not associated with pain, and she was not suffering at the time with a cold in the head. On the following day she discovered that she was completely deaf in the right ear. Her regular medical attendant made an examination with the speculum and reflected light, and found the tympanic membrane in a perfectly normal condition. There was no nausea or vertigo at the time of the attack or at any time afterward. The tinnitus slowly diminished, and she soon discovered that her hearing was gradually returning. Present condition: The membrana tympani is normal; the pharyngeal mucous membrane is free from congestion. The ticking of my watch is heard only when it is pressed against the right auricle. Whispered words are heard correctly at a distance of eighteen inches; those spoken in an ordinary tone of voice are heard at a distance of several feet.

Comments.—In addition to the present case I have seen two or three others in which marked or complete deafness has developed during advanced pregnancy and, so far as could be seen, independently of any middle-ear disease. Politzer speaks of the predisposition of pregnant women to various ear disorders as if it were a well-known fact, but he makes no attempt to explain why this should be the case. Is it possible that the nutrition of the delicate blood-vessels of the labyrinth is less perfect at this period than at other times, and that consequently they are then less able to withstand some unusual strain?

In the case which I have just narrated, all the facts harmonize best with the assumption that a blood-vessel must have ruptured; but it is by no means clear where we should locate the ruptured vessel—whether in the scalæ of the cochlea, or in some part of the auditory nerve outside the scalæ, or finally in the auditory nerve centre in the brain. The more plausible assumption, as it appears to me, is that which locates the rupture in some part of the cochlear channels.

Rupture of Labyrinthine Blood-Vessel under Too Great a Strain.

Case CVII.—*Apoplectiform deafness, due, probably, to excessive strain upon the veins of the cochlea and final rupture of one of them; no vertigo or nausea; prolonged administration of large and increasing doses of sodium iodide, but with no beneficial effects.*

Musician (player of the bass tuba), fifty-two years of age, rather corpulent, but otherwise in vigorous health. November 2d, 1883. Gradual but complete loss of the hearing-power of the left ear; the impairment being first discovered in 1877. Six days ago he began to experience some difficulty with his right ear, and in the course of forty-eight hours he lost the hearing of this ear completely. No other symptoms—such as vertigo, nausea, etc.—were associated with this loss. No history of syphilis. Patient is himself disposed to believe that the violent blowing required in playing the bass tuba has something to do with his misfortune. Examination of the left ear reveals simply a little thickening of the membrana tympani. I applied three leeches in front of the right tragus, and allowed the after-bleeding to continue unchecked; and at the same time I applied as large a blister as possible to the skin of the right mastoid region.

On the 7th of November, the patient began taking, three times daily, ten drops of a saturated solution of sodium iodide. Every other day he increased the dose by five drops. By the end of December he had reached the point where he was taking habitually every day, and without any discomfort, three hundred and sixty drops of this saturated solution. Under this treatment no improvement whatever in the hearing occurred; and I accordingly advised the patient to abandon it.

Labyrinthine Disease as a Sequel to the Grippe.

Case CVIII.—*Apoplectiform deafness, with marked vertigo, following an attack of the grippe; permanent loss of the hearing in the affected ear; both the cochlea and the semicircular canals involved; an embolism the possible cause.*

Female, forty years of age, and previously in good health, had an attack of the grippe during the spring of 1891. During convalescence she developed some chest trouble—exactly what, she was unable to say. While this complication was in progress, her left ear began to roar, and she soon discovered that she had lost the power of hearing with this ear. There were several kinds of noises in the affected ear; and besides, there were other distressing symptoms, which became much worse whenever she attempted to move—viz., vertigo, and very marked faintness. These symptoms gradually diminished, but did not entirely disappear for a period of about six weeks. Present condition: Patient can hear my voice in the left ear, but she is unable to distinguish words; the ticking of my watch cannot be heard in this ear; the sound of a vibrating tuning-fork—no matter on what part of the head it may be placed—is heard only in the right ear; the membrana tympani presents an essentially normal appearance.

Comments.—The development of the ear symptoms during the active progress of some chest complication (pneumonia? endocarditis?) naturally suggests the idea of an embolus; and if such indeed were the nature of the lesion which caused the deafness and the vertigo, we are warranted in making the further supposition that this embolus became lodged in the internal auditory artery just before it subdivides to send one branch to the vestibule and semicircular canals, and another to the structures within the cochlea.

Labyrinthine Disease Developing in the Course of Mumps.

Case CIX.—*Loud noises in the head and complete loss of hearing in one ear on the third or fourth day of an attack of mumps; development of nausea and vertigo on the fifteenth day, and slow increase of the same during the following forty-eight hours; no return of the hearing; the causative lesions were probably two successive intralabyrinthine hemorrhages—the first one in the cochlea, and the second one at some point where pressure would be exerted upon the ampullar branches of the auditory nerve.*

The patient, a man forty-one years of age and in good health, contracted the mumps on or about the first day of June, 1881. The swelling was noticeably greater on the left than on the right side of the face. The motions of the jaw were decidedly painful. On the third or fourth day of the attack he discovered that he was unable to hear with his left ear. He also suffered at the same time with a loud roaring sound in the head. In the course of three or four days this noise, which had hitherto been general throughout the head, gradually became localized in the left ear. On or about the fifteenth day the patient experienced nausea and dizziness, and found considerable difficulty in maintaining his balance. These new symptoms grew more marked during the following forty-eight hours, and then began slowly to diminish in intensity. No very marked change for the better took place, however, until after four leeches had been applied behind and in front of the affected ear. This was done on the 20th or 21st of June, by the advice of the physician whom he first consulted. The roaring and deafness remained unaffected by the local blood-letting, but the nausea, dizziness, and difficulty in maintaining his equilibrium were at once greatly diminished by this procedure. Leeches were also applied on two subsequent occasions, each time with a certain amount of benefit to his general condition, but without affecting the damaged hearing in the slightest degree.

On the 15th of July I examined the left ear with the speculum and reflected light, but failed to find anything in the condition of the parts that might account for the deafness or other symptoms. So far as could be ascertained by means of the usual tests, the hearing-power of the left ear had been completely destroyed. The sound of the vibrating tuning-fork, when placed against the patient's teeth, was heard by him only in the right ear.

Local blood-letting, counter-irritation, etc., were all tried without any apparent benefit, and the case was dismissed as incurable.

CASE CX.—*Sudden loss of hearing and tinnitus in one ear shortly after an attack of mumps; sense of equilibrium disturbed for a period of weeks; labyrinthine lesions undoubtedly the cause of all the symptoms.*

Boy, fourteen years of age. April 30th, 1893. His mother gave the following history: About one week after he was first attacked with the mumps, he complained that his own voice resounded in a peculiar manner in his right ear. After this had lasted for only three or four hours, he noticed that the whole region about the right ear felt numb. He also felt sick at his stomach, and staggered when he attempted to walk. Then shortly afterward —exactly when, neither the boy nor his mother could say—he discovered that he had entirely lost the power of hearing in the right ear. The other symptoms distressed him for about one week, and then they all gradually passed away. The hearing, however, did not return, and a little of the dizziness still annoys him at times.

I tested the hearing of his right ear very thoroughly, and became satisfied that it had been entirely destroyed. The tones of the vibrating tuning-fork, no matter where it was placed upon the boy's skull, were promptly heard by him in the left ear. When the latter ear was closed tightly, and words were spoken in a moderately loud tone of voice close to the right ear, the boy was able to distinguish them correctly, but he said that he was conscious that they reached the good ear through the skull.

Nothing was found in the condition of the right middle ear that could explain any of the symptoms of which the patient complained.

LABYRINTHINE DISEASE RESULTING FROM EPIDEMIC CEREBRO-SPINAL MENINGITIS.

CASE CXI.—*Gradual but complete and permanent loss of hearing in both ears in the early part of an attack of epidemic cerebro-spinal meningitis; difficulty in maintaining the equilibrium persisted for many weeks; the invasion of the micro-organisms peculiar to this disease evidently extended no farther than into both labyrinths.*

The patient, a boy seven years of age, was brought to the Infirmary on the 26th of June, 1872. His father stated that ten weeks previously his son had been taken ill with severe headache, fever, pain in the back, and bending backward of the head and shoulders. About the fourth day of the attack it was noticed that the boy was decidedly deaf, and twenty-four hours later he appeared to have lost the sense of hearing entirely. There had been no discharge from either ear, and the only complaint which the boy had made with reference to his ears was, that he constantly heard noises in them of the most varied character. This symptom still persisted at the time when I saw him. During convalescence, whenever the patient attempted to walk without assistance, he experienced great difficulty in maintaining his equilibrium. Although this difficulty had afterward greatly diminished, it was still sufficiently marked, when the boy came to the Infirmary, to attract my attention. On examination, I found both external and middle ears in a comparatively healthy state. The deafness was absolute.

Comments.—In this case it is reasonably clear that the original disease partook of the nature of a meningitis, and that the inflammation at a certain stage spread to both labyrinths. If the inflammation had not involved these cavities, but had simply damaged the main trunks of the auditory nerves, it is difficult to understand why the trunks of the facials, which are so intimately related to these nerves, should have escaped. Equally great are the difficulties that stand in the way of the assumption that the auditory centres in the medulla oblongata are the parts involved. Weber-Liel has shown,[1] by direct experimentation, that a free communication exists between the endolymphatic and perilymphatic spaces of the labyrinth and the extra-labyrinthine intracranial spaces, and it is probably by these routes—viz., by way of the aquæductus vestibuli and the aquæductus cochleæ—that the inflammation spreads from the meninges to the labyrinth.

Among the epidemic infectious diseases, mumps, influenza, and epidemic cerebro-spinal meningitis doubtless furnish the major part of the labyrinthine affections which come under our observation; and yet scarlet fever, typhoid fever, and measles also furnish a fair proportion of cases.

Labyrinthine Disease of Reflex Origin.

Case CXII.—*Apoplectiform attack, characterized by only slight but permanent impairment of the hearing in one ear; attack ushered in by vertigo and tinnitus; previous habitual stomach indigestion; the causative lesion involved both the cochlear and the ampullar branches of the auditory nerve.*

The patient, a clerk, about forty years of age, and a decided sufferer from stomach indigestion (nausea, heartburn, gaseous eructations, etc.), was taken suddenly ill, about the 15th of August, 1880, with marked dizziness and noises in the left ear. When he attempted to walk, he found that he could do so only with great difficulty, as he was unable to keep his balance. On the second or third day he discovered that his sense of hearing in the left ear was not so acute as before the attack.

On the 30th of August he consulted his regular medical adviser, and was by him sent to me for a report on the condition of his ear. Although his gait had, he thought, steadily improved, it was still at that time noticeably unsteady. He not only used a cane, but in walking out-of-doors he seemed to avail himself of the assistance of his wife. He was barely able to distinguish the ticking of my watch, when I pressed it firmly against the left mastoid process. With the right ear closed, he distinguished words spoken in an ordinary tone of voice at a distance of several feet from the left ear. The tuning-fork was heard best (by bone conduction) in the right ear. The drum-

[1] Virchow's Archiv, Bd. 77, 1879.

membrane showed slight evidences of a subacute catarrhal inflammation, and there was also a moderate degree of naso-pharyngeal catarrh.

CASE CXIII.—*Apoplectiform attacks which were associated with marked and long-continued vertigo, but without any disturbance of the hearing; hepatic and stomachic indigestion probably gave rise to the attacks, through a reflex mechanism; lesions of a more or less permanent character were probably produced in the semicircular canals.*

Male, thirty-nine years of age, more or less of a sufferer from indigestion, and rather unhealthy in appearance. November 2d, 1893. He states that seven months previously he had a sudden attack of vertigo which lasted about three hours. During the attack, which was associated with nausea and a distressing sense of weakness, he noticed that the vertigo presented two distinct phases: at one time everything in the room seemed to him to be whirling around from left to right, and then at another he experienced the sensation of being himself whirled rapidly through space. At no time during the attack did he lose consciousness. Two or three days after this first attack he had a second one, which lasted during the greater part of one week. He travelled for a few weeks, after he had recovered from this attack, and experienced decided benefit to his health from the trip. He did not, however, entirely recover the power to walk with comfort. The hearing, which for years previously had been defective, was not rendered worse by either of these attacks.

Present condition: Both drum-membranes are somewhat atrophied and moderately depressed, but not sufficiently so to warrant the belief that undue pressure, on the part of the stapes, upon the contents of the labyrinth, might have caused the peculiar attacks referred to above. The patient complains that in walking he is still annoyed by the sensation that the ground is about to rise up and strike him in the face.

CEREBRAL EMBOLISM SIMULATING LABYRINTHINE DISEASE.

CASE CXIV.—*Apoplectiform attack, characterized by temporary but complete loss of hearing in both ears; attack ushered in by severe pain in the head, marked vertigo, nausea, double vision, and tinnitus; probably due to cerebral embolism, in connection with valvular disease of the heart.*

The patient, a decidedly stout, full-blooded lady, about forty years of age, consulted me on the 1st of August, 1871. She stated that on the previous Christmas morning, while in the enjoyment of her usual good health, she had been suddenly seized with a severe pain in her head, accompanied by dizziness, nausea, and loud noises in both ears. She was walking about the room at the time of the attack, and was obliged to take hold of some article of furniture in order to escape from falling. The objects in the room seemed to her to be turned upside down; she also saw double. She lay down upon the bed, and soon afterward vomited. When her friends came into the room and spoke to her, she discovered that she had completely lost the sense of hearing. The nausea and vomiting ceased in the course of a few hours, and with the disappearance of these symptoms she experienced decided relief

from the pain in the head. Her hearing soon began to return, and at the end of about six days she was able to hear fairly well. The double vision lasted somewhat longer, and did not finally disappear until after the lapse of several weeks. The subjective noises, however, and a moderate degree of deafness, had continued to annoy her up to the time when I saw her. I tested the hearing and found it to be: R., $\frac{2.5}{12}$; L., $\frac{0.3}{12}$. The sound of the vibrating tuning-fork, no matter at what point it was placed on the cranium, was heard best in the right ear. Aside from the slightly opaque condition of the drum-membranes, the external and middle ears appeared to be normal. Both pupils responded to the light, but the left was fully twice as large as the right. From Dr. Carl Reincke I ascertained that the ophthalmoscopic examination had yielded only negative results. Auscultation revealed the existence of a loud systolic bellows-murmur, heard most distinctly at the base of the heart. (The patient was not seen again.)

Extra-Labyrinthine—Probably Cerebral—Hemorrhage Causing Deafness.

Case CXV.—*Apoplectiform, one-sided, incomplete deafness in a person suffering from chronic naso-pharyngeal catarrh; the underlying lesion was doubtless a small hemorrhage at some point outside of the labyrinth, but whether in the brain-substance or on its surface, is not clear.*

A school-teacher, about twenty-six years of age, and of rather florid complexion, consulted me on March 11th, 1898, for marked general impairment of the hearing. Her story was, in brief, as follows: Seven years previously she had begun to lose the hearing of the right ear, while that of the left ear remained normal, so far as she could judge, up to late last summer (1897). Then, while travelling on a railroad train, she suddenly experienced a severe pain in the left temple, together with marked impairment of the hearing in the left ear and a sense of numbness throughout the entire left side of the body (including the left half of the tongue). There was no vertigo, so far as she could remember; but at the end of about half an hour the numbness and the pain in the head gave way to nausea and vomiting, which lasted for several hours. From that day to the time when she called to consult me, the hearing in the left ear had slowly improved under naso-pharyngeal treatment. On examination, I found her hearing (both ears) so greatly impaired that I could converse with her only with considerable difficulty. When the two ears were tested separately, it was found that the hearing of the right ear was noticeably better than that of the left. Both tympanic membranes were atrophic, and the region of Shrapnell's membrane (L.) was represented by a deep pit on both sides of the neck of the malleus. There was marked hypertrophy of both middle turbinated bodies, and diffuse hyperæmia and swelling of the naso-pharyngeal mucous membrane.

Labyrinthine Disease of Unknown Origin.

Case CXVI.—*Apoplectiform attack, characterized by complete and permanent loss of hearing in one ear; severe pain in the head, vertigo, and nausea;*

two similar attacks after the lapse of five weeks; due to some lesion involving both the cochlear and the ampullar branches of the auditory nerve.

The patient, a well-to-do farmer, about sixty years of age, consulted me on the 15th of April, 1873. He gave the following history: About two months previously he was taken suddenly ill with severe pain in the head, dizziness, and nausea. The objects in the room seemed to be revolving in a circle. He lay down, and in about five minutes all the more marked symptoms, with the exception of the headache, disappeared. The attack, however left him in such a prostrated condition that he was compelled to keep his bed for about three weeks. During this period he occasionally vomited his food, and whenever he attempted to walk about the room he experienced great difficulty in maintaining his equilibrium. About five weeks after this attack he experienced two more attacks of a similar character, the interval between the two not exceeding twenty four hours. At the time when he consulted me there was complete deafness in the left ear, the sound of the tuning-fork being referred very promptly by the patient to the right ear. I was unable, however, to ascertain satisfactorily at what precise time during the previous eight weeks this loss of the hearing-power had taken place. The patient complained chiefly of a throbbing pain throughout the left side of the head. The noises in the left ear also distressed him. On examination I found both ears in a comparatively healthy state. Suction with Siegle's tympanoscope diminished the throbbing appreciably. An examination of the urine showed simply a rather low specific gravity (1004).

Dr. Brown-Séquard, to whom I referred the patient, wrote as follows: "Your patient is evidently attacked with what has been miscalled Ménière's disease (an affection which I had described in lectures and books three or four years before Ménière spoke of it). He has no organic affection of the brain so far as it is possible to say so from the fact that there are no brain-symptoms actually. I would, however, recommend the use of the two medicines for which I have given him a prescription, and I will suggest that counter-irritation of some kind be used behind each of the ears. The patient must live well, taking chiefly nourishing food, but avoiding excess as regards quantity of any kind of food. He has no need of stimulants." The prescription referred to is the following:

℞ Sodii iodidi..... ʒ iiss.
Sodæ bicarb. ..... ʒ i.
Infus. calumbæ fl..... ℥ ij.
Tinct. rhei..... ʒ ij.

M. S.—A teaspoonful and a half three times a day before meals, with a little water. (B.-S.)

Also:

℞ Strychniæ sulphatis..... gr. i.
Acid. sulph. dil..... ♏ xv.
Aquæ destillatæ..... fl. ℥ v.

M. S.—Two teaspoonfuls three times a day after meals. (B.-S.)

The plan of treatment suggested above was carried out faithfully up to the 23d of May. As the effects of the strychnine were then beginning to

show themselves (muscular pains and stiffness), the patient was advised to discontinue internal treatment. His general condition had certainly improved during the interval, but the aural symptoms had remained unchanged.

Syphilitic Labyrinthine Disease.

Case CXVII.—*Rapid loss of hearing and constant tinnitus in both ears, together with a staggering gait, due, in all probability, to the development of syphilitic gummata in both labyrinths; result of the treatment unknown.*

Male, fifty-eight years of age, and with the external appearances of fair health. February 14th, 1893. Says that following an attack of tonsillitis, during the last week of December, 1892, he became quite deaf, and found difficulty in maintaining his balance. He also suffered from constant noises in both ears. Since this attack the deafness had increased, while the difficulty in walking had remained about the same. His hearing, before the attack in question, had always been excellent. Present condition: Is unable to hear the ticking of my watch in either ear; hears correctly only words that are spoken loudly close to each ear. Both drum-membranes are somewhat depressed, but in other respects they are fairly normal. A well-marked gumma occupies the central part of the brightly red surface of each tonsil. On each tibia, just below the knee, is a painful node. Patient also complains of rheumatic pains in various parts of the body. He remembers that two or three years previously there had been a large copper-colored patch on his abdomen, but that it was no longer there at the present time. There had been no falling out of the hair, and I was unable to discover any enlargement of the lymphatic glands at the elbow, the back of the neck, etc. I suggested to his physician a prolonged course of anti-syphilitic treatment.

Case CXVIII.—*Sudden and almost complete loss of the hearing in both ears in a case of acquired syphilis; very marked improvement following the administration of large daily doses (359 grains on one occasion) of potassic iodide and the systematic employment of mercurial inunctions; the causative lesions probably involved only the cochlear branches of the auditory nerve.*

The patient, a man twenty-eight years of age and in good general health, consulted me on the 24th of March, 1877, at the request of Dr. Roosa. During January of that year he had rapidly and almost completely lost the hearing-power in both ears. At first, tinnitus, together with a little nausea and dizziness; no unsteadiness of his gait at any time; chancre eighteen months previously. No other evidence of syphilis, with the exception of an ill-defined ulcer on the right side of the tongue, near its tip. Nothing worthy of note in the condition of the middle ear. His hearing, at the present time, is so much impaired as to be of very little use to him. Anti-syphilitic treatment (by Dr. Roosa), consisting of inunctions with the oleate of mercury, and the internal administration of iodide of potassium in large doses (reaching over six drachms in a single day on one occasion), brought about, in the course of a few weeks, a very marked improvement of the hearing.[1] (Full

[1] It should be stated here that this patient had already been subjected to what might be termed an ordinary course of antisyphilitic treatment. Little

details with regard to this case will be found on p. 615 of the sixth edition of Dr. Roosa's "Treatise on the Ear.")

CASE CXIX.—*Slow but well-marked diminution of the hearing and tinnitus in one ear, together with vertigo, in a case of acquired syphilis; almost perfect recovery of the hearing under the use of potassic iodide in moderately large doses; both the ampullar and the cochlear branches of the auditory nerve were probably involved.*

Female, æt. 40, a teacher, somewhat anæmic, October 6th, 1877. Totally deaf in the right ear since childhood. Two weeks ago she began to notice slight deafness in the left ear, together with occasional pains and a sense of tightness in the ear. Left drum-membrane apparently normal. The ticking of a watch heard at a distance of four feet. Right drum-membrane very much disfigured by inflammation that occurred during childhood. Pharynx healthy. As there are no indications for treatment, she is advised to wait.

On the 23d of October she returned. The hearing-power had been steadily and even quite rapidly diminishing. Tinnitus constant. On the 12th she began to experience a sensation of dizziness, which soon became so marked that she could only walk with the assistance of a friend. No change in the condition of the drum-membrane. Treatment: Iodide of potassium in fifteen-grain doses three times a day.

October 30th.—Slight improvement in the hearing; dizziness the same. Dose of the iodide increased to twenty grains three times a day.

November 28th.—Hearing is now, so far as she herself can perceive, as acute as when I first saw her on the 6th of October. The ticking of the watch is heard at a distance of four feet. The dizziness has also disappeared entirely, although a little tinnitus still remains. All treatment is to be stopped.

From her physician, Dr. Charles Packard, I learn that he has had occasion to treat her for a suspicious periostitis on both tibiæ. The deafness was therefore probably due to a syphilitic affection of the auditory nerve, or of the labyrinth, or of some structure in its immediate neighborhood.

CASE CXX.—*Almost complete loss of hearing in both ears in a case of tardily developed inherited syphilis; nearly perfect recovery under the use of potassic iodide, in moderately large doses; the causative lesions were probably located in the region of both fenestræ.*

A child, seven years of age, and of somewhat delicate appearance, was brought to me by his parents on January 11th, 1887, for the relief of pronounced deafness. The history given by them was, in brief, as follows:

About three weeks previously the child had what seemed to be an attack of croup, which lasted four or five days, and was followed by impaired hearing. The deafness rapidly became so marked that it was almost impossible to communicate with him by speech. Previously to the present attack the child, it

or no benefit, however, resulted. It was not until the more vigorous anti-syphilitic plan of treatment had been instituted—the plan which Dr. Roosa was the first, I believe, to employ in these cases of sudden and complete deafness—that decided benefit was obtained.

was said, had never shown any signs of impaired hearing, although on cross-examination the parents admitted that they had sometimes observed a certain degree of inattention on his part, yet not sufficient to make them suspect impairment of the hearing-power.

Inflations of the middle ears according to Politzer's method were resorted to promptly by the physician in attendance, and were continued, at regular intervals, up to the time when I saw the case—that is, for a period of about two weeks. Noticeable improvement in the hearing, lasting for a few minutes, or for an hour or two, followed these inflations. In the main, however, the hearing power diminished rather than increased during this period.

At the time when I first saw the child there seemed to be, for all practical purposes, total deafness. From the statements made by the parents, and also from my own observations, I became satisfied that there were brief intervals of time during which the hearing was sufficiently acute for the child to distinguish correctly at least some of the words that were spoken loudly into one or the other ear. A careful inquiry into the previous history revealed nothing that might throw light on the nature of the aural affection. There had been no complaint of pain, no staggering or uncertain gait, no paralysis. On examination, both drum-membranes were found to present a somewhat dull and sunken appearance. The dull appearance was of such a nature as to suggest the presence of mucus in the drum cavities. However, when air was forced into them by aid of the Eustachian catheter, the sound conveyed to my ear through an auscultation tube was that of air entering freely a tympanum of undiminished size and free from the presence of fluid. This satisfied me that the dulness observed was due, not to the presence of mucus, but rather to an œdematous condition of the mucous membrane on the reverse side of the membrana tympani. The hearing seemed to be impaired to an equal degree in both ears. There were ample evidences of nasal and naso-pharyngeal catarrh.

In the matter of a diagnosis I was obliged to confess that both the nature and the precise seat of the disease were unknown to me. The rapidity with which the hearing had disappeared, and the apparent absence of physical changes in the middle ears adequate to explain the deafness, favored the hypothesis of lesions involving the labyrinth; while, on the other hand, the development of the deafness in connection with a croupy attack, the existence of decided catarrhal manifestations in and about the ear, and the temporary improvement brought about by inflations of the drum cavities, favored rather the idea that the affection was, after all, simply a subacute catarrhal inflammation of the middle ears with an unusual degree of secondary labyrinthine congestion. At that time there were no visible lesions in the external auditory canals; or, if they were present, they were so insignificant as to escape my notice.

Under these circumstances I gave a guarded prognosis, and recommended a plan of treatment based on the supposition that the disease was simply catarrhal in its nature.

On January 26th, I noticed, for the first time, the existence of a circumscribed area of redness (localized periostitis) on the posterior and upper wall of the right external auditory canal, in close proximity to the membrana tympani. The redness of the skin did not extend perceptibly beyond the periphery of the latter membrane. An examination of the left ear showed that

almost precisely the same condition of the parts existed in that ear; the only difference being that the redness was somewhat less pronounced on one side than on the other. In the absence of pain, of fever, and of any other sign of an ordinary inflammation, and from the fact that the family history was not entirely free from a tuberculous taint, I drew the inference that the case in hand was one of tuberculous osteitis involving the bony floor of the antrum, and extending inward and forward as far as to the fenestra ovalis and probably into the labyrinth itself. With this new light on the case I suggested to the attending physician that in addition to the inflations and tri weekly applications of silver nitrate to the vault of the pharynx, cod liver oil and Huxham's tincture of cinchona should be administered internally, and a modified Wilde's incision[1] be made behind the right ear. It was hoped that, by the aid of the decided counter-irritation which would be established by this last measure, the inflammation of the bone might be made to subside.

February 10th.—The incision was made as suggested, but the localized periostitis still persists, and, so far as the eye can discover, it has not materially diminished in degree. The external wound has healed. There is a slight improvement in the hearing, according to the statement of the parents, but it is not recognizable by the physician.

February 15th.—Incision repeated, on the same side, and wound stuffed with coarse oakum, with a view to exciting more decided counter-irritation than before.

February 21st.—Very little inflammatory reaction has followed both this and the first incision, and no recognizable benefit has resulted from the procedure.

By the merest accident I learned to-day, from a person who had been acquainted with the child's parents in earlier years, that both of them had had syphilis before the birth of the child. I made careful inquiries in regard to the ailments and general condition of health of the patient prior to the attack of "croup," but failed to obtain any satisfactory information. From the attending physician, however, I learned that the patient had been a pale, delicate babe. He had had no serious illness during the first year. When a little over a year old he began to have attacks of vomiting, and at varying intervals they would recur. They began by his emptying his stomach, and then he would retch and throw up whatever he took, for three days. They learned to expect a three-days' siege whenever an attack began. There was no system or regularity about the return of these attacks. There were no head symptoms nor anything simulating a convulsion. The mother had had one miscarriage and had lost two or three children at an early age. An examination of the child's incisor teeth (not yet the permanent ones) shows no evidences of the characteristic defects described by Hutchinson.

Again the treatment was changed. All attempts at counter-irritation were abandoned, no further applications of silver nitrate were made to the vault of the pharynx,—which, in fact, seemed then to be in so nearly a normal condition as not to require any further active interference,—and the child was put under a regular course of potassic iodide, in slowly increasing doses. It

[1] Incision of the mastoid integuments, followed by stuffing of the wound with lint or other irritating material.

was also suggested that mercurial inunctions should be added, later, to the internal administration of the iodide. My impression is that this part of the treatment was not adopted.

On the 27th of March the attending physician reported that the child was improving, both in his general health and in his hearing-power. The iodide of potassium had been given, at first, in five-grain doses, three times a day, but it had been gradually increased, and at that date the dose had reached seventeen grains, three times a day. The cod-liver oil and compound tincture of cinchona had also been continued. "There is no change," his physician writes, "in the appearance of the external auditory canal that I can discover. The remedy has not yet shown its effect on the skin or in any other way; but the child hears better. Of this I am positive."

I quote again from a letter dated June 11th: "He has taken the iodide regularly since I wrote you last, and is improving quite steadily in respect to his hearing. He took at one time thirty-eight grains, three times a day, but it caused some coryza and he has taken less since. I have not seen him, until to-day, for nearly six weeks. Meantime he has developed a trouble with the left eye, the nature of which I do not understand [? keratitis parenchymatosa]. The chief symptoms are photophobia and watering of the eye. His parents have during this time taken the responsibility of reducing his iodide to seven and a half grains three times a day. I have directed them to increase it again. The child's general health is good. He is growing, but not increasing in weight."

In answer to my request for more detailed information in regard to the condition of the hearing, the doctor wrote, under date of June 18th: "He hears equally well, as nearly as I can ascertain, with both ears. He would not hear an *ordinary* tone to know what was said. He would hear a tone *slightly* elevated, if the words were spoken slowly and distinctly. His parents think he hears ordinary conversation at times." Again, on the 12th of July, he wrote that "one of the child's knees has been in a swollen condition since ten days ago. There has been no pain, however, nor does it hurt him to use it." Finally, at a still later date (September 13th), he wrote that the boy had continued to take the iodide, and that he was then able to hear almost as well as he had ever heard.

Comments.—It seems to me that there can be very little doubt in regard to the syphilitic nature of the lesions which damaged this child's hearing so seriously. The miscarriage experienced by the mother, the loss of two or three of her children in infancy, the selection of the bony parts of the ear by the disease for its first centre of activity, the subsequent development of inflammation of the eye, and then of some sluggish disease of the knee, and, finally, the markedly beneficial effects of potassic iodide administered internally—all these facts, I believe, favor strongly the idea that the case was one of tardily developed inherited syphilis.

A number of similar cases have been reported by Knapp, of New York (Vol. IX. of *The Archives of Otology*, where the earlier

literature of the subject may be found), by Kipp, of Newark, N. J. (Vol. II. of the Transactions of the American Otological Society), and by others. The chief point of interest in the present case lies in the fact that a circumscribed periostitis was demonstrable, for a comparatively long period, at symmetrically placed spots in both external auditory canals. These spots corresponded to the bony floors of the mastoid antra. In all other material respects the case differed but little from those previously reported.

CASE CXXI.—*Apoplectiform attack, characterized by incomplete loss of hearing in one ear; attack ushered in by severe pain in the head, vertigo, and loud subjective noises in the affected ear; decided improvement in the hearing under the administration of moderately large doses of potassic iodide; the lesion involved both the ampullar and the cochlear branches of the auditory nerve; the possibility of a syphilitic origin suggests itself.*

The patient, a healthy but rather full-blooded lady, about thirty years of age, consulted me on the 17th of September, 1872. She stated that during the previous spring she had experienced a sudden attack of severe pain in the head, with loud noises in the right ear. Afterward she discovered that she could not walk without staggering, and that the hearing of the right ear was very much impaired. The former symptom had gradually disappeared, but the deafness and the noises still persisted. On examination, I found both drum-membranes—so far as they could be seen—normal in appearance. In each external auditory canal, however, there was a hemispherical exostosis, sufficiently large to conceal the lower two-thirds of the membrana tympani. These symmetrically placed bony tumors were in close proximity to the drum-membranes. The tuning-fork was heard best in the left ear; the ticking of the watch was not heard at all in the right ear; when the left ear was closed, words spoken in an ordinary tone of voice were not heard correctly in the right ear beyond a distance of about one foot.

In the course of about two months, under the employment of the iodide of potassium in ten-grain doses, repeated three times a day, the patient so far regained her hearing that she could distinguish the ticking of my watch at a distance of half an inch, and words spoken in an ordinary tone of voice at a distance of about five feet. The tinnitus continued unchanged. Two or three times, during this period of eight weeks, the remedy had disagreed with her, and she had been obliged to discontinue it for about one week each time.

As recently as during the summer of 1879, I learned that the patient had not experienced a relapse.

TRANSIENT VASOMOTOR PARESIS OF THE LABYRINTHINE BLOOD-VESSELS.

CASE CXXII.—*Transient increase of pressure upon the contents of the labyrinth, the result partly of some disturbance of the digestion, and partly of a catarrhal inflammation more particularly of the Eustachian tube. A reflex*

vasomotor neurosis is the term which describes the more important features of the case.

Male, thirty-eight years of age, and of a fairly healthy appearance. History: Stomach indigestion (nausea, flatulence, etc.), during past two or three years; two weeks ago, he was taken suddenly with ringing in his left ear and marked vertigo; two or three days later, he discovered that the hearing in the affected ear was somewhat impaired. Present condition (August 30th, 1880): gait is very unsteady, and the hearing-power of the left ear is somewhat, but not markedly, diminished; sound of a vibrating tuning fork placed upon the centre of the forehead is referred to the right ear; the tympanic membrane presents no marked alterations; at most, it is somewhat depressed; inflation with a Politzer bag brings it back to a natural position and diminishes the tinnitus; evidences of a moderately active naso-pharyngeal catarrh.

The patient was never seen again.

Case CXXIII.—*Intermittent complete deafness, dependent primarily upon hypertrophy of the lymphoid tissue in the vault of the pharynx; the labyrinthine blood vessels were undoubtedly in a dilated condition, and the lamina spiralis must also have sustained some damage.*

A boy, about four years of age, and in fairly good health, was brought to the New York Eye and Ear Infirmary by his mother for the relief of his deafness. According to her account, the child had, on two previous occasions, remained in a condition of complete deafness for a period, each time, of several weeks. During the intervals he had heard sufficiently well for those around him to be able to make themselves understood. At the time when I saw the boy, he had been—according to the mother's report—absolutely deaf for a period of six weeks, and the parents were beginning to fear that he had permanently lost the sense of hearing. On examination I found the drum-membranes so highly atrophied that each of them lay like a thin film in contact with the purplish and swollen mucous membrane of the inner wall of the tympanum. The tonsils were enormously swollen, and the naso-pharyngeal space seemed to be almost obliterated by the highly swollen condition of the surrounding walls [doubtless hypertrophied lymphoid tissue]. As a consequence the boy was obliged to breathe wholly through the mouth. So far as I could ascertain by actual experiment, he was totally deaf. (Unfortunately, my notes of this interesting case stop at this point.)

Anomalies of Hearing Believed to be Dependent upon Lesions Confined to the Cochlea.

Case CXXIV.—*Non-suppurative inflammation of one middle ear, and chronic suppurative inflammation of the other, associated with progressive diminution of the range of hearing for musical tones; probably due to lesions involving the cochlear portions of the labyrinth.*

Male, nineteen years of age, in robust health. Discharge from the right ear since childhood. Hearing in this ear very much impaired. He complains that the hearing in the left ear, which has hitherto fairly well suf-

ficed for his needs, is now beginning to fail perceptibly. Tinnitus has recently developed in this ear. Present condition (October 10th, 1881) : Pus in the right meatus; large perforation in the right membrana tympani. Left membrane intact, somewhat depressed, but not congested. Decided naso-pharyngeal catarrh. Words spoken in an ordinary tone of voice are not easily heard in the left ear beyond a distance of six feet; the ticking of my watch is heard only when it is pressed against the left auricle. When the piano was used for testing purposes it was discovered that the patient (who possessed a fair degree of musical cultivation) was not able (with the right ear firmly closed) to distinguish well-defined musical tones (in the upward direction) beyond F_4.[1] With the left ear (the comparatively good ear) closed, he could hear no notes lower than D_3.

My memoranda give very little further information in regard to this case. Treatment of the naso-pharyngeal catarrh afforded him relief from the tinnitus, but it did not effect any improvement of the hearing in the left ear. A memorandum for December 2d, 1891, states that the tinnitus had recently returned, and that a test with the piano showed that there had been a further diminution of his range of audition for musical tones, amounting in all to four notes.

Case CXXV.—*Subacute catarrhal inflammation of one middle ear, accompanied by diplacusis monauricularis.*

Male, about thirty-two years of age, has only a little musical cultivation. He contracted a severe cold in the head, and soon afterward began to have some discomfort in the right ear. When notes of a rather low pitch were sounded, he heard them as well-defined musical tones. When, however, the highest tones, and even those of a moderately high pitch were sounded, he heard (in the affected ear), besides the fundamental tone, a second and less distinct one. His ear not being sufficiently cultivated, he was unable to state what was the interval between these two tones. Furthermore, while suffering in this way he attended a public concert, but, instead of deriving pleasure from the music, he experienced positive discomfort by reason of the great confusion of sounds which it produced in his ear. He discovered, however, that by keeping the right ear closed the confusion entirely disappeared, and the musical tones which reached his ear appeared to be distinct and harmonious. In the course of a few weeks these unpleasant symptoms entirely disappeared.

Comments.—In this case, the term *diplacusis monauricularis* (or double hearing in one and the same ear) would be the ap-

[1] In my notes of this case I can find no record of any tests having been made, as regards this ear, in the downward direction of the musical scale. I infer from this—although perhaps wrongly—that no deficiency was found in this left ear as regards its power to distinguish correctly the lower notes. The same omission appears to have been made in regard to the power of the right ear to distinguish the higher notes of the piano. It is a source of regret to me that this omission should have occurred, especially as my memory is not equal to the task of supplying the deficiency.

propriate expression to use in designating the pathological condition.[1]

CASE CXXVI.—*Subacute otitis media catarrhalis affecting one ear, and accompanied by diplacusis binauricularis.*

The patient, who was suffering at the time from a naso-pharyngeal catarrh, accompanied doubtless by a similar condition of one middle ear, experienced an annoyance of the following nature: "When I whistled," I quote very nearly his own words as written down at the time in my note-book—"I heard in one ear the corresponding (or correct) note, but in the other ear I heard a tone which harmonized with the first note; the exact relation of which, however, to the note whistled I am not musical enough to state. If I closed the ear that was out of tune I heard only one note, and not a chord." As the patient was giving me an account of something that had happened before I saw him, I was unable to gather more accurate information with regard to several points which would be apt to occur to anybody on reading the above statement.

Comments.—In classifying this case, we might very properly designate it by the term *diplacusis binauricularis*, the phenomenon of double hearing requiring, in this case, both ears for its production.

CASE CXXVII.—*Chronic catarrhal inflammation of both middle ears, accompanied by the symptom of double hearing.*

The patient, a maiden lady about fifty years of age, consulted me on the 25th of June, 1873, for a slowly increasing deafness, which on examination I found to be due to a chronic catarrhal inflammation of both middle ears. When I placed the vibrating tuning-fork (C) upon the central portion of the forehead, she said that she heard it differently in the two ears, that is, lower in the left than in the right. As she knew very little about music, she could not tell what the interval was between the two notes. She was positive, however, that it was less than an octave. She also said that the two notes harmonized. I then held the vibrating fork first in front of one ear and then in front of the other, and she still insisted that the pitch of the tone heard on one side was lower than that heard on the other.

Comments.—Those who are interested in the subject will find, in the sixth edition of Dr. Roosa's treatise (pp. 604 and 605), the report of a case in which all the more important details are given with great fulness. Dr. Knapp's article, referred to above, may also be consulted with advantage.

It is precisely these cases of diplacusis which are considered as *par excellence* instances of disease of the cochlea. It is assumed

[1] Dr. Herman Knapp, of this city, was, I believe, the first person to suggest this term as the appropriate one for this peculiar anomaly. (See vol. ii. of his Archives of Ophthalmology and Otology.)

that those particular fibres or sets of fibres in the organ of Corti, which normally should vibrate in sympathy with a different tone from that sounded, become so altered in their tension or in their loading that they too—in addition to the fibres which vibrate normally—respond to the tone in question, and so send a wrong communication to the auditory centres in the brain. I have no means of proving that this is not the correct interpretation of these rare phenomena; and yet at the same time it is conceivable that the transmitting mechanism of the tympanic cavity may, by reason of certain catarrhal alterations, be so mistuned as to allow certain harmonics of the note sounded outside of the ear to exert a preponderating influence upon its mode of vibration, and thus to excite unduly the corresponding portions of Corti's organ. In this way the brain would receive the full impression of the fundamental note sounded, and, in addition, a lesser impression—but yet very much greater than it should be under normal conditions—of one of the harmonics.

Anomalies of Hearing of Extra-Labyrinthine Origin.

Case CXXVIII.—*Subjective and objective systolic bruit in one ear; pressure upon an arteriole in the tympanic cavity the probable cause.*

The patient, an intelligent woman, about forty years of age, consulted me at the Infirmary for a very distressing puffing noise in the right ear. She said that she had discovered that, by making pressure behind the right ear, she could stop the noise. Her hearing had not been affected, nor had she experienced any pain in the right ear. On examination, I found the drum-membrane normal both in texture and in position. No visible pulsation could be detected, nor was there any congestion of the parts. By means of the auscultation-tube, however, a distinct systolic bruit was heard, both by Dr. William McFarland, who was at that time my assistant, and by myself. The pressure of the conical end of the auscultation-tube against the walls of the orifice of the auditory canal rendered the bruit inaudible. The heart-sounds were normal, and the carotids of the two sides seemed to beat with equal force. Unfortunately, I neglected to ascertain whether firm pressure upon the carotid of the right side caused the noise to cease, or not. From the fact, however, that the woman herself was able to stop the noise by pressing upon some spot situated behind the ear, and from the fact that the conical hard-rubber end-piece of the auscultation-tube accomplished the same result, there can be very little doubt but that the bruit originated either in some twig of the stylo-mastoid artery, which supplies the drum-membrane and posterior portion of the tympanum, or in that branch of the posterior auricular artery which supplies the external auditory canal.

Comments.—It does not seem to me to be necessary to assume

that the noise in question owed its origin to an aneurismal dilatation; it might equally well have been caused by some pathological process that took place outside of the artery, as, for example, by the contraction of cicatricial tissue in its neighborhood, causing diminution in its calibre.[1] Cicatricial bands may occupy any position in the tympanic cavity, and consequently may very readily, under favorable circumstances, exert pressure, either directly or indirectly, upon an arteriole.

Cases like the one just narrated are, so far as my experience goes, quite rare.

In the case of a young man who was brought by Dr. William Cowen, of this city, before the New York Otological Society, at one of its meetings in the early part of 1897, a pulsating sound, of a distinctly musical character, was easily heard, in one of the patient's ears, through an auscultation-tube, by all the members who were present. The ear in which this musical sound was audible presented a nearly normal membrana tympani; in fact, no cause for the sound could be discovered, either in the local conditions found or in the past history of the case. The suggestion was made that it might be due to the presence in the tympanum of a delicate band of connective tissue, which was tensely stretched from the outer wall of some arteriole to a neighboring fixed point. The thrill of the current of blood passing through this vessel would probably be sufficient to excite this tensely stretched band into continuous vibration, with regular crescendos corresponding to each systole of the heart. One of the cases reported by Dr. J. Orne Greene[2] is almost precisely similar to the one referred to above.

Diagnosis.

So far as the diagnosis is concerned, it is necessary, it appears to me, to say but very little in addition to what I have already said in other parts of this chapter, and in that which is devoted to diagnostic methods in general. By comparing the history of the case with the conditions which are revealed by an examination with the speculum and reflected light, and with the results of the tuning-fork and other tests of the hearing-power, no special difficulty ought to

[1] Consult, on this subject, a paper by Dr. J. Orne Greene, of Boston, in the Transactions of the American Otological Society for 1878. Dr. Spencer, of St. Louis, has also, I believe, written on this subject in a recent number of one of the St. Louis journals.

[2] *Op. cit.*, p. 259.

be experienced by the physician in determining — in the case of an adult or an older child — whether or not he is dealing with labyrinthine or auditory-nerve disease. In the case of a young child, however, the problem is by no means an easy one to solve. Under these circumstances the physician is compelled to trust almost entirely to the observation of the parents or guardian in determining to just what extent the little patient has lost its hearing-power.

In most cases insurmountable difficulties will be encountered whenever the attempt is made to decide whether the lesions should be located in the labyrinth or on the outside of this system of cavities — *i.e.*, in the trunk of the auditory nerve or in the auditory centres in the medulla oblongata. It is only in exceptional instances (like that of Case CXIV.) that certain special symptoms are presented which warrant the conclusion that the causative lesion is located in some part of the brain rather than in the labyrinth.

Prognosis.

The prognosis, in the great majority of cases such as I have described in the present chapter, is unfavorable. It is unqualifiedly bad in those which have developed in the course of an attack of epidemic cerebro-spinal meningitis or of mumps; and it is scarcely less so in those of Ménière's disease. Some slight degree of encouragement may be derived from the fact that among the cases of labyrinthine disease due to other epidemic causes (for example, scarlet fever, typhoid fever, the grippe, etc.), a few partial or even complete recoveries have been reported. The case of syphilitic deafness treated by Dr. Roosa (Case CXVIII.) and that of the boy with inherited syphilis (Case CXX.) furnish striking examples of what may sometimes be accomplished by the adoption of a vigorous anti-syphilitic course of treatment. On the other hand, the profound deafness of young children whose labyrinths have been kept for months or years under a constant high degree of pressure may be improved a little, but never — so far as my experience goes — to any very conspicuous degree.

Treatment.

The proper treatment to be adopted must vary according to the special conditions presented in each case. To discuss these here would necessitate a great deal of unnecessary repetition. The reader is therefore referred to the preceding accounts of individual cases.

CHAPTER XXIV.

(Supplementary.)

SKETCH OF THE ANATOMICAL RELATIONS AND PHYSIOLOGY OF THE EAR.

Anatomy of the Middle Ear.

The ear in mammals consists of three different cavities—the external auditory canal, the tympanum, and the labyrinth. The first cavity, which is nearly cylindrical in shape, communicates freely, at one end, with the outer world, while at the other it is entirely shut off from the cavity beyond (namely, the tympanum) by a thin, inelastic membrane — *the membrana tympani*, or *drum-membrane*. The second cavity, *the tympanum*, so far as the naked eye can see, is a closed cavity, filled with air, which, through the intervention of the Eustachian tube, is maintained at essentially the same degree of density as the air on the outer side of the membrana tympani; or, in other words, the atmospheric pressure upon the outer side of the membrana tympani and that upon the inner side very nearly counterbalance each other so long as the Eustachian tube is permeable to air. A slight predominance of the external over the internal pressure—just sufficient to keep the tympanic membrane in a fairly tense condition—may be considered as representing the habitual aërostatic condition in the normal ear. The outer side of the tym-

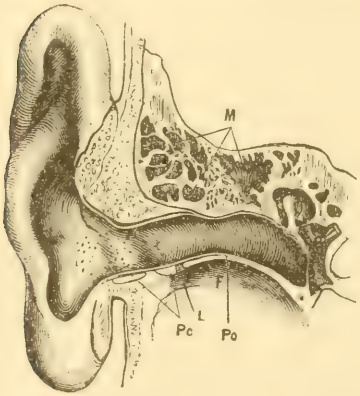

Fig. 124.—Transverse Vertical Section of the Temporal Bone, showing the relations of the external auditory canal to the middle ear, and of the ossicles to each other and to the membrana tympani and fenestra ovalis. (After Urbantschitsch.) *M*, Mastoid cells; *Pc*, cartilaginous meatus; *Po*, osseous meatus; *L*, membranous connection between the cartilaginous and the osseous portions of the canal; *F*, fossa of the temporo-maxillary articulation.

panum, as will be seen by the accompanying figure (Fig. 124), is formed chiefly by the membrana tympani, while the inner is a somewhat dome-shaped surface of bone, covered of course with mucous membrane. In this inner wall of the cavity, near its posterior end, are two openings—the one oval in shape, the other round—which lead by separate passages into the last cavity or system of

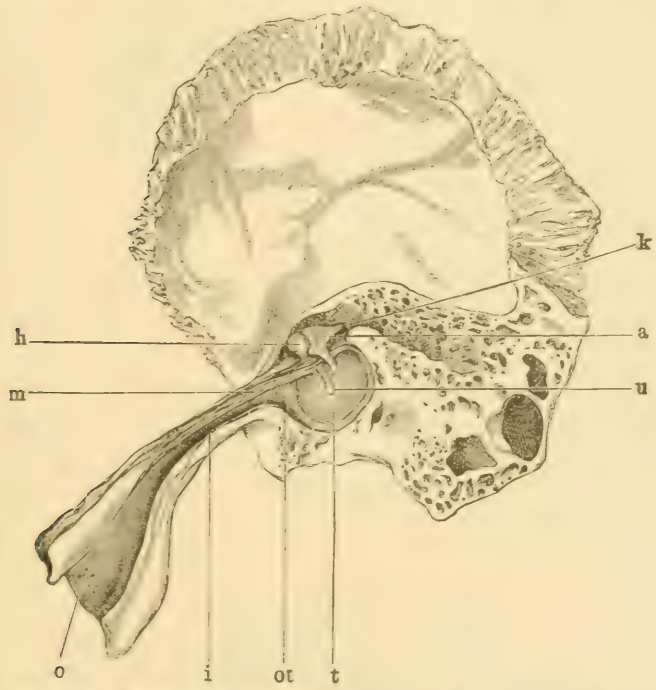

FIG. 125.—View of the Outer Wall of the Tympanum. (After Politzer.) *a*, Ambos; *k*, its short process, resting against the posterior wall of the tympanum just beneath the entrance to the mastoid antrum; *h*, the head of the malleus; *u*, the tip end of the handle of this ossicle, corresponding to the umbo of the membrana tympani; *m*, the fleshy part of the musculus tensor tympani; *o*, the pharyngeal orifice, *ot*, the tympanic orifice, and *i*, the isthmus of the Eustachian tube; *t*, the tympanic membrane.

cavities of the ear, *viz., the labyrinth*. In the natural state these openings are closed, the upper one—*the fenestra ovalis*—by the foot-plate of the stirrup, the lower—*the fenestra rotunda*—by a delicate membrane—*the membrana tympani secundaria*. The apparatus provided for transmitting vibrations of sound from the air in the external auditory canal to the acoustic nerve in the labyrinth consists of a compound lever formed by the three ossicles—*the malleus, the incus,* and *the stapes*. If we examine carefully the anatomical and

mechanical relations of these little bones to each other, to the membrana tympani, and to the adjacent parts, we shall find ample evidence of the function which they are intended to perform. In the first place, if we disconnect the incus from the malleus, thus leav-

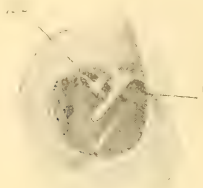

FIG. 126.—Direct View of the Tympanic Cavity after the Removal of the Anterior Wall of the External Auditory Canal and the Tympanic Membrane. (After Zuckerkandl.) *St*, Tendon of the stapedius muscle; *T*, tendon of the tensor tympani muscle, with fold.

FIG. 127. Frontal Section through a Right Tympanic Cavity; Anterior Half. (After Zuckerkandl.) *T*, tendon of the tensor tympani muscle; *P*, promontory, with its niche.

ing the latter ossicle free to follow the movements of the drum-membrane, and then press upon it from different directions and at different points, we find that its attachments are of such a nature that it can only rotate inward and outward, as far as the drum-membrane will permit it to rotate, around an axis corresponding to

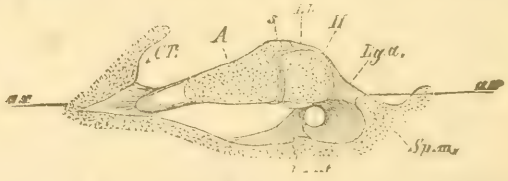

FIG. 128.—View of the Malleus and Incus as Seen from Above (diagrammatic). (After Hensen.) *A*, Incus; *H*, malleus; *Lg.a.*, ligamentum anticum; *ax*, *ax*, axis-line.

a line drawn from the spina tympanica posterior through the neck of the malleus, and finally through the band of fibres known as the ligamentum anticum of the malleus (Fig. 128 *Lg.a*). This axis-line is represented in the accompanying figure by a straight line running from *ax* to *ax*.

The next point that will be noticed is the peculiar manner in which the incus is attached to the malleus. As will be seen in Fig. 124, the head of the latter and the body of the incus interlock at a level noticeably higher than that of the axis-line referred to above.

Helmholtz, who was the first to describe the real nature of the malleo-incudal joint, compared it to "the joint used in certain watch-keys, where the handle cannot be turned in one direction without carrying the steel shell with it, while in the opposite direction it meets with only slight resistance" ("Mechanik der Gehörknöchelchen," Bonn, 1869). As a result of this peculiar union between the two ossicles, an excursion of the head of the malleus from within outward —corresponding to an excursion of the membrana tympani in the reverse direction—will, by reason of the fact that the short process of the incus is quite firmly anchored to the posterior wall of the tympanic cavity, cause the forward part of the body of this ossicle to be lifted both upward and outward. As a further result of this lifting of the body of the incus upward and outward, the end of the long lever which projects downward from the incus, and which is known by the name of its long process, wi . be made to rotate upward and inward, and probably a little forward, through a short arc of a circle. The axis-line of the rotatory movements of the incus, it will thus be seen, is quite different from that of the malleus. With the reverse excursion of the latter ossicle, all direct pressure upon the incus is withdrawn, and this little bone returns to its former position of rest, partly through the force of gravity and partly through the elasticity of the articular capsule which binds it to the head of the malleus. The third member of the chain of ossicles, or rather of the compound lever which we are endeavoring to describe, is the stapes. The head of this little bone articulates with the end of the long process of the incus. The opposing bony prominences are provided with regular articular surfaces, and the joint thus formed is enveloped by a capsular ligament and lubricated, apparently, by synovial fluid. The capsular ligament holds the opposing articular surfaces together so firmly that the head of the stapes must necessarily follow all the movements of the long process of the incus. These movements, as we have just seen, would cause the head of the stapes to be carried, first in an inward, upward, and slightly forward direction, and then in the reverse direction back to the starting-point. What effect this excursion of the head of the stapes will have upon the foot-plate of this ossicle depends upon the anatomical relations of the latter to the oval window. In the first place, it should be borne in mind that in a state of rest the foot-plate lies in a plane which is very nearly parallel with that of the membrana tympani or of the inner wall of the tympanic cavity. The plane of the circle in whose arc the head of the stapes moves

when it makes its excursion, is therefore nearly at right angles to the plane of the foot-plate. Consequently there are six different axes around which the foot-plate of the stirrup may rotate, three of them horizontal, and three vertical, viz.: (1) it may rotate around an axis running through its upper border; or (2) through one traversing its lower border; or, finally (3), through one situated midway between the two parallel borders. These are the three horizontal axes. The vertical axes are: (4) one running through the anterior border or lip of the foot-plate, (5) or one running through the posterior border, or, finally (6), one running midway between the two.

1. In the case of an axis of rotation running through the upper border, we should find the attachments of the foot-plate to the oval window firmer, *i.e.*, less mobile, along the upper than along the lower border, as the excursion of the foot-plate would be far greater at the latter than at the former point.

2. In the case of an axis of rotation running through the lower border, we should find the conditions exactly reversed; the lower border would be more firmly attached to the edge of the oval window than the upper one.

3. In the case of an axis of rotation running midway between the upper and the lower borders, we should find the attachments equally yielding or equally firm at both borders; for, like the damper in a stove-pipe, one border of the foot-plate would, in such an arrangement of the axis of rotation, be obliged to travel exactly as far in one direction as did the other in the opposite direction.

The same line of reasoning may be applied to the three possible vertical axes. If the axis of rotation runs through the anterior margin of the foot-plate, the relations of the soft parts along the posterior margin would be found to be such as favor greater freedom of motion on the part of the stapes at this point, and less freedom near the axial line. On the other hand, if it runs through the posterior margin, the relations just described would be reversed. And, finally, if the axis of rotation is situated midway between the two, no material difference between the attachments of the anterior and posterior borders should be discoverable.

From a mechanical standpoint it would not make any difference whether the axis of rotation of the foot-plate of the stapes was coincident with the upper, the lower, the anterior, or the posterior border; for in either case a direct displacement of the fluid contents of the labyrinth as a whole must follow. On the other hand, if

the axial line ran through the centre of the foot-plate, midway between the upper and the lower borders, or midway between the anterior and the posterior margins, the excursions of the stapes would simply disturb slightly that part of the labyrinthine fluid which lay in its immediate neighborhood, but there would be no displacement of the fluid contents as a whole. The determination of the position of the axial line of rotation of the foot-plate of the stapes is therefore a matter of importance.

A study of the minute anatomical relations of this ossicle to the oval window throws considerable light upon this question, and the observation that the membrana tympani secundaria makes to-and-fro excursions when the membrana tympani and chain of ossicles are set in vibration virtually settles the question in favor of a total displacement of the contents of the labyrinth—that is, in favor of locating the axial line at either one of the four margins of the foot-plate of the stapes, and not through its centre.[1] In the hope of determining this point by direct observation, Politzer cut away enough of the pars petrosa of the temporal bone to gain an unobstructed view of the vestibular aspect of the foot-plate of the stirrup, with-

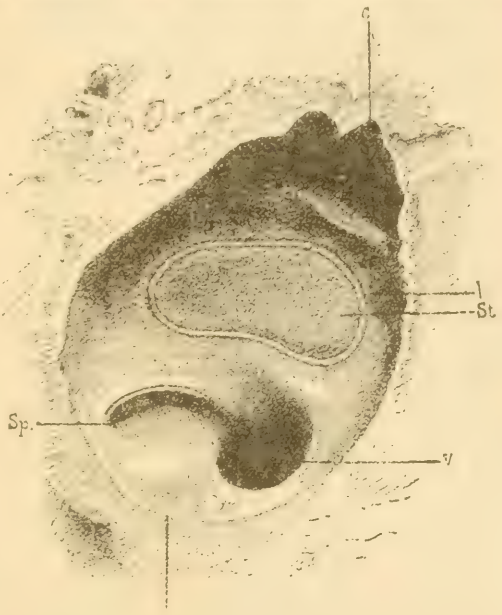

FIG. 129.—View of the Foot-plate of the Left Stapes, as Seen from Within the Vestibule. (Magnified several diameters.) *St*, Foot-plate of the stapes; *l*, annular ligament, which spans the space between the margin of the fenestra ovalis and the edge of the foot-plate; *Sp*, commencement of the lamina spiralis ossea on the lower wall of the vestibule (*m*); *v*, opening leading into the scala vestibuli. (Copied from Politzer's *Lehrbuch der Ohrenheilkunde, 2te Ausgabe.*)

[1] See, in this connection, the author's paper on the "Mechanism of the Ossicles of the Ear," published in the Archives of Ophthalmology and Otology, in 1870.

out disturbing any of the connections of this or of the other two ossicles and membrana tympani. The view thus gained is well shown in the preceding cut (Fig. 129), which is a copy of that printed in the second edition of Professor Politzer's exhaustive treatise. When the membrana tympani was made to perform to-and-fro excursions, in imitation of those which it naturally performs, Politzer found that visible motion took place along the upper border of the foot-plate and at its anterior end, whereas it was only with great difficulty that he could distinguish any evidences of motion along the inferior border. In 1869, while a pupil in the laboratory of Prof. Julius Arnold, of Heidelberg, I made a series of sections, both vertical and horizontal, through the foot-plate of the stapes and surrounding oval window. The accompanying illustrations (Figs. 130 and 131) are direct copies of two of these sections, and they show very distinctly, it seems to me, that the anterior end (the end opposite *A*, in Fig. 130) and the upper edge (that opposite *B*, in Fig. 131) are better fitted, anatomically, to perform wide excursions than are respectively the posterior end and the lower margin of this ossicle. The anatomical relations, therefore, harmonize

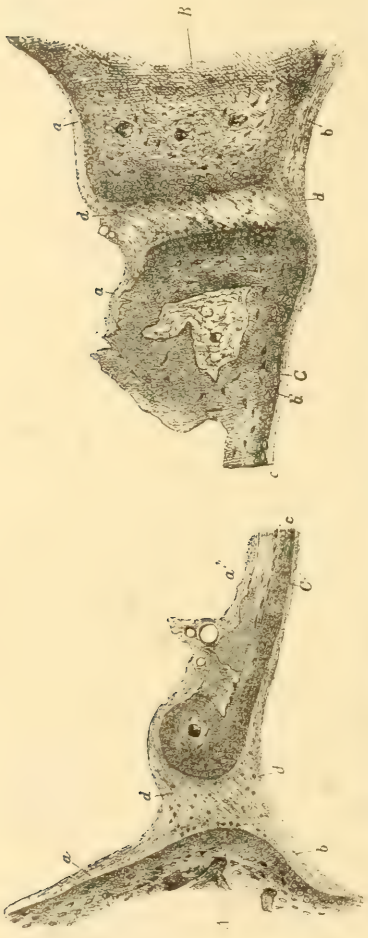

FIG. 130.—Longitudinal Section of the Foot-plate of the Stapes, and of the Anterior and Posterior Margins of the Fenestra Ovalis. (Magnified about 40 diameters.) *A*, Anterior margin, *B*, posterior margin of the fenestra ovalis; *C*, *C*, foot-plate of the stapes; *a*, periosteum (=mucosa) of the niche for the oval window; *b*, endosteum of the vestibular wall; *b'*, endosteum of the vestibular aspect of the foot-plate; *d*, stapedio-vestibular or annular ligament. (Copied from a specimen belonging to the author.)

with the results of direct observation, and we are justified in stating that the axis of rotation of the foot-plate of the stirrup is not fixed, but represents what I might term the resultant of both a vertical (through the posterior border) and a horizontal (through the lower border) axis. In the light of these facts, then, we may compare the motion of the stapes to that of a treadle rather than to that of a piston, as is commonly done. The mechanical effect upon the fluid of the labyrinth, it is true, is the same in both motions, but when we come to consider the action of the stapedius muscle, we shall see that it is important to bear clearly in mind what is the precise nature of the excursions of the foot-plate.

Fig. 131.—Vertical Section of the Foot-plate of the Stapes, and of the Upper and Lower Margins of the Fenestra Ovalis. (Magnified about 40 diameters.) *A*, Lower margin, *B*, upper margin of the oval window; *C*, foot-plate of the stapes; *c*, lower edge, *d*, upper edge of the foot-plate; *e*, stapedio-vestibular or annular ligament; *f*, *f*, endosteum of the vestibular aspect of the foot-plate; *g*, *g*, periosteum (= mucosa) of the tympanic aspect of the foot-plate. (Copied from a specimen belonging to the author.)

If further corroborative evidence were needed in support of the doctrine that the ossicles play the part of a compound lever, and effect to-and-fro displacements of the labyrinthine fluid, we might furnish instances among the lower animals where a single bone (columella) takes the place of a chain of ossicles, and is so disposed, anatomically, that it can perform no other than a piston-like motion inward and outward. Such is the case, for example, in the sea turtle (see Fig. 133).

In the human being the compound lever composed of the ossicles is provided with two relatively powerful muscles, by the aid of which the different parts of the lever may at will be brought into a state of greater tension, or greater readiness to respond quickly to

vibrations of sound. The effort to pay closer attention implies, I believe, not simply the concentration of the mind upon the different sounds that reach the brain through the ear, but also the unconscious holding of these muscles in readiness to quickly attune the compound lever to all the various kinds and rates of vibration which it may be called upon to perform. A deep tone probably calls for little or no muscular co-operation, whereas the higher tones necessitate a great degree of tension of the vibrating mechanism of the middle ear, and this extreme tension can only be effected through the intervention of muscular action. While it is true that will-power exercises a certain degree of control over the action of these muscles, it is plain that habitually they must act automatically, that is, through the intervention of separate automatic nerve centres. The two muscles referred to are the tensor tympani and the stapedius.

The belly of the tensor tympani muscle rests upon a gutter-like shelf of bone on one side of the membranous part of the Eustachian tube. At the tympanic orifice of the tube the muscular substance merges into a slender cylindrical tendon which passes backward to a point on the inner wall of the tympanum, at a level a little higher than that of the oval window, where it traverses a pulley-like structure which changes the line of traction of the tendon from a direction that is chiefly antero-posterior to one that is chiefly transverse. Its final insertion is on the inner surface of the malleus, directly opposite the situation of the short process, and about midway between the extreme tip of the handle and the top of the head of this ossicle. When the muscle contracts, therefore, it puts all the ligamentous attachments of the malleus, together with the membrana tympani itself, upon the stretch. It probably also causes a somewhat closer interlocking of the opposing articular surfaces of the malleo-incudal joint.

The stapedius muscle is concealed within the pyramidal mass of bone which lies immediately back of the oval window. The belly of the muscle and the facial nerve lie side by side in their respective channels in the bone. The tendon emerges from the apex of the pyramid and passes directly forward to the head of the stapes. The contraction of the stapedius muscle will therefore produce a threefold effect: it will tend to drive the posterior margin or lip of the foot-plate farther into the vestibule; it will also tend to lift the anterior margin or lip farther out from the vestibule; and, finally, it will bring the head of the ossicle into closer contact with the end

of the long process of the ambos. Thus, through the combined action of both these muscles every part of the transmitting apparatus of the middle ear may be rendered tense, or, in other words, ready to vibrate in quick sympathy with whatever tones may reach it from the outer world.

In some animals special provision is made for the reinforcement of sounds that may reach the ear. Thus, for example, in the dog there is one large spherical bony chamber (the bulla tympanica) which apparently performs no other function but that of a resonator.[1] The elephant is provided with

FIG. 132.—Diagrammatic Representation of the Transmitting Apparatus of the Middle Ear. *MAE*, Meatus auditorius externus; *MT*, membrana tympani; *M*, hammer or malleus; *A*, anvil or ambos; *S*, stirrup or stapes; *L*, labyrinth; *FR*, fenestra rotunda. The arrows show the direction of movement in all parts of the apparatus during an inward excursion of the membrana tympani.

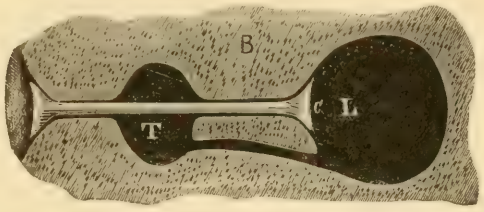

FIG. 133.—Diagrammatic Representation of the Sea-turtle's Ear. *A*, Dense elastic pad of connective tissue, separating the head or outer end of the columella (*c*) from the horny side surface of the turtle's head; *B*, solid mass of bone in which the nerve cavity or labyrinth (*L*) and a second cavity (*T*), which may be called the tympanum, are situated. That some kind of communication exists between these two cavities is shown by the fact that when pressure is made upon the outer end of the columella—and therefore upon the contents of the labyrinth—the soft parts at one point in the wall of the tympanum may be seen to move outward as if to compensate for the displacement which has taken place in the labyrinth. This yielding-point therefore represents (mechanically) the membrana tympani secundaria. (From a specimen in the author's possession.)

a perfect labyrinth of such hollow chambers, some of them of large size, and all apparently destined to serve as resonators. Both of these animals possess very acute hearing: more acute,

[1] The reader is doubtless familiar with the fact that the sound given forth by a vibrating tuning-fork can be rendered very much louder by resting its handle upon an empty wooden box, open at one end, or by bringing the ends of the tines in close proximity to and directly opposite the open mouth of a metal Helmholtz's resonator. If the tone of the resonator happen to coincide with that of the fork, the sound given forth by the latter when set in vibration and held near the mouth of the resonator will be unusually loud. It is thus seen how hollow chambers of a material like wood, some hard metal, or bone may aid greatly in reinforcing or intensifying sound.

it seems to me, than that of the human being, in whom, as a rule, the resonating chambers—the mastoid cells—are small and sometimes lacking altogether. In the elephant, the giraffe, and a few other animals, peculiar osteophytes are found in the middle ear which seem to play some part in the work of reinforcing sound. One of these osteophytes, for example, consists of a very slender rod of bone which projects free into the cavity of the middle ear, and is provided at its extremity with a com-

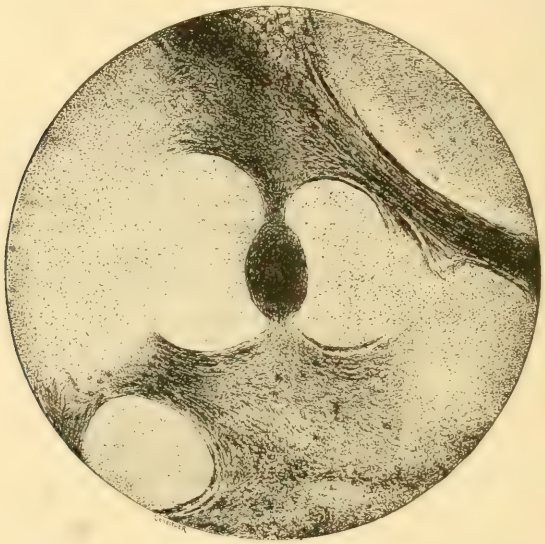

FIG. 134.—Connective-tissue Network from Vicinity of Stapes, with Peculiar Pear-shaped Body Attached. Copied from a microphotograph taken by the late Prof. J. W. S. Arnold, M.D., from a specimen belonging to the author. ×50 diameters.

paratively heavy knob.[1] Such a heavily loaded elastic rod could, in accordance with well-known acoustic laws, vibrate only in sympathy with tones of a deep pitch. Large as are some of the resonating chambers of the elephant's ear, it is improbable that any of them can serve to reinforce a decidedly low tone. I think it likely, therefore, that this particular osteophyte performs for low tones precisely the same function as the numerous larger and smaller hollow chambers do for the middle and higher tones of the musical scale. No such contrivance as this is to be found in the

[1] See a paper by the author entitled, "A Contribution to the Anatomy of the Elephant's Ear," in the Transactions of the American Otological Society for 1888.

human being, but, on the other hand, there have been found,[1] in the immediate neighborhood of the stapes, in the mastoid antrum, and, in a single instance, on the membrana tympani itself, certain peculiar ovoid bodies which very probably perform this very function of reinforcing tones of a deep pitch. One of these bodies which I discovered in a specimen prepared for the purpose of ascertaining the relations of the stapes to the oval window, is represented in the preceding cut (Fig. 134). Mechanically, the relations

FIG. 135.—View of Inner Side of the Membrana Tympani, Showing the Course of the Chorda Tympani Nerve between the Malleus and the Long Process of the Ambos. (After Urbantschitsch.) *Ci*, Body of the ambos; *Cm*, head of the malleus; *Ch*, chorda tympani nerve; *T*, inner fold of the posterior pocket.

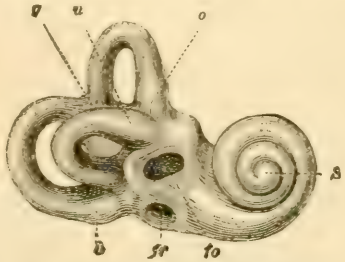

FIG. 136.—Thin Shell of Bone Immediately Surrounding the Vestibule, Cochlea, and Semicircular Canals, and Showing the Form and Relations of these Cavities to Each Other. (Right ear.) (After Gruber.) *o*, Upper semicircular canal; *h*, posterior semicircular canal; *g*, terminal canal common to both the posterior semicircular canals; *fo*, foramen ovale; *fr*, foramen rotundum; *S*, cochlea.

of these bodies are those of a loaded string or cord, tensely stretched from the sides of the niche for the oval window to the posterior limb of the stapes.

Before dismissing the subject of the middle ear, I would like to call attention to the peculiar course taken by the chorda tympani nerve on its way to the tongue. As will be seen in Fig. 135, this nerve emerges from the outer wall of the tympanic cavity, close to the posterior and upper boundary of the membrana tympani, traverses the open space between the middle portion of the malleus and the long process of the ambos, and finally loses itself in the tissues at the upper and anterior boundary of the drum-membrane. So far as we possess any knowledge in regard to the function of this nerve, it takes absolutely no part in the mechanism of hearing. Furthermore, it furnishes the only instance in the human body, so far as I am aware, of a nerve crossing an open air-containing space, without any special protecting covering beyond that afforded by a very thin layer of mucous membrane.

[1] By Politzer first, and then by Kessel, in 1869.

Thus far we have studied the anatomical and physiological relations of the external auditory canal and tympanic cavity, and of the apparatus contained therein for transmitting sound from the outer world to the labyrinth. It now remains for us to give a brief sketch of at least the gross anatomical features of the latter system of cavities.

Anatomy of the Labyrinth.

If we take a human temporal bone, either in its natural fresh condition or in the dried state, and endeavor by simple inspection to get some idea of the form, size, and relations of the labyrinth, we shall fail completely. There are only three points—the oval window, the round window, and the meatus auditorius internus—

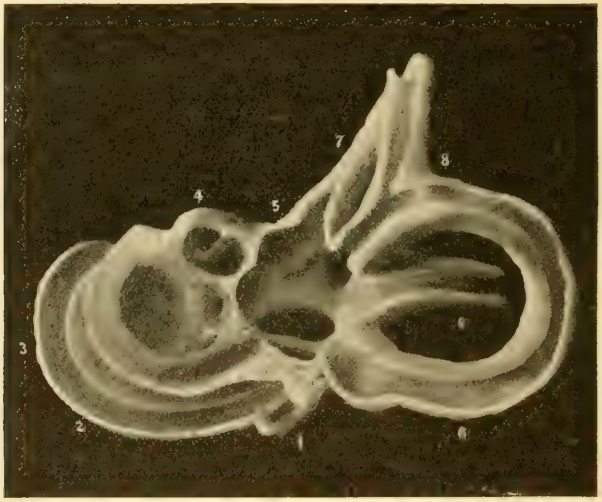

Fig. 137.—The Right Osseous Labyrinth of a New-born Infant, Opened on its Posterior Surface. Magnified about Four and a Half Diameters.

1. The fenestra cochleæ partially opened. The curved projection about 5 mm. distant from the lower edge of the fenestra rotunda (measured on the picture), appears to be the commencement of the outer wall of the cochlea, and the ridge opposite the lamina spiralis ossea represents a prolongation of the lamina spiralis accessoria, to which the lamina spiralis membranacea is attached, as far as the interior of the vestibule. The bony bridge across the commencement of the spiral canal was retained in the preparation because of the attachment of the vestibular end of the osseous spiral lamina to that portion of the wall.

2. The osseous spiral lamina (lamina spiralis ossea) projects 1.5 mm. from the inner wall of the cochlea. At the point of its origin from the wall of the cochlea, it is at first irregular; that is to say, there is a succession of uniform depressions, separated from one another on the under surface of the spiral lamina, by small bony ridges, which gradually disappear toward its free edge.

3. The osseous spiral canal of the cochlea (canalis spiralis cochleæ) is divided by the

where we can get a glimpse of the approaches to this system of cavities. At all other points the various channels and cavities of the labyrinth are deeply embedded in the substance of the petrous portion of the temporal bone. It is only by aid of a hammer, chisel, and knife that we can obtain the thin shell of bone which represents, as it were, the mould of the contained cavities. (See Figs. 136 and 137.) In this way we shall find that the labyrinth —we are speaking now only of its osseous boundaries—consists of a central cavity, from four to six millimetres in diameter, from one side of which spring, like arches, the three semicircular canals, while from the other side a canal leads into the snail-shaped body called the cochlea. In their natural state these bony cavities are filled with membranous structures and fluid. Thus, for example, the central cavity, the vestibule, contains two distinct membranous sacs which together do not quite fill the entire space of the cavity, but leave room, in the immediate vicinity of the foot-plate of the stapes, for a certain amount of free fluid—*the perilymph*. The smaller of the two sacs, the saccule (*S*, in Fig. 138), communicates with one of the membranous channels of the cochlea, the ductus cochlearis (*D.c.*, in Fig. 138). The larger sac, the utricle (*U*, in Fig. 138), is continuous with the membranous tubes which partially fill the osseous semicircular canals. The two sacs just mentioned do not

---

spiral lamina into two passages or scalæ. The lower and broader is called the tympanic, and the upper and narrower the vestibular passage—scala tympani, scala vestibuli.

4. The floor of the internal meatus, with the openings of the commencement of the Fallopian canal and the four depressions of varying size which receive, through the fine perforations (foramina cribrosa), the fibres of the nervus acusticus and the vessels accompanying it into the labyrinth. The three smaller depressions are the maculæ cribrosæ internæ, which receive the vestibular nerves, and the larger spiral-shaped depression marks the base of the cochlea. (In the photograph, unfortunately, the spirally arranged openings [tractus spiralis foraminulentus] lie in deep shadow.)

5. The vestibule (vestibulum osseum) has a height of 6.1 mm., and a breadth of 4.7 mm. In the tympanic wall, thrown somewhat into shadow in the photograph, is the fenestra ovalis, and, toward the right, are the openings which lead into the semicircular canals.

6. The posterior semicircular canal opened from behind, arising by its inferior osseous ampulla, curves upward, and joins the superior or sagittal canal in the common termination which opens into the posterior wall of the vestibule.

7. The superior semicircular canal, opened from behind and above, arises by the superior ampulla from the upper wall of the vestibule, near the figure 5, and curves upward and backward to unite with—

8. The posterior semicircular canal in the common termination.

9. The horizontal semicircular canal, much foreshortened in the plate, arises near the common termination of the two other canals, and re-enters the vestibule below and near the same, with an expansion of its end, which has sometimes the form of an ampulla.

(Copied from the Rüdinger Atlas of the Osseous Anatomy of the Human Ear; translated by Dr. Clarence J. Blake. Boston: A. Williams & Co., 1874.)

communicate with each other directly. From each, however, a narrow membranous duct is given off, and these two unite together, at a short distance from the parent sacs, to form the so-called aquæductus vestibuli (*A.v.*, Fig. 138), or ductus endolymphaticus, which traverses the intervening bone and communicates with the endolymph of the cranial cavity. Another small membranous channel, the canalis reuniens of Hensen, establishes a direct communication between the saccule and the ductus cochleæ (*D.c.*, Fig. 138).

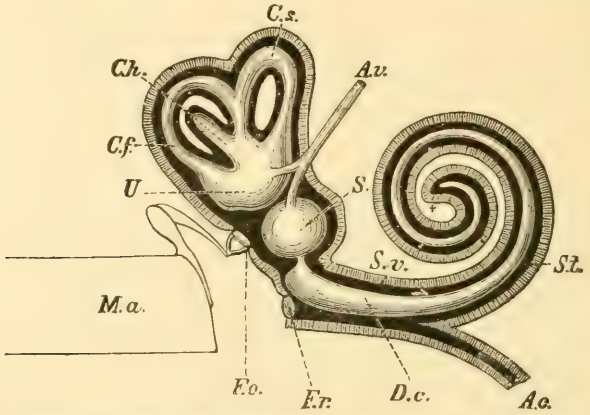

FIG. 138.—Diagram Showing the Relations of the Membranous Structures of the Labyrinth to One Another, to the Surrounding Bony Walls, and to the Transmitting Apparatus of the Middle Ear. (After Arthur Hartmann.) *Ma*, External auditory canal; *U*, utriculus; *Cf*, frontal semicircular canal; *Ch*, horizontal semicircular canal; *Cs*, sagittal semicircular canal; *Av*, aquæductus vestibuli; *S*, sacculus; *Sv*, scala vestibuli; *St*, scala tympani; *Ac*, aquæductus cochleæ; *Dc*, ductus cochleæ; *Fr*, fenestra rotunda; *Fo*, fenestra ovalis.

The mass of fluid (the perilymph) surrounding the saccule and utricle is a direct continuation of that which fills the upper spiral staircase of the cochlea, the scala vestibuli (*S.v.*, Fig. 138), and also—through a small opening at the very top of the cochleal whorl, called the *helicotrema* (see Fig. 139)—with that which fills the lower spiral staircase, the scala tympani (*S.t.*, Fig. 138). A spiral diaphragm separates these two masses of fluid. This diaphragm, which is exceedingly complex in structure, contains within it a small duct filled with fluid—the endolymph—and called the *ductus cochleæ* (*D.c.*, Fig. 138).

These coarser relations of the different cavities, ducts, and masses of fluid contained within the labyrinth may all be made out either with the naked eye or by aid of lenses of feeble magnifying power, and they are well shown in Hartmann's diagram (Fig. 138).

As regards the finer details of the labyrinthine structures, I shall make no attempt to give here more than a very superficial description. The *membranous semicircular canals*, to begin with, present but few peculiarities worthy of note. A cross section of one of them reveals the fact (easily observable in ordinary dissections) that it fills but a small portion, perhaps one-third, of the calibre of the osseous semicircular canal. The inner surface of this membranous canal is lined with columnar epithelium, and this epithelial lining, when not distended by endolymph, is thrown into folds or rugæ. Like every other part of the labyrinth the semicircular

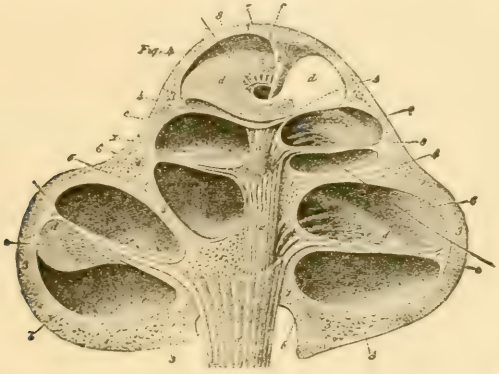

FIG. 139.—Transverse Section of the Human Cochlea in the Plane of the Axis of the Modiolus. (After Breschet.) × circa 12 diameters. *a*, *a*, *a*, Trunk of the cochlear portion of the auditory nerve; *b*, *b*, filaments of this nerve branching off from the trunk and passing into the substance of the lamina spiralis ossea; *c*, *c*, anastomosing nerve filaments; *d*, *d*, lamina spiralis membranacea; *e*, *e*, ligamentum spirale of Henle; 1, 1, 1, osseous modiolus; 2, columella; 3, 3, outer bony shell of the cochlea; 4, 4, partition of bone separating the individual cochleal whorls; 5, 5, tympanic portion of the lamina spiralis ossea; 6, 6, vestibular portion of the same; 7, hamulus; 8, helicotrema. A black bristle is represented as passing from the scala tympani below, through the helicotrema, into the scala vestibuli above.

canals are well supplied with blood-vessels; but nerve filaments have not been discovered in any part of these canals except in the ampullæ.

The *utricle* and *saccule* present no anatomical features of special interest. The saccule is round in form and communicates with the ductus cochlearis through the medium of the canalis reuniens of Hensen. Both in the saccule and in the utricle there is one spot where the wall of the sac is thickened, partly by an increase in the amount of the connective tissue, but also in large measure by reason of the presence of an aggregation of peculiar cylindrical epithelial cells which stand in direct communication with nerve fibres coming

from the ramus vestibuli of the auditory nerve. These spots are called the *maculæ acusticæ*. The free extremities of these epithelial cells are provided with hair-like cilia or rods, and among them are scattered (post-mortem at least, if not during life) the small six-sided crystals of carbonate of lime known as *otoliths*.[1]

There still remains to be considered the *cochlea*, the most complicated and evidently the most essential part of the labyrinth. The auditory nerve, it will be remembered, gains entrance into the

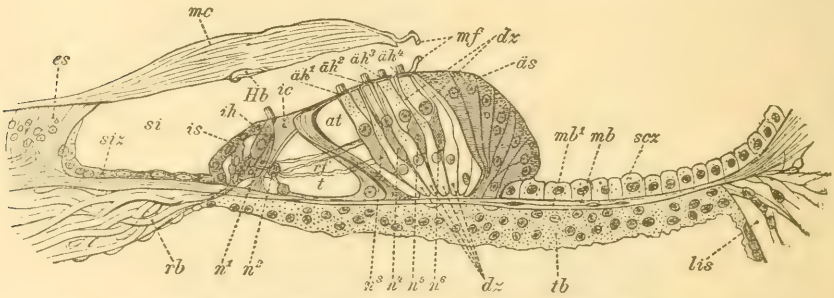

FIG. 140.—Radial Vertical Section of the Papilla Acustica Basilaris or Corti's Organ, from the Middle Whorl of the Cochlea of a Man 29 Years of Age. (After Retzius.) *es*, Limbus laminæ spiralis; *mc*, membrana tectoria or membrane of Corti; *Hb*, Hensen's band; *mf*, fibres which attach the membrane of Corti to the basilar membrane; *si*, sulcus spiralis internus; *siz*, epithelium of the sulcus spiralis internus; *is*, inner epithelial or supporting cells; *ic*, inner pillars, the heads of which articulate with those of the outer pillars; *t*, the tunnel-shaped space under the arch formed by the junction of the inner and outer pillars; *ih*, inner hair or ciliated cells; $äh^1$, $äh^2$, $äh^3$, $äh^4$, four rows of outer hair or ciliated cells; *dz*, Deiters cells, intercalated between the outer hair cells; *äs*, Hensen's supporting cells; *rb*, nerve fibres of the Ramulus basilaris; n^1, n^2....n^6, outer twigs of the spiral nerve fibres; *rf*, radial nerve twigs which cross the tunnel-like space; *at*, inner portion of Nuel's space; *mb*, upper layer of the membrana basilaris; mb^1, lower layer of the membrana basilaris; *tb*, tympanal coating of the membrana basilaris; *lis*, ligamentum spirale.

cochlea by way of the *modiolus*—the cone-shaped standard of bone around which the cochleal channels are coiled spirally. The base of this standard corresponds with the cribriform bottom, or *cul-de-sac*, of the porus acusticus internus; its summit, with the cupola or highest point of the scala vestibuli. The modiolus is traversed lengthwise by countless channels through which run the filaments of the auditory nerve. From the base to the vicinity of the summit of this conical core of the cochlea, nerve filaments are constantly being given off laterally to the spiral diaphragm which separates the two scalæ from each other. Just as the filaments are about to leave the modiolus and enter the substance of the *lamina spiralis*,—

[1] These anatomical relations have been thoroughly investigated by Urban Pritchard (Quarterly Journal of Medical Science, 1876).

the technical name of the diaphragm just mentioned,— they pass through an aggregation of ganglion nerve cells (ganglion spirale). Up to this point, and even beyond it, as far as to the line of junction between the lamina spiralis ossea and the lamina spiralis membranacea, the nerve filaments retain their sheathing (white substance of Schwann, etc.), but after they pass this last point they are encountered only as delicate nerve fibrillæ, like those which are found in the rabbit's cornea.

The spiral diaphragm separating the scala tympani below from the scala vestibuli above is found, on more careful examination, to contain within itself a third channel—the scala or ductus cochleæ, the fluid contents of which bathe the complicated structures known collectively as Corti's organ. It is here that the delicate fibrillæ of the auditory nerve may be traced to their ultimate destination, and it is here, beyond all question, that those sensations are elaborated which reach the brain as impressions of sound.



FIG. 141.—Surface View of the Organ of Corti and the Entire Lamina Velamentosa (=lamina reticularis). (After Deiters.) *a*, Huschke's hearing teeth (Corti's first row of teeth); *b*, bundles of dark-bordered nerve fibres; *c*, openings of the habenula perforata; *d*, vas spirale; *e*, first row of Corti's fibres (=inner pillars); *f*, pars membranosa of the lamina reticularis; *g*, line of union of the first and second rows of Corti's fibres (*i.e.*, of the inner and outer pillars); *h*, the second row of intermediate connecting pieces; *i*, second row of Corti's fibres; *k*, rods; *l*, first row of phalanges; *m*, second row of phalanges; *n*, *n*, *n*, the three rows of circles with their inner arches; *o*, the first row of rectangular frames; *p*, two additional rows of rectangular frames (these are sometimes lacking); *q*, connective-tissue framework supporting the large cells (*r*).

The more important individual histological elements entering into the formation of Corti's organ are the following:

1. The *lamina spiralis membranacea*, or the *membrana basilaris*. —This membrane, which is attached along its inner border to the outer edge of the lamina spiralis ossea, and is inserted into that part of the outer wall of the cochlea which is known as the *ligamentum spirale* (Fig. 139, *e*), is subdivisible into three zones, viz., the inner, the middle, and the outer zones. The inner zone is extensively perforated, to permit the passage through it of nerve filaments from the auditory nerve; hence its name, *zona perforata*. The middle zone is that part of the membrana basilaris which affords immediate support to the organ of Corti; it is called the *zona arcuata*. The outer zone is finely striated in a direction at right angles to the long axis of the membrane; that is, as if the striæ radiated from the central axis of the modiolus.

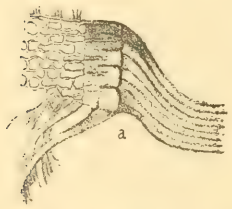

FIG. 142.—Detached Fragment of Corti's Organ, showing the upper parts of the inner and outer pillars, and a portion of the lamina velamentosa or reticularis. At one part of the latter the cilia of the hearing cells still remain attached. (After Deiters.)

2. A series of stiff but elastic rod-like bodies which occur in two rows and are so disposed as to form an arched way above the membrana basilaris. These are the *outer* and *inner pillars of Corti* (also known as *Corti's fibres* or *rods*).

In their anatomical relations these pillars present one or two peculiarities which throw some light upon their physiological function: their bases are firmly anchored to the membrana basilaris, while their upper ends or heads articulate one with another—each inner pillar with its corresponding opposite outer pillar—in such a manner as to suggest for these parts the very sort of vibratory motion (in an up-and-down direction) which on theoretical grounds has been attributed to them.

3. A peculiar fenestrated membrane, the *lamina reticularis*, which extends in a horizontal direction some little distance outward from the heads of the pillars of Corti, to which it seems to be in some way attached.

4. Five rows of ciliated cells, four on the outer side of the arch, and one on the inner side, close to the inner pillars of Corti. The four outer rows insert their heads into the openings of the fenestrated lamina reticularis in such a manner that the cilia stand up like fine but short rods at regular intervals along the surface of the membrane. Bundles of primitive nerve-fibrils from the cochleal branch of the auditory nerve have been traced to all five rows of

ciliated cells, but to no other structures in the ductus cochlearis. Hence the name of *hearing cells* which has very appropriately been awarded to these evidently the most important elements in the apparatus we are endeavoring to describe.

5. Simple epithelial cells, destined apparently to serve as a support to the lamina reticularis and to the outer and inner rows of hearing cells.

6. A peculiar membranous structure, which starts from the upper side of the hooked-shaped process of the *lamina spiralis* and

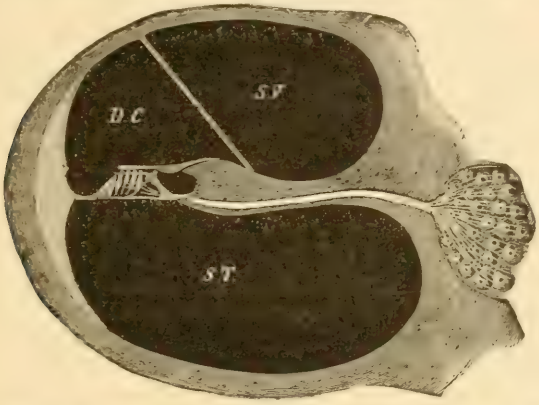

FIG. 143.—Transverse Section of a Cochleal Whorl (diagrammatic). On the right, embedded in the substance of the bone, is a group of ganglion cells, through which the fibres of the auditory nerve pass before entering the lamina spiralis ossea. This latter is represented in the figure as a broad septum separating the scala vestibuli (*S.V.*) from the scala tympani (*S.T.*), and containing a canal for the passage of the auditory nerve filaments. The latter, on emerging from the lamina spiralis ossea, pass in part directly to the inner row of hearing cells, and in part beneath the arch of Corti's pillars to the four outer rows of hearing cells. The cilia belonging to the latter may be seen projecting through the lamina reticularis; those of the single row of inner hearing cells project above the head of the inner pillar of Corti. The lamina reticularis is drawn as a horizontal projection (outward) of the upper portion of the head of the outer pillar of Corti. Above, the cilia of the hearing cells are covered by the membrana tectoria or Corti's membrane, which springs from the outer hook-shaped edge of the lamina spiralis ossea and terminates at a point in the immediate vicinity of the outermost row of hearing cells. The space bounded below by the organ of Corti (membrana basilaris and superimposed structure) and above by Reissner's membrane (represented in the drawing by a straight band which extends from the bony wall of the cochlea downward and inward to the upper side of the lamina spiralis ossea), is called the ductus cochleæ (*D.C.*).

extends outward over the lamina reticularis. This membrane is mucoid (or doughy) in consistency, and, from the fact that it lies like a gelatinous veil over, and perhaps in contact with, the cilia of the hearing cells, it is called the *membrana tectoria* or covering membrane—also *Corti's membrane*. As far as to the outer limit of the hearing cells, this membrane retains its thick, doughy consist-

ency. From the appearance of the parts it is believed that in its natural state the membrana tectoria does not terminate in a free border, but is attached to the underlying cellular structures at some point beyond the limit of the outermost row of hearing cells. By

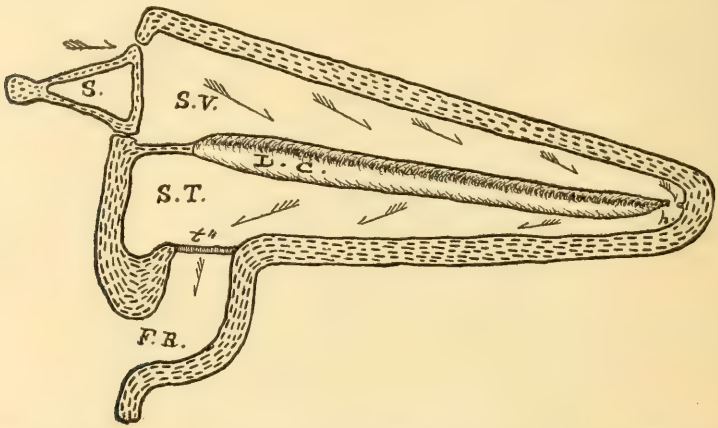

Fig. 144.—Diagram Showing the Mechanical Effects of an Inward Excursion of the Foot-plate of the Stapes upon the Different Structures and Bodies of Fluid Contained in the Cochlea.

When the foot-plate of the stapes (*S*) presses upon the perilymph contained in the scala vestibuli (*S. V.*) it causes the latter to push the entire elongated sac, called the ductus cochlearis (*D. C.*), down toward the scala tympani (*S. T.*). This downward pressure on the part of the cochleal duct in turn causes a corresponding displacement of the perilymph contained in the scala tympani, the ultimate result of which is to force the secondary tympanic membrane (*t''*) in the fenestra rotunda outward toward the tympanic cavity. In this disturbance of the various intralabyrinthine masses of fluid an insignificantly small amount of perilymph doubtless passes from the scala vestibuli through the helicotrema (*h*) into the scala tympani; this amount being unquestionably too small to materially diminish the breadth of the excursion made by the sac composing the cochleal duct (and containing the long keyboard of organs of Corti), in a direction at right angles to its long axis.

several authorities it is maintained that fibrils pass from the under surface of the membrana tectoria to the upper extremity of each hearing cell belonging to the four outer rows.

7. A thin, membranous diaphragm, separating the scala cochleæ from the scala vestibuli, and known as *Reissner's Membrane*.

Mode of Action of the Labyrinthine Mechanism.

It is a difficult task to build up a theory which shall explain satisfactorily what takes place, in the act of hearing, in all these different labyrinthine structures. Helmholtz's theory, which makes this act to depend upon the sympathetic vibration of the organs of

Corti, and attributes to Corti's membrane (Pritchard's membrana tectoria) the function of a damper upon such vibrations, is undoubtedly the correct one, so far as it goes; but it does not go far enough to satisfy one's hunger for knowledge in regard to this question. Unfortunately, the problem is of such a character that we can scarcely hope for such a thing as precise knowledge in regard to its solution, but must rest satisfied with hypotheses which are at most mere amplifications of the Helmholtz theory and of those put forward by Hensen and by Boettcher. There are, however, a number of important points in regard to which the best authorities are agreed.

Thus, for example, I believe that very few will dispute the statement that the impulses of sound reach the cochlea by way of the fenestra ovalis; that the foot-plate of the stapes, after the fashion of a piston, imparts individual shocks to the perilymph which fills a large part of the vestibule and the channel which is called the scala vestibuli; that these shocks, being given to an incompressible mass of fluid, are transmitted without appreciable loss to Reissner's membrane throughout its entire length—or, in other words, to the endolymph contained within that three-sided tube called the ductus cochlearis; that from the membranous part of the under surface of this tube—*i.e.*, from the lamina spiralis membranacea—these shocks are in turn transmitted to the perilymph which fills the scala tympani; and, finally, that each individual displacement of this last-named mass of fluid (corresponding to each individual shock or outward phase of a vibratory excursion) finds the amount of space required for such displacement at the tympanic end of the scala tympani, at which point the secondary tympanic membrane is pushed outward by the perilymph to just the extent which may be necessary for providing this required amount of space. Doubtless the elasticity of all the parts displaced by this excursion inward of the foot-plate of the stapes furnishes all the force required for their return to a condition of rest or equilibrium. Furthermore, few will to-day dispute the necessity of some such contrivance as the helicotrema—the narrow passage of communication, in the cupola, between the scala tympani and the scala vestibuli—for the preservation of the required equilibrium between the pressure exerted from above (scala vestibuli) and that exerted from below (scala tympani) upon the ductus cochlearis, and also, at the same time, for the maintenance of a uniform specific gravity between these two large bodies of perilymph. On the other hand, this chan-

nel of communication is so narrow that, with each impulse communicated by the stapes, little or no longitudinal displacement of the perilymph—that is, little or no current in a direction parallel with the ductus cochlearis—can take place. In other words, the stapedial impulses will be felt, along the entire length of the ductus cochlearis, as a force acting chiefly at right angles to its long axis. If we study the relations of the component parts of Corti's organ—that complicated and most delicate piece of machinery which rests upon, and makes a part of, the floor of the cochleal duct—we shall find that they are of such a nature that vibration cannot take place in them except in one direction, viz., up and down, or in a plane which cuts the long axis of the duct at a right angle. Thus, for example, the membranous lamina spiralis—or the membrana basilaris, as it is also called—is not a homogeneous membrane like the membrana tympani, but is composed of separate narrow bands or fibres, which run at right angles to the long axis of the duct, are placed side by side like the individual keys of a piano, and are feebly glued together, edge to edge, by an interfibrillar glueing material. These, therefore, can only vibrate in planes which cut the duct at a right angle. Then again, the cilia of the hearing cells do not project free into the endolymph, but are, as it were, blanketed by the dough-like membrane of Corti. All lateral motion on their part, therefore, is entirely out of the question. The hearing cells themselves stand in a nearly upright position upon the membranous lamina spiralis, and they are arranged in such a manner that to each band-like or cord-like subdivision of the lamina spiralis a row of four hearing cells is assigned—one upon the inner side of the arch and three upon the outer side. From the summit of the arch a lattice-like framework projects, and into each opening in this comparatively rigid framework the upper end or neck of a hearing cell fits. The arch itself is formed by the junction of two inclined pillars, whose bases are firmly amalgamated with the lamina spiralis; each separate band of the lamina being provided with its own individual arch. All these anatomical arrangements, as it seems to me, utterly forbid the idea of anything like vibration from side to side.[1] On the other hand, the mode of union between the head of the inner and that of the outer pillar is of such a nature as to favor strongly the idea of an up-and-down vibration of the organs of Corti. This mode of union suggests that of the two halves of an

[1] Boettcher, for example, maintains that the sensation of sound is produced by the transverse vibration of the hearing cells.

ordinary hinge; and this hinge-like union is so arranged, in the case of the inner and outer pillars of a Corti's organ, that the only play possible is that which would result from an up-and-down vibration of the whole complex structure. All the anatomical features of the cochleal apparatus seem, therefore, to be in perfect harmony with the hypothesis of vertical vibrations, and with these alone.

But even if this point be conceded, there still remain other equally difficult problems which demand a solution. One of these, for instance, relates to the *modus operandi* of the membrane of Corti, another to the application of the principle of sympathetic vibration to separate portions of the lamina spiralis with their superimposed structures, a third to the way in which the ultimate fibrillæ of the cochlear portion of the auditory nerve are stimulated by sonorous vibrations, and so on. The parts to which these problems relate are so closely connected that it is scarcely possible to discuss their mode of action separately. I shall therefore restrict my further remarks upon the mechanism of the cochleal apparatus to a consideration of the action of these different parts in combination.

If we reduce the problem of hearing—that is, of the perception of sound—to its simplest form, the question presents itself in these terms: What influence does a simple fundamental musical tone, shorn of all its overtones, exert upon the cochleal apparatus, and how is a special sensation, corresponding to that particular tone, conveyed to the brain? Let us assume that a musical tone of about one hundred vibrations (G♯, for example) is produced in the neighborhood of a normal ear. The stapes receives these one hundred shocks and transmits them to the perilymph in the scala vestibuli. In correspondence with these shocks the ductus cochlearis is displaced throughout its entire length, from the vestibule to the cupola, one hundred times; this excursion taking place in the direction of the scala tympani and causing a compensatory displacement of the perilymph contained in that channel. Every one, therefore, of the thirteen thousand or fourteen thousand individual strings[1] of the spirally disposed collection of Corti's organs must, in response to these shocks, likewise perform these one hundred up-and-down excursions. The dough-like but yet elastic membrane of Corti, resting as it does upon the cilia of the countless hearing cells be-

[1] Variously estimated by different authorities. Hensen's latest estimate (1871) places them at 13,400.

longing to this long array of Corti's organs, must also necessarily be subjected to this same up-and-down excursion, in precisely the same manner as it would be if it formed an integral part of these organs and were not merely spread out over them like a blanket.

Inasmuch as a slender nerve fibril is supplied to every one of the hearing cells, and to no other structures in the complicated mechanism called Corti's organ, we are justified in drawing the inference that it is upon these hearing cells that the peculiar influence is brought to bear which causes an excitation of the attached nerve fibril, or, in other words, which causes a sensation of sound to be transmitted to the brain. The question, therefore, which requires next to be considered is that relating to the nature of this particular influence. If we examine the structure and relations of the hearing cells, we find that they possess the following characteristics: first, the long axis of each cell invariably runs at nearly a right angle to the plane of Corti's membrane or to that of the membrana basilaris; second, its upper extremity is provided with rod-like cilia of a rather rigid character, unlike those which are seen in other parts of the body and which habitually move in a horizontal direction (that is, a direction at right angles to the long axis of the cell); third, these rod-like cilia furnish a direct support to the overlying membrane of Corti; and, fourth, the lower extremity of each cell is firmly attached to one of the numerous fibres or cord-like subdivisions of the membrana basilaris. These last structures are evidently the only distinctively vibratory elements in the complex mechanism of the cochlea. They alone, of all the cochleal structures, manifest evidences of adaptation to the function of spontaneous vibration, or of vibration at certain fixed rates of speed. They are tensely stretched, and their length at the cupola is several times (twelve times, as estimated by Hensen) as great as it is at the vestibule. These differences in length certainly favor the idea that the individual units of this series of stretched strings are tuned to vibrate in sympathy with all the known tones of the musical scale; those answering to the deepest tones being located near the cupola, while those which are tuned to the highest pitch occupy the vestibular end of the basilar membrane. Accustomed as we are to think that a deep tone can only be produced by a cord of considerable length, it is indeed a difficult matter to believe that a tense fibre that measures only three or four millimetres in length can by any possibility be brought to vibrate in sympathy with the deeper tones of the musical scale; or indeed, for that matter, to vibrate in sym-

pathy with even the higher ones. We are forced, in the presence of this difficulty, to assume that the principle of the loaded string



FIG. 145.—Diagram Representing a Longitudinal Section of the Ductus Cochlearis, and Including Only its More Important Structures. *f*, Reissner's membrane; *e*, membrane of Corti, or the membrana tectoria; *d*, rod-like cilia of the hearing cells; *c*, membrana reticularis, or membrana velamentosa; *b*, hearing cells, the only cochleal structures which have any connections with nerve fibres; *a*, individual bands or cords (seen in cross section) of the membrana basilaris. For the sake of greater clearness the glue-like material which binds these cords together into a continuous membrane has been omitted in the diagram. The arrows indicate the direction in which motion takes place during an inward excursion of the stapes. (For further details see the main text).

furnishes the true explanation of how such sympathetic vibration may take place.

After these brief explanatory remarks we may return to the consideration of the question of what constitutes a specific stimulus of

an auditory nerve fibril. Hensen's belief[1] is, that a blow upon the terminal ends of the cilia of a hearing cell furnishes this stimulus. The way in which such a blow or series of blows is brought about is the following:

A musical tone of say one hundred vibrations to the second is produced, and in consequence the entire membrana basilaris, with all its superimposed structures, will vibrate at precisely the same rate in an up-and-down direction. Almost everywhere throughout this long stretch of membrane these vibrations are merely passive in character; that is, they occur in response to a series of pushes from above downward which recur at the rate of one hundred in every second. The membrane of Corti, wherever this passive kind of vibration is going on, remains in contact with the cilia which support it, and follows their up-and-down excursions as if it were glued to their extremities. But there is one part of this long, spiral membrana basilaris where the individual fibres which compose it perform these up-and-down vibrations in a much more vigorous fashion. This they do by reason of the fact that they are tuned so as to vibrate in sympathy with a tone of one hundred vibrations per second; and, as a result of this extra-vigorous vibration, the dough-like membrane of Corti, not being attached to the hearing cells, but simply resting by its own dead weight upon their projecting cilia, is no longer capable of following these excursions throughout their full amplitude. In other words, in each one of these excursions there is an instant of time when the membrane of Corti is lifted off the ends of the cilia; and consequently the return of this membrane to its previous position of contact must be accompanied by a tap or blow upon the free ends of the cilia. This is the way, as it

[1] Hensen, in his treatise on the morphology of the human cochlea (Zeitschrift für wissensch. Zoölogie, Bd. xiii., December, 1863) gives expression to essentially the same view as that which I have here stated. Although I have not been able to gain access to a copy of this treatise, I find the following reference to the point in question in an article which he has published in vol. vi. of the Archiv für Ohrenheilkunde (p. 31): "Ich glaube nämlich, wie ich in meiner Arbeit über die Schnecke (S. 507) schon mittheilte, dass die Gehörsempfindung in der Schnecke dadurch vermittelt werde, dass die Stäbchen der Gehörszellen durch Schwingungen (der Saiten) der Membrana basilaris gegen die Membrana Corti, welche als Fremdkörper auf ihnen ruht, gestossen werden. Dass die Stösse nicht zerstörend wirken, dafür sorgt, meine ich, der zwischen sie und die Membran eingeschaltete zierliche Apparat der Bögen, welcher bekanntlich den unvollkommneren Wirbelthieren nicht mehr zukommt. Um nun diese Stösse zur Wahrnehmung zu bringen, dürften diese an die Tastkörperchen erinnernden Kapseln dienen können."

seems reasonable to suppose, in which the hearing cells are stimulated to send impressions of sound to the brain.

Something similar to this momentary throwing-off of Corti's membrane may be observed in the familiar experiment of placing little riders of paper upon a stretched violin string. Those which are placed at the chief nodal-points are so little disturbed by the vibrations that they generally do not fall off, whereas those which are placed astride the string at other points are usually thrown violently from it as soon as the bow is brought into play. What takes place at the nodal-points of a vibrating violin string may therefore serve to illustrate the relations which probably exist in all those organs of Corti which are undergoing simple passive vibrations. On the other hand, the violent dismounting of the paper riders at other parts of the vibrating string furnishes an exact analogue of what I believe must take place in the case of those comparatively few fibres which are undergoing sympathetic vibrations. Let us assume, for the sake of illustrating this point more fully, that sixteen separate cords or bands of the membrana basilaris belong to each half-tone of the musical scale.[1] In Fig. 145 a series of twenty-eight of these bands is represented. The first six may be assigned to the last part of the series belonging to the tone G natural; then, next to these, come all the sixteen belonging to the tone G sharp; while at the end of the series are placed the first six cords of the tone A natural. During the intonation, upon some musical instrument, of the tone G sharp, sympathetic vibration will occur in those bands which are designated in the figure as $G^{1\equiv}$, $G^{2\equiv}$, etc., while those which are marked G^{11}, G^{12}, etc., and A^1, A^2, etc., will be subjected to simple passive vibrations. These different kinds of vibratory movement are represented graphically in Fig. 146, on the next page.

There is still another point which must not be forgotten. I refer to the fact that the number of individual organs of Corti is so large that we may safely assign at least thirty or forty of them to each half-tone in the ordinary musical scale. This means that the production of a single simple musical tone never excites to sympathetic vibration a single organ of Corti, or even three or four of them, but always a group of at least thirty or forty consecutive fibres or organs. Those occupying the centre of such a group ($G^{7\equiv}$, $G^{8\equiv}$, and $G^{9\equiv}$, for example, in Fig. 145) will vibrate most vigorously, for they are always the ones which are most perfectly tuned,

[1] As a matter of fact, there must be over thirty of them for each half-tone.

while those situated at the two extremes ($G^{1}\sharp$ and $G^{16}\sharp$) will be the least agitated, inasmuch as their tuning is the most imperfect. The mechanical result of this state of affairs must be a wave-like disturbance of a limited area of the membranous lamina spiralis.



G *G*♯ *A*

Fig. 146.—Diagram Showing the Difference between Sympathetic and Passive Vibrations. At *G* and *A* the vibrations are passive in character, while at *G*♯ they are extra-vigorous, by reason of the fact that the cords which produce them are tuned to precisely the same pitch as that of the tone which excites them to vibration.

The time has not yet arrived when we may, with any degree of confidence, formulate a theory as to what is the mechanism of the structures located in the semicircular canals. Suffice it to say, therefore, that the consensus of opinion favors the view that the organ of equilibrial sense resides in this part of the labyrinth, and that its more important structures are located in the parts which are known as the ampullæ (Fig. 137, 6 and 7).

VASCULAR RELATIONS OF THE DIFFERENT PARTS OF THE EAR.[1]

The arterial supply of the auricle and external auditory canal is derived entirely from branches of the external carotid artery. The most important of these is the *posterior auricular artery*, which supplies the posterior aspect of the auricle, the neighboring part of the cartilaginous external auditory canal, and that part of the fossa conchæ which is situated farther back than the meatus auditorius. The arterial twigs which supply this latter region pass directly through the intervening cartilaginous framework of the auricle. Another arterial branch of importance is the superficial temporal artery. This vessel gives off the *anterior auricular arteries*, which supply the lobule, the tragus, the anterior wall of the cartilaginous portion of the external auditory canal, and the anterior and upper part of the helix. On the other hand, the medial portion of the cartilaginous external auditory canal, the entire osseous portion, and the cutaneous covering of the membrana tympani receive their blood supply from the *auricularis profunda*, which is a branch of the arteria maxillaris interna.

[1] The following account of the vascular relations of the different parts of the ear is taken mainly from Berthold's article in vol. i. of Schwartze's "Handbuch der Ohrenheilkunde," Leipzig, 1892. The part relating to the labyrinth is from Siebenmann's contribution to Bardeleben's "Handbuch der Anatomie des Menschen." Jena, 1898.

The tympanic membrane receives its blood supply partly from the auricularis profunda, as just stated, and partly from the arteria tympanica.

The veins of the external ear usually follow the same course as do the corresponding arteries. The anterior auricular veins pour their blood into the superficial temporal vein, the posterior auricular into the external jugular, and the deep auricular into the internal maxillary, by way of the pterygoid plexus.

The cuticular veins of the membrana tympani empty the larger part of their blood into the veins of the external auditory canal, but nevertheless they may—through certain branches which penetrate into the tympanum—pour it into the veins of that cavity. On the mucous surface of the membrana tympani the veins radiate from the periphery toward the manubrium, and *vice versa*, from the central portions toward the periphery. Around the border of the membrane the venous trunks are clustered together in the form of a wreath. At various points perforating branches connect this venous circle with the similar one which exists on the cutaneous side of the membrane.

The tympanic cavity is supplied with blood from as many as five different sources, viz., the stylo-mastoid, the middle meningeal, the ascending pharyngeal, the internal carotid, and the anterior tympanic arteries. The *stylo-mastoid artery*, itself a branch of the posterior auricular, gives off twigs which supply the mastoid region, the vicinity of the stapes, and the posterior end of the tympanic cavity. The *middle meningeal artery* (a branch of the internal maxillary) gives off three twigs: one for the tensor tympani muscle, a second (the superior tympanic artery) for the mucous membrane covering the upper part of the promontory, and a third (the ramus petrosus superficialis) which anastomoses with the stylo-mastoid artery. The *ascending pharyngeal artery* gives off twigs which supply the floor of the tympanic cavity and the lower part of the promontory. The *internal carotid artery* gives off a branch, the ramus carotico-tympanicus, which supplies the anterior wall of the tympanic cavity. There is also another small twig which passes between the crura of the stapes on its way to the promontory. Von Troeltsch attaches some importance to this arterial twig as the probable source of some of the pulsating subjective noises complained of by patients. The *anterior tympanic artery*, a branch of the internal maxillary, supplies the processus Folianus of the malleus, the ligamentum mallei anterius, and—in connection with twigs

of the stylo-mastoid artery—the mucous membrane of the membrana tympani.

Politzer describes anastomoses between the blood-vessels of the tympanic cavity and those of the labyrinth, but Eichler maintains that they do not exist. Siebenmann, who has recently made a

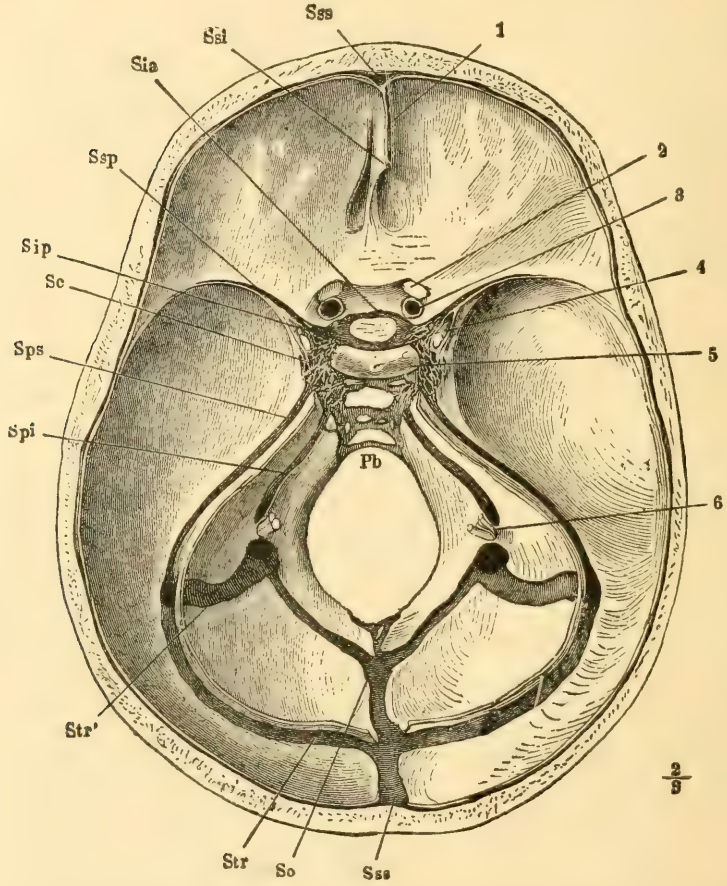

FIG. 147.—Internal View of the Base of the Skull, Showing the Relations of the Venous Sinuses. (After Henle.) 1, Horizontal section of the falx cerebri; 2, optic nerve, divided at the entrance into the optic canal; 3, trunk of the internal carotid artery; 4, oculomotor nerve; 5, dorsum of the sella turcica; 6, nerves projecting from the jugular foramen; *Sss*, *Ssi*, the superior and inferior sagittal sinuses, seen in cross section; *Sia*, *Sip*, the anterior and posterior intercavernous sinuses, including the hypophysis between them; *Ssp*, the spheno-parietal sinus; *Sc*, the cavernous sinus; *Sps*, *Spi*, the superior and inferior petrosal sinuses; *Str*, *Str*^{1}, the transverse sinus, or lateral sinus, or sigmoid sinus; *So*, the occipital sinus; *Pb*, the basilar plexus. (Reduced about ⅓.)

thorough examination of the vascular relations of the labyrinth, confirms the statement of Politzer.

The mastoid cells are supplied with blood by branches of the stylo-mastoid and middle meningeal arteries; the latter passing through the petro-squamous suture on their way from the cranial cavity.

The Eustachian tube receives its blood supply from the ascending pharyngeal, middle meningeal, and Vidian arteries.

The veins of the tympanic cavity pour their blood into the middle meningeal vein, the pterygoid plexus, and the deep auricular vein. Minute veins also pass from the mastoid region (antrum and pneumatic cells situated farther back) to the superior petrosal and the sigmoid sinuses.

The blood supply of the labyrinth is derived from a single main trunk (a branch of the basilar artery), which enters the porus acusticus internus along with the auditory nerve, and subdivides into three branches: the arteria vestibularis (anterior), the arteria cochlearis (propria), and the arteria vestibulo-cochlearis. The *arteria vestibularis* supplies the anterior and upper half of the vestibule together with the ampullæ and semicircular canals located at this end of the cavity. It also supplies the posterior half of both the utriculus and the sacculus. The *arteria cochlearis* supplies the larger part of the cochlear structures; whereas the *arteria vestibulo-cochlearis* furnishes blood to only the lower part of the cochlea, to the posterior and lower half of the vestibule, and to the posterior ampullæ and the semicircular canals which terminate in this part of the vestibule. The venous blood escapes from the labyrinth by three different routes: 1, through the vein which passes through the aquæductus vestibuli; 2, through that which passes through the aquæductus cochleæ; and 3, through the venous plexus which is located in the porus acusticus internus. Acording to Henle, the venous blood from the latter source finds its way into the inferior petrosal sinus. I might venture to add that inasmuch as it is now conceded that anastomosis takes place between the blood-vessels of the labyrinth and those of the tympanum—these vessels piercing the ligamentum annulare of the foot-plate of the stapes, as noted first by Politzer and then by myself[1]—we are warranted in maintaining that any interference with the venous circulation of the tympanic cavity may make itself felt in that of the labyrinth.

[1] Article entitled "On the Mechanism of the Ossicles," in vol. i., No. 2, of the Archives of Ophthalmology and Otology, New York, 1870.

GENERAL INDEX.

Abscess cavity, washing out of, in the brain, 514
Abscesses, intravenous, in the neck, 462
Acetic acid, glacial, employment of, as a caustic, 356
Acid nitrate of mercury, employment of, as a caustic, 356, 391
Acoumeter, Politzer's, 5
Acromegaly, relationship of, to adenoid vegetations, 262
Adams' septal forceps, 290
Adenoid vegetations in the vault of the pharynx, 254
  facial expression characteristic of, 259
  influence of, upon the organs of hearing, 264
  operative removal of, 272
Adhesions between membrana tympani and inner wall of tympanum, 71, 77, 366
Aërostatic conditions of the middle ear, habitual, 542
Agnew, C. R., 97
Allen, Harrison, 256
Alum, powdered, introduction of, into the tympanic cavity, 326
Ambos and malleus, relations of, to each other and to the surrounding parts, 543
Ampullæ of the semicircular canals, 555
Anæsthetics, necessity of employing, when paracentesis of the membrana tympani is performed, 316
Analysis of aural symptoms, 47
Anatomical peculiarities, influence of, in determining the course of an acute inflammation of the middle ear, 42, 292
Anatomical relations of the middle ear, 203
Anatomy of the auricle, 82
  of the external auditory canal, 542
  of the labyrinth, 547, 554
  of the middle ear, 542
Aneurism, cirsoid, of the auricle, 99
  false, of the posterior auricular artery, as a result of a Wilde's incision, 316
Angeio-neurotic œdema of the tongue, following cauterization of the tympanic membrane with chromic acid, 357
Angelo's ear-douche, 30, 322
Angioma cavernosum of the auricle, 99
Angiomata of the middle ear, 388
Angular forceps, 22
Annular ligament of the stapes, 547
Annulus tympanicus, 17, 18
Anterior auricular arteries, 570
  tympanic artery, 571
Antihelix, 82
Antisyphilitic treatment in cases of supposed labyrinthine disease, 530, 531, 533, 541
Antitragus, 82
Antrum of Highmore (antrum maxillare), suppurative disease of, a cause of chronic catarrhal inflammation of the middle ear, 243
Antrum, the mastoid, 404
  cholesteatoma of, 499, 501
Apoplectiform deafness, 518

Apoplectiform deafness, occurrence of, during pregnancy, 522
Aprosexia, 262
Aquæductus cochleæ, 556
vestibuli, 556
Aristol, usefulness of, in the treatment of foul conditions of the middle ear, 360
Arnold, Julius, 548
Arnold, J. W. S., 552
Arslau, 266
Arteria cochlearis, 573
Arteria r. axillaris interna, 570
Arteria vestibularis, 573
Arteria vestibulo-cochlearis, 573
Arthritis of the temporo-maxillary joint, 60
Artificial drum-membrane, 371
forced into the middle ear through a perforation in the membrana tympani, 373
Ascending pharyngeal artery, 571
Asch's nasal gouge and blunt-pointed elevator, 288
Asch's scissors, 289
Asch's vulcanized rubber nasal tubes, 290
Aspergillus, growth of, in the external auditory canal, 112, 142
Aspirator needle, for use in puncturing the brain, 512
Atrophy of the tympanic membrane, 70
Audition, limited range of, 536
Auditory canal, anatomical peculiarities of, at different ages, 17
anatomical relations of, 542, 570
bands and membranous structures in, 144
blood supply of, 570
carcinoma of the, 171
caries of bony walls of, 131
cysts of, 177
desquamative inflammation of, 138
false membranes in the, 144
foreign bodies in the, 155
growth of aspergillus in, 142
Auditory canal, localized syphilitic periostitis in, 532, 535
myxo-fibroma of, 177
osteoma of, 166
outward, horizontal motion of epidermis in, 149
parchment-like diaphragm in, 146
relations of gout or lithæmia to inflammations of, 130
sarcoma of, 173
syphilitic ulcers and condylomata of the, 151
wounds and injuries of, 164
Auditory nerve, cochlear filaments of, 557
diseases of, 516
Auricle, anatomy of, 82, 570
angioma cavernosum of, 99
burns of, 101
chondromalacosis of the, 86
cirsoid aneurism of, 99
cleft lobule of, 100
congenital malformations of, 102
drooping of, after a mastoid operation, 442
eczema of, 82
epithelioma of, 97
fibroid tumors of, 96
frost-bite of the, 91, 92, 101
hæmatoma of the, 86
herpes zoster of, 102
horny growth of, 98
lupus of, 99
operative displacement of, for the removal of a foreign body from the auditory canal, 160
perichondritis of, 86
simple diffuse inflammation of, 85
syphilitic ulcerations of, 99
wounds and contusions of, 100
Auricularis profunda, 570
Axis-line of rotation of the malleus, 544

Bacon, Gorham, 314, 349, 396, 491
Bacon's apparatus for local blood-letting, 314

Bacteria of decomposition, part played by, in chronic mastoid disease, 447
Bacterial organisms, influence of, in the causation of suppurative inflammations of the middle ear, 293
Barr, of Glasgow, 503
Basilar membrane, 558
Basilar plexus of veins, 572
Beckman, 255, 261, 264
Beekman, J. N., 101
Benzoated oxide of zinc ointment, in the treatment of eczema of the auricle, 85
Berthold, 570
Bertolet, 96
Bezold, 11
Bezold's symptom, in mastoid disease, 416
Bicarbonate of soda, as a solvent of hardened cerumen, 112
Blake, Clarence J., 96, 103, 112, 149, 155, 555
Blake's polypus-snare, 352
Bleeding from the ear, importance of, as a symptom of fracture at the base of the skull, 382
Bloodletting, local, in acute inflammations of the middle ear, 314
in eczema of the auricle, 84
Blood-sac on the outer side of the membrana tympani, 209
Blood-supply of different parts of the ear, 570
Body-temperature in cerebral abscess, 491
in mastoid disease, 417
Boettcher's theory in regard to the mode of vibration of the cilia of the hearing cells, 564
Boiler-makers' deafness, 49, 242, 519
Bollinger, 516
Bone-caries, a common cause of chronic suppurative inflammation of the middle ear, 329
treatment of, 361
Bone-chisels, Schwartze's, 436
Bone disease of gouty origin, 134
Bone rongeur forceps, 439
Bone structures, operative work upon, 434
Bone substance, growth of, in the external auditory canal, 166
Borolyptol, beneficial effects of, when used as a nasal spray, 283
Bosworth, Francke H., 262
Bosworth's saw, 287
Brain abscess, 488
Brain symptoms in mastoid disease, 418
Brandegee's adenoid forceps, 272
Breschet, 557
Bright spot on the membrana tympani, shortening of, 74
Brown-Séquard, 529
Brunner, 91, 94
Bubbles of air encaged in tympanic cavity, 223, 225
Bulging of the membrana tympani, 207
Bulla tympanica of the dog, 551
Bullet wound of the ear, 378
Burnett, Charles H., 97, 98, 102, 149
Burns of the auricle, 101

Calcareous deposits in the membrana tympani, 68, 366
Calcareous material in the external auditory canal, 131, 133
Calomel, internal administration of, in acute inflammations of the middle ear, 311
Canal of Fallopius, 555
Canalis reuniens of Hensen, 556, 557
Canalis spiralis cochleæ, 554
Carcinoma of the external auditory canal, 171
of the middle ear, 395
Caries of the external auditory canal, 131
of the middle ear, 329, 331, 341
Carlsbad treatment of goutiness, 238
Carotid artery, erosion of, in chronic caries of the temporal bone, 449
Catarrhal inflammations of the middle ear, 205
Catheterization of the Eustachian tube, 189, 195, 214

Caustic potassa, employment of, for softening impacted cerumen, 112
Caustics, employment of, in the treatment of adenoid vegetations, 270
Cavernous sinus, 572
Cerebellar abscess, 489, 494, 498, 515
Cerebral abscess, 488
Cerebral embolism simulating labyrinthine disease, 527
Cerebro-spinal meningitis, epidemic, as a cause of labyrinthine disease, 525
bacteria peculiar to, 516
Cerumen, diminished secretion of, in connection with sclerosis of the tympanic and pharyngeal mucous membrane, 107
excessive secretion of, in connection with naso-pharyngeal catarrh, 106
Cerumen, impacted in the external auditory canal, 105
conditions which resemble it, 139
methods of removing, 110
Ceruminous glands, 105
Cervical glands, involvement of, in cases of mastoid inflammation, 416
Chalky mass in the external auditory canal, 131
Chappell, 265
Chatellier, 258
Cheesy changes in the products of a tuberculous inflammation of the middle ear, 402
Cheesy débris, removal of, from vault of tympanum, 358
Cheesy products a common cause of chronic suppurative inflammation of the middle ear, 329, 342
Chenopodium, oil of, may cause deafness, 520
Cheyne-Stokes respiration, 491
Chimani, 90, 99
Chisels for mastoid bone work, 436
Cholesteatoma of the temporal bone, of unusually large dimensions, 451
Cholesteatomatous disease of the middle ear, 509
Cholesteatomatous material in the vault of the tympanum and the mastoid antrum, 343
Chondromalacosis of the auricle, 86
Chorda tympani nerve, anatomical relations of, 553
effects resulting from cauterization of, 357
Chromic acid, employment of, as a caustic, 356
Chronic catarrhal inflammations of the middle ear, 230
Chronic suppurative inflammation of the middle ear, 328
Cicatrices of the membrana tympani, 76, 364
granulating, 366
Cicatricial reproductions of the membrana tympani, 339
Ciliated cells, inner and outer, of Corti's organ, 558, 560
Circumscribed inflammation of the external auditory canal, unusual cases of, 117
Cirsoid aneurism of the auricle, 99
Clark, Sir Andrew, 254
Classification of middle-ear diseases, 198
Cleft lobule, 100
Climate, influence of, upon a chronic catarrhal inflammation of the middle ear, 241
Cochlea, 553, 558
hemorrhage into, 522
Cochleal whorl, transverse section of, 557, 561
Cochleal whorls, relations of, to one another and to neighboring parts, 557
Cold applications in acute inflammations of the middle ear, 311, 313
Cold in the head, pathology of, 199
Columella, 549, 551
Concha, 82
Condensing mastoid osteitis, probably an invariable result of a chronic suppurative inflammation of the mastoid antrum, 447

Condylar veins, phlebitis of, 461
Condylomata of the external auditory canal, 151
Congenital fistula of the ear, 103
Connecting-pieces, intermediate, in Corti's organ, 559
Contrecoup, fractures of the temporal bone by, 380
Convulsions, in abscess of the brain, 491
in patients with adenoid vegetations, 261
significance of, in mastoid disease, 418
Cord-like band in the external auditory canal, 144
Cornu humanum (cornu cutaneum) of the auricle, 98
Corrosion-preparation, metallic, of the pneumatic spaces of the middle ear 407
Corti's fibres, first row of (=inner pillars), 559
Corti's first row of teeth, 559
Corti's membrane, 558, 561, 567
Corti's organs, 558, 559
nature of vibrations of, 569
sympathetic and passive vibrations of, 568, 570
total estimated number of, 565
Corti's rods or fibres, 559, 560
Cotton-carriers, 24, 211
for use in making applications to the pharyngeal vault, 284
Cowen, William, 540
Cupola of the scala vestibuli, 558
Curettes, 25
Gottstein's, 272, 274
Cuticular motion, horizontal, in the external auditory canal, 149
Cyst-like tumors of the membrana tympani, 79
Cysts of the external auditory canal, 177
of the membrana tympani, 396
Czermak, 254

Dalby, Sir William, 396
Danziger, 172
Deafness due to cerebral hemorrhage, 528
due to labyrinthine disease, 522, 523, 524, 525, 526, 527, 528, 530, 531, 535, 536
for certain tones, 52
of boiler-makers, 49
temporary, due to cerebral embolism, 527
various degrees and rapidity of development of, 47
Deformities of the auricle, 102
of the malleus, 386
of the nasal septum, 286
Deiters, 559
Deiters' cells, in Corti's organ, 558
Delafield, Francis, 176
Delavan, D. Bryson, 267, 270, 286
Delirium, significance of, in mastoid disease, 418
Delstanche, 172
Denker, 165
Dental engine, employment of, in operations upon the osseous external auditory canal, 170
Desquamative inflammation of the external auditory canal, 138
often mistaken for impacted cerumen, 139
Desquamative processes in the middle ear, 329, 358
Diabetes insipidus in a case of chronic inflammation of the external auditory canal, 135
Diabetes mellitus complicated by mastoid disease, 426, 471
Diabetes renders tympanic mucous membrane more vulnerable to assaults of micro-organisms, 200
Diachylon ointment, Hebra's, 85
Diaphragm, membranous, in the external auditory canal, 146
Diarrhœa, in infective thrombosis, 463
Diastasis in some part of the temporal bone, 381
Dieting, effects of, in the treatment of eczema of the ear, 84
Diffuse inflammation of the external auditory canal, 121

Diplacusis, 519
Diplacusis binauricularis, 538
Diplacusis monauricularis, 537
Diploëtic spaces of the mastoid process, 405
Discharge from the ear, physical characteristics of, 45, 62
sources of, 61
Dizziness or faintness caused by the use of the syringe in the external auditory canal, 29
Double-curved catheters of Noyes, 196
Double hearing, 519, 537, 538
Douching with hot water an effective therapeutic agent in acute inflammations of the middle ear, 321
Downie, 261
Drowsiness, significance of, in mastoid disease, 418
Drum-membrane, abnormal depression of the, 71
abnormal distention of, by an excess of air in the tympanic cavity, 71
anatomical relations of the, 542
artificial substitutes for the, 371
atrophy of the, 70
blood-supply of the, 570
bound to promontory by adhesions, 71, 77, 367
calcareous deposits in the, 68, 368
changes in position of the, 206
cicatrices of the, 76, 339, 364
cyst-like tumors of the, 79, 396
deformed, 367
desquamative inflammation of the, 141
distension of the, by an excess of air in the tympanum, 78
eczematous lesions of the, 80
granulating cicatrices of the, 366
granulations upon outer surface of the, 79
horn-like transformation of the, 363
horny growth of the, 76
hyperæmia of the, 66
Drum-membrane, inclination of the, to axis of external auditory canal, 18
normal, 64
normal position of the, 206
not to be incised for the evacuation of fluid contained in the tympanic cavity, 228
paracentesis of the, 316
perforations in the, 79, 367
probing the, 179
rupture of the, 375
syphilitic lesions of the, 81
thickening of the, 70, 363
tuberculous lesions of the, 81
vascular new-growths of the, 75
without the malleus, 75
Ductus cochlearis, 555, 556, 559, 567
Ductus endolymphaticus, 556
Duplay's bivalve speculum, 251
Dupuytren, 100
Dwyer's mouth-gag, 273

Earaches often underestimated by non-professional persons, 296
Ear cough, 141
Ear-douche, Angelo's, 30
Ear, hemorrhage from the, after an injury of the head, 49
routine method of examining the, 1
Eczematous inflammation of the auricle, 82
of the external auditory canal, 123
Eichler, 572
Electro-cauteries, employment of, in the treatment of adenoid vegetations, 270
Elephant's ear, peculiarities of, 551
Embolism a possible cause of labyrinthine disease, 523
Emissary vein, mastoid, 409
Endolymph, labyrinthine, 556
of the cranial cavity, 556
Engleman, George T., 145
Enteritis, infective, in thrombosis of the sigmoid sinus, 463
Epidemic cerebro-spinal meningitis,

as a cause of labyrinthine disease, 525
Epidemic parotitis, as a cause of labyrinthine disease, 524
Epithelioma of the auricle, 97
Equilibrial sense, organ of, located in the semicircular canals, 570
Equilibrium, disturbance of, in labyrinthine disease, 523, 524, 525, 526, 527, 529, 530, 531, 535
Eustachian bougies, 217
Eustachian catarrh, 206
Eustachian catheter, 187, 189, 194, 214
Eustachian tube as a drainage channel for the middle ear, 37
blood-supply of, 573
effects of narrowing of, upon the membrana tympani, 55
functions of, 542
injections into the, 216
narrowing of; alterations in the membrana tympani which show the existence of this condition, 72
ventilation and drainage of, interference with, 232
Examination of the middle ear, 179
Excision of the ossicles, 360
Exercise, physical, value of, in the treatment of gouty inflammations of the ear, 127, 246
Exostoses of the external auditory canal, 166
External auditory canal, carcinoma of, 171
chalky mass in the, 131
circumscribed inflammation of, 113, 117
desquamative inflammation of, 138
diffuse inflammation of, 121, 126
extruding power possessed by walls of, 105
foreign bodies in, 155
gouty inflammation of, 128
impacted cerumen in, 105
movement outward of its epidermal covering, 149
External auditory canal, necrosis of osseous portion of, 118
syphilitic disease of, 151, 532, 535
External ear, veins of, 571
Extradural abscess, 488, 509
Extra-labyrinthine (probably cerebral) hemorrhage, as a cause of deafness, 528
Ewing, 510

FACIAL CANAL, 410
Facial expression, in cases of adenoid vegetations in the naso-pharyngeal cavity, 259
Facial nerve, relations of, to the middle ear, 38
Facial paresis, in mastoid disease, 416
Fahnestock's guillotine, 279
Faintness as a result of syringing the ear, 29
Fallopian canal, 555
False aneurism of the posterior auricular artery, 316
False membranes in the middle ear, 366
Falx cerebri, 572
Faucial catheter of Pomeroy, 196
Faucial tonsils, hypertrophy of, 277
Fenestra ovalis, 543, 548
Fenestra rotunda, 543
Fibroid tumors of the auricle, 96
Fibroma of the middle ear, 388
Fistula of the ear, congenital, 103
Foramina cribrosa, 555
Forceps, angular, for use in the external auditory canal, 22
Forehead-mirrors, 13, 19, 249
Foreign bodies in the external auditory canal, 155
in the middle ear, 373
Formalin sterilizer, 431
Fossa conchæ, 82
Fossa of Rosenmueller, 252
Fractional method of recording the hearing distance, 6
Fracture of the malleus, 377
Fractures of the temporal bone, hemorrhage from the ear in, 382

Fractures of the temporal bone, watery discharge from the ear in, 383
Fraenkel's cutting forceps, 288
Frankenberger, 266
Friedrich, 258
Frost-bite of auricle, 91, 92, 101
Fulness, sensation of, in the ear, 54
Furunculosis of the external auditory canal, 113

Galton's whistle, 10
Galvano-cautery, employment of, in the treatment of enlarged faucial tonsils, 279
in the treatment of hypertrophy of the nasal mucous membrane, 285
Ganglion cells in the modiolus, 561
Ganglion spirale of the cochlea, 559
Garrod, 236
Giampetro-Löwenberg method of catheterizing the Eustachian tube, 194
Giantism, relationship of, to adenoid vegetations, 262
Gillette, 261
Glaserian fissure, diastasis along the line of the, 385
Goodwillie's plug-placer, 285
Glottis, spasm of, from applications of silver nitrate to the pharyngeal vault, 211
Gottstein's curettes, 272, 274
Goutiness, a cause of diffuse inflammation of the external auditory canal, 125, 130
a factor in the causation of a chronic catarrhal inflammation of the middle ear, 204, 234
influence of, upon inflammations of the ear, 301
Gouty inflammation of external auditory canal, illustrative cases of, 128
mistaken for sarcoma, 126
treatment of, 126
Gowers, 493
Gradenigo, 520
Gradle's adenoid forceps, 272
Graduated tuning-forks, 8
Granulation-growths a common cause of chronic suppurative inflammation of the middle ear, 329
Graves, 234
Gravity douche, employment of, with hot water, in the treatment of an acute inflammation of the middle ear, 313
Green, J. Orne, 97, 102, 162, 163, 170, 171, 173, 396, 417, 540
Griesinger's symptom, 462
Grippe may be a cause of labyrinthine disease, 523
Gruber, Josef, 12, 17, 102, 166, 553
Gunshot injuries of external auditory canal, 165
Guye, 262

Habenula perforata, 559
Habermann, 11
Hackley, Charles, 168
Hæmatoma of the auricle, 86
Hair cells, inner, of Corti's organ, 558
Hammer. *See under Malleus.*
Hamulus, 557
Hand mirrors, 13
Harrison Allen, 256
Harrison Allen cotton-carrier, 24
Hartmann, Arthur, 266, 396, 556
Hassenstein's apparatus, 371
Haug, 171
Headache, significance of, in mastoid disease, 418
Hearing, anomalies of, 536
causes of variations in, 50
diminished range of, 52
disturbances of, 47
Hearing better in the midst of noise, 52
Hearing cells, in Corti's organ, 561
Hearing distance, mode of recording the, 6
Hearing power, tests of the, 3
Heat and cold as aural therapeutic agents, 311

Heat, uncomfortable sense of, in the external auditory canal, 124
Hebra's diachylon ointment, 85
Helicotrema, 556, 557
Helix, 82
Helmholtz, 545
Helmholtz's resonators, 551
theory, 562
Hemorrhage from the ear, after excision of an aural polypus, 354
due to ulceration of the carotid artery or the sigmoid sinus, 449
significance of, in fractures at the base of the skull, 382
Hemorrhage from the nose, an occasional symptom of hypertrophied adenoid tissue in the vault of the pharynx, 260
sometimes associated with thrombosis of the sigmoid sinus, 465
Hemorrhage from the wound, in mastoid operations, 443
Hemorrhage in the labyrinth, 518
in tonsillotomy, 281
Henle, 557, 572, 573
Hensen, 544, 565, 566, 568
Hensen's band, 558
supporting cells, in Corti's organ, 558
theory, 563, 568
Heredity, influence of, in development of tuberculous disease of the middle ear, 201
Hernia cerebri, 515
Herpes zoster of the auricle, 102
Hessler, 487
Heurteloup's artificial leech, 314
Highmore's antrum, suppurative disease of, a cause of middle-ear catarrh, 243
Hoffmann's rongeur forceps, 439
Hook-shaped manubrium mallei, 386
Hooper, 269
Horny growth of membrana tympani, 76
Horny transformation of the membrana tympani, 363
Hun, 87
Huschke's hearing teeth, or Corti's first row of teeth, 559
Hutchinson, 533
Hydrogen dioxide, usefulness of, in the removal of cheesy débris from the vault of the tympanum, 359
Hydrotympanum, 219
Hyperæmia of the skin behind the auricle, in mastoid disease, 414
Hyperostosis of external auditory canal, 166
of the bony wall of the tympanum, 387
Hypertrophy of Luschka's tonsil, 254
Hypophysis, 572
Hyrtl, 409

Iced water, employment of, by means of Leiter's coil, in the treatment of an acute inflammation of the middle ear, 313
Imaginary foreign bodies in the external auditory canal, 158
Incisions often useless in alleviating the pain of furuncles in the external auditory canal, 116
Incisura intertragica, 82
Incus and malleus, relations of, to each other and to the surrounding parts, 543
Inflammations of the ear, characteristic differences between, 39
Inflating the middle ear, different methods of, 180
Inflations in the treatment of chronic catarrhal inflammation of the middle ear, 245
not advisable in the treatment of suppurative inflammations of the middle ear, 326
Inherited syphilis, tardily developed, as a cause of deafness, 531, 534
Injections into the Eustachian tube, 216
Inner epithelial supporting cells of Corti's organ, 558
Inner hair cells of Corti's organ, 558
Inner pillars of Corti's organ, 558
Instruments, sterilization of, 431

Intercavernous sinuses, anterior and posterior, 572
Intermittent, almost complete deafness, 521, 536
Internal carotid artery, 571, 572
Internal ear, 34
Internal maxillary artery, 571
Intra-ocular inflammatory changes, in thrombosis of the sigmoid sinus, 463
Intratympanic injections, 322
Intratympanic new-growths, 387
Iodide of potassium in supposed syphilitic disease of the labyrinth, 330
Iodoform, usefulness of, in the treatment of foul conditions of the middle ear, 360
Itching in the external auditory canal, 57

Jansen, 440, 512
Josselin de Jong, 174
Jugular foramen, 572
Jugular vein, internal, cord-like condition of, when thrombosed, 462
internal, ligation of, in thrombosis of the sigmoid sinus, 484
Jurka, 171

Keratitis parenchymatosa, in a case of deafness due to tardily developed inherited syphilis, 534
Kessel, 171, 553
Kipp, Charles J., 91, 99, 316, 535
Klebs, 517
Knapp, Herman, 103, 396, 474, 495, 515, 534, 538
Knife, proper pattern of, for incising furuncles in the external auditory canal, 116
Koch's lymph, injections of, in a case of tuberculous disease of the temporal bone, 508
Koerner, 491, 513, 515
König's steel rods, 10

Labyrinth, the, 543, 554
Labyrinth, blood-supply of, 573
hemorrhage in, 518
leukæmic disease of, 520
primary acute inflammation of, 519
syphilitic disease of, 541
Labyrinthine blood-vessels, rupture of, due to excessive strain, 523
vasomotor paresis of, 518, 535
Labyrinthine circulation disturbed in cases of hypertrophy of Luschka's tonsil, 264
Labyrinthine disease as a sequel to the grippe, 523
may occur in the course of mumps, 524
occurrence of, during pregnancy, 522
of a syphilitic character, 530, 531, 534
of reflex origin, 526
of unknown origin, 528
resulting from epidemic cerebro-spinal meningitis, 525
simulated by cerebral embolism, 527
Labyrinthine fluid, how disturbed by the excursions of the foot-plate of the stapes, 547
Labyrinthine mechanism, mode of action of, 562
Lachrymal ducts, escape of air through, in inflations according to Politzer's method, 181
Lamina reticularis, of Corti's organ, 560
Lamina spiralis membranacea, of Corti's organ, 560, 561
wave-like disturbances of, limited in area, 570
Lamina spiralis ossea, 554
commencement of, on lower wall of vestibule, 547
Lamina velamentosa (=lamina reticularis), 559
Laminated masses of epithelium in the external auditory canal, 139
in the middle ear, 346
Lange, Frederic, 476

Larvæ of the house-fly in the external auditory canal, 156
Laryngismus stridulus in patients with adenoid vegetations, 261
Lateral sinus, 572
Leeches, employment of, in the treatment of acute inflammations of the middle ear, 314
Lennox Browne, 260
Leukæmic disease of the labyrinth, 520
Lewis, Robert, Jr., 167, 231, 238, 247, 356, 451, 459, 498, 509
Ligamentum annulare of the stapes, 547
Ligamentum anticum of the malleus, 544
Ligamentum spirale of Henle, 557, 558, 560
Light, sources of, for examinations of the ear, 19
Limbus laminæ spiralis, 558
Limited range of audition, 536
Lips, power of reading the, 6
Liquor potassæ, employment of, as a solvent of hardened cerumen, 112
Lithæmia a cause of chronic catarrhal inflammation of the middle ear, 237
Lithæmia a cause of diffuse inflammation of the external auditory canal, 125
Loaded string, principle of, 567
Lobule of the auricle, 82
Löwenberg, 184, 254
Lucae, 8, 11
Lupus of the auricle, 99
Lyman, 236
Lymphoid tissue in the vault of the pharynx, injurious effects of, when hypertrophied, 201
removal of, by operative measures, 272

Macdonald, 267
Macewen, 427, 430, 460, 462, 490, 492, 513
MacFarland, 539
Mackenzie's bull's-eye condenser, 247
Maculæ acusticæ, 558
Maculæ cribrosæ internæ, 555
Maggots, living, in the external auditory canal, 347
Malformations of the auricle, congenital, 102
of the malleus, 386
Malignant growths of the external auditory canal, 171
of the middle ear, 395
Malleable steel cotton-carriers, 24, 211, 284
Malleo-incudal joint, peculiarities of, 545
Mallet of rawhide, for operations upon the mastoid process, 437
Malleus, absence of, 75
fracture of the, 377
Malleus and ambos, relations of, to each other and to the surrounding parts, 543
Manubrium mallei, hook-shaped, 76, 386
Marcé, 449
Markoe, Thomas M., 496
Mastoid cells, blood-supply of, 573
Mastoid disease, acute, 404
chronic, 446
in diabetic individuals, 471
of gouty origin, 134
Mastoid hook guide, 434
Mastoid operation: preliminary measures, 430; the external incision, 432; separation of the periosteum from the bone, and control of the bleeding, 433; operative work upon the bone structures, 434; accidental occurrences, 442; after-treatment, 443; stage of convalescence, 445
Mastoid process, condensing osteitis of, 447
Mastoid vein, over-distention of, 461
Mathewson, Arthur, 170
Membrana basilaris, of Corti's organ, 560
Membrana flaccida, 65
Membrana tectoria (Urban Pritchard)

or Corti's membrane, 558, 561, 563, 567
Membrana tympani, abnormal depression of, 71
abnormal distention of, by an excess of air in the tympanic cavity, 71
anatomical relations of, 542
artificial substitutes for, 371
atrophy of, 70
blood-supply of, 570
bound to promontory by adhesions, 71, 77, 367
calcareous deposits in, 68, 366
changes in position of, 206
cicatrices of, 76, 339, 364
cyst-like tumors of, 79, 396
deformed, 367
desquamative inflammation of, 141
distention of, by an excess of air in the tympanum, 78
eczematous lesions of, 80, 130
granulating cicatrices of, 366
granulations upon outer surface of, 79
horn-like transformation of, 363
horny growth of, 76
hyperæmia of, 66
inclination of, to axis of external auditory canal, 18
normal, 64
normal position of, 206
not to be incised for the evacuation of fluid contained in the not acutely inflamed tympanic cavity, 228
paracentesis of, 316
perforations of, 79, 367
probing the, 179
rupture of the, 375
syphilitic lesions of, 81
thickening of, 70, 363
tuberculous lesions of, 81
vascular new-growths of, 75
without the malleus, 75
Membrana tympani and ossicles, anatomical relations of, 551
Membrana tympani secundaria, 543
Membrana tympani secundaria, excursions of, 547
Membrane of Corti, 558
Ménière's disease, 518, 529, 541
Meningitis, 488
tuberculous, 495, 506
Mercury, acid nitrate of, employment of, as a caustic, 356, 391
Meyer, of Copenhagen, 254, 255, 265
Meyer, of New York, 274
Meyer's vulcanized rubber nasal tubes, 290
Mial's saw, 287
Micro-organisms, different varieties of, found in the middle ear, 201
influence of, in the causation of suppurative inflammations of the middle ear, 42, 293
part played by, in the etiology of middle-ear diseases, 199
Middle ear, acute catarrhal or non-suppurative inflammation of, 208
acute suppurative inflammation of, 292
anatomical relations of, 34, 203, 542
chronic catarrhal or non-suppurative inflammation of, 40, 230, 244
chronic suppurative inflammation of, 328
false membranes in, 366
foreign bodies in, 373
injuries of, 375
malignant growths of the, 395
methods of examining the, 179
new-growths of the, 387
proliferative inflammation of, 199
syphilis of the, 397
treatment of bone caries in, 361
tuberculosis of the, 398
Middle-ear diseases, classification of, 198
general etiology of, 199
Middle-ear pipette, 323
Middle meningeal artery, 571
Modiolus, 558
Moos, 516, 517

Mucus in the tympanic cavity, 219
ropy, significance of, when present in a discharge from the ear, 46
Mumps as a cause of labyrinthine disease, 524
loss of hearing in, 518
Musical tones, diminished range of hearing for, 536
Mussey, 100
Myringotome, 317
Myxo-fibroma of the external auditory canal, 177

Nasal and vault lesions, as causes of chronic catarrhal inflammation of the middle ear, 231
Nasal douche, employment of, a frequent cause of inflammation of the middle ear, 200
Nasal mucous membrane, hypertrophy of, 282
Nasal passages and pharynx, relations of, to the Eustachian tube, 191
Nasal septum, deformities of, 286
Nasal specula, Duplay's bivalve, 251
Zaufal's, 197
Nasal stenosis, effects of, upon the Eustachian tube and middle ear, 233
Nausea and vomiting, as evidence of brain involvement in mastoid disease, 418
Necrosis of osseous external auditory canal, 118
Neumann, 99
Neuralgia of the ear, 58
Neuro-retinitis, in thrombosis of the sigmoid sinus, 463
New-growths of the auricle, 96
of the external auditory canal, 166
of the middle ear, 387
Nitrate of silver solutions in the treatment of diffuse (eczematous) inflammation of the external auditory canal, 126
of naso-pharyngeal catarrh, 246, 284
Nitric acid, employment of, as a caustic, 355, 389
Noise, hearing better in the midst of, 52
North, Alfred, 520
Nosebleed, in hypertrophy of the lymphoid tissue in the vault of the pharynx, 260
in thrombosis of the sigmoid sinus, 463
Nosophen, usefulness of, in the treatment of foul conditions of the middle ear, 360
Noyes, Henry D., 196
Nozzle for ear-douche, proper shape of, 30
Nuel's space, in Corti's organ, 558
Nuhn, 406
Numbness around the ear, 64

Occipital sinus, 572
Occupation, influence of, upon a chronic catarrhal inflammation of the middle ear, 242
Oculomotor nerve, 572
Œdema of the skin behind the auricle, in mastoid disease, 414
Olive oil, introduction of, into external auditory canal, liable to excite a growth of the aspergillus fungus, 112, 143
Ophthalmic vein, engorgement of, in thrombosis of the sigmoid sinus, 463
Optic nerve, 572
Optic neuritis, in abscess of the brain, 491
significance of, in mastoid disease, 418
Ossicles, destruction of, 368
relations of, diagrammatically represented, 551
Ossiculectomy, 360
Osteitis, circumscribed, of external auditory canal, 118
proliferative, of external auditory canal, 119
Osteoma of external auditory canal, 166

Osteophytes, resonating, found in the tympanum of certain animals, 552
Osteo-sarcoma of the external auditory canal, 174
Otalgia, 58
Othæmatoma, 86
Otitis externa, 121
interna, 516
media, 205, 230, 292, 328
Otoliths, 558
Outer pillars of Corti's organ, 558

Packard, Charles, 531
Pain in the ear, significance of, 57
in mastoid disease, 412
in the head, in abscess of the brain, 489
Painless ulceration of the membrana tympani, 400
Panse, 452
Papilla acustica basilaris, 558
Paquelin's thermo-cautery, 100
Paracentesis of the membrana tympani, 316
not necessary in the treatment of accumulations of serum or mucus in the tympanic cavity, 228
Parchment-like diaphragm in the external auditory canal, 146
Pareidt, 87
Parotid abscess, 119
Parotitis, epidemic, as a cause of labyrinthine disease, 524
loss of hearing in, 518
Pars membranosa of the lamina reticularis, 559
Pathology, general aural, 33
Pear-shaped body found suspended in the middle ear, 552
Penicilium glaucum, growth of, in the external auditory canal, 142
Perforations in the membrana tympani, 79, 367
Perichondritis of the auricle, 86
Perilymph, labyrinthine, 555
Periostitis (syphilitic), localized, in the external auditory canal, 532
Periphlebitis of the sigmoid sinus, 460
Peroxide of hydrogen. *See under* Hydrogen dioxide.
Petrosal sinus, inferior, 572, 573
superior, 410
Phalanges, first and second rows of, in Corti's organ, 559
Pharyngeal vault, digital exploration of, 268
Phlebitis of a mastoid emissary vein, 416
of the sigmoid sinus, 460
Photophobia, significance of, in mastoid disease, 418
Photophore, Phillips', 248
Physical exercise, value of, in the treatment of chronic catarrhal inflammation of the middle ear, 246
in the treatment of eczema of the external auditory canal, 127, 128
Pillars of Corti, or Corti's fibres or rods, 558, 560
Pipette of glass, for introducing remedial solutions into the middle ear through a perforation in the membrana tympani, 324
Pituitary body, reflex action of, 263
Pneumatic ear speculum, Siegle's, 77
Pneumatic spaces, mastoid, 409
Pneumonia, metastatic, 464
Pockets in the vicinity of the neck and head of the malleus, 43
Politzer, Adam, 5, 9, 11, 18, 22, 43, 100, 102, 168, 184, 349, 376, 522, 543, 547, 553, 572, 573
Politzer eyelets, 373
Politzer's method of inflating the middle ear, 181, 186, 214
Pollak, 88
Pollen of certain plants, influence of, upon a chronic catarrhal inflammation of the middle ear, 242
Polypoid growths, 349, 355
Pomeroy, Oren D., 93, 107, 196
Porte-acid, of glass, 355

Porus acusticus internus, 558
Posterior auricular artery, 570
false aneurism of, 315
Posterior fold, circumscribed inflammation of, 120, 305
Posterior pocket of the membrana tympani, 553
Potassa, caustic, as a solvent of hardened cerumen, 112
Potassic iodide, large doses of, in the treatment of syphilitic labyrinthine disease, 530, 531, 534
Pregnancy, labyrinthine disease liable to occur during, 522
Prescott Hewett, 383
Pressure, sensation of, in the ear, 54
Pritchard, Urban, 558
Probes, 25
Prolapse of the upper and posterior cutaneous wall of the auditory canal in the neighborhood of the membrana tympani in mastoid disease, 415
Proliferative osteitis of external auditory canal, 119
Promontory, 544
Protector, Stacke's, 455
Prout, J. S., 6
Ptosis, in abscess of the brain, 492
Pulsating sound, of a distinctly musical character, heard in the ear both by the patient and by the physician, 540
Pulsation in the ear, 56
Pulse slow in abscess of the brain, 491
Pyæmia, in mastoid disease, 417
Pyæmic sinus thrombosis, 478

Quinlan's modification of Physick's tonsillotome, 280

Radial nerve twigs of the cochleal portion of the auditory nerve, 558
Ramulus basilaris of the auditory nerve, 558
Randall, B. Alexander, 76, 226, 227, 376, 410
Range of hearing for musical tones diminished, 536
Rawhide mallet, for use in operations upon the mastoid process, 437
Reading the lips, 6
Rectangular frames, in Corti's organ, 559
Reflectors, forehead, 12
Reflex influences in the causation of a catarrhal inflammation of the middle ear, 233
Reflex labyrinthine disturbances, 526
Reflex neuralgia in the ear, 58
Reincke, Carl, 528
Reissner's membrane, 561, 562, 567
Resinol ointment, in the treatment of eczema of the external auditory canal, 85
Resisting powers of the individual, part played by, in acute inflammations of the middle ear, 42
Resonance of one's own voice, 55
Resonating chambers in the elephant's skull, 551
Rest an important agent in the treatment of an acute inflammation of the middle ear, 319
Retinal vessels, congestion of, in abscess of the brain, 491
Retractor, for use in mastoid operations, 437
Retzius, 558
Rhinitis, acute purulent, of children, 258
Rhinoscopic examinations, 251
Richards, Huntington, 375
Rinne's experiment, 11
Rivinian recess, 73
Robertson, 396
Rods, in Corti's organ, 559, 560
Rongeur forceps, usefulness of, in operations upon the temporal bone, 438
Roosa, D. B. St. John, 98, 163, 175, 530, 531, 538, 541
Rosenmüller's fossa, 191, 194
Rüdinger, 555
Rupture of the membrana tympani, 375

Saccule, 555, 556, 557
Salt water, entrance of, into the middle ear, injurious, 200
Santorinian fissures, 18
Sarcoma, erroneous diagnosis of, in a case of gouty inflammation of the external auditory canal, 126
of external auditory canal, 173
Sass' tongue-depressor, 251
Scala tympani, 556
vestibuli, 547, 556
Scalp, abscesses of, in connection with mastoid disease, 417
Scharffer, 269
Schleich's mixture, employment of, as an anæsthetic, in operations for the removal of adenoid vegetations, 274
Schmiegelow, 265
Schrötter's headband, 250
Schwabach, 101
Schwartze, H., 94, 100, 154, 163, 227, 430, 436, 507, 509, 514, 515, 520, 570
Schwartze-Stacke operation, 458
Sclerosis of the mastoid process, 447
of the mucous membrane of the middle ear, 41
Sea-turtle's ear, 549
Secondary tympanic membrane, 543
excursions of, 547
Self-inflations in the treatment of catarrhal affections of the middle ear, 218
Sella turcica, 572
Semicircular canals, 553, 555, 557
Septicæmia, in mastoid disease, 417, 449
Sequelæ of suppurative disease of the middle ear, 363
Serous exudations in the tympanic cavity, 219
Sexton, 396
Sheild, 173
Shrapnell's membrane, region of, 43, 65, 73
Siebenmann, 407, 570, 572
Siegle's pneumatic speculum or tympanoscope, 77, 180
Sigmoid sinus, 409, 572
danger of cutting the, in operations upon the mastoid process, 442
periphlebitis and infective thrombosis of, 460
Silver-nitrate applications to the vault of the pharynx, 210, 246
Silver-nitrate solutions, intratympanic injections of, for purposes of direct vasomotor stimulation, 322
Sinuses, venous, at the base of the brain, 572
Slow cerebration, 490
Snuffing of medicinal solutions or of salt water into the nasal passages not to be recommended, 283, 298
Spear, Edmund D., 10
Specula, aural, 12
mode of introducing into the external auditory canal, 17, 21
Specula, nasal, 251
Speech, disordered, significance of, in mastoid disease, 418
Spencer, H. N., 540
Spheno-parietal sinus, 572
Spina tympanica posterior, 544
Spiral nerve fibres of the cochlea, 558
Spoken words as a test of the acuteness of the hearing, 6
Spraying the nasal and naso-pharyngeal mucous membrane, 283
Stacke's radical operation, 454
Staggering gait, in abscess of the brain, 492
Stamp mills, operatives in, are liable to become deaf, 242, 519
Stapedectomy, 370
Stapedio-vestibular ligament, 548, 549
Stapedius muscle, action of, 549, 550
tendon of, 544
Stapes, destruction of, does not necessarily rob the patient of a useful degree of hearing, 369
relations of, 544
Stapes foot-plate, mechanism of, 545
Staphylococcus in middle-ear inflammations, 201

Starr, M. Allen, 492
Sterilization of instruments, 431
Stirrup. *See under Stapes.*
Stomach indigestion a cause of labyrinthine disease, 526
Strabismus, in abscess of the brain, 492
  significance of, in mastoid disease, 418
Strawbridge, 98, 103
Streptococcus in middle-ear inflammations, 201, 294
  invasion of the labyrinth by, 516
Stylo-mastoid artery, 571
Sulcus spiralis internus, 558
Superficial temporal artery, 570
Superior and inferior sagittal sinuses, 572
Supporting cells, inner epithelial, of Corti's organ, 558
Sympathetic and passive vibrations of Corti's organs, 568, 570
Symptoms, aural, analysis of, 47
Syphilis, inherited, as a cause of deafness, 531, 534
Syphilitic disease of the external auditory canal, 151
  of the middle ear, 397
Syphilitic labyrinthine disease, 530, 531, 534
Syringes for aural purposes, 26
Systolic bruit in ear, both subjective and objective, 539
Swain, Henry L., 489

Temperature of the body an uncertain indication of the presence of serious mastoid disease, 417
Temporal artery, superficial, 570
Temporal bone, fractures of, by contrecoup, 380
  of a new-born child, 17
Temporo-maxillary joint, arthritis of, 60
  relations of, to external auditory canal, 542
Temporo-sphenoidal lobe of the cerebrum, abscess of, 513
Tenderness on pressure behind the auricle, in mastoid disease, 413
Tendon of the stapedius muscle, 544
  of the tensor tympani muscle, 544
Tensor tympani muscle, 543
  action of, 550
  tendon of, 544
Tervaert, 174
Tests of the hearing power, 3
Testut, 411
Third tonsil, enlarged, 254
Thrombosis of the sigmoid sinus, 460
Tobacco-smoking, influence of, upon a chronic catarrhal inflammation of the middle ear, 241
  irritating effects of, upon inflamed mucous membrane of the pharyngeal vault, 215
Tongue-depressors, 250
Tonsillotome, Physick's, 279
Tonsillotomy, 280
Tonsils, faucial, hypertrophy of, 277
Toynbee, 234
Toynbee's artificial drum membrane, 371
Tractus spiralis foraminulentus, 555
Tragus, 82
Transverse sinus, 572
Triquet, 101
Tubercle bacilli in the pus of an extradural abscess, 509
Tuberculosis of the middle ear, 398
  of the temporal bone, 506
Tuning-fork tests, 7
Turbinated bodies, 191, 253
  hypertrophy of, 283
Türck, 254
Tympanic cavity, anatomical relations of, 542
  blood-supply of, 571
  hemorrhagic exudations in, 226
  mucus in, 219
  serous fluid in, 219
  vascular new-growth in, with intact membrana tympani, 68
  veins of, 573
Tympanic membrane, blood-supply of, 570

Tympanic membrane, desquamative inflammation of, 141
exfoliation of the epidermal covering of, 148
Tympanoscope, Siegle's, 77

Umbo of the membrana tympani, 543
Urbantschitsch, 542, 553
Uterine disease, a cause of middle-ear catarrh, 243
Utricle, 555, 556, 557

Valsalva's experiment, employment of, as an aid in ascertaining the condition of the membrana tympani, 180
Van Gieson, 350, 395
Vas spirale of Corti's organ, 595
Vascular new-growths of the middle ear, 388
with intact membrana tympani, 68
Vascular relations of the different parts of the ear, 570
Vasomotor paresis, a characteristic of eczema of the external auditory canal, 123
of the tympanic mucous membrane, 320
transient, of the labyrinthine blood-vessels, 535
Vault of pharynx, convenient method of applying silver nitrate in solution to, 210
digital exploration of the, 197
Venous sinuses at the base of the brain, 572
Ventilation and drainage of the Eustachian tube, interference with, 232
Vertigo, in abscess of the brain, 492
in caries of the temporal bone, 450
in ear diseases, 62
in labyrinthine disease, 523, 524, 525, 526, 527, 529, 530, 531, 535
Vestibule of the labyrinth, 553, 554, 555
Vidian arteries, 573
Volkmann's spoons, usefulness of, in operations upon the mastoid process, 437
Voltolini, 254, 519
Vomiting, as an evidence of brain involvement in mastoid disease, 418
in abscess of the brain, 490
Von Esmarch's rongeur forceps, 439
Von Troeltsch, 162, 571
Vulnerability of the tympanic mucous membrane, part played by, in inflammations of the middle ear, 200

Wagenhäuser, 165
Watch-test, 4
Weber's experiment, 8
Weinlechner, 99, 100
Weir, Robert F., 16, 175, 210, 376, 388
Welch, 175
Welsbach light, 248
Wendt, 90, 94
Whiting, Frederic, 461, 462, 463, 478, 485
Wilde's ear specula, 12
Wilde's incision, 315
modified, 533
Wilde's polypus snare, 352
Wind-instrument players liable to rupture of labyrinthine blood-vessels through excessive strain, 523
Wood, James R., 496
Wormseed oil, when taken internally, may cause deafness, 520
Wounds of external auditory canal, 164
Wright's snare, 286

Xeroform, 442

Yearsley, 371

Zaufal, 484
Zaufal's specula, 197
Zona arcuata, of Corti's organ, 560
perforata, of Corti's organ, 560
Zuckerkandl, 64, 405, 544

DUE

Date ~~Issued~~

DEC 6	1933		

RT12
898E